RESEARCH ARTICLE Indian Journal of Animal Research, Volume 60 Issue 2: 240-243 (February 2026)

Analysis of Uterine and Systemic Parameters in Fertile and Barren Mares

Aeknath Virendra[1], Sarita U. Gulavane[1], Firdous A. Khan[1], Ravindra J. Chaudhari[1], Sandeep M. Gaikwad[1], Raju R. Shelar[1], Nilesh R. Dagli[1], Shailesh D. Ingole[1], Varsha D. Thorat[1], Zulfikar A. Ahmed[1] **10.18805/IJAR.B-4893**

ABSTRACT

Background: Breeding success in mares is dependent on both local and systemic factors. Uterine conditions such as endometritis have a negative impact on fertility. Similarly, poor body scores and systemic inflammatory conditions are associated with reduced pregnancy rates. This study aimed to investigate differences in uterine and systemic status between fertile and barren mares.

Methods: Uterine ultrasonographic findings, endometrial cytology, body condition score, rectal temperature and complete blood count were evaluated in sexually mature fertile (n=15) and barren (n=15) thoroughbred mares. Differences in the mean values of various parameters between the two groups were evaluated for statistical significance through independent t-tests using commercial statistical software.

Result: Compared to fertile mares, barren mares had a significantly higher number of neutrophils and a significantly higher neutrophils: epithelial cell ratio as per endometrial cytology. The ultrasonography revealed presence of uterine fluid in 12 out of the 15 barren mares. Uterine fluid was not observed in any of the fertile mares. No differences in body condition score, rectal temperature and complete blood count were observed between the two groups. These results suggest that infertility in mares results predominantly from alterations in the uterine health.

Key words: Body condition score, Equine, Fertility, Ultrasonography, Uterine cytology.

INTRODUCTION

Mare fertility is paramount to the success of an equine breeding operation. Mares are typically classified into fertile and barren, depending on their pregnancy status after the breeding season. Establishment of a successful pregnancy is based on the interaction of local and systemic factors (Fox *et al.,* 2016). Uterine status is directly related to fertility and, therefore, its evaluation is essential prior to breeding mares. Endometritis has been reported in about 25-60% of barren mares (Card, 2005) and, consequently, results in great losses to the equine breeding industry. The condition can be diagnosed on the basis of history coupled with external examination, transrectal palpation and ultrasonography, vaginal examination, endometrial cytology, bacterial culture and biopsy (McCue, 2008; LeBlanc and Causey, 2009; LeBlanc, 2010). Pregnancy failures resulting from endometritis have been attributed to conception failure (Bracher *et al.,* 1996; Gilbert, 2011), direct negative effects on the embryo, increased prostaglandin production resulting in luteolysis, or a combination of these factors (Allen, 2001). Apart from the uterine factors, systemic status of the mares influences their fertility. Body condition score (BCS) appears to be important for successful reproduction and rearing of a healthy foal (Morley and Murray, 2014). The BCS is based on visual assessment and palpation of fat in six areas of the horse's body, namely the lumbar spine, ribs, tail, area behind the shoulder, neck and withers (Henneke *et al.,* 1983). Another factor that can influence the pregnancy outcome in mares is the presence of any systemic inflammatory or infectious condition, commonly characterized by the presence of fever and changes in the blood parameters such as CBC.

Considering that breeding success is influenced by multiple factors, the goal of this study was to evaluate the uterine and systemic status of fertile and barren mares. The specific objectives were to investigate the differences in uterine (ultrasonographic appearance of the uterus and endometrial cytology) and systemic parameters (BCS, rectal temperature and CBC) between fertile and barren mares.

[1]Department of Animal Reproduction, Gynecology and Obstetrics, Mumbai Veterinary College, Mumbai-400 012, Maharashtra, India.

Corresponding Author: Aeknath Virendra, Department of Animal Reproduction, Gynecology and Obstetrics, Mumbai Veterinary College, Mumbai-400 012, Maharashtra, India.
Email: draeknathvirendra@gmail.com.

How to cite this article: Virendra, A., Gulavane, S.U., Khan, F.A., Chaudhari, R.J., Gaikwad, S.M., Shelar, R.R., Dagli, N.R., Ingole, S.D., Thorat, V.D. and Ahmed, Z.A. (2026). Analysis of Uterine and Systemic Parameters in Fertile and Barren Mares. *Indian Journal of Animal Research*. **60(2):** 240-243. doi: 10.18805/IJAR.B-4893

Submitted: 21-02-2022 **Accepted:** 12-08-2022 **Online:** 22-08-2022

MATERIALS AND METHODS

The present study was conducted during 2021-2022 at various stud farms in and around Pune and the Department of Animal Reproduction, Gynaecology and Obstetrics, Mumbai Veterinary College, Mumbai. Mares were classified

into fertile (n=15) and barren (n=15) on the basis of their history and breeding records. All mares were reared under standard feeding and managemental conditions.

Evaluation and sample collection

Each mare was restrained in a travis and examined for body condition score and rectal temperature followed by transrectal ultrasonography and collection of uterine swabs for endometrial cytology. Blood samples were also collected in EDTA blood collection vials followed by CBC analysis using an automated CBC analyser.

Body condition score

The body condition of all mares were accessed on the basis of Henneke Body Condition Scoring System (Henneke *et al.*,1983; Hoopes *et al.,* 2019).

Rectal temperature

Rectal temperature was measured using a calibrated digital thermometer manufactured by Omron Healthcare India Pvt. Ltd., Gurgaon, Haryana, India.

Ultrasonographic examination

A real-time B-mode ultrasonography machine (SonoScape A5) with a 5-7.5 MHz multi-frequency linear array trans-rectal transducer was used to scan the uterus (Fig 1).

Endometrial cytology

Samples were collected using double-guarded sterile swabs. Immediately after collection of the intra-uterine swabs, the swabs were rolled on a clean glass slide followed by fixing of smear with 10% buffered formalin and staining with Fields stain. The stained slides were observed under high power (40x) microscope (Fig 2). The number of neutrophils and epithelial cell in 10 microscopic fields on each slide were counted and recorded. The results were evaluated as per Ferris *et al.* (2015).

Statistical analysis

The quantitative data were analysed by t-test to compare the mean values using SPSS 24 software (IBM SPSS for Windows, Version 24, IBM SPSS Inc.). Results were

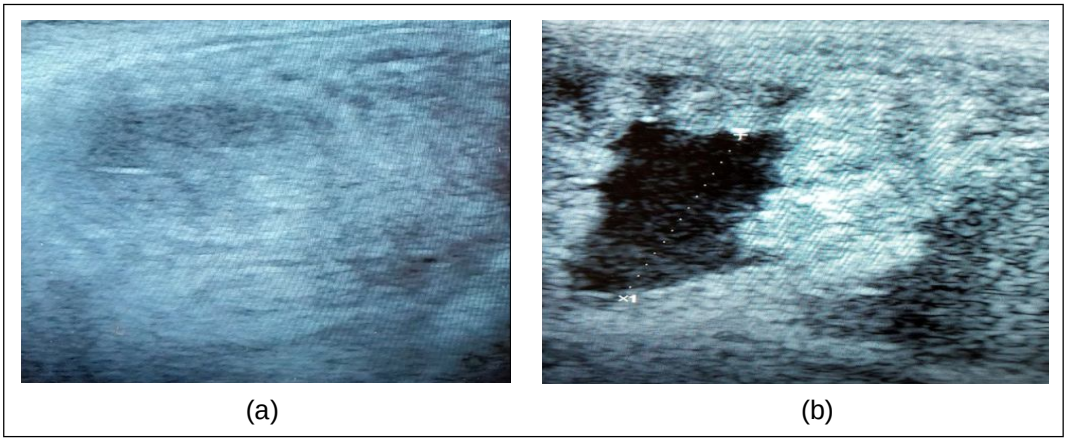

Fig 1: Representative uterine ultrasonographic images from a fertile mare (a) and a barren mare (b).

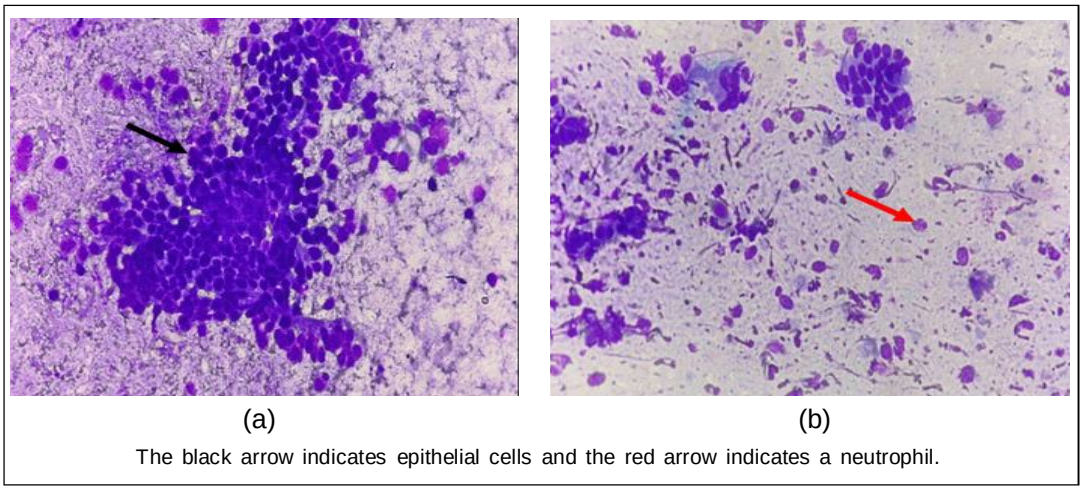

Fig 2: Representative endometrial cytology images from a fertile mare (a) and a barren mare (b).

described as the mean±S.E. P-values less than 0.05 were considered significant.

RESULTS AND DISCUSSION

Uterine parameters

On transrectal ultrasonographic examination of the uterus, intrauterine fluid was observed in 12 out of the 15 barren mares and none of the fertile mares (n=15) showed presence of intrauterine fluid. These findings are in agreement with previous studies that reported presence of intrauterine fluid in a vast majority of barren mares (Ibrahim *et al.,* 2015; Barbary *et al.,* 2016; Kouider *et al.,* 2017; Derbala *et al.,* 2018). The presence of intrauterine fluid in the barren mares suggests that they had endometritis because intrauterine fluid is considered as a reliable indicator of endometritis (Brinsko *et al.,* 2003; Barbary *et al.,* 2016). This assumption is further supported by the results of endometrial cytology. As compared to fertile mares, barren mares had significantly higher neutrophil number and neutrophil: epithelial cell ratio (Table 1). The greater abundance of neutrophils observed in the endometrial smears of barren mares is attributed to increased blood flow and diapedesis of the neutrophils associated with endometritis. All the barren mares in this study had severe inflammation of the uterus as indicated by an average of more than 5 neutrophils per high power field (Ferris *et al.,* 2015). These mares also had a greater than 1% neutrophils: epithelial cells ratio (Table 1). This ratio is considered as a very sensitive cytological evaluation approach for diagnosing -endometritis in mares (Sikora *et al.,* 2015). There is a variation in the cut-off percentages used for diagnosing endometritis in mares ranging between 1% and 5%. The barren mares in the present study had neutrophils: epithelial ratios that exceeded 5% and the average ratio for all 15 mares was in a close agreement with Rua *et al.* (2018) who reported an average of 10.1% in mares with endometritis.

Table 1: Differences in uterine parameters (mean±SE) between fertile and barren mares.

Parameters	Barren mares	Fertile mares
Neutrophils	97.8 ± 6.3^{A}	0.46 ± 0.13^{B}
Epithelial cells	773.3±13.0	922±33.8
Neutrophils: Epithelial cells (%)	12.6 ± 0.83^{A}	0.04 ± 0.01^{B}

Systemic parameters

As shown in Table 2, no differences in the rectal temperature, BCS and CBC parameters were observed between fertile and barren mares. Previous studies conducted by Henneke *et al.* (1983), Hoopes *et al.* (2019), Munoz *et al.* (2021) suggested that the BCS of the brood mares should lie between 4 to 7. In our study, the BCS of all the mares, regardless of their fertility status, was in the 4 to 7 range. Similarly, rectal temperature and CBC values were within the normal range. Hall *et al.* (2019) recorded that the normal rectal temperature in case of mares is 96.6 to 100.9°F. The blood parameters in equines suffering from endometritis were previously evaluated by Gavazza *et al.* (2002) who

Table 2: Differences in systemic parameters (mean±SE) between fertile and barren mares.

	Parameters	Fertile mares	Barren mares
	BCS	$5.40^{A}\pm0.13$	$5.46^{A}\pm0.13$
	Rectal temperature	$99.77^{A}\pm0.07$	$100.04^{A}\pm0.06$
	Haemoglobin (11-18 gm%)	13.7	14.3
	Erythrocyte's count (6.5-13 million/cmm)	7.8	8.2
	PCV (30-50%)	39.0	40.0
	MCV (40-65 Fl)	50.3	50.9
	MCH (12-19 Pg)	17.4	17.7
	MCHC (31-38 g/dl)	34.7	35.5
	RDW (18.3-22.3 %)	20.5	21.5
Complete Blood Count (CBC)	Total WBC count (06-12 × 10^3/cmm)	8.5	9.2
	Neutrophils (40-75%)	55.5	59.9
	Eosinophils (01-05%)	2	2.7
	Lymphocytes (20-45%)	41.4	35.7
	Monocytes (01-10%)	1.06	2.2
	Basophils (00-01%)	0	0
	RBC Morphology	Normocytic Normochromic	Normocytic Normochromic
	WBC Morphology	Normal	Normal
	Platelets (100000-400000/cmm)	162533.3	193933.3
	Parasites	Not detected	Not detected

reported that all the blood parameters were within the normal range. Likewise, Gul *et al.* (2007) studied the haematological values in apparently healthy horses kept under field conditions. The CBC values observed in the present study were also in agreement with the reference values established by Pritchard *et al.* (2009). The results of the present study suggest that rectal temperature, BCS and CBC are not reliable for differentiating between barren and healthy mares.

CONCLUSION

Based on the results of this study, it can be concluded that uterine health status is a major determinant of breeding success in mares. The absence of any difference in the systemic parameters between normal mares and mares with endometritis suggests that these parameters are not reliable indicators of endometritis or fertility in mares. Future studies involving larger sample sizes are required to further our understanding of the determinants of breeding success in the equine species.

ACKNOWLEDGEMENT

The authors are thankful to the Mumbai Veterinary College for providing the research facilities and financial assistance to conduct the study.

Conflict of interest statement

The authors declare that they have no conflict of interest.

REFERENCES

Allen, W.R. (2001). Luteal deficiency and embryo mortality in the mare. *Reproduction in Domestic Animals*. **36(34):** 121-131.

Barbary, H.A., Aboghonema, I.I., ElBawab, I.E. and Fadel, M.S. (2016). Diagnosis and treatment of bacterial endometritis in arabian mares. *Alexandria Journal for Veterinary Sciences*. **49(2):** 116-125.

Bracher, V., Mathias, S. and Allen, W.R. (1996). Influence of chronic degenerative endometritis (endometrosis) on placental development in the mare. *Equine Veterinary Journal*. **28(3):** 180-188.

Brinsko, S.P., Rigby, S.L., Varner, D.D. and Blanchard, T.L. (2003). A practical method for recognizing mares susceptible to post-breeding endometritis. *In AAEP Proc*. **49:** 363-365.

Card, C. (2005). Post-breeding inflammation and endometrial cytology in mares. *Theriogenology*. **64(3):** 580-588.

Derbala, M.K., Fadel, M.S., Asfour, H.A. and Gawad, E.M.A. (2018). Diagnosis of endometritis in infertile arabian mares using ultrasonography and bacteriological examination. *Assiut Veterinary Medical Journal*. **64(156):** 138-141.

Ferris, R.A., Bohn, A. and McCue, P.M. (2015). Equine endometrial cytology: Collection techniques and interpretation. *Equine Veterinary Education*. **27(6):** 316-322.

Fox, C., Morin, S., Jeong, J.W., Scott Jr, R.T. and Lessey, B.A. (2016). Local and systemic factors and implantation: What is the evidence?. *Fertility and Sterility*. **105(4):** 873-884.

Gavazza, A., Delgadillo, A.J., Gugliucci, B., Pasquini, A. and Lubas, G. (2002). Haematological alterations observed in equine routine complete blood counts. A retrospective investigation. *Comparative Clinical Pathology*. **11(3):** 131-139.

Gilbert, R.O. (2011). The effects of endometritis on the establishment of pregnancy in cattle. *Reproduction, Fertility and Development*. **24(1):** 252-257.

Gul, S.T., Ahmad, M., Khan, A. and Hussain, I. (2007). Haemato-biochemical observations in apparently healthy equine species. *Pakistan Veterinary Journal*. **27(4):** 155.

Hall, E.J., Carter, A.J., Stevenson, A.G. and Hall, C. (2019). Establishing a yard-specific normal rectal temperature reference range for horses. *Journal of Equine Veterinary Science*. **74:** 51-55.

Henneke, D.R., Potter, G.D., Kreider, J.L. and Yeates, B.F. (1983). Relationship between condition score, physical measurements and body fat percentage in mares. *Equine Veterinary Journal*. **15(4):** 371-372.

Hoopes, K., Thacker, E. and Greenhalgh, L. (2019). Body Condition Scoring for Horses. Utah State University Extension.

Ibrahim, M.M., Kandiel, M.M., Sosa, G.A. and Abouel, Roos, M.E. (2015). Ultrasonographic, cytological and bacteriological investigation of endometritis in Arabian mares. *Global Veterinaria*. **15(3):** 296-303.

Kouider, Z.E.A., Benallou, B. and Houari, H. (2017). Ultrasonographic and cytological diagnosis of endometritis in the mare. *Global Vet*. **19(4):** 586-589.

LeBlanc, M.M. (2010). Advances in the diagnosis and treatment of chronic infectious and post-mating induced endometritis in the mare. *Reproduction in Domestic Animals*. **45:** 21-27.

LeBlanc, M.M. and Causey, R.C. (2009). Clinical and subclinical endometritis in the mare: both threats to fertility. *Reproduction in Domestic Animals*. **44:** 10-22.

McCue, P.M. (2008). The problem mare: management philosophy, diagnostic procedures and therapeutic options. *Journal of Equine Veterinary Science*. **28(11):** 619-626.

Morley, S.A. and Murray, J.A. (2014). Effects of body condition score on the reproductive physiology of the broodmare: A review. *Journal of Equine Veterinary Science*. **34(7):** 842-853.

Munoz, L., Briones, M. and Saavedra, M.J. (2021). Relationship between the body condition index and the modified henneke body condition score in chilean horses. *Chilean Journal of Agricultural and Animal Sciences*. **37(1):** 74-80.

Pritchard, J.C., Burn, C.C., Barr, A.R. and Whay, H.R. (2009). Haematological and serum biochemical reference values for apparently healthy working horses in Pakistan. *Research in Veterinary Science*. **87(3):** 389-395.

Rua, M.A.S., Quirino, C.R., Ribeiro, R.B., Carvalho, E.C.Q., Bernadino, M.D.L.A., Junior, A.B. and Barreto, M.A.P. (2018). Diagnostic methods to detect uterus illnesses in mares. *Theriogenology*. **114:** 285-292.

Sikora, M., Krol, J., Nowak, M., Stefaniak, T., Aubertsson, G. and Kozdrowski, R. (2015). The usefulness of uterine lavage and acute phase protein levels as a diagnostic tool for subclinical endometritis in Icelandic mares. *Acta Veterinaria Scandinavica*. **58(1):** 1-10.