RESEARCH ARTICLE Indian Journal of Animal Research, Volume 59 Issue 9: 1605-1608 (September 2025)

Immunohistochemical Identification of Pancreatic Stellate Cells in Developing Pancreas of Guinea Pig (*Cavia porcellus*)

S. Rajathi[1], T.A. Kannan[2], R. Gnanadevi[3], P. Dharani[4], V. Ramakrishnan[1], S. Paramasivan[5], Geetha Ramesh[6]

10.18805/IJAR.B-4900

ABSTRACT

Background: Pancreatic stellate cell (PSC) is now known to play a critical role in pancreatic fibrosis in chronic pancreatitis and pancreatic cancer. In health, quiescent PSCs maintain normal tissue architecture.

Methods: The immunohistochemistry of the pancreas of guinea pig six animals each from 0-2 weeks, 2-8 weeks, 8-16 weeks and 16-32 weeks age groups irrespective of sex were conducted by procuring the animals from the Department of Laboratory Animal Medicine. Tissues were normally processed and embedded in paraffin and paraffin sections of three micron thickness were cut and immunohistochemistry staining protocol was followed with using primary antibody markers namely GFAP, alpha SMA and vimentin.

Result: In guinea pigs of 0-2 weeks of age, quiescent pancreatic stellate cells surrounding the acini showed mild positive vimentin immunoreaction. Mild alpha SMA immunopositive reaction was noticed in the quiescent pancreatic stellate cells of 2-8 weeks, 8-16 weeks and 16-32 weeks of age groups within the pancreatic acini. The star shaped quiescent pancreatic stellate cells in the pancreas were located in the interacinar spaces or periacinar spaces, with elongated cytoplasmic processes. Strong vimentin positive quiescent pancreatic stellate cells were found in the pancreatic acini of 2-8 weeks, 8-16 weeks and 16-32 weeks of age groups.

Key words: Guinea pig, Immunohistochemistry, Pancreas, Pancreatic stellate cells.

INTRODUCTION

Quiescent pancreatic stellate cells or vitamin A storing cells were first described in the pancreas of mice by Watari *et al.* (1982), using fluorescence and electron microscopy. Pancreatic stellate cell (PSC) is now known to play a critical role in pancreatic fibrosis in chronic pancreatitis and pancreatic cancer. In health, quiescent PSCs maintain normal tissue architecture via regulation of the synthesis and degradation of extracellular matrix (ECM) proteins and storage of vitamin A. Recent studies have also implied other functions for PSCs as progenitor cells, immune cells or intermediaries in exocrine pancreatic secretion in humans (Apte *et al.* 2012). During pancreatic injury, PSCs transform from their quiescent phase into an activated, myofibroblast-like phenotype that secretes excessive amounts of ECM proteins leading to the fibrosis of chronic pancreatitis and pancreatic cancer (Fig 1). It is now essential to differentiate quiescent state of pancreatic stellate cells from active state. PSCs play a crucial role in the behavior of pancreatic cancer. Its immunohistochemical expression with antibody markers showed varied heterogeneity between normal state and cancer state in humans (Fugiwara *et al.,* 2012). Ikejiri (1990) showed PSCs in normal pancreatic sections in rats and humans using light, florescence and electron microscopy. Active and quiescent pancreatic stellate cells identification with alpha SMA, desmin and platelet-derived growth factor receptor type beta were studied in rats (Haber *et al.,* 1999). Nielson *et al.* (2017) found that the cytoglobin and adipophilin were the markers of quiescent PSCs in normal human pancreas. Norberg *et al.* (2020) identified quiescent pancreatic stellate cells in normal human pancreas using vimentin and CD10 antibody markers. Since, there is paucity of literature in the identification of quiscent type of pancreatic stellate cells in developing guinea pig using immunohistochemistry, the present research work is carried out with the following objectives namely to identify and locate the pancreatic stellate cells in guinea pig.

[1]Department of Veterinary Anatomy, Veterinary College and Research Institute, Tirunelveli-627 358, Tamil Nadu, India.
[2]Education Cell, Madras Veterinary College, Chennai-600 007, Tamil Nadu, India.
[3]Department of Veterinary Anatomy, Veterinary College and Research Institute, Udumalpet-642 205, Tamil Nadu, India.
[4]Department of Veterinary Anatomy, Veterinary College and Research Institute, Namakkal-637 002, Tamil Nadu, India.
[5]Department of Veterinary Anatomy, Veterinary College and Research Institute, Orathanadu-614 625, Tamil Nadu, India.
[6]Department of Veterinary Anatomy, MadrasVeterinary College, Chennai-600 007, Tamil Nadu, India.

Corresponding Author: S. Rajathi[1], Department of Veterinary Anatomy, Veterinary College and Research Institute, Tirunelveli-627 358, Tamil Nadu, India. Email: rajathis9936@gmail.com

How to cite this article: Rajathi, S., Kannan, T.A., Gnanadevi, R., Dharani, P., Ramakrishnan, V., Paramasivan, S. and Ramesh, G. (2025). Immunohistochemical Identification of Pancreatic Stellate Cells in Developing Pancreas of Guinea Pig (*Cavia porcellus*). *Indian Journal of Animal Research*. **59(9):** 1605-1608. doi: 10.18805/IJAR.B-4900.

Submitted: 17-03-2022 **Accepted:** 23-06-2022 **Online:** 13-07-2022

MATERIALS AND METHODS

The present work was conducted at the Department of Veterinary Anatomy, Madras Veterinary College, Chennai from 2018 to 2021. The immunohistochemistry of the pancreas of guinea pig was conducted with six animals each from 0-2 weeks, 2-8 weeks, 8-16 weeks and 16-32 weeks age groups irrespective of sex by procuring the animals from the Department of Laboratory Animal Medicine, Madhavaram Milk Colony, TANUVAS, Chennai-51 as per the ethical committee approval of Tamilnadu Veterinary and Animal Sciences University (Lr. No. 1467/DFAB/IAEC/2018 dated 13.07.2018). After collection of the guinea pigs, they were euthanized as per the standard operating procedure by using the carbon dioxide asphyxiation as per CPCSEA (Committee for the purpose of control and supervision of experiments on animals) norms and they were subjected for the dissection. The pancreas from 0-2 weeks, 2-8 weeks, 8-16 weeks and 16-32 weeks of age was collected. They were washed in the normal saline and fixed in 10% neutral buffered formalin for immunohistological studies. Then the tissues were dehydrated in the ascending grades of the alcohol cleared in xylene and embedded in paraffin (58-60°C).

Immunohistochemistry staining protocol (Info@Pathn Situ)

1. Paraffin sections of three micron thickness were cut and mounted on charged slides and incubated at 60-70°C for 30 minutes.
2. Sections were deparaffinized with two changes in xylene.
3. Sections were dehydrated with absolute alcohol two changes and washed twice in distilled water.
4. Heat mediated antigen retrieval was done using TRIS-EDTA, buffer (pH 8.5 -9.0).
5. Sections were washed twice in distilled water for two minutes.
6. Blocking of endogenous peroxidase was done with three per cent hydrogen peroxide for ten minutes.
7. Sections were incubated in the following antibodies (Ready to use) primary antibody in a moist chamber for one hour.
   - GFAP.
   - Alpha SMA.
   - Vimentin.
8. Poly Excel HRP (Ready to use) secondary antibody was added and incubated for twelve minutes and sections were washed three times in PBS.
9. Diaminobenzidine (DAB) chromogen solution (1 ml DAB buffer+1 drop DAB chromogen) was added and kept for two to five minutes and washed in distilled water.
10. The sections were counterstained with Gill's haematoxylin for one minute. The sections were treated with running tap water for five minutes. Sections were dehydrated through graded series of alcohol and xylene and mounted in synthetic mountant.

RESULTS AND DISCUSSION

GFAP immunohistochemical reaction in the pancreas of 0-2 weeks, 2-8 weeks, 8-16 weeks and 16-32 week-old guinea pig did not show any positive reaction regarding the presence of quiescent pancreatic stellate cells in the parenchyma of pancreas. In contrast to this observation, Apte *et al.* (1998) in adult rat pancreas observed GFAP mild immunopositive reaction in quiescent pancreatic stellate cells with elongated cytoplasmic processes. This might be due to fact that the author used the isolated and cultured pancreatic tissue cells for the experiment.

In preweaning group of animals of 0-2 weeks of age, pancreatic stellate cells were not seen by alpha SMA antibody reaction. Similar observations were reported by

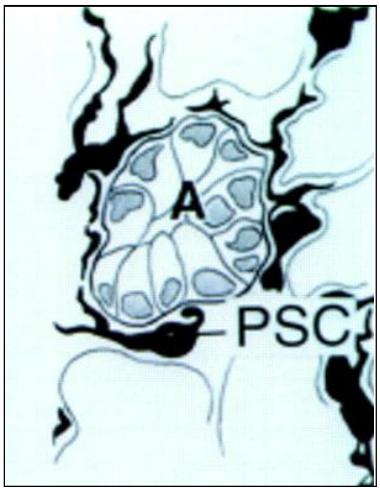

Fig 1: Picture showing the diagrammatic representation for the location of quiescent pancreatic Stellate cells-black colour (qPSC) around the Acini (A). Apte *et al.* (1998).

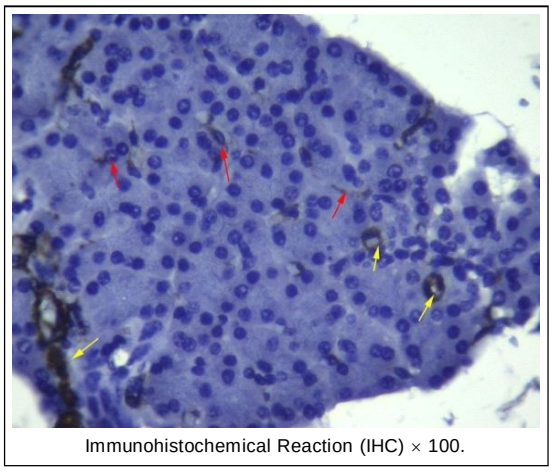

Immunohistochemical Reaction (IHC) × 100.

Fig 2: Photomicrograph of two week old guinea pig pancreas showing mild alpha SMA immunopositive reaction (red arrow) for the pancreatic stellate cells and (yellow arrow) for the smooth muscles cells.

Apte *et al*. (1998) in adult rat pancreas. In guinea pigs of 0-2 weeks of age, pancreatic stellate cells surrounding the acini showed mild positive vimentin immunoreaction. This shows that the pancreatic stellate cells were developing. The quiescent PSCs showed strong positive immunoreaction with vimentin antibody of adult rat (Bonner-weir and Orci, 1982), human and rodent pancreas (Xue *et al.,* 2018). This proves that the vimentin immunoreaction was mild in the pancreatic stellate cells in the weaning group and strong in the post-weaning groups of animals. The number os PSCs increased with age in rats (Bachem *et al.,* 1998).

Mild alpha SMA immunopositive reaction showed the presence of quiescent pancreatic stellate cells in the pancreatic acini of 2-8 weeks, 8-16 weeks and 16-32 weeks of age groups (Fig 2). Similar results were also found in rats as mild positive alpha SMA reaction on quiescent pancreatic stellate cells (Bachem *et al.,* 1998). Winter *et al.* (2021) also observed a mild positive alpha SMA reaction on pancreatic stellate cells in human healthy pancreas. But he also noticed that the pancreatic stellate cells of humans affected with pancreatic cancer and chronic pancreatitis showed strong alpha SMA immunopositive reation. This shows that alpha SMA can be used as an immunohistochemical marker for diagnosis of pancreatic cancer and chronic pancreatitis. In contrast to the present observation, Apte *et al.* (1998) in rat pancreas found that the quiescent pancreatic stellate cells were negative for alpha SMA reaction whereas, he found a positive reaction for active pancreatic stellate cells. This might be due to the reason that Apte *et al.* (1998) done immunostaining reaction with the isolated and the cultured cells of rat pancreatic tissue and not from the intact pancreatic tissue.

The pancreatic stellate cells were thin and elongated in appearance with star shaped and found at the periphery of the few acinar cells with eccentrically located small dark brown coloured nucleus (Fig 3) as found by Apte *et al.* (1998) in rats. The star shaped pancreatic stellate cells were located in the interacinar spaces or periacinar spaces, with elongated cytoplasmic processes encircled the base of adjacent acinar cells. Such cells were not observed in association with pancreatic islets as reported by Bachem *et al.* (1998) in rats and Apte *et al.* (2012) in human pancreas. The pancreatic stellate cells were scattered in arrangement, small in size and irregular shape with cytoplasmic processes that differentiated it from the smooth muscle cells. Smooth muscle cells found within the pancreatic parenchyma surround the duct system showed a strong immunopositive reaction with alpha SMA. Apte *et al.* (1998) in rat pancreas found that stellate cells contributed about 3.99 per cent of all pancreatic cells. In the present study, quantification of pancreatic stellate cells was not done.

Vimentin positive quiescent pancreatic stellate cells were found as a strong reaction in the pancreatic acini of 2-8 weeks, 8-16 weeks and 16-32 weeks of age groups (Fig 4). Pancreatic stellate cells were found in the periacniar, interlobular and interacinar spaces demonstrating strong

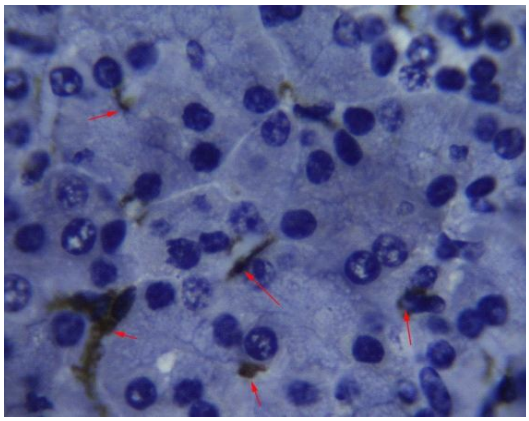

IHC × 400.

Fig 3: Photomicrograph of 28 week old guinea pig pancreas showing mild alpha SMA immunopositive reaction (red arrow) in the pancreatic stellate cells surrounding the acini.

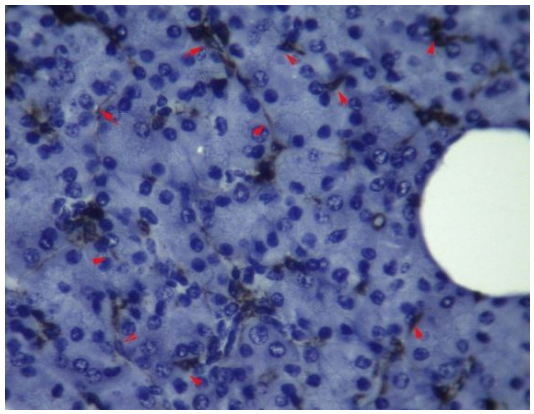

IHC × 100.

Fig 4: Photomicrograph of 12 week old guinea pig pancreas showing strong vimentin immunopositive reaction (red arrow) in the pancreatic stellate cells surrounding the acini.

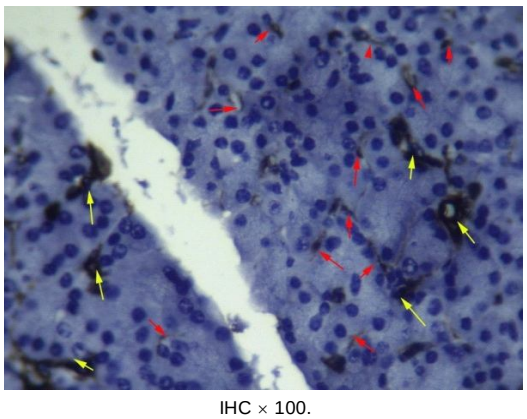

IHC × 100.

Fig 5: Photomicrograph of four week old guinea pig pancreas showing strong vimentin immunopositive reaction (red arrow) in the quiescent pancreatic stellate cells and (yellow arrow) in the connective tissue cells.

vimentin positivity which were of same architecture as that of alpha SMA reaction (Fig 5). Similar findings were also observed by Bonner-weir and Orci (1982) in adult rats and Xue *et al.* (2018) in human and rodents. Xue *et al.* (2018) in human and rodents pancreas found that the vimentin marker was used to demonstrate quiescent pancreatic stellate cells as strong reaction and the vimentin marker was shown only a mild reaction in the active pancreatic stellate cells as stated by Xue *et al.* (2018) in human and rodents pancreas which was also proved in the present study.

CONCLUSION

Quiescent pancreatic stellate cells were identified using vimentin antibody from neonatal to adult pancreas of guinea pig with a strong immunopositive reaction. Alpha SMA antibody showed only a mild positive reaction in the adult quiescent PSCs. GFAP antibody does not show any type of reaction with the quiescent PSCs of guinea pig. So it can be concluded that vimentin antibody can be used as an immunohistochemical marker for quiescent PSCs in guinea pigs of all postnatal age groups.

ACKNOWLEDGEMENT

The authors sincerely acknowledge Tamil Nadu Veterinary and Animal Sciences University for providing financial support for the preparation of the manuscript.

Conflict of interest

All authors declare that they have no conflict of interest.

REFERENCES

Apte, M.V., Haber, P.S., Applegate, T.L., Norton, I.D., McCaughan, G.W., Korsten, M.A., Pirola, R.C., Wilson, J.S. (1998). Periacinar stellate shaped cells in rat pancreas- identification, isolation and culture. *Gut*. **43:** 128-133.

Apte, M.V., Pirola, R.C., Wilson, J.S. (2012). Pancreatic stellate cells: a starring role in normal and diseased pancreas. *Frontiers in Physiology*. **3:** 1-14. doi: 10.3389/fphys. 2012. 00344.

Bachem, M.G., Schneider, E., Gross, H., Weidenbach, H., Schmid, R.M., Menke, A., Siech, M., Beger, H., Grunert, A., Adler, G. (1998). Identification, culture and characterization of pancreatic stellate cells in rats and humans. *Gastroenterology*. **115(2):** 421-32. doi: 10.1016/s0016-5085(98)70209-4.

Bonner-Weir, S. and Orci, L. (1982). New perspective on the microvasculature of the islets of Langerhans in the rat. *Diabetes*. **31:** 883-889. doi: 10.2337/diab.31.10.883.

Fujiwara, K., Ohuchida, K., Mizumoto, K., Shindo, K., Eguchi, D. (2012). CD271$^+$ Subpopulation of pancreatic stellate cells correlates with prognosis of pancreatic cancer and is regulated by interaction with cancer cells. *Plos One*. **7(12):** e52682. https://doi.org/10.1371/journal.pone.0052682.

Haber, P.S., Keogh, G.W., Apte, M.V., Moran, C.S., Stewart, N.L., Crawford, D.H., Pirola, R.C., McCaughan, G.W., Ramm, G.A., Wilson, J.S. (1999). Activation of pancreatic stellate cells in human and experimental pancreatic fibrosis. *American Journal of Pathology*. **155(4):** 1087-95. doi: 10. 1016/S0002-9440(10)65211-X.

Ikejiri, N. (1990). The vitamin A-storing cells in the human and rat pancreas. *Kurume Medical Journal*. **37:** 67-81. doi: 10.2739/ kurumemedj.37.67.Info@pathnsitu.com/immunohistochemistrystainingprotocol.

Nielsen, M.F.B., Mortensen, M.B., Detlefsen, S., (2017). Identification of markers for quiescent pancreatic stellate cells in the normal human pancreas. *Histochemistry and Cell Biology*. **148(4):** 359-380. https://doi.org/10.1007/s00418-017-1581-5.

Norberg, K.J., Liu, X., Fernndez-Moro, C. (2020). A novel pancreatic tumour and stellate cell 3D co-culture spheroid model. *BMC Cancer*. **20(1):** 475. doi: https://doi.org/10.1186/s128 85-020-06867-5.

Watari, N., Hotta, Y., Mabuchi, Y. (1982). Morphological studies on a vitamin A-storing cell and its complex with macrophage observed in mouse pancreatic tissues following excess vitamin A administration. *Okajimas Folia Anatomy of Japan*. **58:** 837-858. doi: 10.2535/ofaj1936.58.4-6_837.

Winter, K., Dzieniecka, M., Strzelczyk, J., Wągrowska-Danilewicz, M., Danilewicz, M., Malecka-Wojciesko., E. (2021). Alpha smooth muscle actin (αSMA) immunohistochemistry use in the differentiation of pancreatic cancer from chronic pancreatitis. *Journal of Clinical Medicine*. **10(24):** 5804. doi: 10.3390/jcm10245804.

Xue, R., Jia, K., Wang, J. (2018). A rising star in pancreatic diseases: Pancreatic stellate cells. *Frontiers in Physiology*. **9:** 754. doi: 10.3389/fphys.2018.00754.