CASE STUDY Indian Journal of Animal Research, Volume 59 Issue 11: 1948-1952 (November 2025)

A Ten Year Retrospective Study on Cor Triatriatum Sinister Associated Heart Failure in Dogs

K. Satish Kumar[1], P. Nagaraj[2], G. Ambica[1], J. Jyothi[2]

10.18805/IJAR.B-4925

ABSTRACT

Background: Although cor triatriatum sinister (CTs) represents a well-known and widely described cardiac malformation in humans, its description in the canine population is rare. The aim of this ten-year study is to place on record about the most unusual congenital cardiac malformation, cortriatriatum sinister that was sporadically reported among veterinary patients.

Methods: The dogs were examined clinically, physically and later subjected for chest radiograph and echocardiography to confirm CTs. All were showing regular femoral pulse that was strong and synchronous to the heart beat, pale mucosa, mean systolic arterial blood pressure of 145 mm Hg and with normal hemato-biochemical parameters. Cardiomegaly with increased sternal contact, elevated trachea, pulmonary congestion and engorged caudal vena cava were radiographic findings. 2d-echocardiography revealed a left atrium that was subdivided by a transverse membrane into two distinct compartments, one proximal and one distal, thus confirming the cortriatriatum sinister.

Result: Cor triatriatum sinister (CTs) was diagnosed in 4 dogs with a prevalence of 4.59% amongst those suffering from congenital heart anomalies, that were aged between 5y-7y and the breeds include Boxer, Doberman and Cocker spaniel. All these dogs were presented with similar signs suggestive of heart failure *viz*., exercise intolerance, dyspnoea at rest, cough that was dry nocturnal type, generalised weakness and syncope. All of these patients were successfully managed with frusemide, benazapril and pimobendan. Hence, it may be concluded that the CTS, a rare congenital cardiac anomaly in dogs should also be included in the differential diagnosis of heart failure, particularly if presented at early life, which also helps to prevent further breeding from such stock.

Key words: Cortriatriatum sinister, Diagnosis, Dog, Managemen.

INTRODUCTION

Cor triatriatum sinister and dexter occur from a fibrous membrane dividing the left or right atrium, respectively, resulting in a “heart with three atria”. Cor triatriatum sinister (CTs) is a rare defectin dogs and cats, that arises when the common pulmonary vein fails to regress normally, resulting in a fibrous membrane that persists within the left atrium, dividing the left atrium into two subchambers (Oliveira *et al.,* 2011; Menaut *et al*., 2009). In CTs, the left auricle has two distinct compartments, the proximal one that receives blood from pulmonary vein and the distal compartment communicates with the left ventricle through mitral valve. One or more small orifices that are present on the intra atrial separating membrane allows communication between these two compartments (Cote *et al.,* 2011). CTs is documented to be a result of lack of normal regression of the fetal pulmonary veins to form the roof of the left atrium (Lima *et al.,* 2010). One or more small orifices present in the intra-atrial separating membrane allows the communication between both the compartments of the left atrium (Oliveira *et al.,* 2011). The proximal, high-pressure subchamber receives pulmonary venous return, while the distal, low-pressure subchamber is adjacent to the mitral valve and contains the left auricular appendage. The malformation and its hemodynamic consequences can be diagnosed with the help of 2d-echocardiography (Castagna *et al.,* 2019). Inspite of palliative medical management, complete surgical excision of the membrane is the definitive treatment protocol that is commonly recommended in all symptomatic human patients (Bruce, 2015). The aim of this study was to place on record about this most unusual condition (resulted in heart failure) that was sporadically reported among veterinary patients.

[1]Department of Veterinary Medicine, College of Veterinary Science, Rajendranagar, P.V. Narasimha Rao Telangana Veterinary University, Hyderabad-500 030, Telangana, India.
[2]Department of Veterinary Clinical complex, CVSc, Rajendranagar, Hyderabad-500 030, Telangana, India.

Corresponding Author: K. Satish Kumar, Department of Veterinary Medicine, College of Veterinary Science, Rajendranagar, P.V. Narasimha Rao Telangana Veterinary University, Hyderabad-500 030, Telangana, India. Email: drsatish.ksk@gmail.com

How to cite this article: Kumar, K.S., Nagaraj, P., Ambica, G. and Jyothi, J. (2025). A Ten Year Retrospective Study on Cor Triatriatum Sinister Associated Heart Failure in Dogs. *Indian Journal of Animal Research*. **59(11):** 1948-1952. doi: 10.18805/IJAR.B-4925.

Submitted: 04-05-2022 **Accepted:** 05-08-2022 **Online:** 16-08-2022

MATERIALS AND METHODS

The present investigation was carried out among the dogs that were suspected for cardiac ailment and presented to cardiology ward of Veterinary Clinical Complex, CVSc Rajendranagar and those referred from various private

clinics, for a period of 10 years (2012 to 2022). Almost all these dogs were showing the signs of heart failure of varied intensity and were subjected to a detailed clinical examination such as, recording temperature, pulse and respiration followed by physical examination. Chest auscultation was carried out in a sound proof environment, on specific points at left and right cardiac region. Thoracic plain radiograph was taken on both the right lateral and ventro dorsal views. Further, 2d-echocardiographyand colour doppler studies were performed on *Mindray Z5Vet* Ultrasound machine, using 6C micro convex probe to diagnose various cardiac diseases and specifically to confirm cortriatriatum sinister (CTs) in these dogs. Both short and long axis of cardiac chambers was evaluated to detect the cardiac anomaly on B-mode and dimension of the left ventricle was evaluated on M-mode echocardiography. Later Doppler evaluation of CTs dogs was also carried out to study the abnormal blood flow. These dogs were medically managed with angiotensin converting enzyme inhibitors (ACEi), diuretics and positive ionotropic drugs.

2dimensional echocardiography was performed in right lateral recumbancy as right parasternal transthoracic echocardiograms in non-sedated dogs suspected for CTs. Access to the right side of the thorax was facilitated by using a table with a special cut-open to allow the transducer to be directed upward towards the site of maximal cardiac pulsation (Allworth *et al.,* 1995). Transducer is located parasternally between right third and sixth intercostal spaces between sternum and costochondral junction (Thomas *et al.,* 1994). M-mode recordings were taken at the high papillary level and themeasurement of left ventricular dimension at end-diastole (LVEdD) and end-systole (LVEsD) was made intraluminally from the trailing edge of the septal wall image to the leading edge of the ventricular free wall. End-diastolic and end-systolic measurements of the thickness of the Inter Ventricular Septum (IVSd, IVSs) and left Ventricular Posterior Wall (LVPWd, LVPWs) were made using trailing edge (AllWorth *et al.* 1995). Further, colour flow Doppler was also done to assess the directional flow as per the technique suggested by Dominique and Marc-Andre (2008).

RESULTS AND DISCUSSION

Occurrence of CTs

During the present investigation, a total of 795 dogs were diagnosed for various acquired (89%) and congenital cardiac diseases (11%), accounting for 708 and 87 cases, respectively. Out of the total congenital diseases (87), cortriatriatum sinister (CTs) was diagnosed in 4dogs (4.59%), aged between 5-7 years amongst Boxers (2), Doberman (1) and Cocker spaniel (1) breeds. Congenital anomalies of the cardiovascular system are defects present at birth and often lead to perinatal death in dogs. However, in some cases, congenital heart diseases (CHDs) are asymptomatic and undetected until later in life, so the percentage of dogs with congenital heart diseases that survive to adulthood to breed can be rather high (Garncarz *et al.,* 2017 and Caivano *et al.,* 2018). Bulldog and Boxers are reportedly common affected breeds (Gustavo *et al*., 2012). The difference in the prevalence of CHDs depends on the popularity of the breed in a country in a given period of time (Ghirlanda *et al.,* 2014). Knowing the epidemiology of CHDs plays an important role in maintaining dog health and in preventing the diffusion of CHDs in the dog population (Garncarz *et al.,* 2017). Cor triatriatum is among the rarest developmental anomalies of cardiovascular system reported in humans (Hamdan *et al.,* 2010) followed by dogs and cats (Cote, 2011). Cor triatriatum can be either, sinister or dexter that result from a fibrous membrane dividing the left or right atrium, respectively. Cor triatriatum dexter (CTd) is thought to account for only 0.1% of human congenital heart disease and only 0.3% of canine congenital heart disease (Bruce, 2015). While CTd has been well described in the dog, historically, CTs was first described in human beings (Church, 1868) and later after more than a century in the veterinary patients. The first ever case was reported in a cat (Gordon *et al.,* 1982). Among dogs, cortriatriatum dexter has been reported earlier (Tobias *et al.*,1993; Kittleson, 1998; Mitten *et al.,* 2001; Oliveira *et al.,* 2011) and CTs quite recently (Gustavo *et al.,* 2012).

Clinical presentation of CTs

All the dogs diagnosed for CTs were presented with similar history and signs suggestive of heart failure *viz*., exercise intolerance, dyspnoea at rest, cough- particularly dry nocturnal type that was ignited by physical activity and deep sleep, generalised weakness. Syncope was additionally reported in the Cocker spaniel. Physical examination revealed,a considerably elevated heart rate and a femoral pulse that was regular, strong and synchronous to the heart beats. Auscultation revealed a soft systolic murmur on left heart base (75%), tricuspid area (50%) and pulmonic valve area (25%), withmoderately distended jugular vein (50%) and jugular pulse (50%). The details are given in Table 1. Rectal temperature was within the normal range among all the affected cases, slightly pale conjunctival mucous membrane. The averagesystolic arterial blood pressure that was recorded among these dogs, using Doppler blood pressure (BP) machine was 145 mm Hg. Mild neutrophilia, normal BUN and serum creatinine values were observed. Radiographic abnormalities noticed on right lateral thoracic radiograph included cardiomegaly, increased sternal contact, elevated trachea, pulmonary congestion and engorged caudal vena cava (Fig 1). Though cortriatriatum sinister is a well-documented cardiac malformation among humans, published reports amongst canines are rare (Castsgna *et al* 2019). CTs affected dogs and cats are presented with the signs of left heart failure, with pulmonary edema, pleural effusion, or both (David, 2016). The pathophysiology and complications of CTs are variable and depends whether it is an isolated defect or associated with other cardiovascular anomalies, including the size of the membrane's orifice (Kelmendi *et al.* 2009). If the

Table 1: Various clinical manifestations recorder in Cortriatriatum sinister dogs (n=4).

Clinical parameter	Cortriatriatum sinister dogs			
	Boxer, M, 6y	Boxer, M, 7y	Doberman, M,5y	Cocker spaniel, F, 6y
Temperature (°F)	101	100	101	102
Pulse	Regular and easily palpabl	Regular and easily palpable	Regular and easily palpable	Palpable with regular pulse deficit
Respiration	Exaggerated	Exaggerated	Exaggerated	Exaggerated
Mucosa	Pale	Pale	Pale	Pale to Cyanotic
CRT (sec)	3	4	4	4
Exercise intolerance	Moderate	Moderate	Moderate	Severe
Distended jugular vein	No	Yes	No	Yes
Jugular pulse	Absent	Present	Absent	Present
Dyspnoea at rest	Moderate	Moderate	Moderate	Severe
Cough	Mild	Severe nocturnal	Moderate nocturnal	Severe nocturnal
Insomnolence	Absent	Present	Absent	Present
General weakness	Absent	Present	Present	Present
Syncope	Absent	Absent	Absent	Present
Auscultation	Grade I murmur	Soft systolic murmur at heart base, at tricuspid area	Soft systolic murmur at heart base, at pulmonic area	Soft systolic murmur at heart base, at tricuspid area

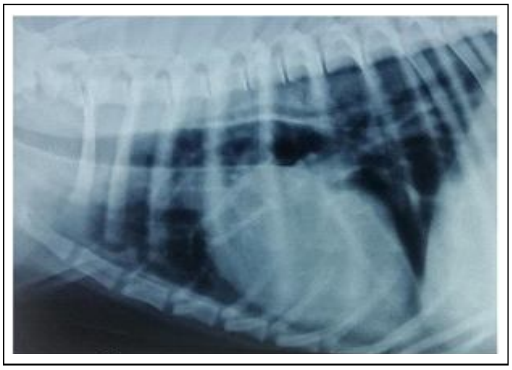

Fig 1: Right lateral X-ray showing increased sternal contact with pulmonary congestion.

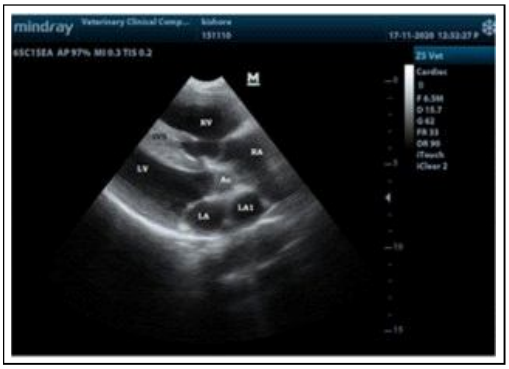

Fig 2: B-mode long axis view of CTS dog showing two compartments of left atrium (LA and LA1), in systole. Also note thick interventricular septum (IVS).

anomalies remain associated with other cardiovascular defects or if the foramen is too large, the prognosis might be serious (Nassar and Hamdan, 2011; Lima *et al.,* 2010; Sandra, 2020).

Echocardiographic features of CTs

Right parasternal 2d-echocardiography revealed a left atrium that was subdivided by a transverse membrane into two distinct compartments, one proximal and one distal, thus confirming the cortriatriatum sinister (Fig 2). Dilatation of right atrium, right ventricle and thickened right interventricular septum with normal interatrial septum were also noticed (Fig 3 and 4). The mitral valve did not reveal any abnormality, but billowing of the tricuspid valve was noticed (Fig 5). Pulse wave Doppler at mitral area showed laminar flow and regurgitant flow with turbulence jet was seen at the tricuspid valve area (Fig 6 and 7). Mild pulmonary valve regurgitation was also noticed on the right parasternal 4-chamber short-axis view. The presence of obstructive membrane in the left atrium leads to increased pulmonary venous capillary pressure resulting in pulmonary edema, congestion and pulmonary hypertension (Gordon *et al.,* 1982; Oliveira *et al.,* 2011). 2d-echocardiography is the most promising procedure to confirm the anomaly (Thakrar *et al.* 2007; Nassar and Hamdan, 2011; Menaut *et al.,* 2009). As the disease progress, subsequently there will be enlargement of left proximal atrial chamber and main pulmonary artery, thereby resulting in dilatation of right atrium and right ventricle resulting in eccentric hypertrophy (Cote *et al*., 2011).

Management of HF associated with CTs

Following treatment with diuretic (frusemide), ACE inhibitor (benazepril) andinotropic agent (pimobendon), all the CTs dogs showed improvement in overall physical activity from day 10. There was alleviation in dyspnoeathat improved to near normal breathing pattern, absence of cough, improvement in physical activity, energy levels with exercise



Fig 3: B-mode long axis view of CTS dog showing two compartments of left atrium in systole: note the opening of mitral valves at the distal compartment (LA), dilated right atrium (RA) and thick IVS.



Fig 4: B-mode short axis view of CTS dog showing two compartments separated by septum (S). Also note dilated right ventricle (RV).



Fig 5: B-mode long axis view of CTS dog, showing billowing of tricuspid valve (Arrow).

tolerance levels and normal appetite by day 20, following therapy. Like any other heart failure, CTs dog can also be managed with beneficial effects using diuretics and angiotensin converting enzyme inhibitors (Gordon *et al.,* 1982; Macdonald, 2006; Gustavo *et al.,* 2012). Diuretics is the primary drug in the management of heart failure, as it reduces preload and relieves congestion secondarily to cardiac dysfunction. However, diuretics should never be used as single therapy as they activate Rennin Angiotensin



Fig 6: Pulse wave Doppler tracing at mitral valve area showing clear envelop form.



Fig 7: Pulse wave Doppler tracing at tricuspid valve area showing turbulence jet form.

Aldosterone System (RAAS), therefore they should be used in conjunction with ACE inhibitors (Sandra, 2020). BENCH Study Group (1999) reported the effect of a long acting ACEi and benazepril on the survival times and clinical signs of dogs with heart failure and documented that the drug counteracts the adverse effects caused by ACE activity in heart failure. In the present study, the combination therapy significantly improved the clinical signs such as, breathing, physical activity and exercise strength and duration subsequently resulting in prolonged survival time.

CONCLUSION

From the available reports and present study, it may be concluded that the rare congenital cardiac anomaly,CTs should also be included in the differential diagnosis of heart failure particularly if presented at early life. Early detection not only helps to increase survival time of the affected dog, but also prevents unnecessary breeding.

ACKNOWLEDGEMENT

The authors are thankful for the administration, PVNR TVU, Hyderabad in providing the facilities for completing the work.

Conflict of interest

The authors have declared no conflict of interest.

REFERENCES

Allworth, S.M., Church, D.B., Maddison, J.E., Einstein, R. and Brennar, P. (1995). Effect of enalapril in dogs with pacing induced heart failure. *American Journal of Veterinary Research*. **56:** 86-94.

BENCH (BENazepril in Canine Heart disease) Study Group, Pouchelon, J.L., King, J., Martignoni, L., Chetboul, V., Lugardon, B., Rousselot, J.F., Corlouer, J.P., *et al*. (1999). The effect of benazepril on survival times and clinical signs of dogs with congestive heart failure: Results of a multicenter, prospective, randomized, double-blinded, placebo-controlled, long-term clinical trial. *Journal of Veterinary Cardiology*. **1(1):** 7-18.

Bruce, W.K. (2015). Cor Triatriatum. Veterinary Image guided Interventions. Editors: Chick Weisse and Allyson Bernt. pp. 127-139.

Caivano, D., Dickson, D., Martin, M. and Rishniw, M. (2018). Murmur intensity in adult dogs with pulmonic and subaortic stenosis reflects disease severity. *Journal of Small Animal Practice*. **59:** 161-166.

Castagna, P., Romito, G. and Toaldo, M.B. (2019). Cor triatriatum sinister in a dog. *Journal of Veterinary Cardiology*. **25:** 25-31.

Church, W.S. (1868). Congenital malformation of the heart: Abnormal septum in the left auricle. *Transactions of Pathological Society of London*. **19:** 188-190.

Cote, E., Macdonald, K.A., Meurs, K.M. and Sleeper, M.M. (2011). Congenital Malformations, in Feline Cardiology, Wiley-Blackwell, West Sussex, UK, 1st edition. pp. 85-100.

David, S. (2016). Heart murmurs in puppies and kittens. *Companion Animal.* **21(7):** 376-383.

Dominique, P. and Marc-Andre d' A. (2008). Atlas of Small Animal Ultrasonography, I edn., Blackwell Publishing, Australia.

Garncarz, M., Parzeniecka-Jaworska, M. and Szalus-Jordanow, O. (2017). Congenital heart defects in dogs: A retrospective study of 301 dogs. *Medicine Weter*. **73:** 651-567.

Ghirlanda, S., Acerbi, A. and Herzog, H. (2014). Dog movie stars and dog breed popularity: A case study in media influence on choice. *Pub Lib Sci (PLOS) One*. **9:** 1-5.

Gordon, B., Trautveter, E. and Patterson, D.F. (1982). Pulmonary congestion associated with cortriatriatum in a cat. *Journal of American Veterinary Medical Association*. **180(1):** 75-77.

Gustavo, L.G.A., Marcelo, B.A., Carolina, M.S., Angela, V.M., Ludmila, S.C.O. (2012). Cor Triatriatum Sinister in a French Bulldog. *Veterinary Medicine*. doi: 10.1155/2012/413020.

Hamdan, R., Mirochnik, N., Celermajer, D., Nassar, P. and Iserin, L. (2010). Cor triatriatum sinister diagnosed in adult life with three dimensional transesophageal echocardiography. *BMC Cardiac Diseases*. **12:** 54-60.

Kelmendi, M., Bejiqi, R., Bajraktari, G. and Beqiraj, R.(2009). Cor triatriatum sinister-three case reports. *Medical Arhiv*. **63(5):** 300-302.

Kittleson, M.D. (1998). Other Congenital Cardiovascular Abnormalities, in Small Animal Cardiovascular Medicine, [Kittleson, M.D. and Kienle, R.D., (Eds)]., Mosby, St. Louis, Mo, USA, 1st edition. pp. 282-296.

Lima, R.P., Fonseca, C., Sampaio, F., Ribeiro, J. and Ribeiro, V.G. (2010). Cor triatriatum sinistrum-description and review of four cases. *Revista Portuguesa de Cardiologia*. **29(5):** 827-836.

Macdonald, K.A.(2006). Congenital heart diseases of puppies and kittens. *Veterinary Clinics North America*. **36(3):** 503-531.

Menaut, P., Fuentes, V.L. and Dennis, S. (2009). Cor Triatriatum Sinister in cats: 5 cases. in 15th FECAVA Eurocongress, AFVAC-SAVAB-LAK, Lille, France, November. pp. 27-29.

Mitten, R.W., Edwards, G.A. and Rishniw, M. (2001). Diagnosis and management of cortriatriatum dexter in a Pyrenean Mountain dog and an Akita Inu. *Australian Veterinary Journal.* **79(3):** 177-180.

Nassar, P.N. and Hamdan, R.H. (2011). Cor triatriatum sinistrum: Classification and imaging modalities. *Europian Journal of Cardiac Medicine*. **1(3):** 84-87.

Oliveira, P., Domenech, O., Silva, J., Vannini, S., Bussadori, R. and Bussadori, C. (2011). Retrospective review of congenital heart disease in 976 dogs. *Journal of Veterinary Internal Medicine*. **25(3):** 477-483.

Sandra, P.T. (2020). Miscellaneous Congenital Cardiac Abnormalities in Animals. https://www.msdvetmanual.com.

Thakrar, A., Shapiro, M.D., Jassal, D.S., Neilan, T.G. and King, M.E.E. (2007). Cor triatriatum: the utility of cardiovascular imaging. *Canadian Journalof Cardiology*. **23(2):** 143-145.

Thomas, P.W., Gaber, C.E., Jacobs, G.J., Kaplan, P.M. and Lombard, C.W. (1994). Recommendations for standards in transthoracic two-dimensional echocardiography in the dog and cat. *Veterinary Radiology and Ultrasound*. **35:** 173-178.

Tobias, A.H., Thomas, W.P., Kittleson, M.D. and Komtebedde, J. (1993). Cor triatriatum dexter in two dogs. *Journal of American Veterinary Medical Association*. **202(2):** 285-290.