RESEARCH ARTICLE Indian Journal of Animal Research, Volume 58 Issue 10: 1786-1792 (October 2024)

Molecular Detection and Seroprevalence of Lumpy Skin Disease in Cattle

S.D. Gayal[1], M.P. Sakhare[1], Pankaj Suman[1], T.A. Shafi[1], M.F.M.F. Siddiqui[1], P.V. Yeotikar[1]

10.18805/IJAR.B-4933

ABSTRACT

Background: To investigate seroprevalence, clinical manifestations, molecular diagnosis of Lumpy Skin Disease in cattle in an around Parbhani during outbreak of LSD.

Methods: The cattle irrespective of their age, breed and gender were screened for detection of LSDV. Duration of study period was from December, 2020 to August, 2021. The cattle showed high fever, presence of nodules on body, nasal discharge, ocular discharge, brisket oedema and lameness were screened for lumpy skin disease and were further confirmed using molecular tests. Total 478 cattle were screened for the seroprevalence of lumpy skin disease by ELISA and PCR tests. The cattle were categorized into different age groups as calves (less than 0-2 years), young (between 2-4 years) and adults (4 years and above). The various breeds such as Khillar, Red Kandhari, Gir, Holstein-Friesen, cross-bred and non-descript cattle were screened. The seroprevalence of Lumpy Skin Disease in female and male was also recorded.

Result: The molecular assay of LSD revealed that, out of 478 cattle screened, 267 (55.85%) serum samples were found positive by ELISA test. Whereas, among 267 blood samples and 8 scab samples tested by PCR, 82 blood samples (30.7%) and 5 scab samples (62.5%) were found positive for LSDV in cattle. LSD is an emerging, transboundary and economically important viral disease of cattle. The overall seroprevalence of LSD in cattle was 55.85%. Prominent clinical manifestations in LSD affected cattle was Prominent clinical manifestations in LSD affected cattle were fever followed by generalized appearance of skin nodules on body. In addition, LSD affected cattle showed oculo-nasal discharge, enlarged lymph nodes, brisket oedema, lameness, corneal opacity and anorexia. The scab samples were more reliable material for LSDV confirmation by PCR.

Key words: *Capripoxvirus*, ELISA, Lumpy skin disease, PCR, Seroprevalence.

INTRODUCTION

Livestock production constitutes one of the principal means of achieving improved living standards in many regions of the World (Gumbe *et al.,* 2018).

India, one of the twelve mega biodiversity countries in the world, is home to large diversified cattle genetic resources, having 190.9 million cattle population and so far 43 native cattle breeds. Lumpy skin disease (LSD) is caused by lumpy skin disease virus (LSDV) which is antigenically related to sheep and goat poxvirus. LSDV is a member of the genus *Capripoxvirus* within the subfamily *Chordopoxvirinae*, family *Poxviridae*. The prototype strain is known as the Neethling *poxvirus* (OIE, 2018 and Coetzer *et al.,* 2018).

Sheep pox and Goat pox caused by *Capripoxvirus* in sheep and goats respectively are endemic in India, despite the sporadic use of indigenously developed live attenuated homologous sheeppox and goatpox vaccine, LSD an economically important transboundary disease in cattle was considered exotic. LSD is an emerging disease found first time in India having economic importance.

LSD is one of the most economically significant viral disease of cattle which is characterized by high fever, enlarged lymph nodes, firm and circumscribed nodules (OIE, 2018). It has been recently reported from China and Bangladesh sharing borders with India. In August 2019, LSD was reported for the first time in Odisha State of India with 7.1% morbidity among cattle (Sudhakar *et al.,* 2020).

LSDV usually causes 10-20% morbidity and 1-5% mortality among the livestock (OIE, 2017) but other studies have reported 100% morbidity in cattle (Gupta *et al.,* 2020). Usually, mortality rate is variable (50% in young animals and 5% in adults) depending on the viral strain, its virulence and susceptibility of host; (Roche *et al.,* 2020).

Lumpy skin disease is economically important because of its prolonged debilitating effects in severely afflicted

[1]Department of Epidemiology and Preventive Medicine, College of Veterinary and Animal Sciences, Maharashtra Animal and Fishery Sciences University, Parbhani-431 402, Maharashtra, India.

Corresponding Author: S.D. Gayal, Department of Epidemiology and Preventive Medicine, College of Veterinary and Animal Sciences, Maharashtra Animal and Fishery Sciences University, Parbhani-431 402, Maharashtra, India.
Email: sachin.gayal007@gmail.com

How to cite this article: Gayal, S.D., Sakhare, M.P., Suman, P., Shafi, T.A., Siddiqui, M.F.M.F. and Yeotikar, P.V. (2024). Molecular Detection and Seroprevalence of Lumpy Skin Disease in Cattle. Indian Journal of Animal Research. 58(10): 1786-1792. doi: 10.18805/IJAR.B-4933.

Submitted: 14-05-2022 **Accepted:** 17-11-2022 **Online:** 09-12-2022

animals including reduced weight gain, temporary or permanent cessation of milk production, sometimes accompanied by mastitis, temporary or permanent infertility or even sterility in bulls as a consequence of orchitis, as well as permanent skin damage. Abortion following infection has also been reported in approximately 10% of pregnant cows (Coetzer *et al.,* 2018).

Infected cattle excrete the virus in saliva, lacrimal secretions and nasal discharges, which may contaminate common feeding or watering sites (Weiss, 1968). LSDV persists in semen of infected bulls, hence natural mating or artificial insemination, may be a source of infection for cows and heifers (Annandale *et al.,* 2014). At field condition, infected pregnant cows are known to give birth to calves with skin lesions (Rouby and Aboulsoud, 2016). Inspite of strict quarantine measures LSD can occur through insect vectors (Chihota *et al.,* 2001).

MATERIALS AND METHODS

Selection of cattle

The cattle population irrespective of their age, breed and gender were screened for detection of LSDV during the period from December, 2020 to August, 2021. The cattle exhibited high fever, presence of nodules on body, nasal discharge, ocular discharge, brisket oedema and lameness were screened for Lumpy Skin Disease and were further confirmed using molecular tests. In the present study, total 478 cattle were screened for the investigation of LSD seroprevalence. The cattle were divided into different age groups as calves (>0-2 years), young (>2-4 years) and adults (>4 years) as per (Abera *et al.,* 2015). The different cattle breeds such as Khillar, Red Kandhari, Gir, Holstein Friesen, cross bred and non-descript were screened. The seroprevalence of lumpy skin disease in female and male was also recorded.

Isolation of DNA from whole blood sample

The whole blood sample was collected from jugular vein from LSD suspected cattle were further LSDV confirmed with molecular tests.

Total DNA was extracted from whole blood sample using blood DNA isolation kit (Nucleospin Blood DNA Isolation kit) following manufacturer's instructions.

Isolation of DNA from scab sample

The scab samples from cattle affected with LSD was collected with sterile scissors/scalpel and placed in sterile container and stored at -20°C until processing. Then scab sample was added to autoclaved mortar and pestle and minced with sterile PBS and filter through 0.22 µm filter paper. Filtrate obtained had LSDV. The concentration of DNA was measured using nanodrop (1.7 ng/µl).

Polymerase chain reaction

A 910 nt fragment of the G-protein-coupled chemokine receptor (GPCR) gene (6981 7891 of the Genbank accession number: AF325528.1) of the LSDV reference strain (Neethling strain provided by the Pirbright Institute to the Friedrich-Loeffler-Institute, Greifswald-InselRiems, Germany) was amplified using the in-house designed (FP) 5′-CATAGTCGATATCCCACATTG-3′ and (RP): 5′- GCTAATA CTACCAGCACTAC-3′ and the Taq DNA Polymerase.

The additional primer was designed for enhanced specificity and sensitivity of detection. All PCR products was resolved on 1.5% agarose gel against 100 bp DNA ladder at 125 V in 1X Tris-Acetic acid-EDTA (TAE) buffer containing 0.5 µg/ml ethidium bromide for 35 min. The gel was visualized using the gel documentation system.

Indirect enzyme-linked immunosorbent assay

A checkerboard titration was performed to determine the optimal dilution of the coating antigen, serum and horseradish peroxidise labelled goat-anti cow IgG (HRP-IgG) (Abcam) using a 96- well ELISA plate. Commercially available live goat pox vaccine (Uttarkashi strain) serially diluted 1:10, 1:100, 1:500 in carbonate-bicarbonate buffer (pH 9.6) and 100 µL was used to coat each well, which was incubated overnight at 4°C to immobilize antigen into the well. Plate was washed once (for 5 minutes) using PBS to remove excess antigen that is unbound on to well and 1% BSA diluted in PBS containing 0.05% (v/v) Tween-20 (Sigma) (PBST) *i.e* Blocking Buffer (BB) was added into the plate to block non-specific binding sites, with 100 µL each well and incubated for 1 hr at 37°C in incubator. Plate was washed one time (for 5 minutes) using PBS and 1:10, 1:100, 1:500 dilutions of primary antibody *i.e*., serum diluted in Blocking Buffer (BB) were added to each well and incubated for 1 hr at 37°C in an incubator. Plate was washed three times (for 5 minutes) using PBST to remove excess primary antibody with 200 µL in each well. The secondary antibody which is HRP linked, diluted 1:5000 in 1% BSA+PBST and 100 µL was added to each well and incubation was carried out at 37°C in an incubator.

The plate was washed five times with PBST, 100 µL of substrate o-phenylenediamine dihydrochloride (OPD) reagent per well was added and wait 15-30 minutes for developing colour. The reaction was stopped using sulfuric acid, the plate was read at 450 nm absorbance using a ELISA plate reader. Positive negative control serum and test samples were run in duplicate. Optical density (OD) values were determined to check antibody titer.

Statistical analysis

The collected data was statistically analyzed using online software www.icargoa.res.in following the methods described by Snedecor and Cochran (1994) with chi square test

RESULTS AND DISCUSSION

Out of 478 cattle screened for LSDV, 267 were found seropositive indicating overall seroprevalence of 55.85%. The seroprevalence of LSD recorded in different breeds of cattle was highest in non-descript (79%) cattle followed by Holstein Friesian (9.7%), Khillar (6.4%) and Red Kandhari

(4.9%) (Table 1). Gender wise higher prevalence of LSD was recorded in males (59.2%) than in females (40.8%) cattle (Table 2). The age wise seroprevalence in calves, young and adults was 31.5%, 12.4% and 56.2% respectively (Table 3). Statistically non-significant differences were found in breed wise, gender wise and age wise seroprevalence of LSD in cattle.

Overall clinical manifestations in all Lumpy skin disease affected cattle were fever (100%) in initial stage of disease followed by appearance of skin nodules all over the body surface (73%). The nodules were well circumscribed, round, slightly raised, firm, painful and were around (1-3 cm) in size (Fig 1, 2). In addition, oedema of legs (27%) (Fig 1), lameness (Fig 3) (27%), enlarged lymph node (14.2%) and corneal opacity (4.8%) (Fig 5) were recorded. In few LSD affected cattle, some of the nodules were oozing and formed deep-seated drained nodules (Fig 4). The nodular skin lesions were particularly extensive in the fetlock region, extending up to the underlying subcutis and muscle. Some of the nodules regressed and in some the necrosis of the skin resulted in hard, raised areas (sit-fasts) clearly separated from the surrounding skin. Nasal discharge was apparent only in few LSD affected cases.

The molecular assay of LSD revealed that, out of 478 cattle screened, 267 (55.85%) serum samples were found positive by ELISA test. Whereas, among 267 blood samples and 8 scab samples tested by PCR, 82 blood samples (30.7%) (Fig 7) and 5 scab samples (62.5%) (Fig 6) were found positive for LSDV in cattle. Gel electrophoresis of the P32 amplicons showed a 164 bp product in blood samples collected in Parbhani district, as illustrated for Ten representative samples of blood selected samples in Fig 7. An amplification of 199 bp DNA fragment with capripoxvirus-specific primers indicated the presence of capripoxvirus in five scab samples (Fig 5). The PCR result confirmed *capripoxvirus* DNA in all samples.

Out of 478 serum samples 267 serum samples tested positive by indirect ELISA showing high OD titre value. High titre value shown by sample no 7, 33, 49 and 50 as shown (Fig 8).

The seroprevalence of LSDV in the present study was 55.85% in contrast 85.91% reported by Kresic *et al.* (2020).

The first successful isolation of LSDV in India was reported by Kumar *et al.,* (2021) and might be introduced in India by way of import of animals or animal products from Africa or due to movements of vectors from neighboring countries such as Bangladesh in recent years and movements of livestock across international borders.

Various researchers have recorded prevalence of LSDV such as 12.3% (Sevik *et al.,* 2016), 6.5% (Zeynalova *et al.,* 2016), 7.1% (Sudhakar *et al.,* 2020) and 13.93% (Sethi *et al.,* 2021). The morbidity rate varied widely from 3% to 85% depending on the immune status of the hosts and the abundance of mechanical arthropod vectors and can reach as high as 100% in natural outbreaks of LSD. While mortality rate rarely exceeds 5% sometimes reach upto 40% Amenu *et al.* (2018).

The cattle of all ages, gender and breeds (mostly of indigenous/non-descript) and cross breed were affected for LSD (Sudhakar *et al.,* 2020). In contrast, Sethi *et al.* (2021)

Table 1: Breed wise seroprevalence of lumpy skin disease in cattle.

Breed	Number of cattle screened	No. of cattle positive	Per cent seroprevalence	Chi square value
Non-descript	348	211	79.00	8.18
Holstein friesian	56	26	9.7	
Khillar	39	17	6.4	
Red Kandhari	30	13	4.9	
Gir	5	0	0	
Total	478	267		

Table 2: Gender wise seroprevalence of lumpy skin disease in cattle.

Gender	Number of cattle screened	No. of cattle positive	Per cent seroprevalence	Chi square value
Male	297	158	59.2	0.98
Female	181	109	40.8	
	478	267		

Table 3: Age wise seroprevalence of lumpy skin disease in cattle.

Age group	Number of cattle screened	No. of cattle positive for lumpy skin disease	Per cent seroprevalence of lumpy skin disease	Chi square value
0-2 Year	129	84	31.5	3.41
2-4 Year	72	33	12.4	
4 Year and above	277	150	56.2	
	478	267		



Fig 1: Oedematous swelling on dewlap, brisket region with generalized nodules in a Non-descript cattle.



Fig 4: Oozing of wound in LSD affected cattle.



Fig 2: Extensive nodular lesions in nasal cavity, around nostril, with serous blood-tinged nasal discharge in LSD affected HF cattle.



Fig 5: Corneal opacity with lacrimation in LSD affected cattle.



Fig 3: Small skin nodules, lameness in left foreleg in LSD affected Khillar bullock.

noted higher prevalence of LSD 14.31% in crossbred cattle and lowest 7.79% in native breeds. The breed showed a significant association with LSD seropositivity with cross breed being approximately 3 times more likely to be seropositive compared to indigenous animals (Abera *et al.,* 2015).

Adult cattle showed higher prevalence (55.42%), than calves under one year of age (46.34%) by (Albayrak *et al.,* 2018). Similarly, Ahmed and Zaher (2008), Biswas *et al.,* (2020) and Limon *et al.,* (2020) reported more incidence of LSD in young age than in adults. The LSD affected animals were between 4 months and 14 years (mean age 6.4 year) as recorded by Pandey *et al.,* (2021). In contrast, the highest prevalence of LSD in animals less than one year age group was observed by (Ahmed and Zaher, 2008; Sevik and Dogan, 2017) and opined that the incidence of LSD increased as age increases.

Clinically LSD is characterized with visible skin nodules, anorexia, pyrexia, decreased milk production and body weight However, mastitis and myiasis were noted as complication in a few LSD affected animals (Abutarbush *et al.,* 2015). Marked reduction in milk production, fever, skin nodules and lesions in the mucous membranes of mouth, lacrimation, nasal discharge, anorexia, unwillingness, emaciation and enlarged lymph nodes were also observed in LSD infected animals. Skin lesions mostly observed on neck and back region while mammary gland and teats were also affected in LSD (Sevik *et al.,* 2016).

The clinical findings like fever, skin nodules on the neck, back, perineum, tail, hind limbs and genital organs, enlarged superficial lymph nodes and, in some cases, legs and brisket edema along with lameness were also reported by Kumar *et al.* (2021); Sudhakar *et al.* (2020); Pandey *et al.* (2021) and Sethi *et al.* (2021) with variable clinical signs which corroborated with our findings.

Scab samples are more efficient for detection of LSDV by PCR than blood samples. Molecular-based assays are powerful and precise diagnostic tools for the detection of clinically relevant infectious agents (Cara, 2016). The Lumpy skin disease virus confirmation from blood samples by oolymerase chain reaction test was reported by Ben-Gera *et al.* (2015); Zeynalova *et al.* (2016); Zeedan *et al.* (2019); Acharya *et al.* (2020); Ochwo *et al.* (2020) and Sudhakar *et al.* (2020).



Fig 6: PCR and agarose gel electrophoresis (1.5%) for screening of LSDV suspected cattle from scab sample.



Fig 7: PCR and agarose gel electrophoresis (1.5%) for screening of LSDV suspected cattle from blood sample.

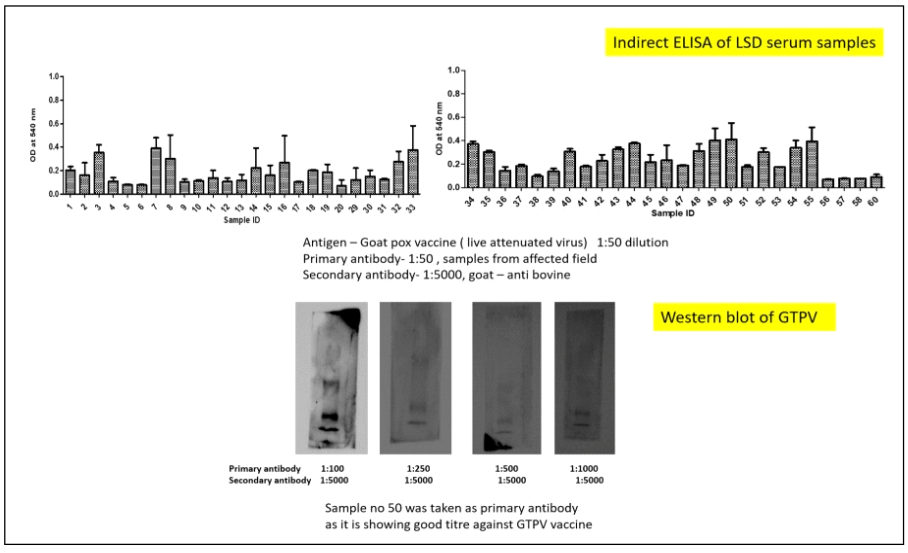

Fig 8: Serum samples showing the OD titre values by indirect ELISA sample no 50 showing high titre value.

The LSDV confirmation from tissue/scab samples by PCR test was documented by Molini *et al.* (2018); Zeedan *et al.* (2019); Acharya *et al.* (2020); Sudhakar *et al.* (2020); Badhy *et al.* (2021) and Yimer, (2021). The PCR technique was also used to detect *capripoxvirus* antigen from cell culture and biopsy specimens (Bowden *et al.,* 2009). LSDV genome was detected more in scabs (79.16%) than blood (31.81%) reported by Sudhakar *et al.* (2020).

The earliest ELISA developed for *Capripoxviruses* utilized a protein encoded by P32 (vaccinia H3L homologue) as an antigen (Carn *et al.,* 1994 and Heine *et al.,* 1999). More recently, an indirect ELISA was developed based on whole heat-inactivated sheep pox virus as an antigen (Babiuk *et al.,* 2009). *Capripoxviruses* antibodies were detected with ELISA in 85.91% (250/291) (Kresic *et al.,* 2020) and 48.70% (75/154) samples sero-positive (Milovanovic *et al.,* 2020). Antibodies against LSDV were detected in serum sample using ELISA (Bhanuparkash *et al.,* 2006 and Zeedan *et al.,* 2019).

CONCLUSION

Seroprevalence was highest in non-descript cattle than other pure breed cattle. Scab/tissue was found more efficient in comparison to blood for molecular detection by PCR. Fever and circumscribed nodules on the skin were predominant clinical manifestations along with other signs such as oedema of legs, lameness, lymph node enlargement and corneal opacity.

ACKNOWLEDGEMENT

We are grateful to National Institute of Animal Biotechnology, Hyderabad for providing the necessary support to carry out the molecular studies and his kind counsel whenever necessary and provided access to laboratory and research facilities. Without they precious support it would not be possible to conduct this research.

Conflict of interest

All authors declare that they have no conflict of interest.

REFERENCES

Abera, Z., Degefu, H., Gari, G. and Kidane, M. (2015). Sero-prevalence of lumpy skin disease in selected districts of West Wollega zone, Ethiopia. BMC Veterinary Research. 11(1): 1-9.

Abutarbush, S.M., Ababneh, M.M., Al Zoubi, I.G., Al Sheyab, O.M., Al Zoubi, M.G., Alekish and Al Gharabat, R.J. (2015). Lumpy Skin Disease in Jordan: Disease emergence, clinical signs, complications and preliminary associated economic losses. Transboundary and Emerging Diseases. 62(5): 549-554.

Acharya, K.P. and Subedi, D. (2020). First outbreak of lumpy skin disease in Nepal. Preventive Veterinary Medicine. 102(4): 274-283.

Ahmed, W.M. and Zaher, K.S. (2008). Observations on lumpy skin disease in local Egyptian cows with emphasis on its impact on ovarian function. African Journal of Microbiology Research. 2(10): 252-257.

Albayrak, H., Ozan, E., Kadi, H., Cavunt, A., Tamer, C. and Tutuncu, M. (2018). Molecular detection and seasonal distribution of lumpy skin disease virus in cattle breeds in Turkey. Medycyna Weterynaryjna. 74(03): 175-178.

Amenu, A., Bekuma, F., Abafaji, G. and Abera, D. (2018). Review on epidemiological aspects and economic impact of lumpy skin disease. Journal of Dairy and Veterinary Sciences. 7(4): 555-716.

Annandale, C.H., Holm, D.E., Ebersohn, K. and Venter, E.H. (2014). Seminal transmission of lumpy skin disease virus in heifers. Transboundary and Emerging Diseases. 61(5): 443-448.

Babiuk, S., Wallace, D.B., Smith, S.J., Bowden, T.R., Dalman, B., Parkyn, G. and Boyle, D.B. (2009). Detection of antibodies against capripoxviruses using an inactivated sheeppox virus ELISA. Transboundary and Emerging Diseases. 56(4): 132-141.

Badhy, S.C., Chowdhury, M.G.A., Settypalli, T.B.K., Cattoli, G., Lamien, C.E., Fakir, M.A. and Sadekuzzaman, M. (2021). Molecular characterization of lumpy skin disease virus (LSDV) emerged in Bangladesh reveals unique genetic features compared to contemporary field strains. BMC Veterinary Research. 17(1): 1-11.

Ben-Gera, J., Klement, E., Khinich, E., Stram, Y. and Shpigel, N.Y. (2015). Comparison of the efficacy of Neethling lumpy skin disease virus and x10RM65 sheep-pox live attenuated vaccines for the prevention of lumpy skin disease-The results of a randomized controlled field study. Vaccine. 33(38): 4837-4842.

Bhanuprakash, V., Hosamani, M., Juneja, S., Kumar, N. and Singh, R.K. (2006). Detection of goat pox antibodies: Comparative efficacy of indirect ELISA counter immune electrophoresis. Journal of Applied Animal Research. 30(2): 177-180.

Biswas, D., Saha, S.S. and Sayeed, S.B. (2020). Outbreak of lumpy skin disease of cattle in south-west part of Bangladesh and its clinical management. Veterinary Sciences: Research and Reviews. 6(2): 100-108.

Bowden, T.R., Coupar, B.E., Babiuk, S.L., White, J.R. and Boyd, V. (2009). Detection of antibodies specific for sheeppox and goatpox viruses using recombinant capripoxvirus antigens in an indirect enzyme-linked immunosorbent assay. Journal of Virological Methods. 161: 19-29.

Cara, N., (2016). Challenges and solutions in the development and validation of molecular-based assays. The Essentials of Life Science Research Globally Delivered, USA.

Carn, V.M., Kitching, R.P., Hammond, J.M. and Chand, P. (1994). Use of a recombinant antigen in an indirect ELISA for detecting bovine antibody to *capripox virus*. Journal of Virological Methods. 49(3): 285-294.

Chihota, C.M., Rennie, L.F., Kitching, R.P. and Mellor, P.S. (2001). Mechanical transmission of lumpy skin disease virus by *Aedes aegypti (Diptera: Culicidae)*. Epidemiology and Infection. 126 (2): 317-321.

Coetzer, J.A.W, Tuppurainen, E., Babiuk, S. and Wallace, D.B. (2018). Lumpy Skin Disease. In: Infectious Diseases of livestock, [Coetzer, J.A.W., Thomson, G.R., Maclachlan, N.J. and Penrith, M.L. (eds)]. Part II. Gauteng, South Africa, Anipedia. pp.1268-1276.

Gumbe, A.A.F. (2018). Review on lumpy skin disease and its economic impacts in Ethiopia. Journal of Dairy, Veterinary and Animal Research. 7(2): 39-46.

Gupta, T., Patial, V., Bali, D., Angaria, S., Sharma, M. and Chahota, R. (2020). A review: Lumpy skin disease and its emergence in India. Veterinary Research Communications. 1-8.

Heine, H. Stevens, M.P., Foord, A.J. and Boyle, D.B. (1999). A capripoxvirus detection PCR and antibody ELISA based on the major antigen P32, the homolog of the vaccinia virus H3L gene. Journal of Immunological Methods. 227 (1-2): 187-196.

Kresic, N., Simic, I., Bedekovic, T., Acinger-Rogic, Z. and Lojkic, I. (2020). Evaluation of serological tests for detection of antibodies against lumpy skin disease virus. Journal of Clinical Microbiology. 58(9): e00348-20.

Kumar, N., Chander, Y., Kumar, R., Khandelwal, N., Riyesh, T., Chaudhary, K. and Tripathi, B.N. (2021). Isolation and characterization of lumpy skin disease virus from cattle in India. PloS one. 16(1): e0241022.

Limon, G., Gamawa, A.A., Ahmed, A.I., Lyons, N.A. and Beard, P.M. (2020). Epidemiological characteristics and economic impact of lumpy skin disease, sheeppox and goatpox among subsistence farmers in northeast Nigeria. Frontiers in Veterinary Science. 7: 8.

Milovanovic, M., Milicevic, V., Radojicic, S., Valcic, M., Hoffmann, B. and and K. Dietze, K. (2020). Suitability of individual and bulk milk samples to investigate the humoral immune response to lumpy skin disease vaccination by ELISA. Virology Journal. 17(1): 1-7.

Molini, U., Aikukutu, G., Khaiseb, S., Haindongo, N.N., Lilungwe, A.C., Cattoli, G. and Lamien, C.E. (2018). Molecular characterization of lumpy skin disease virus in Namibia, Archives of Virology. 163(9): 2525-2529.

Ochwo, S., Vander Waal, K., Ndekezi, C., Nkamwesiga, J., Munsey, A., Witto, S.G. and Mwiine, F.N. (2020). Molecular detection and phylogenetic analysis of lumpy skin disease virus from outbreaks in Uganda 2017-2018. BMC Veterinary Research. 16(1): 1-10.

OIE, (2017). Chapter 2.4.13. Lumpy skin disease OIE Terrestrial Manual. https://www.oie.int/fileadmin/home/eng/health_standards/tahm/2.04.14_lsd.pdf.

OIE, (2018). Manual of Diagnostic Tests and Vaccines for Terrestrial Animals, Office International des Epizooties. Paris, France: World Organization for Animal Health.

Pandey, N., Hopker, A., Prajapati, G., Rahangdale, N., Gore, K. and Sargison, N. (2021). Observations on presumptive lumpy skin disease in native cattle and Asian water buffaloes around the tiger reserves of the central Indian highlands. New Zealand Veterinary Journal. pp. 1-8.

Roche, X., Rozstalnyy, A., TagoPacheco, D., Pittiglio, C., Kamata, A., Beltran Alcrudo, D., *et al*. (2020). Introduction and Spread of Lumpy Skin Disease in South, East and Southeast Asia: Qualitative Risk Assessment and Management. FAO Animal Production and Health, Paper 183. Rome, FAO. https://doi.org/10.4060/cb1892en.

Rouby, S. and Aboulsoud, E. (2016). Evidence of intrauterine transmission of lumpy skin disease virus. The Veterinary Journal. 209: 193-195.

Sethi, R.K., Senapati, S.K., Selim, A.M., Acharya, A.P., Mishra, C., Das, M. and Biswal, S.S. (2021). Molecular Epidemiology of first Lumpy Skin Disease outbreak in Odisha, India.

Sevik, M. and Dogan, M. (2017). Epidemiological and molecular studies on lumpy skin disease outbreaks in Turkey during 2014-2015. Transboundary and Emerging Diseases. 64(4): 1268-1279.

Sevik, M., Avci, O., Dogan, M. and Ince, O.B. (2016). Serum biochemistry of lumpy skin disease virus-infected cattle. BioMed Research International. https://doi.org/10.1155/2016/6257984.

Snedecor, G.W. and Cochran, W.G. (1994) Statistical Methods. Oxford and IBH, New Delhi.

Sudhakar, S.B., Mishra, N., Kalaiyarasu, S., Jhade, S.K., Hemadri, D., Sood, R. and Singh, V.P. (2020). Lumpy skin disease (LSD) outbreaks in cattle in Odisha state, India in August 2019: Epidemiological features and molecular studies. Transboundary and Emerging Diseases. 67(6): 2408-2422.

Weiss, K.E. (1968). Lumpy skin disease virus. In *Cytomegaloviruses.* Rinderpest Virus. Lumpy Skin Disease Virus Springer, Berlin, Heidelberg. pp. 111-131.

Yimer, L. (2021). Conventional and molecular tests of lumpy skin disease. Journal of Animal and Veterinary Advances. 20(1). doi: 10.36478/javaa.2021.15.31.

Zeedan, G.S.G., Mahmoud, A.H., Abdalhamed, A.M. and Abd El, K.A.E.H. (2019). Detection of lumpy skin disease virus in cattle using real-time polymerase chain reaction and serological diagnostic assays in different governorates in Egypt in 2017. Veterinary World. 12(7): 1093-1100.

Zeynalova, S., Asadov, K., Guliyev, F., Vatani, M. and Aliyev, V. (2016). Epizootology and molecular diagnosis of lumpy skin disease among livestock in Azerbaijan. Frontiers in Microbiology. 7: 1022.