RESEARCH ARTICLE Indian Journal of Animal Research, Volume 60 Issue 3: 522-527 (March 2026)

Application of Autologous Platelet Rich Plasma in a Wound Management in Animals

J.J. Parmar[1], Arnold Mecvan[2], Aditya Shah[1], Neha Rao[1], Kamlesh Hadiya[1]

10.18805/IJAR.B-4942

ABSTRACT

Background: Now a days application of PRP has gain an attraction in veterinary surgical cases for the management of complicated wounds on animal body specially open fractures of long bones with deep, extensive, complicated wounds where routine medicinal management alone not work to preserve the limbs and healing of wounds.

Methods: Total forty five animals comprised of dogs (n = 28), goats (n = 14), cat (n = 2) and horse (n = 1) with different complicated wounds on limbs and other body parts were taken in to study. The evaluation of wound and therapeutic management according to conditions were carried out. The wounds were treated with autologous PRP. The day on which first application of autologous PRP was done considered as a day '0' and repeat application done after one week interval till healing as per requirements.

Result: The limbs of animals were preserved instead of amputation and other wounds healed within 15-20 days except in a cat. Only two repetition of PRP treatment was needed for complete healing of wounds.

Key words: Animals, Complicated wounds, PRP, Wound management.

INTRODUCTION

In animals due to various types of injuries and trauma, the deep extensive wounds are most common encountered condition which needs emergency attention of veterinarians. The animals are more prone to various wounds on body with multiple complications and the management of such cases become very difficult and challenging. In some cases animals with injuries on limbs need to be amputation of limbs or chronic wounds need long term therapy comprised of complex managemental therapeutics with regular debridement of damaged and necrotic tissues local and/or systemic infection control, protection of the underlying tissues and induction of cutaneous tissue regeneration. Sometime reconstructive surgeries along with medicinal therapeutics do not maintain normal anatomical and functional properties of damaged tissues. To prevent such complications and for batter outcome regenerative or cell therapy need to be applied in animals. The use of autologous platelet concentrates has gained large popularity in a variety of medical fields like dentistry, oral and maxillofacial surgery, orthopaedics and sports medicine (Virchenko and Aspenberg, 2006), to treat various ophthalmic disorders and also applied in plastic surgery and aesthetic medicine (Cervelli *et al*., 2009). PRP is newly considered in veterinary practice and widely used in clinical practice due to its autologous structure restraining immune reactions, availability, easy and fast application procedure, relatively less expense and high efficiency with satisfactory results are reported in various animals (Dalgin *et al*., 2017).

Now a days applications of PRP has gain an attraction in veterinary surgical cases for the management complicated wounds on animal body, tendon injuries for the therapeutic management along with batter outcome and welfare on animals. This paper presents a study on applications of autologous PRP on various types of complicated wounds in animals.

[1]Veterinary Clinical Complex, Veterinary College, Kamdhenu University, Anand, Gandhinagar-382 010, Gujarat, India.
[2]Department of Vet. Surgery and Radiology, Veterinary College, Kamdhenu University, Anand, Gandhinagar-382 010, Gujarat, India.

Corresponding Author: J.J. Parmar, Veterinary Clinical Complex, Veterinary College, Kamdhenu University, Anand, Gandhinagar-382 010, Gujarat, India. Email: jigneshparmar2000@gmail.com

How to cite this article: Parmar, J.J., Mecvan, A., Shah, A., Rao, N. and Hadiya, K. (2026). Application of Autologous Platelet Rich Plasma in a Wound Management in Animals. *Indian Journal of Animal Research*. **60(3):** 522-527. doi: 10.18805/IJAR.B-4942.

Submitted: 23-05-2022 **Accepted:** 07-09-2022 **Online:** 17-09-2022

MATERIALS AND METHODS

Forty five cases comprised of dogs (n=28), goats (n=14), cat (n=2) and horse (n=1) with different types complicated of wounds on limbs and other body parts were presented to Veterinary Clinical Complex, College of Veterinary Science and Animal Husbandry, Kamdhenu University, Anand- Gujarat. The evaluation of wound done and therapeutic management according to conditions were carried out. The day on which first application of autologous PRP was done considered as a day '0' and repeat application done after one week interval till healing as per requirements. 5-20 ml of whole blood as per wounds size was collected from all animals aseptically and centrifuged 3000 rpm for ten minutes. After centrifugation the blood was divided in to three parts. One third of plasma supernatant (PPP) was discarded and remaining plasma was collected and used as platelet reach plasma. The PRP was injected locally on different region of wounds.

In second cycle onwards of application the PRP was injected on wound where more granulation needed.

RESULTS AND DISCUSSION

Total forty five clinical cases were included in the study comprising of dogs (n = 28), goats (n = 14), cat (n = 2) and horse (n = 1) presented with different types of complicated wounds. Amongst the cases of dogs, five dogs were presented with extensive loss of muscles, skin and open fracture of radius and ulna along with maggot infestation (Fig 1A) while in three dogs extensive wound from upper hock joint to paw region (Fig 2A) and chronic wound on left hind limb and maggot infestation with bone exposure in two dogs (Fig 3A) whereas in six dogs there were open fracture of digits among them, in five dogs there were extensive tear of digital region and all digital bones were exposed (Fig 4A), in a one dog there were complete separation of first and second digits along with mild granulation and infection seen but skin wound was extensive at the time of presentation (Fig 5A). All cases were presented in very bad conditions with expectation of amputation of limbs as a last treatment. In twelve dogs, chronic ulcerated wounds on limbs due various aetiologies like vincristine slough (Fig 6A), licking habit of dogs (n = 6), ulcerated wound on neck region and chronic diabetic ulcerated wound on base of right ear since one year, deep extensive wound with damage to muscles and skin along with maggot infestation on perineal area, lumber region, tail, maggoted wound on face region and extensive

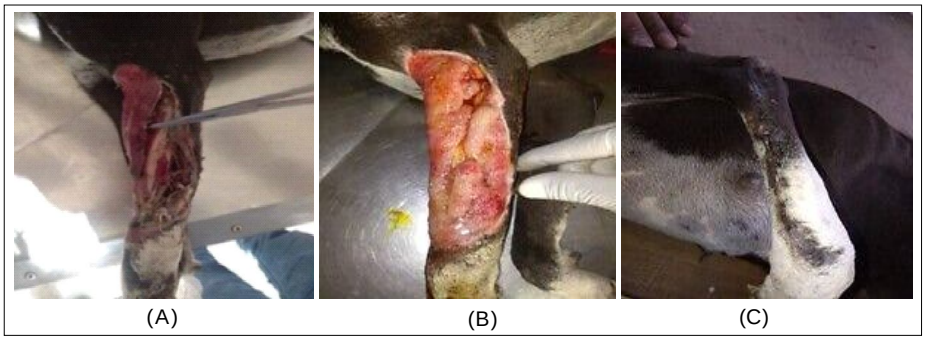

Fig 1: (A) Open fracture of radius and ulna with maggot infestation; (B) Marked granulation with wound contraction on day 7th; (C) Complete wound healing on day 20th.

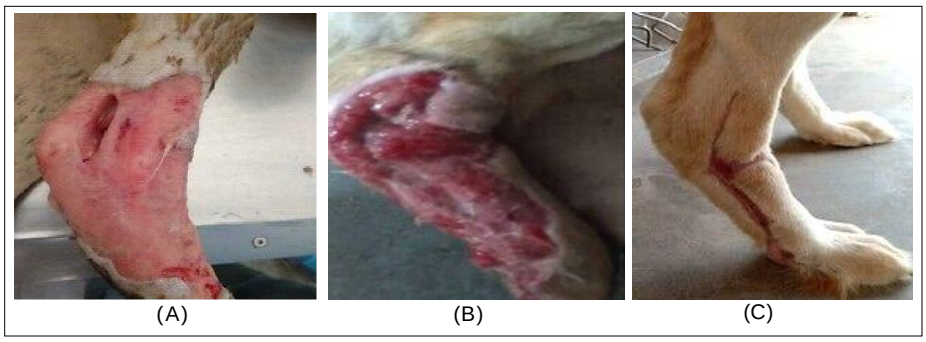

Fig 2: (A) Extensive wound from upper hock joint to paw region; (B) Marked granulation and significant wound contractions on day 5th; (C) Wound healing on day 23rd.



Fig 3: (A) chronic wound on left hind limb and maggot infestation with bone exposure; (B) Mild over granulation on digital region; (C) Complete wound healing on day 25th.

damage to nostrils and nasal bone was exposed (n = 1, each) (Fig 7A). In cases of goats various types of deep chronic wounds on different body parts were treated with PRP among them five goats were presented with extensive wounds on limb with history of automobile accident while in remaining nine goats deep chronic, contaminated, maggot wounds caused by various aetiologies like dog bites, injuries by sharp objects on thigh (Fig 8A), abdominal region and base of tail. In cats there were extensive skin sloughing due to dermatitis and itching on face region and extensive cutaneous wound on back region. In a horse there was a deep wound in sternal region caused by trauma by wire fencing.

In all dogs the wounds treated with antiseptic dressing using Betadine 5% along with Inj. Cefrtiaxone and Tazobactum @ 15 mg/kg body weight in dogs and cat, in goat 20 mg/kg body weight and 10 mg/kg body weight in horse; and Inj. Meloxicam @ 0.2 mg/kg body weight in dogs, goats and cat, 0.5 mg/kg body weight in horse, intravenously. The cases presented with maggot wounds were treated initially by removing maggots manually, tropical antiseptic dressing along with Inj. Ivermectine @ 200 mcg/kg body weight in dogs and goats, subcutaneously. The wounds treated with autologous PRP on day of presentation except the wounds with maggot wounds treated next day. In cases of open fractures the bones were aligned and the cases with digital bone fractures were stabilize by bandages. All animals were treated every alternate day and bandages were changed. All the animals were given daily oral antibiotics to cure and prevent infections on wounds.

In dogs with open fractures, noticeable granulation seen on day 3 along with exudation from periphery of wound which treated with anti-inflammatory and antibiotics. The gradual



Fig 4: (A) Extensive tear with exposed digital bones; (B) Mild over granulation on digital region; (C) Complete wound healing on day 21st.

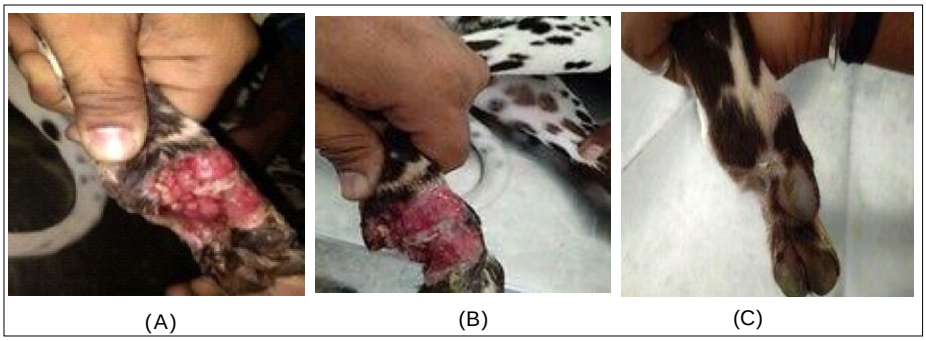

Fig 5: (A) Extensive wound with mild granulation; (B) Mild over granulation on digital region; (C) Complete wound healing on day 30th.

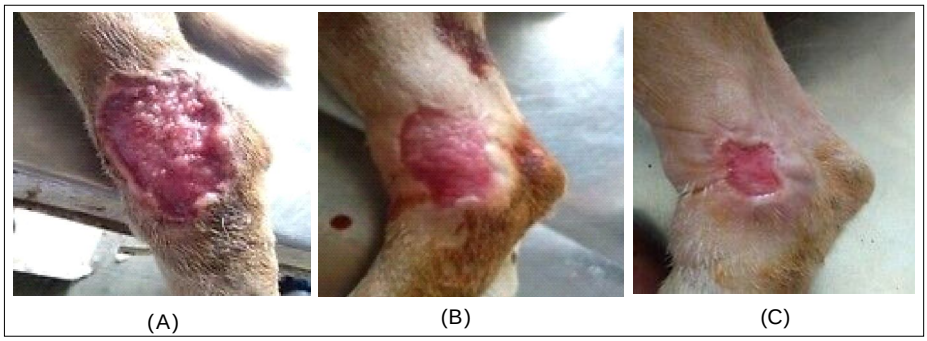

Fig 6: (A) Vincristine slough; (B) Mild over granulation on digital region; (C) Wound healing on day 30th.

rise in granulation cover the bones and marked wound contraction seen (Fig 1B) on day 7-10. In cases of fractures healing noticed within twenty five days. The wounds were completely healed within 28 to 35 days in all cases. In other dogs granulation was started from second day, on fifth day there was marked granulation and significant wound contractions seen in all cases (Fig 2B). The epithelisation was significantly noticed in wounds treated with PRP. The PRP treatment was repeated at week interval up to second repetition. In dogs with wounds on digital region there were mild over granulation seen which interfere in skin healing (Fig 3B to 6B). So further PRP treatment was not given. In these cases, the skin separated from underlying granulating tissue carried every three days to enhance skin regeneration while the wound and the complete healing seen on day 20 to day 35 according to size of wound and gap between skin edges (Fig 1C to Fig 6C). In dogs with wounds other than limbs does not required separation of skin and wound heals completely within day 18 to day 21 (Fig 7B and 7C). In dogs with fracture PRP also helps to heal the fractures. In case of goats and horse similar healing pattern was seen and wounds heal within fifteen days (Fig 8B and 8C). In cat after PRP treatment granulation was not marked as in dogs and goats on next day. There was mild granulation seen on day 5. The granulation and wound contraction were not satisfactory in this cat and it was died due to automobile accident so further observations were not possible. In horse on next day marked granulation seen thus, suturing of muscles tissue and skin planned three days after PRP treatment. These wounds treated as routine wound management till healing and it was healed completely within fifteen days of PRP.

In this study it was observed that PRP help to regenerate granulation tissue which is very necessary in wounds with bones exposed or fractured. These granulation tissue protects the osteal surface from the environmental contamination as well as necrosis. The granulation tissue carry capillaries which also help bone to remodelling. In some cases of extensive skin damage on limbs, it was observed that at some point skin separation from underlying tissues was needed to further growth of skin for healing of wounds.

Wound healing is a well-orchestrated and complex series of events involving cell-cell and cell-matrix interactions with growth factors serving as messengers to regulate the various processes involved. Platelets are non-nucleated cells megakaryocytes that reside in the bone marrow. During their development platelets obtain large numbers of storage granules that contain different growth factors, cytokines and hormones required for activating acute inflammation which is the first stage of wound repair (Parrish and Roides, 2017). The α-granules release many growth factors that may favour regeneration and healing. Among them there are: platelet-derived growth factor, transforming growth factor-β,vascular endothelial growth factor, basic fibroblast growth factor, insulin-like growth factor, epidermal growth factor and platelet-derived epidermal growth factor (Sequeria *et al.*, 2006).



Fig 7: A Exposed nasal bone and damage to nostrils; (B) Granulation and wound contraction on face region on day 7th; (C) Complete wound healing on day 18th.

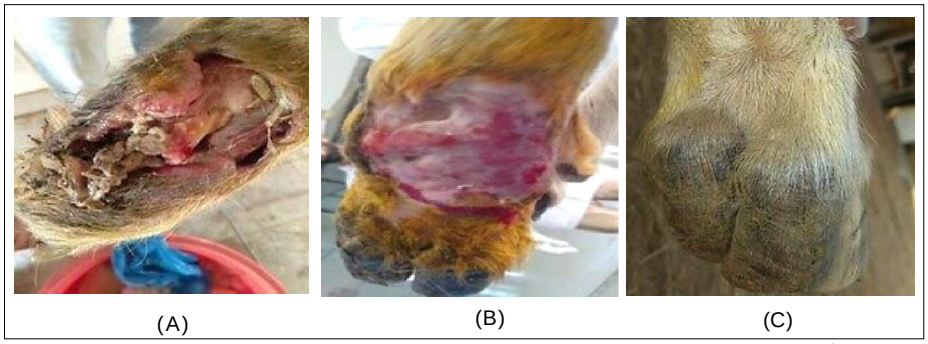

Fig 8: (A) Chronic maggoted wound on limb; (B) Granulation and wound contraction on day 7th; (C) Complete wound healing on day 15th.

Various intrinsic and extrinsic factors like diabetes, environmental contamination, animal behaviour which affects the wound healing and lead to delayed healing or non-healing. Sometime expansion of the wounds leads exposure of deep tissues and bones. The conventional treatment for the wound management like debridement, lavage and antiseptic dressing not always act effectively. Such cases needs advanced therapeutic to regenerate new tissue for enhance healing and to save the affected body parts.

Cutaneous wound healing requires a complex balance between matrix elements and growth factors and is dependent on multiple variables, including blood supply, defect size, tension and mobility that affect the rates of healing and residual scarring (Diegelmann and Evans, 2004). Platelet rich plasma (PRP) not only enhances wound healing but also used as a source of growth factors in bone fracture treatment and helps regenerate skin tissue (Chung *et al*., 2015). In the PRP treated wounds the polymorphonuclear cells were infiltrating the top of wound whereas marcrophages and migrating fibroblasts were observed at the base of the wound at the first week; Re-epithelization recorded a significant increase at the second week, granulation tissue was formed beneath the epithelium that was rich in fibroblasts and newly formed blood vessels at the third week, the epithelium increased in thickness that was more observed in the wound treated with PRP in dogs (Farghali *et al*., 2017).

There are various reports available for the preparation of PRP with different centrifuged to achieve a proper concentration of platelets. In the present study the whole blood was centrifuged at 3000 rpm for ten minutes which was found satisfactory for granulation. The amount of blood was varies from 5 ml to 20 ml due to variable size of wounds. Dalgin *et al*. (2017) treated injured tail in a Kangal dog and reported satisfactory granulation within week period of time. The reduction in exudation and increase amount of granulation observed in our study which is in agreement with the findings of Iacopetti *et al.* (2020) reported significant wound contraction and complete closure, re-epithelialisation in all cases and no complications associated with PRP treatment occurred in any patient, healing time varied between 30 and 45 days and no abnormal tissue formation, keloid or pathologic scarring were observed and in all cases, a hair growth occurred even where large losses of skin were present. Gemignani *et al*. (2017) used canine derived heterologous PRP in cat with contaminated wound results in significant granulation and wound contraction while in the present study used homogenous PRP which did not got satisfactory granulation. Cat platelets appear especially sensitive to activation during blood sample collection and handling, resulting in degranulated platelet aggregates which may be overlooked by an inexperienced observer. Some of the precipitated cryoglobulin recognized in blood from a cat with a monoclonal cryoglobulinemia also resembled aggregates of degranulated platelets (Zufferey *et al*., 2017). Ferdousy *et al*. (2013) used homogenous platelet rich gel in caprine and found similar healing pattern while DeRossi *et al*. (2009) and Iacopetti*et al*. (2011) had used PRP in skin wound in horse but the healing period was logger than the findings of this study in horse.

CONCLUSION

In the present study the topical application of autologous PRP was found to be useful in different species of animals. It helps to preserved the limbs of animals which need amputation in cases of open fractures of long bones. PRP is a cost-effective and readily available therapeutic blood derivative that is rich in growth factors and cytokines and increases tissue regeneration and easy to use compare with other techniques which do not required any specialization. Topical treatment with autologous PRP is a safe adjunct therapy for fractures and skin wound healing particularly beneficial to manage large skin defects in animals.

Conflict of inteest

All authors declare that they have no conflict of interest.

REFERENCES

Cervelli, V., Palla, L., Pascali, M., De Angelis, B., Curcio, B.C. and Gentile, P. (2009). Autologous platelet-rich plasma mixed with purified fat graft in aesthetic plastic surgery. *Aesthetic Plastic Surgery.* **33(5):** 716-721.

Chung, T., Baek, D., Kim N, Park, J. and Park, C. (2015). Topical allogeneic platelet-rich plasma treatment for a massive cutaneous lesion induced by disseminated intravascular coagulation in a toy breed dog. *Irish Veterinary Journal.* **68:** 1-4.

Dalgin, D., Meral, Y., Onyay, T. and Cenesiz, M. (2017). Platelet rich plasma (PRP) treatment in a dog with heavily injured tail due to tail chasing behavior. *Harran Üniversitesi Veteriner Fakültesi Dergisi.* **6(1):** 99-101.

DeRossi, R., Coelho, ACAO., Mello, G.S., Frazílio, F.O., Leal, CRB., Facco, G.G. and Brum, K.B. (2009). Effects of platelet-rich plasma gel on skin healing in surgical wound in horses. *Acta Cirúrgica Brasileira*. **24(4):** 276-281.

Diegelmann, R.F. and Evans, M.C. (2004). Wound healing: An overview of acute, fibrotic and delayed healing. *Frontiers in Bioscience.* **9:** 283-289.

Farghali, H.A., AbdEl, K.N.A., Khattab, M.S. and Abu, B.H.O. (2017). Evaluation of subcutaneous infiltration of autologous platelet-rich plasma on skin-wound healing in dogs. *Bioscience Reports.* **37(2):** BSR20160503. doi: 10.10 42/ BSR20160503.

Ferdousy, R.N., Rahman, M., Paul, S., Hadi, A. and Khan, H.N. (2013). Role of platelet rich plasma gel in the wound healing of black Bengal goat. *Journal of Agriculture and Veterinary Science.* **6(5):** 14-21.

Gemignani, F., Perazzi, A. and Iacopetti, I. (2017). Use of canine sourced platelet-rich plasma in a feline contaminated cutaneous wound. *Canadian Veterinary Journal*. **58:** 141-144.

Iacopetti, I., Perazzi, A., Ferrari, V. and Busetto, R. (2011). Application of platelet rich gel to enhance wound healing in the horse: A case report. *Journal of Equine Veterinary Science.* pp. 1-6.

Iacopetti, I., Patruno, M., Melotti, L., Martinello, T., Bedin, S., Badon, T., Righetto, E.M. and Perazzi, A. (2020). Autologous platelet-rich plasma enhances the healing of large cutaneous wounds in dogs. *Frontier in Veterinary Science.* **7:** 1-8.

Parrish, W.R. and Roides, B. (2017). Platelet rich plasma in osteoarthritis: More than a growth factor therapy. *Musculoskeletal Regeneration.* **3:** 1518.

Sequeria, J.P. and Johri, S. (2015). Platelet rich plasma: Clinical applications in dentistry. *Scholars Journal of Dental Sciences.* **2(6):** 355-362.

Virchenko, O. and Aspenberg, P. (2006). How can one platelet injection after tendon injury lead to a stronger tendon after 4 weeks? Interplay between early regeneration and mechanical stimulation. *Acta Orthopaedica.* **77(5):** 806-812.

Zufferey, A., Fontana, P., Reny, J., Nolli, S. and Sanchez, J. (2012). Platelet proteomics. *Mass Spectrometry Reviews.* **31(2):** 331-351.