RESEARCH ARTICLE Indian Journal of Animal Research, Volume 59 Issue 2: 344-348 (February 2025)

Age Related Histoarchitectural Studies on the Adrenal Gland of Goat (*Capra hircus*)

Vishnudeo Kumar[1], Anil Sharma[1], Tapas K. Patbandha[2]

10.18805/IJAR.B-4953

ABSTRACT

Background: Adrenal gland is an important endocrine gland that secrets several hormones that play a key role in the adaptation of the newborn to extra uterine life. The study was conducted to explore the histomorphological development of adrenal glands in Gohilwadi Goat (*Capra hircus)*.

Methods: The research work was carried out on twenty pair of goat adrenal gland collected from local abattoir. The animals were divided into three age groups, *viz*. group- I (day old to 1 month), group- II (>1 month to 6 months) and group- III (>6 months).

Result: Histological observations revealed that the gland was fully differentiated into cortex and medulla, completely surrounded by a dense fibrous capsule in the day old goats. In group- I, adrenal cortex was made up of definite and foetal cortex, whereas former one comprised of zona glomerulosa and zona fasciculata only. Small to elongate foetal cortical cells were characterized by eosinophilic cytoplasm and arranged into irregular cords. In group II, the foetal cortex disappeared and only definite cortex was present with well-developed three zones *i.e*. Zona glomerulosa, Zona fasciculata and Zona reticularis. Zona glomerulosa was the smallest of the three cortical zones and thickness increased from group-I to group-III. The zona fasciculata was the largest among the three cortical zones in all the age groups and thickness increased from group-I to group-III. Zona reticularis was well organized in the adrenal gland of adult Gohilwadi goat. Medulla occupied greater proportion of the gland and inner medullary cells were the main cellular constituent of medulla. Thickness of medulla increased from group-I to group-III.

Key words: Adrenal, Gohilwadi Goat, Histoarchitectural.

INTRODUCTION

Gohilwadi breed is considered as triple purpose breed (*i.e.* milk, meat and fiber) and reared by the traditional livestock keepers like Rabari and Bharwar communities of Gujarat. Adult average body weight of Gohilwadi goat varies from 42 to 60 kg in females and males, respectively. The daily milk production of females ranges from 1.0 to 3.5 kg (Verma *et al*., 2007). The growth, development and productivity of the animal depend on the proper functioning of all the organ systems, and particularly endocrine system plays important role. Anatomical location of the adrenal glands are supra renal position (Smith *et al*., 1998). The adrenal gland has two distinct portions *i.e.* an outer cortex, which is of mesodermal origin and an inner medulla, which develops from neuroectoderm (Eurell and Frappier, 2006). Hormones like mineralocorticoids, glucocorticoids and sex steroids are secreted from adrenal cortex. The adrenal medulla secrets adrenaline and nor-adrenaline which play a key role in the adaptation of the newborn to extra uterine life. The architecture of the gland also depends on age and sex of the animals (Paul *et al*., 2016). Although this gland plays important role during stress and unfavorable environment, very few studies conducted on indigenous goats particularly Gohilwadi goat. Therefore, the present study was designed to see the age related changes in adrenal gland of Gohilwadi goats.

[1]Department of Veterinary Anatomy, College of Veterinary Science and Animal Husbandry, Kamdhenu University, Junagadh-362 001, Gujarat, India.

[2]Polytechnic in Animal Husbandry, College of Veterinary Science and Animal Husbandry, Kamdhenu University, Junagadh-362 001, Gujarat, India.

Corresponding Author: Vishnudeo Kumar, Department of Veterinary Anatomy, College of Veterinary Science and Animal Husbandry, Kamdhenu University, Junagadh-362 001, Gujarat, India. Email: drvishnudeo@gmail.com

How to cite this article: Kumar, V., Sharma, A. and Patbandha, T.K. (2025). Age Related Histoarchitectural Studies on the Adrenal Gland of Goat (*Capra hircus*). Indian Journal of Animal Research. 59(2): 344-348. doi: 10.18805/IJAR.B-4953.

Submitted: 09-06-2022 **Accepted:** 09-02-2023 **Online:** 20-06-2023

MATERIALS AND METHODS

The study was conducted on both left and right adrenal glands of 20 goats of different age groups at Department of Veterinary Anatomy, College of Veterinary Science and Animal Husbandry, Junagadh, Gujarat during 2015 and 2016. On the basis of age the goats were divided into three groups; group- I (day old to 1 month), group- II (>1 month to 6 months) and group- III (>6 months). The adrenal glands were collected aseptically from local abattoir soon after slaughter of the animals. Immediately after gross

observations the glands were fixed in 10% neutral buffered formalin (NBF). The tissue samples were processed by standard protocol (Prophet *et al.,* 1992) and paraffin blocks were prepared. Tissue sections of 5-6 micrometer thickness were obtained on glass slide with the help of rotatory microtome. The sections were stained with Hematoxylin and Eosin, Masson's trichrome, Gridley's silver impregnation method and Verhoeff's stains (Prophet *et al.,* 1992). The stained paraffin sections were analyzed using an optical microscope (Zeiss Primo Star) attached with a microscopic camera (Zeiss Axiocam ERC 5s) and captured with the help of Carl Zeiss Zen 2 (Blue edition) software. The micrometrical data were compiled and analyzed statistically (Snedecor and Cochran, 1994).

RESULTS AND DISCUSSION

Adrenal gland was differentiated into cortex and medulla in the day old Gohilwadi goat which was surrounded by a thick fibrous capsule (Fig 1). The adrenal capsule composed of thick layer of collagen, reticular and few elastic fibers. The elastic fibers were mainly confined to blood vessels situated in capsular area. The connective tissue trabeculae made up of collagenous and reticular fibers arose from the inner aspect of capsule and infiltrate the cortical parenchyma of the gland (Fig 2, 3). Similar findings were observed by Paul *et al.* (2016) and Kale *et al.* (2003) in goat and Kumar and Sharma (2019) in pig. The capsule contained many undifferentiated cells which were arranged in the form of follicles. The average thickness of capsule was 29.63±1.64 micrometer in group-I, 39.56±3.06 micrometer in group-II and 45.27±2.04 micrometer in group-III (Table 1). The increase in thickness of capsule was significant ($P<0.05$) from group-I to group-II, while it was non-significant between group-II and III. Increase in capsule thickness with progression of age was mainly due to increase in the connective tissue fibers. Whereas, Al-Zubaidi and Nasif (2020) observed the average thickness of capsule was 4.75±0.32, 6.12±0.42, 7.50±0.64, 10.50±0.66, 8.50±0.70 micrometer, respectively in day 1, 1 month, 2 month, 6 months and 2 years of age in Awassi sheep. In buffalo, Kumar *et al.* (2009) recorded the average thickness of capsule 230.66±33.45 micrometer in day 1 to 3 month of age, 240.13±9.04 micrometer in >3 month to 6 month of age and 243.54±6.22 micrometer in >6 month to 1 year of age.

The formation of different zones of adrenal cortex of goat was observed from day old goat. The adrenal cortex of day old goat was divisible into definite and fetal cortex. In early stage of development of group-I the definite cortex only comprised zona glomerulosa. Further differentiation was taken place and in the later stage of development of group- I the zona fasciculata was also formed between zona glomerulosa and fetal cortex. In group-II the fetal cortex was completely disappeared and all the three zones of adrenal cortex was observed. The development of different zones of adrenal cortex was well explained by Mitani *et al.* (1999), they observed that in the rats, formation of adrenal zones

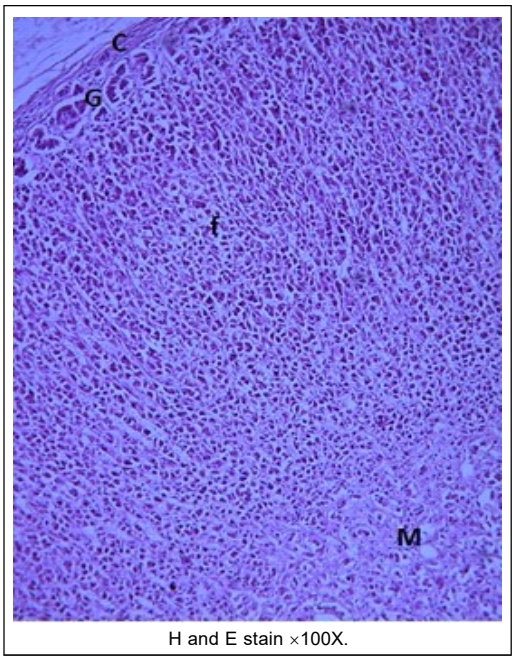

H and E stain ×100X.

Fig 1: Adrenal gland showing fibrous capsule (C), zona glomerulosa (G) foetal cortex (f) and Medulla (M) in day old kids.

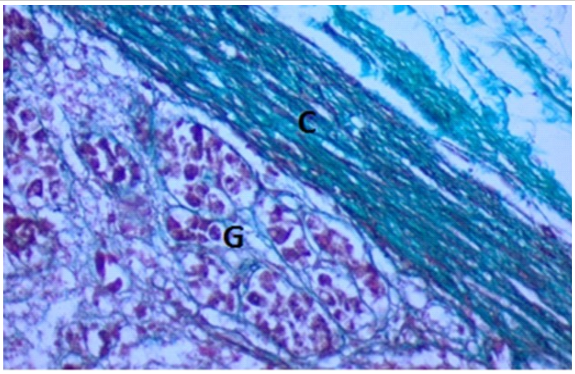

Masson's trichrome stain × 400X.

Fig 2: Adrenal gland showing collagen fibers in capsule (C), zona glomerulosa (G), in 5 months old goat.

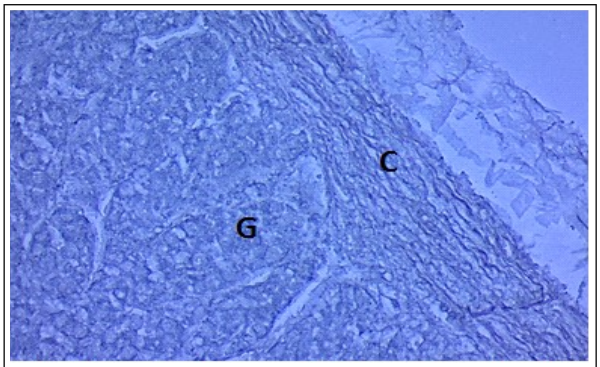

Gridley's stain × 400X.

Fig 3: Adrenal gland showing reticular fibers in capsule (C), zona glomerulosa (G), in adult goat.

started near the time of birth and the zonation was maintained by stem cells, localized between zona glomerulosa and zona faciculata. Nwaogu *et al.* (2009) reported that in Kano brown goats, the area of definite cortex increased while fetal cortex decreased with the advancement of age.

The adrenal cortex of day old goat comprised definite and fetal cortex. The definite zone was comprised of zona glomerulosa, observed in the sub-capsular area and consisted of darkly stained basophilic cells with irregular nuclei and large number of sinusoidal capillaries (Fig 1). Similar findings were reported by Nwaogu *et al.* (2009) in fetal goat, Kumar and Sharma (2013) in day old foal and Kumar *et al.* (2009) in buffalo. In the present study the cellular mass in this zone was arranged in clusters of columnar cells and had spherical or oval nuclei surrounded by a homogenous cytoplasm in all three groups (Fig 2, 3). Thickness of zona glomerulosa was 39.72±2.50 micrometer in group-I, 87.15±5.81 micrometer in group-II and 109.11±4.28 micrometer in group-III. Increases in thickness of zona glomerulosa from group-I to group-II are statistically significant (P<0.05). In contrast to present study, Al-Zubaidi and Nasif (2020) observed that in Awassi sheep the average thickness of zona glomerulosa was 10.55±0.62, 11.60±0.3, 12.73±0.69, 16.82±0.85 and 14.55±0.25 micrometer respectively in day 1, 1 month, 2 month, 6 months and 2 years of age. In buffalo, the average thickness of zona glomerulosa was 177.42±21.14 micrometer in day 1 to 3 month of age, 202.75±11.78 micrometer in >3 month to 6 month of age and 252.73±11.51 micrometer in >6 month to 1 year of age (Kumar *et al.,* 2009).

Fetal cortex was made up of small to elongated fetal cortical cells which were having eosinophilic cytoplasm and were arranged into irregular cords. These cells were intermingled with medullary cells at cortico-medullary junction. With progression of age the fetal cortical cells were pushed towards the center of the gland, became closely packed and were moderately vacuolated (Fig 1). Similar observations were reported in day old buffalo calf by Kumar *et al.* (2010a). Fetal cortex was not observed in group-II and group-III, however the remnant of fetal cortex was observed in the group-II. The average thickness of fetal cortex in group-I was 276.93±15.79 micrometer. However, the average thickness of fetal cortex was recorded as 353.45±46.88 micrometer in buffalo during day 1 to 3 months of age (Kumar *et al*., 2009).

The zona fasciculata was interposed between the zona glomerulosa and fetal cortex in the later stage of development in group-I. In group-II and group-III this zone was located between zona glomerulosa and zona reticularis. Cells of this zone were arranged in single or double cords and were larger in size. Zona fasciculata was more organized with the progression of age and contained cells with foamy cytoplasm. Zona fasciculata was the widest zone amongst all the cortical zones. Thickness of this zone was 106.26±5.48 micrometer, 597.43±28.04 micrometer and 687.16±24.38 micrometer in group-I, group-II and group-III respectively. The average thickness of zona fasciculata increased from group-I to group- III. Similar pattern of increase in thickness of this zone was observed by Kale *et al.* (2003) in goat, Al-Zubaidi and Nasif (2020) in Awassi sheep and Kumar *et al.* (2009) in buffalo. In the present study statistical analysis showed that this increase in thickness of zona fasciculata was significant (P<0.05) from group-I to group-II; while non-significant from group-II to group-III.

The zona reticularis was observed from group-II, below the zona fasciculata. Hakeem *et al.* (1993) reported this zone first time in adrenal gland at the age of six month in goat. Cells of this zone were smaller than the cells of zona fasciculata. These cells were having little cytoplasm with pyknotic and heterochromatic nuclei. Zona reticularis was the innermost zone of the cortical parenchyma of the adrenal gland. Thickness of this zone was 252.74±14.37 micrometer in group-II and 358.93±26.40 micrometer in group-III. This increase in thickness of zona reticularis was significant (P<0.05). However, Kumar *et al.* (2009) reported presence of zona reticularis in group-I (day 1 to 3 month of age). They also recorded the average thickness of zona reticularis as 141.23±23.40 micrometer in day 1 to 3 month of age,

Table 1: Micrometrical data showing Mean and standard error (in micrometer) of various parameters of adrenal gland in different age groups of Gohilwadi goat.

Structure	Thickness (Mean±SE) in micrometer		
	Group-I	Group-II	Group-III
Capsule	29.63^{a}±1.64	41.56^{b}±3.06	45.27^{b}± 2.04
Fetal cortex	276.93 ±15.79	-	-
Zona glomerulosa	39.72^{a}±2.50	87.15^{b}±5.81	109.11^{b}±4.28
Zona fasciculata	106.26^{a}±5.48	597.43^{b}±28.04	687.16^{b}±24.38
Zona reticularis	-	252.74^{a}±14.37	358.93^{b}±26.40
Total cortex	434.07^{a}±20.01	966.19^{a}±43.22	1121.20^{b}±21.58
Outer medullary zone	191.34^{a}±17.02	254.80^{ab}±35.24	335.37^{b}±20.48
Inner medullary zone	224.33^{a}±19.27	429.11^{b}±42.64	345.26^{b}±18.37
Total medulla	626.71^{a}±63.04	1053.11^{a}±85.97	1242.92^{b}±36.46

Means with different superscripts (a, b) in a row differed significantly (P<0.05).

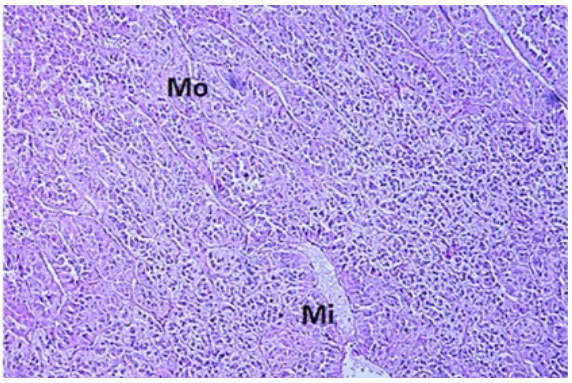

H and E stain × 100X.

Fig 4: Adrenal gland showing outer (Mo) and inner (Mi) zone of medulla in adult goat.

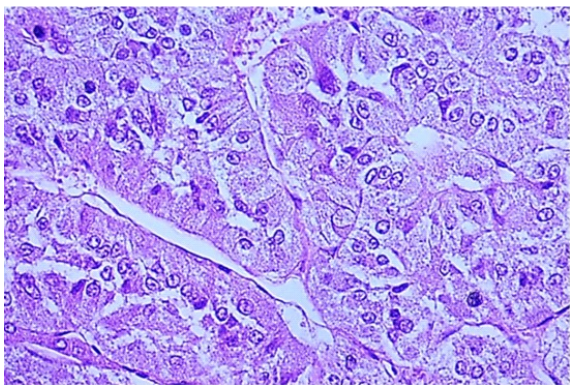

H and E stain × 400X.

Fig 5: Adrenal gland showing outer zone medulla under higher magnification in adult goat.

329.95±17.30 micrometer in >3 month to 6 month of age and 393.14±34.17 micrometer in >6 month to 1 year of age.

There was no distinct line of demarcation between cortex and medulla. The bulk of the adrenal cortex was formed by zona fasciculata and zona reticularis however, the cortical parenchyma constituted a lesser proportion of the gland than the medulla. Similar findings were observed by Kumar and Sharma (2013) in day old foal. Adrenal medulla formed greater part of the adrenal gland and occupied central portion of the gland. Medullary cells situated at the periphery of medulla were larger, arranged in follicular form and forming the outer zone. Similar pattern for outer medullary cell were observed in the adrenal gland of adult Bakerwali goat by Kour *et al.* (2017) and in Buffalo by Sethi and Roy (2007). While cells found in the center of the gland were smaller, compactly arranged and forming inner zone (Fig 4). Outer cells were having homogenous cytoplasm with spherical to round nucleus located more towards apical portion (Fig 5) whereas the inner cells had a less homogenous cytoplasm with a centrally placed nuclei. With progression of age the outer and inner zone of medulla were more clearly differentiated. Similar to present findings, Kumar (2007) reported outer and inner zones in medulla during postnatal development of buffalo adrenal and stated that the cells of the outer zone of medulla were adrenaline secreting and the inner zone cells were nor-adrenaline secreting.

Average thickness of adrenal medulla was 626.71±63.04 micrometer in group-I, 1053.11±85.97 micrometer in group-II and 1242.92±36.46 micrometer in group-III. Thickness increased significantly ($P<0.05$) from group-II to group-III. The proportion of inner medullar zone was more than the outer medullary zone in all the age groups (Table 1). The cortico-medullary ratio decreased from 1:1.44 in group-I to 1:1.10 in group- III which may be due to rapid cortical growth. Kumar *et al.* (2010b) recorded the average thickness of medulla as 1765.97±79.86 micrometer in day 1 to 3 month of age, 1833.40±342.18 micrometer in >3 month to 6 month of age and 1998.73±103.45 micrometer in >6 month to 1 year of age and they also observed decreased cortico-medullary ratio from group-I to group-III.

Conclusion

Adrenal gland of day old goat was fully differentiated into cortex and medulla and completely encapsulated by a fibrous capsule. Adrenal cortex was made up of definite and fetal cortex in day old goat. Definite cortex was represented by zona glomerulosa only. The zona glomerulosa was the smallest of the three cortical zones and consisted of columnar cells having homogeneous cytoplasm with spherical or oval nuclei and cells were arranged in clusters. Zona fasciculata was interposed between zona glomerulosa and fetal cortex in the later stage of development in group-I. Cells at this zone were comparatively larger in size. The zona reticularis was observed from group- II, below the zona fasciculate. Cells of this zone were small in size with little cytoplasm and pyknotic and heterochromatic nuclei. Zona reticularis was well organized in the adrenal gland of adult goat. Medulla occupied greater proportion of the gland and inner medullary cells were the main cellular constituent of medulla.

Conflict of interest

All authors declare that they have no conflict of interest.

References

Al-Zubaidi, K.A. and Nasif, S.M. (2020). Histological and histomorphometrical postnatal developmental study of adrenal gland in Awassi sheep (*Ovis aris*). Plant Archives. 20(1): 1602-1606.

Eurell, J.A. and Frappier, B.L. (2006). Textbook of Veterinary Histology 6th edn. Blackwell Publishing, Iowa, USA. pp. 256-277.

Hakeem, N.A., Sulochana, S., Sharma, G.P. and Murthy, C.T. (1993) Histological studies on the adrenal grand of the common Indian goat. Indian Journal of Veterinary Anatomy. 5(1-2): 66-77.

Kale, M.A., Bhamburkar, V.R., Banubakode, S.B., Nandeshwar, N.C. and Dalvi, R.S. (2003). Histomorphology of adrenal cortex of goat. Indian Journal of Veterinary Anatomy. 15(1-2): 13-17.

Kour, G., Suri, S. and Sarma, K. (2017). Histology and histochemistry of the adrenal medulla in adult Bakerwali goat. Journal of Animal Research. 7(6): 1111-1114

Kumar, V. and Sharma, A. (2013). Histomorphological observations on the adrenal gland of day old foal. The Indian Journal of Veterinary Science. 1(2): 39-42.

Kumar, V. (2007). Histomorphochemical study on the adrenal gland of neonatal buffalo calves, M.V.Sc thesis. GADVAS Univ., Ludhiana, India.

Kumar, V. and Sharma, A. (2019). Gross and histological observations on adrenal gland of pig. Indian Journal of Veterinary Anatomy. 31(2): 117-118.

Kumar, V., Sethi, R.S. and Singh, O. (2009). Micrometrical study on adrenal cortex during postnatal development in buffalo. Indian Veterinary Journal. 86(2): 186-188.

Kumar, V., Sethi, R.S. and Singh, O. (2010a). Foetal cortical cells during postnatal remodeling of adrenal gland in buffalo. Indian Veterinary Journal. 87(4): 380-382.

Kumar, V., Sethi, R.S. and Singh, O. (2010b). Micrometrical study on adrenal medulla during postnatal development in buffalo. Indian Journal of Veterinary Anatomy. 22(1): 18-20.

Mitani, F., Mukai, K., Miyamoto, H., Suematsu, M. and Ishimura, Y. (1999). Development of functional zonation in the rat adrenal cortex. Endocrinology. 140(7): 3342-3353.

Nwaogu, I.C. and Francis, B. (2009). Morphological features of fetal and adult adrenal glands in Kano brown goats (*Capra hircus*). Animal Research International. 6(1): 953-957.

Paul, B., Sarkar, S., Islam, M.N. and Das, R. (2016). Morphological and histological investigations on the adrenal glands in black Bengal Goat (*Capra hircus*). Journal of the Sylhet Agricultural University. 3(2): 181-187.

Prophet, E.B., Mills, B., Arrington, J.B. and Sobin, L.H. (1992). Armed Forces Institute of Pathology, Laboratory Methods in Histotechnology. 1st eds., Amer Registry of Pathology, Washington D.C., USA.

Sethi, R.S. and Roy, K.S. (2007). Cytodifferentiation of medullary cells in adrenal gland in adrenal gland during prenatal development in buffalo (*Bubalus bubalis*). Indian Journal of Animal Science. 77(6): 452-454.

Smith, R., Mesiano, S., Chan, E., Brown, S. and Jaffe, R.B. (1998). Corticotrophin releasing hormone directly and preferentially stimulates dehydroepiandrosterone sulphate secretion by human fetal adrenal cortical cells. The Journal of Clinical Endocrinology and Metabolism. 83: 2910-2920.

Snedecor, G.W. and Cochran, W.G. (1994). Statistical Methods. 9th eds. Iowa State University Press, Ames.

Verma, N.K., Aggarwal, R.A.K., Dangi, P.S., Dixit, S.P., Sharma, R., Ahlawat, S.P.S. and Singh, G. (2007). Goat genetic resources of India - Gohilwadi - A multipurpose goat of Gujarat. Research Monograph 60, National Bureau of Animal Genetic Resources, Karnal, Haryana. p. 27.