RESEARCH ARTICLE Indian Journal of Animal Research, Volume 57 Issue 2: 190-195 (February 2023)

Ultrasonographic Morphometry of Reticulum in Cattle and Buffaloes

T.P. Patel[1], D.B. Patil[1], G.R. Chaudhary[1], C.M. Bhadesiya[1]

10.18805/IJAR.B-4987

ABSTRACT

Background: Tremendous achievements have been made in diagnostic and therapeutic aspects of digestive tract affections of bovines throughout the world, wherein clinical traumatic reticuloperitonitis (TRP) is the most commonly reported and studied condition in bovines. TRP is accidental ingestion of foreign body (metallic or non-metallic; penetrating or non-penetrating) objects, which generally get lodged or penetrate the reticulum. The reticulum plays a crucial role in the motility of the digestive tract in bovines and so several invasive and noninvasive methods are used for reticular examination. Hence, the ultrasonographic evaluation of reticular morphometric parameters is the need of the hour.

Methods: The present study was undertaken to evaluate ultrasonographic morphometry of reticulum in bovines (Group I, six clinically healthy cattle and Group II, six clinically healthy buffaloes) at the Postgraduate Institute of Veterinary Education and Research, Kamdhenu University, Rajpur (Nava), Himmatnagar, Gujarat. For ultrasonography, using Esaote MyLabDelta Veterinary Ultrasound System with convex transducer (3-5 MHz), a standing left post-xiphoid paramedian approach was adopted. The morphometric parameters *viz.* half-moon-shaped reticular wall (RW), RW thickness, RW distance from the parietal peritoneum and the roughly triangular area between RW, cranio-ventral rumen sac and diaphragm were evaluated.

Result: The mean RW thickness (Buffalo-5.33±0.58 mm; Cattle-4.53±0.33 mm), mean distance of the closest point of the RW from the peritoneum (25.77±3.23 mm; 13.07±0.67 mm) and mean triangular area (10.21±4.42 cm²; 4.94±0.52 cm²) were higher in healthy buffaloes than cattle.

Key words: Buffaloes, Cattle, Morphometry, Reticulum, Ultrasonographic.

INTRODUCTION

The large livestock ruminants such as cattle and buffaloes contribute significantly to the national economy in terms of annual milk production which is increasing every year. Various systemic and infectious diseases affect milk production in bovines ultimately affecting the economic status of rural livestock owners and the country (Khalphallah *et al.,* 2016). One of the most common systemic disorders of bovines includes digestive disorders such as ruminal impaction, indigestion, bloat, traumatic reticuloperitonitis (TRP) or foreign body syndrome (FBS), simple indigestion, vagal indigestion, acidosis *etc*. Besides TRP, there are several other clinical disorders such as reticular abscess (RA), diaphragmatic hernia (DH), local and diffuse peritonitis, traumatic reticulitis (TR), traumatic pericarditis (TP; especially when penetrating foreign body migrates from reticulum to thorax affecting pericardium) *etc*. are considered as reticular and peri-reticular affections of bovines. All these conditions are economically important, generally take prolonged period of time and are often brought to Veterinary Hospitals when severity is high requiring surgical intervention. Therefore, existing status or morphometric changes of reticulum often go unnoticed because of lack in early diagnostic facilities and are only observed during surgical management. Thus, the reticulum is an important organ to evaluate for proper and early diagnosis of forestomach disorders of ruminants.

[1]Postgraduate Institute of Veterinary Education and Research, Kamdhenu University, Rajpur (Nava), Himatnagar-383 001, Gujarat, India.

Corresponding Author: T.P. Patel, Postgraduate Institute of Veterinary Education and Research, Kamdhenu University, Rajpur (Nava), Himatnagar-383 001, Gujarat, India.
Email: tppatel85@gmail.com

How to cite this article: Patel, T.P., Patil, D.B., Chaudhary, G.R. and Bhadesiya, C.M. (2023). Ultrasonographic Morphometry of Reticulum in Cattle and Buffaloes. Indian Journal of Animal Research. 57(2): 190-195. doi: 10.18805/IJAR.B-4987.

Submitted: 15-07-2022 **Accepted:** 30-11-2022 **Online:** 07-12-2022

Out of all digestive disorders, reticular or peri-reticular affections are studied extensively; however, reports of radiographic or ultrasonographic anatomy of clinically healthy bovines and bovines affected with reticular or peri-reticular affections are sparse. Moreover, most of the scientific reports pertaining to ultrasonographic evaluation of reticulum are available from animals having reticular or peri-reticular affections only. Additionally, there is lack in availability of standardized data on ultrasonographic morphometry of reticulum in bovines in India. Hence, the reticular morphometric parameters need to evaluate and standardize ultrasonographically. The present study was planned with the objective of morphometric evaluation of the reticulum in clinically healthy cattle and buffaloes.

MATERIALS AND METHODS

The present study was designed to evaluate normal ultrasonographic evaluation of the reticulum and adjoining organs of clinically healthy animals at Veterinary Hospital (VH) functional under the Postgraduate Institute of Veterinary Education and Research (PGIVER), Kamdhenu University (KU), Rajpur (Nava), Himatnagar-383010, District: Sabarkantha, Gujarat. The animals were allotted to two major groups (Group I, six clinically healthy cattle and Group II, six clinically healthy buffaloes) and subjected to USG studies, where clinically healthy buffaloes reared at Instructional Livestock Farm Complex (ILFC), KU, Rajpur (Nava), Himatnagar-383010 and clinical cases of crossbred cattle other than digestive disorders presented at VH, Himatnagar were included in the study.

Ultrasonographic examination was carried out in non-sedated animals (Groups I and II) in a standing position using Esaote MyLabDelta Vet Ultrasound System as per the method described by Braun and Gotz (1994). The reticulum was examined with 3.5 MHz convex transducer parallel to the ribs on both sides of the sternum as well as at the left and right lateral thorax over the sixth and seventh intercoastal space up to the level of elbow (Braun and Gotz, 1994; Kaske *et al.,* 1994) and were also examined from the left side, midline and then from the right side, respectively as described by Braun (2009).

The morphometric parameters *viz*. half-moon-shaped reticular wall (RW), RW thickness (in mm), RW distance from the parietal peritoneum (in mm) and the roughly triangular area between RW, cranio-ventral rumen sac and diaphragm (in cm^2) were evaluated. The data collected from the study was analyzed using SPSS and interpreted in Mean±SE values.

RESULTS AND DISCUSSION

All the animals were shaved on left, right and ventral abdominal regions between 5th to 8th ICS and the area was cleaned with water and applied coupling gel over the region. The reticulum scanning procedure started with 3.5 MHz convex transducer from the left and right ICS and post-xiphoid paramedian site in between 6th to 8th ICS up to the level of elbow in a chronological manner as per the method described by Braun and Gotz (1994); Kaske *et al.* (1994) and Braun (2009). The optimum results were obtained from the post-xiphoid paramedian approach and it was carried out throughout the ultrasonographic examinations to evaluate the reticulum and its adjoining organs on either side. The results revealed that the broader ICS approach in cattle proved satisfactorily, while narrower ICS in buffaloes proved an unsatisfactory scanning procedure to evaluate the reticular wall, its contractions and adjoining structures like diaphragm, musculophrenic veins, rumen wall, spleen, liver, peritoneum and abdominal wall. The results were concurrent with the findings of Abouelnasr *et al*. (2014) in buffaloes and Braun and Gotz (1994) in cattle.

Cattle

The normal reticulum was examined using USG and evaluated different parameters like reticular wall (RW) thickness, contour, motility, reticular wall distance from the peritoneum and area between reticulum, rumen and diaphragm in six healthy cattle (Fig 1 to 4) randomly selected from the privately-owned farm at Rajpur village and the results were shown in Table 1. In order to reduce the chances of error, the reticular wall thickness was measured by placing the probe at left post-xiphoid paramedian site and measuring the thickness at two different points/locations of reticular wall in a sonogram (D1 and D2). The reticular wall is half-moon-shaped with an irregular contour structure (hyperechoic line) easily accessible from the left side at post-xiphoid paramedian approach in all the cattle. Most of the cattle showed biphasic reticular contractions observed at one-minute interval, where the first contraction was incomplete and the second contraction was complete in nature.

The reticular wall thickness was measured from two different places and the mean diameter of the reticular wall thickness was 4.53±0.33 mm in six cattle. The average distance of the highest point of the reticular wall from the

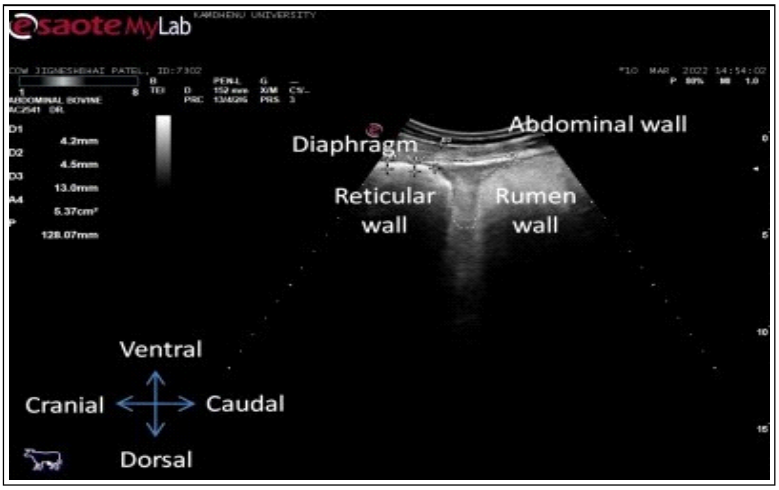

Fig 1: Ultrasonogram from left post-xiphoid paramedian window in cow-1.

peritoneum (D3) was 13.07±0.67 mm. The probe was placed in longitudinal straight direction without any angulations on both sides and the area between the reticular wall, rumen wall and diaphragm was measured with the mean area (D4) of 4.94±0.52 cm². Though the parameter was observed for the first time in normal six cattle only, hence needs to be validated in larger normal and clinical settings.

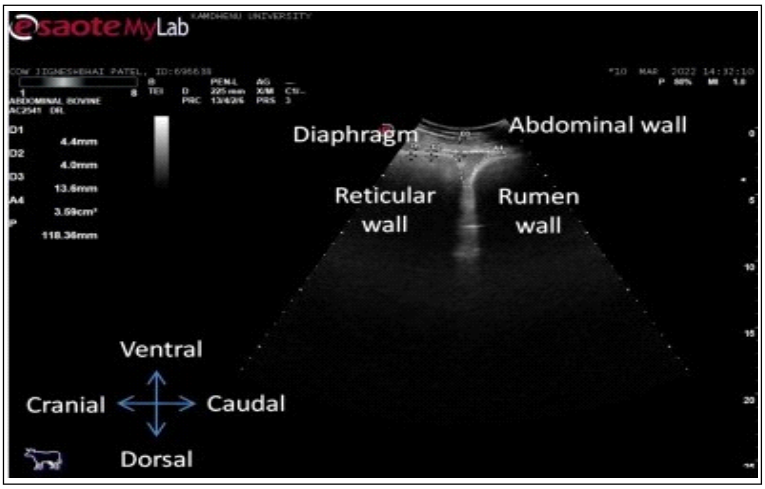

Fig 2: Ultrasonogram from left post-xiphoid paramedian window in cow-2.

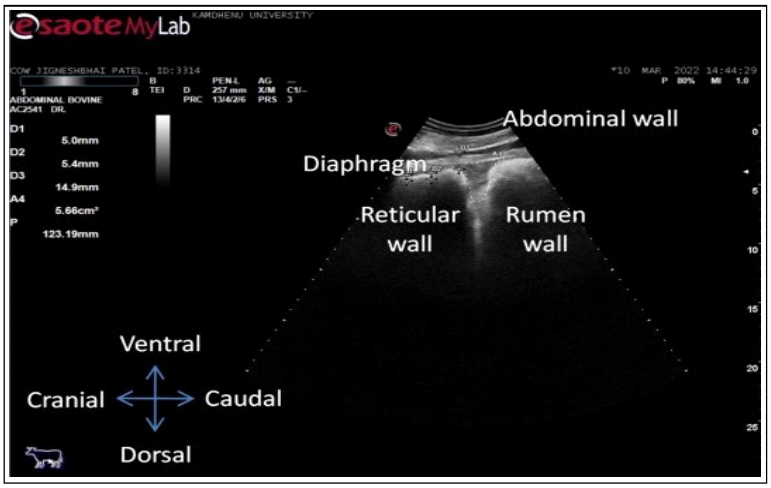

Fig 3: Ultrasonogram from left post-xiphoid paramedian window in cow-3.

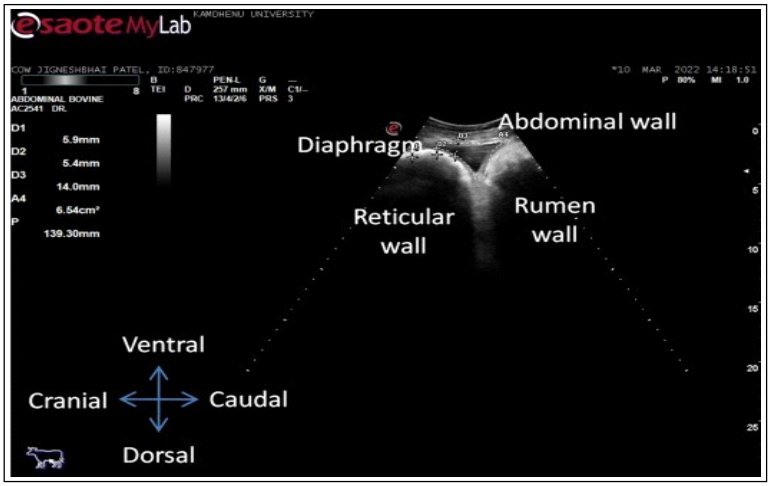

Fig 4: Ultrasonogram from left post-xiphoid paramedian window in cow-4.

Buffaloes

The normal reticulum was examined for USG and evaluated different parameters like reticular wall (RW) thickness, contour, motility, reticular wall distance from the peritoneum and area between reticulum, rumen and diaphragm in six healthy buffaloes (Fig 5 to 8) randomly selected from the ILFC, KU, Rajpur (Nava), Himmatnagar. The results were shown in Table 2.

In order to reduce the chances of error, the reticular wall thickness was measured by placing the probe at left post-xiphoid paramedian site and measuring the thickness at two different points/locations of reticular wall in a sonogram (D1 and D2). The reticular wall was smooth in contour and half moon shaped structure (hyper echoic line) easily assessable from the left side at post-xiphoid paramedian approach in all the buffaloes. The biphasic

Table 1: Ultrasonographic morphometry of normal reticulum in cattle (n=6).

Animal	Thickness of reticular wall (RW) (mm)			Distance of RW from peritoneum (mm)	Area between RW, rumen wall and diaphragm (cm²)
	D1	D2	D (Average)	D3	D4
847977	3.50	3.10	3.30	10.10	3.26
847938	5.90	5.40	5.65	14.00	6.54
696638	4.40	4.00	4.20	13.60	3.59
7302	4.20	4.50	4.35	13.00	5.37
3314	5.00	5.40	5.20	14.90	5.66
6040	4.70	4.30	4.50	12.80	5.20
Mean±SE		4.53±0.33		13.07±0.67	4.94±0.52

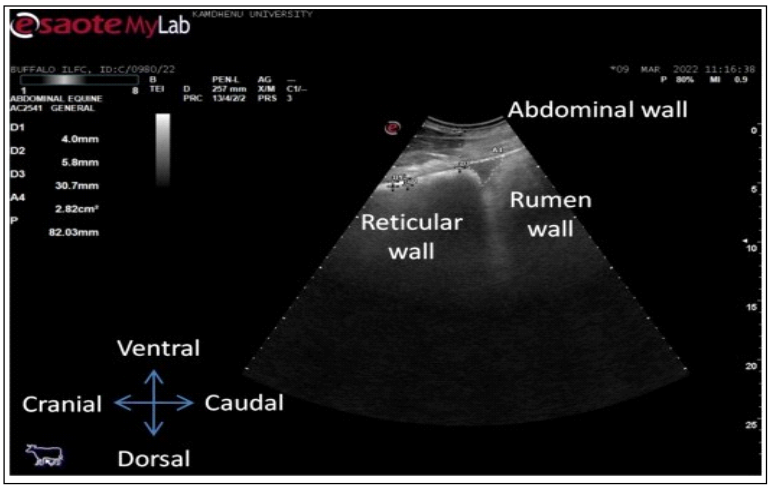

Fig 5: Ultrasonogram from left post-xiphoid paramedian window in buffalo-1.

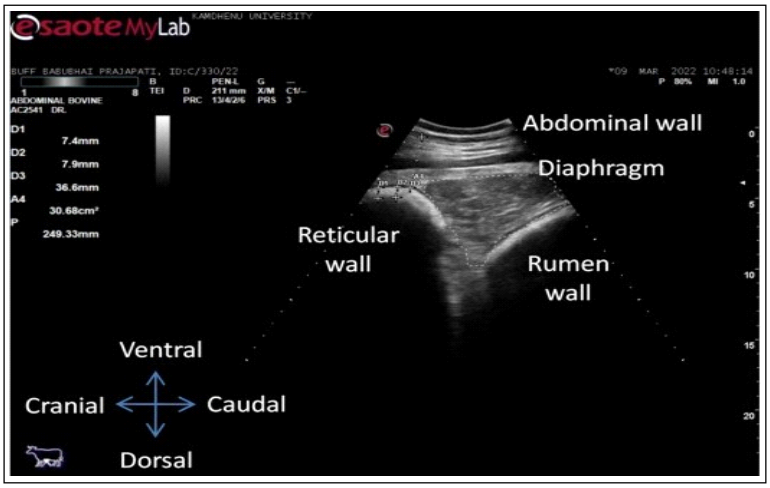

Fig 6: Ultrasonogram from left post-xiphoid paramedian window in buffalo-2.

reticular contractions were observed in all the buffaloes except one, where a triphasic contraction was observed.

The reticular wall thickness was measured from two different places and the mean diameter of the reticular wall thickness (D) was 5.33±0.58 mm in six buffaloes. The average distance of the highest point of the reticular wall from the peritoneum (D3) was 25.77±3.23 mm. The probe was placed in longitudinal straight direction without any angulations on both the sides and the area between the reticular wall, rumen wall and diaphragm was measured. The mean area (D4) between the reticular wall, rumen and the diaphragm was 10.21±4.42; where the area ranged from 2.71 to 6.10 cm² in four buffaloes and 13.81 to 30.68 cm² in two buffaloes. This wide variation might be due to the angulations between the probe and both sides of the ventral abdominal wall at the time of scanning procedure and the movement of animals.

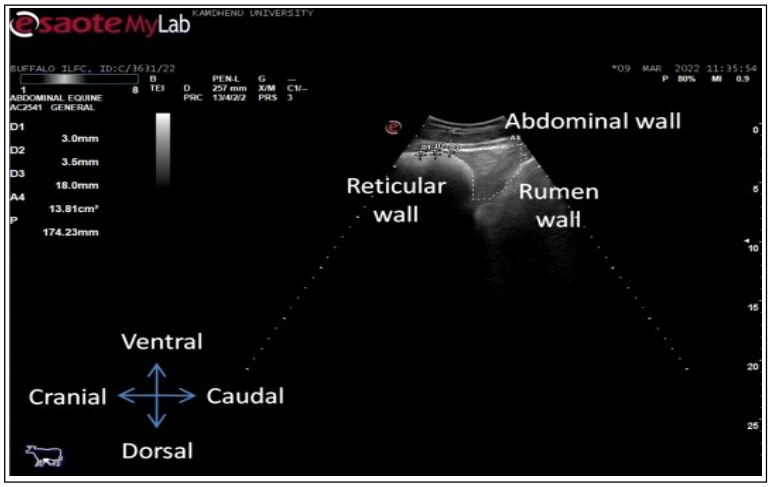

Fig 7: Ultrasonogram from left post-xiphoid paramedian window in buffalo-3.

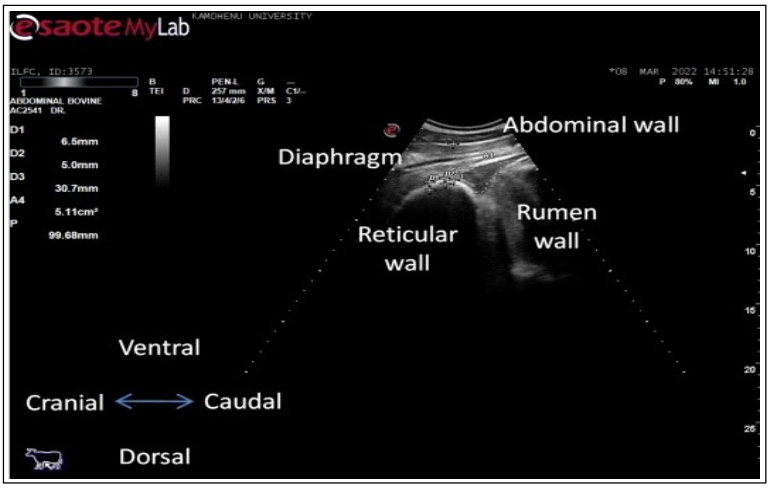

Fig 8: Ultrasonogram from left post-xiphoid paramedian window in buffalo-4.

Table 2: Ultrasonographic morphometry of normal reticulum in buffaloes (n=6).

Animal	Thickness of reticular wall (RW) (mm)			Distance of RW from peritoneum (mm)	Area between RW, rumen wall and diaphragm (cm²)
	D1	D2	D (Average)	D3	D4
C/330/22	7.40	7.90	7.65	36.60	30.68
0980	4.00	5.80	4.90	30.70	2.82
3631	3.00	3.50	3.25	18.00	13.81
3573	6.50	5.00	5.75	30.70	5.11
3774	5.00	5.40	5.20	20.40	6.10
3904	5.40	5.00	5.20	18.20	2.71
Mean±SE		5.33±0.58		25.77±3.23	10.21±4.42

Makhdoomi *et al*. (2019) evaluated smooth reticular wall in 66.66% cattle and 57.14% of buffaloes and concluded that it was better to examine the reticulum from the left ventral window. Braun *et al.* (2018) also examined the reticulum ultrasonographically from the ventral aspect of the thorax on both the sides of sternum in cattle. Abouelnasr *et al.* (2014) also evaluated the reticulum using USG from the left ventral thoracic area at the level of 6th to 7th ICS in all the buffaloes, while the reticulum could not be seen in 11 animals from the ventral mid line and in 3 animals from the right side. Hence, concluded that the left lateral window proves better to evaluate the reticular thickness in normal as well as FBS affected cattle and buffaloes.

Braun *et al.* (2018) also found the biphasic type of contractions in 416 (76%) cattle and triphasic contractions in 14 (3%) cattle only. Abouelnasr *et al.* (2014) concluded that the reticular contractions were biphasic in majority of buffaloes, while the triphasic contractions were found in four buffaloes only. The evaluation of reticular contractions in the present study was also concurrent with the observations of Braun and Gotz, (1994); Kaske *et al*., (1994); Braun, (2009); Braun *et al*. (2018a) and Abouelnasr *et al*., (2014). Most workers stated that the reticulum was identified by its crescent or half-moon-shaped smooth-contoured structure in both cattle and buffaloes.

Makhdoomi *et al*. (2019) evaluated the morphometry of the reticulum and found that the reticular wall thickness was 0.34 to 0.82 cm and 0.37 to 0.68 cm in cattle (3-8 years of age and 300-510 kg of body weight) and buffaloes (3-7 years of age and 350-500 kg of body weight), respectively. The findings of the reticular wall thickness (0.3 to 0.5 cm and 0.3 to 0.7 cm in cattle and buffaloes, respectively), also correlated with that of Makhdoomi *et al*. (2019) in cattle and buffaloes. Abouelnasr *et al*. (2014) evaluated 1.603±0.21 cm distances between the reticular wall and abdominal wall and it was lower than that of the present study, where it was 2.577±0.32 cm in six buffaloes. This variation might be due to the difference in the age group and breed of the buffaloes. The measured area between the reticular wall, rumen wall and the diaphragm is for the first time in only normal six buffaloes, hence, needs further validation in cattle and buffaloes from the left paramedian window through USG.

CONCLUSION

In toto, left post-xiphoid paramedian ultrasonography is an excellent non-invasive, non-ionizing, cost-effective, rapid animal side modality to evaluate reticular morphometry in bovines. Further, measurement of various morphometric parameters (RW thickness and triangular area) are of good diagnostic value and will be helpful, when compared with the reticular affections.

Conflict of interest: None.

REFERENCES

Abouelnasr, K.S., Mosbah, E.M., Karrouf, G.I., Zaghloul, A.E. (2014). Ultrasonography of normal reticulum in 30 healthy buffalo (*Bubalus bubalis*). Journal of Applied Animal Research. 42(2): 153-159.

Braun, U. (2009). Ultrasonography of the gastrointestinal tract in cattle. Veterinary Clinics of North America - Food Animal Practice. 25(3): 567-590.

Braun, U. and Gotz, M. (1994). Ultrasonography of the reticulum in cows. American Journal of Veterinary Research. 55: 325-332.

Braun, U., Gerspach, C., Warislohner, S., Nuss, K., Ohlerth, S. (2018). Ultrasonographic and radiographic findings in 503 cattle with traumatic reticuloperitonitis. Research in Veterinary Science. 119: 154-161.

Kaske, M., Midasch, A., Rehage, J. (1994). Sonographic investigation of reticular contractions in healthy sheep, cows and goats and in cows with traumatic reticulo-peritonitis. Journal of Veterinary Medicine. 41: 748-756.

Khalphallah, A., Elmeligy, E., Elsayed, H.K., El-Hawari, S.F., Elrashidy, M.H. (2016). Diagnostic significance of ultrasonography in complicated traumatic reticuloperitonitis in Egyptian buffaloes (*Bubalus bubalis*). Asian Journal of Animal and Veterinary Advances. 11(6): 319-330.

Makhdoomi, S.M., Sangwan, V., Kumar, A., Mohindroo, J., Gupta, A. (2019). Ultrasonographic morphometry of reticulum in cattle and buffaloes suffering from traumatic reticulo-peritonitis. Buffalo Bulletin. 38(3): 421-436.

SPSS Inc. for windows, version 16.0 Chicago, 2007.