RESEARCH ARTICLE Indian Journal of Animal Research, Volume 57 Issue 5: 656-661 (May 2023)

Adverse Effects of Oxytetracycline Hydrochloride, Florfenicol, Sulphadimethoxine and Ormetoprim in Tilapia (*Oreochromis niloticus*) at Therapeutic Dose and Maximum Residual Limit (MRL) Level

L. Akshaya[1], G. Sarathchandra[2], S.A. Shanmugam[3], N. Felix[3], V. Kaliyamurthi[3]

10.18805/IJAR.B-5073

ABSTRACT

Background: In Aquaculture sector, antibiotics are commonly used for treating many diseases and to promote fish growth. Since, many antibiotics have been used improperly, their deposition in aquatic environment causes toxic effects in fish. However, studies on the toxicity of antibiotics in fish is very low. This study explains about the adverse/toxic effects of commonly used antibiotics (Oxytetracycline hydrochloride, florfenicol, Sulphadimethoxine and ormetoprim) in fish. Inspite of their positive effects, antibiotics are able to cause damage to metabolic system and organs. Accordingly, there are serious worries about the harmfulness of antibiotics in fish and further exploration and methodologies are expected to forestall them in different regions of the world.

Methods: The study explores whether the presence of antibiotics alter the normal functioning of organs in Tilapia (*Oreochromis niloticus*). Hematology, biochemical parameters and histopathological examination have been carried out to determine the effect of antibiotics.

Result: The present study revealed that the presence of antibiotics elevates toxic and biochemical lesions in Tilapia (*Oreochromis niloticus*). This study will contribute to the updating on the effect of antibiotics on fish.

Key words: Antibiotics, Biochemical, Hematology, Histopathology, Tilapia.

INTRODUCTION

Antibiotics are widely used for preventing and treating bacterial diseases and its efficiency vary in different environmental conditions, like ground water, surface water and residue (Danner *et al*., 2019). Antibiotics are biotically active which repress proteins, cell wall and nucleic acid synthesis as well as DNA replication and cell division. Antibiotics are not totally removed after wastewater sewage treatment and hence low amount of antibiotics make non-target toxic effects to aquatic organisms (Fent *et al*., 2006).

Different types of toxicity tests are performed in animals to detect the toxic levels of various pharmaceutical products. Among those, the most common toxicity tests performed in fish are acute, subacute, subchronic and chronic. In acute toxicity testing fish are exposed to the drug for 96 hours, under any of the conditions like static, semi-static or flow through. Appearance, behaviour and mortalities of the fish are recorded (OECD, 2019). Toxicological parameters such as hematology, serum biochemistry and histopathological examination of tissues will be carried out to assess the toxicity.

The current study aims to investigate the toxicological effects of antibiotics in fish in order to determine their adverse effects at therapeutic dose and maximum residue limit (MRL) level.

[1]Department of Fish Pharmacology and Toxicology, Institute of Fisheries Post Graduate Studies, Tamil Nadu Dr. J. Jayalalithaa Fisheries University, Chennai-603 103, Tamil Nadu, India.
[2]Pharmacovigilance Laboratory for Animal Feed and Food Safety, Tamil Nadu Veterinary and Animal Sciences University, Chennai-600 007, Tamil Nadu, India.
[3]Tamil Nadu Dr. J. Jayalalithaa Fisheries University, Chennai-603 103, Tamil Nadu, India.

Corresponding Author: L. Akshaya, Department of Fish Pharmacology and Toxicology, Institute of Fisheries Post Graduate Studies, Tamil Nadu Dr. J. Jayalalithaa Fisheries University, Chennai-603 103, Tamil Nadu, India. Email: abiaksh2014@gmail.com

How to cite this article: Akshaya, L., Sarathchandra, G., Shanmugam, S.A., Felix, N. and Kaliyamurthi, V. (2023). Adverse Effects of Oxytetracycline Hydrochloride, Florfenicol, Sulphadimethoxine and Ormetoprim in Tilapia *(Oreochromis niloticus)* at Therapeutic Dose and Maximum Residual Limit (MRL) Level. Indian Journal of Animal Research. 57(5): 656-661. doi: 10.18805/IJAR.B-5073.

Submitted: 16-12-2022 **Accepted:** 28-02-2023 **Online:** 14-03-2023

MATERIALS AND METHODS

The study was conducted during the year 2019-2022 at the Pharmacovigilance Laboratory for Animal Feed and Food Safety, TANUVAS, Chennai, Tamil Nadu.

Collection and preparation of sample

The fingerlings of *Oreochromis niloticus* were procured from the Rhea Fish Farm and Incubation facility Unit, Tirupati Street, Bandikavanoor, Tamil Nadu. The experimental fish were acclimatized in the fish trough (20 litre trough) with standard circumstances for 7 days. Every one of the fishes was graded according to their weight preceding the investigation upto the hour of examination. A sum of 150 fingerlings was chosen for the experimental trial.

The fish were exposed to the antibiotics (oxytetracycline hydrochloride, florfenicol, sulphadimethoxine and ormetoprim) at a therapeutic dose and maximum residue limit (MRL) level for 5 days by dissolving in water. Blood was collected from caudal peduncle of fish using the methodology of Udomkusonsri *et al*. (2007) with minor modifications. The fish were forfeited at 96 hours subsequent to gathering the blood. Hematology and biochemical parameters were investigated utilizing blood and serum of fish. Liver was collected and preserved in 10 per cent neutral buffered formalin for histopathological examination. Experimental design and experimental fish groups were shown in the Table 1 and 2.

Blood sampling and hematological examination

At the end of the experiment, all the experimental fish were famished for 24 hours. Fish from every trough were anesthetized utilizing 0.05 ml of clove oil in 500 ml of water. For acquiring the blood sample, the peduncle area of the body surface was cleaned and dried utilizing blotching paper. Blood samples were collected from six fishes in each gathering using a disposable 1 ml tuberculin syringe. The blood samples were collected in to Lavender top (EDTA) tube for hematological examination and yellow top (non-EDTA) tube for serum biochemical examination. Hemoglobin (Hb) content was determined by Cyanmethemoglobin Method and Packed Cell Volume (PCV) was determined by Microhematocrit method (Drabkin, 1946; Bull *et al*., 2000).

Biochemical parameters examination

Blood samples from non-EDTA tube were allowed to clot at 4°C for 2 hours and the serum was separated by centrifugation at 3000 rpm for 20 min. As per the technique of Reitman and Frankel (1957) and Henry *et al*. (1974), aspartate aminotransferase (AST), alanine transaminase (ALT) and creatinine were determined. total protein (TP), albumin, cholesterol, calcium, phosphorus and glucose were also determined as per the standard procedure.

Histopathological examination

At the end of the experiment, liver tissue was collected in 10% neutral buffered formalin to assess the histopathological changes due to exposure of antibiotics. After fixation tissue samples were dehydrated in ascending grades of 70%, 90% and 100% of ethanol, cleared in xylene and embedded in paraffin wax. Sectioned tissue of 6-8-micron thickness was mounted on glass slides and stained with Haematoxylin (H) and Eosin (E) stains (Bancroft and Gamble, 2008). All areas of liver section was examined using a microscope equipped with camera.

RESULTS AND DISCUSSION

Hematological examination

Hematological parameters in fish have been widely used as good indicators for analysing the harmful effects of antibiotics, an environmental pollutant PCBs and fish physiological status (Kumar *et al*., 2011).

The results of hematology parameters of *Oreochromis niloticus* treated with antibiotics at therapeutic dose and maximum residue limit (MRL) level are presented in the Table 3. There were no major alterations in the values of hemoglobin

Table 1: Experimental design of fish exposed to antibiotics.

Antibiotics	No. of fish		Dose		Treatment days
	Therapeutic dose	Maximum residual limit (MRL) level	Therapeutic dose	Maximum residual limit (MRL) level	
Oxytetracycline hydrochloride	18	18	200 mg/l	100 µg/kg	5
Florfenicol	18	18	10 mg/l	1000 µg/kg	
Sulphadimethoxine and ormetoprim	18	18	50 mg/l	100 µg/kg	

Table 2: Experimental fish groups.

Groups[a]	Antibiotic	Inclusion
C1	-	Fish without treatment
A1	Oxytetracycline hydrochloride (Therapeutic dose)	Fish were treated with oxytetracycline hydrochloride at 200 mg/l for 5 days
A2	Oxytetracycline hydrochloride (Maximum Residue Limit) level	Fish were treated with oxytetracycline hydrochloride at 0.1 mg/l for 5 days
A3	Florfenicol (Therapeutic dose)	Fish were treated with florfenicol at 10 mg/l for 5 days
A4	Florfenicol (Maximum Residue Limit) level	Fish were treated with florfenicol at 1 mg/l for 5 days
A5	Sulphadimethoxine and ormetoprim (Therapeutic dose)	Fish were treated with sulphadimethoxine and ormetoprim at 50 mg/l for 5 days
A6	Sulphadimethoxine and ormetoprim (Maximum Residue limit) level	Fish were treated with sulphadimethoxine and ormetoprim at 0.1 mg/l for 5 days

and packed cell volume between the control group and experimental group. The data were subjected to statistical analysis by ANOVA and found a significant difference at 1% level (P<0.01) between groups. The present study confirmed that the hematological parameters were not influenced in the fish exposed to antibiotics.

Kondera *et al*. (2020) reported that there were no crucial changes in the values of hematological parameters of carp which was fed with 75 mg/g of OTC for every two days/4 times. Consistent with the results of the present study, El-Adawy *et al*. (2018) also demonstrated that there were no changes in the values of hematology and thrombocytes in *Oreochromis niloticus* fed with OTC at 500 mg/kg for 60 days. Reda *et al*. (2016) reported that there were no changes in values of hematology however, a decrease in hematocrit and thrombocyte count in *Oreochromis niloticus* fed with OTC at 500 mg/kg for 2 weeks.

Karadeniz *et al*. (2007) also noticed that there were no changes in the values of hematological parameters of fish following the administration of florfenicol at 100 and 300 mg/kg body weight.

Iftikhar and Hashmi (2021) reported that sulfamethoxazole exposed to *Cyprinus carpio* reduced the level of hemoglobin, platelet and erythrocyte and increased the value of leukocyte which was contrary to the findings in the present study and it might be due to long term exposure of SMX to fish *i.e*., 28 days.

Most of the studies done in fish to demonstrate hematology parameters were not comparable to our findings which might be due to the differences in the fish species studied, environmental differences and the aligned stress factors apart from the type and dosage of the antibiotics.

The dosage of antibiotics and the sensitivity of fish play a major role in causing changes in the blood parameters. The changes in the hematology parameters mainly depend on the concentration of the antibiotics. In our study, concentration of the drug administered to fish and the duration of exposure of fish to the drug did not pose any changes in the hematological parameters.

Table 3: Hematological parameter of *Oreochromis niloticus* exposed to antibiotics at therapeutic dose and maximum residue limit (MRL) level.

Parameter	Haemoglobin	PCV
C1	4.15±0.076^{a}	13.25±0.076^{a}
A1	4.45±0.076^{a}	13.05±0.076^{b}
A2	4.05±0.076^{a}	12.25±0.076^{c}
A3	3.95±0.076^{ab}	11.95±0.076^{c}
A4	4.05±0.076^{bc}	12.55±0.076^{d}
A5	4.35±0.076^{c}	12.75±0.076^{d}
A6	4.55±0.076^{c}	13.05±0.076^{d}
F-value	8.980**	38.204**

**- Statistically significant at 1% level (P<0.01). Values are presented as mean±SE (n-6) and values with different superscripts indicate significant differences as determined by Dunkan's test (P<0.01).

Table 4: Biochemical parameters of *Oreochromis niloticus* exposed to antibiotics at therapeutic dose and maximum residue limit (MRL) level.

Group	ALT (Unit/L)	AST (Unit/L)	TP (g/dL)	Albumin (g/dL)	Cholesterol (mg/dL)	Calcium (mg/dL)	Phosphorus (mg/dL)	Glucose (mmol/L)
C1	17.50±0.764^{a}	66.50±0.764^{a}	3.15±0.076^{a}	1.35±0.076^{a}	91.50±0.764^{a}	26.50±0.763^{a}	5.65±0.076^{a}	81.50±0.764^{a}
A1	36.50±0.764^{b}	109.50±0.764^{b}	4.05±0.076^{b}	2.05±0.076^{ab}	107.50±0.764^{b}	23.55±0.076^{b}	6.25±0.076^{b}	72.50±0.764^{b}
A2	21.50±0.764^{b}	79.50±0.764^{c}	3.65±0.076b^{c}	1.85±0.076^{bc}	103.50±0.764^{c}	24.95±0.076^{b}	5.95±0.076^{c}	55.50±0.764^{b}
A3	44.50±0.764^{c}	80.50±0.764^{c}	3.65±0.076b^{c}	1.75±0.076^{cd}	122.50±0.764^{d}	22.05±0.076^{b}	7.55±0.076^{c}	62.50±0.764^{c}
A4	28.50±0.764^{d}	70.50±0.764^{d}	3.45±0.076^{cd}	1.55±0.076^{cd}	119.50±0.764^{e}	23.35±0.076^{c}	7.05±0.076^{c}	58.50±0.764^{d}
A5	25.50±0.764^{e}	110.50±0.764^{e}	3.95±0.076^{d}	1.95±0.076^{cd}	110.50±0.764^{f}	24.05±0.076^{c}	6.35±0.076^{d}	65.50±0.764^{e}
A6	22.50±0.764^{f}	102.17±0.764^{e}	3.85±0.076^{d}	1.85±0.076^{d}	115.50±0.764^{g}	24.95±0.076^{d}	6.35±0.076^{e}	58.50±0.764^{f}
F-value	152.490**	282.476**	16.408**	9.959**	190.776**	23.028**	72.00**	145.633**

Values are presented as mean±SE (n-6) and values with different superscripts indicate significant differences as determined by Dunkan's test (P<0.01), ** -Statistically significant at 1% level (P<0.01).

Biochemical profile

Biochemical parameters are one of the important parameters for toxicity studies and are also used to evaluate the physiological systems of an organism (Vutukuru, 2003). The results of biochemical parameters for *Oreochromis niloticus* treated with antibiotics at therapeutic dose and maximum residue limit (MRL) level are presented in Table 4. All the parameters expressed some changes in their values between the control and experimental groups.

Oreochromis niloticus exposed to antibiotics showed elevation of the values for all the parameters and the statistical analysis revealed a significant difference between the groups studied.

The present study revealed that there was an increase in the values of alanine aminotransaminase (ALT), aspartate aminotransferase (AST), albumin, total protein (TP), cholesterol, phosphorus and a decrease in the values of calcium and glucose for all the antibiotic treated groups which indicated damage to the liver and kidney tissues.

Similar to the present study, El-Adawy *et al*. (2018) found that when Nile tilapia (*Oreochromis niloticus*) treated with 500 mg OTC/kg, there was an increase in total protein and globulin level.

Soltan *et al*. (2013) stated that *Oreochromis niloticus* exposed to 40 mg OTC/kg increased the level of alanine aminotransaminase (ALT) and aspartate aminotransferase (AST). In addition, Nakano *et al*. (2018) demonstrated that the exposure of Coho salmon (*Oncorhynchus kisutch*) to 100 mg OTC/kg/day for two weeks increased the activity of alanine aminotransaminase (ALT) accompanied by increase in the hepatosomatic index. Ambili *et al*. (2013) illustrated that OTC treatment for *Labeo rohita* increased the activity of hepatic ALT and AST which were similar to the findings of this study.

The outcome of the present study was similar to the results of KuHua *et al*. (2009) , who reported that there was an increase in the alanine aminotransaminase (ALT) activity following the exposure of sea bass to 30, 60, 120 mg FF/kg body weight for seven days.

Abdolhossein *et al*. (2016) studied the effect of florfenicol on biochemical parameters. Common carp (*Cyprinus carpio*) received florfenicol for 10 days at 5 mg/l and 10 mg/kg concentration. The results revealed that there was an increase in the activity of alanine aminotransaminase (ALT), aspartate aminotransferase (AST) and alkaline phosphatase (ALP) with respect to the control group.

Iftikhar and Hashmi (2021) observed that sulfamethoxazole exposed to *Cyprinus carpio* increased the level of alanine aminotransaminase (ALT) which was similar to the present findings. In this trial, common carp (*Cyprinus carpio*) were exposed to sulfamethoxazole for 28 days at a concentration of 25, 50, 100 and 200 µg/l.

The increase in the activity of alanine aminotra nsaminase (ALT) and aspartate aminotransferase (AST) indicated liver damage and a decrease in calcium level reflected kidney damage (Mikulikova *et al*., 2013). The rise in the level of ALT and AST and the decrease in the level of calcium were due to stress conditions caused by antibiotics. Irregular metabolism of protein and carbohydrates was the reason for the high levels of transaminase activity when exposed to antibiotics (Akrami *et al*., 2013; Sampaio *et al*., 2016).

Histopathology of liver

The histopathological results of liver collected at the end of treatment with antibiotics at therapeutic dose and maximum residue limit (MRL) level from *Oreochromis niloticus* are depicted in Fig 1-7.

The control group (C1) showed normal features of the liver, whereas, the A1 (OTC-200 mg/l) and A2 (OTC-0.1 mg/l) groups showed multifocal moderate hydropic degeneration. The A3 (FF-10 mg/l) group showed multifocal mild to moderate vacuolar degeneration and the A4 (FF-1 mg/l) group showed multifocal mild hydropic degeneration. The A5 (Sm and O-50 mg/l) group showed hydropic degeneration and the A6 (Sm and O-0.1 mg/l) group showed mild hydropic degeneration of hepatocytes.

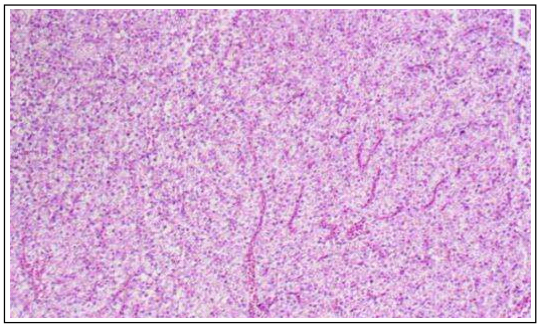

Fig 1: Liver of control (C1) group showing normal architecture, H&E, 20X.

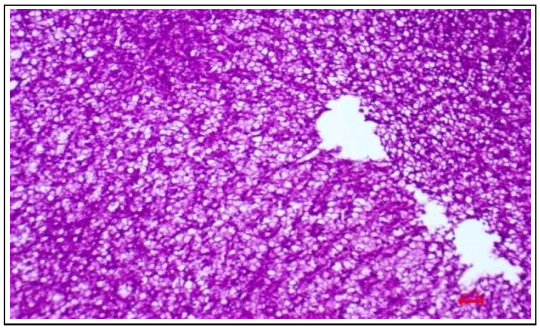

Fig 2: Liver of A1 group showing multifocal moderate hydropic degeneration, H&E, 20X.

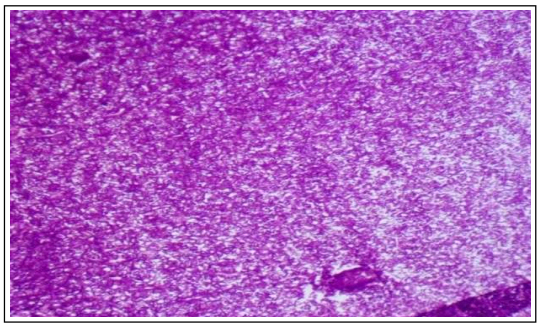

Fig 3: Liver of A2 group showing hydropic degeneration H&E, 20X.

The result of the present study was similar to Reda *et al*. (2013) who reported that the OTC fed at 100 mg/kg for 12 weeks to *Oreochromis niloticus* led to congestion, vacuolations in the hepatocytes and fatty changes in the liver and in kidney. Similar to the results obtained in this study, Dey *et al*. (2022) also reported that when monosex *Oreochromis niloticus* fries exposed to OTC at 350, 700, 2100, 3500 and 7000 mg/l for 30 days at 3 h/day showed dilatation of vascular duct, diffuse necrotized hepatic parenchyma, fatty changes and vacuolation in hepatocytes and necrosis, dissolution of the nephritic tubule and glomerulonephritis.

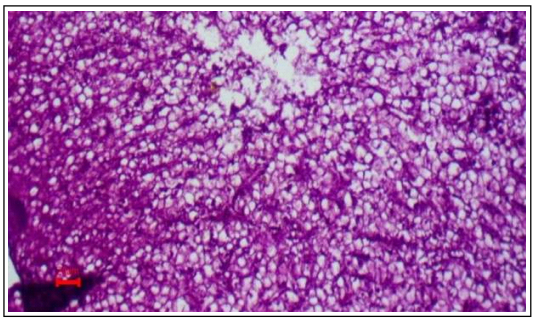

Fig 4: Liver of A3 group showing multifocal mild to moderate vacuolar degeneration, H&E, 20X.

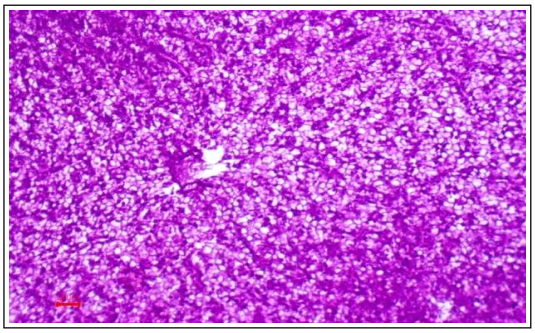

Fig 5: Liver of A4 group showing multifocal mild hydropic degeneration, H&E, 20X.

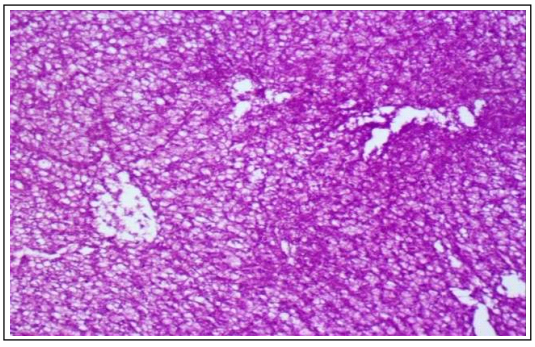

Fig 6: Liver of A5 group showing hydropic degeneration, H&E, 20X.

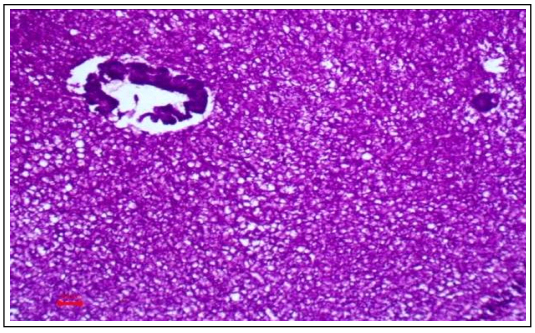

Fig 7: Liver of A6 showing mild hydropic degeneration, H&E, 20X.

Florfenicol administered to tilapia via the feed at 15, 45, 75 mg/kg BW for twenty days caused hepatocellular vacuolation and tubular epithelial cell degeneration and necrosis (Gaikowski *et al*., 2012).

Iftikhar *et al*. (2022) reported that the fresh water fish exposed to sulfamethoxazole at 25-200 µg/l concentration for 28 days caused stagnation of bile, vacuolization of hepatocytes and congestion of liver parenchyma, which were similar to the present research findings.

Hentschel *et al*. (2005) stated that the long-term exposure with high dosage of antibiotics leads to hepatoxicity (liver damage) and nephrotoxicity (kidney damage). The histological changes and elevated activity of ALT and AST were due to the stress caused by antibiotics which in turn led to the damage of liver and kidney.

CONCLUSION

Hematology results revealed that there were no alterations in the value of haemoglobin and packed cell volume of fish exposed to antibiotics. Biochemical profile of the serum showed that there was an increase in the activity of alanine transaminase (ALT), aspartate aminotransferase (AST) and in the levels of total protein, glucose, cholesterol and phosphorus and decrease in the level of calcium which were known to indicate damage to liver and kidney tissue which were further confirmed by histopathological examination. The present study indicates that the exposure of antibiotics, leads to their accumulation in the liver which in turn elevated the level of biochemical parameters and caused more damage to liver tissue which were confirmed by histopathological examination.

ACKNOWLEDGEMENT

The author is thankful to Pharmacovigilance Laboratory for Animal Feed and Food Safety, Tamil Nadu Veterinary and Animal Sciences University, Chennai, India and Institute of Fisheries Post Graduate Studies, Tamil Nadu Dr. J. Jayalalithaa Fisheries University, Chennai, India for providing laboratory facilities to conduct the experiment.

Conflict of interest: None.

REFERENCES

Abdolhossein, J.N., Rahim, P., Hossein, N.V., Ali, S. (2016). Effect of florfenicol following bath and oral administration on hematological and biochemical parameters in common carp, *Cyprinus carpio*. Journal of Animal Environment. 8(1): 237-242.

Akrami, R., Iri, Y., Rostami, H.K., Mansour, M.R. (2013). Effect of dietary supplementation of fructooligosaccharide (FOS) on growth performance, survival, lactobacillus bacterial population and hemato-immunological parameters of stellate sturgeon (*Acipenser stellatus*) juvenile. Fish and Shellfish Immunology. 35(4): 1235-1239.

Ambili, T.R., Saravanan, M., Ramesh, M., Abhijith, D.B., Poopal, R.K. (2013). Toxicological effects of the antibiotic oxytetracycline to an Indian major carp *Labeo rohita*. Archives of Environmental Contamination and Toxicology. 64: 494-503.

Bancroft, J.D., Gamble, M. (2008). Theory and practice of histological techniques. Journal of Neuropathology and Experimental Neurology. 67(6): 633. https://doi.org/10.1097/NEN.0b013e31817e2933.

Bull, B.S., Koepke, J.A., Simson, E., Assendelft, O.W. (2000). Procedure for Determining Packed Cell Volume by the Microhematocrit Method; Approved Standard-Third Edition. Clinical and Laboratory Standards Institute. 20, 18.

Danner, M.C., Robertson, A., Behrends, V., Reiss, J. (2019). Antibiotic pollution in surface fresh waters: Occurrence and effects. Science of the Total Environment. 664: 793-804.

Dey, B., Abraham, T.J., Singha, J., Roy, A., Karmakar, S., Patil, P.K., Roy, U. (2022). Histopathological changes and tissue residue concentrations of monosex *Nile tilapia* (*Oreochromis niloticus* L.) fries exposed to oxytetracycline. Aquaculture International. 30(4): 2113-2128.

Drabkin, D.L. (1946). Spectrophotometric studies XIV. The crystallographic and optical properties of the hemoglobin of man in comparison with those of other species. Journal of Biological Chemistry. 164(2): 703-723.

El-Adawy, M., Abd El-Aziz, M., El-Shazly Ali, N.G., Abu El-Magd, M. (2018). Dietary propionic acid enhances antibacterial and immunomodulatory effects of oxytetracycline on *Nile tilapia*, *Oreochromis niloticus*. Environmental Science and Pollution Research. 25: 34200-34211.

Fent, K., Weston, A.A., Caminada, D. (2006). Ecotoxicology of human pharmaceuticals. Aquatic Toxicology. 76(2): 122-159.

Gaikowski, M.P., Wolf, J.C., Schleis, S.M., Tuomari, D., Endris, R.G. (2012). Safety of Flo administered in feed to tilapia (*Oreochromis sp.*). Toxicologic Pathology. 41: 639-652.

Henry, R.L., Cannon, D.C., Winklemen, J.W. (1974). Clinical Chemistry: Principles and Techniques, 2nd (ed). Harper and Row, Hagerstown, 1128-1135.

Hentschel, D.M., Park, K.M., Cilenti, L., Zervos, A.S., Drummond, I., Bonventre, J.V. (2005). Acute renal failure in zebrafish: A novel system to study a complex disease. American Journal of Physiology-Renal Physiology. 288: 23-29.

Iftikhar, N., Hashmi, I. (2021). Assessment of immunohematological, hematological and biochemical responses in cultivable fish *Cyprinus carpio* exposed to an antibiotic sulfamethoxazole (SMX). Journal of Water and Health. 19(1): 108-119.

Iftikhar, N., Zafar, R., Hashmi, I. (2022). Multi-biomarkers approach to determine the toxicological impacts of sulfamethoxazole antibiotic on freshwater fish *Cyprinus carpio*. Ecotoxicology and Environmental Safety. 233: 113331.

Karadeniz, A., Ince, S. and ALP, H. (2007). The effects of chloramphenicol, Thiamphenicol and florfenicol on glucose 6-phosphate dehydrogenase (G6PD), reduced glutathione (GSH) enzyme activities and some hematological parameters in mice. Ataturk Universitesi Veteriner Bilimleri Dergisi. 2(4): 159-163.

Kondera, E., Bojarski, B., Lugowska, K., Kot, B., Witeska, M. (2020). Effects of oxytetracycline and gentamicin therapeutic doses on hematological, biochemical and hematopoietic parameters in *Cyprinus carpio* Juveniles. Animals. 10(12): 2278. https://doi.org/10.3390/ani10122278.

KuHua, J., Majian, Y.Y., Liu, Z.P., Maxiaoden, C.H. (2009). The impact of different dose florfenicol on blood biochemical indexes in pigs and antibody against classical swine fever virus. Chinese Journal of Veterinary Science. 29: 1586-1589.

Kumar, N., Prabhu, P.A.J., Pal, A.K., Remya, S., Aklakur, M., Rana, R.S., Gupta, S., Raman, R.P. and Jadhao, S.B. (2011). Anti-oxidative and immunohematological status of Tilapia (*Oreochromis mossambicus*) during acute toxicity test of endosulfan. Pesticide Biochemistry and Physiology. 99(1): 45-52.

Mikulikova, I., Modra, H., Blahova, J., Kruzikova, K., Marsalek, P., Bedanova, I., Svobodova, Z. (2013). Recovery ability of common carp (*Cyprinus carpio*) after a short-term exposure to terbuthylazine. Polish Journal of Veterinary Sciences. 16(1): 17-23.

Nakano, T., Hayashi, S., Nagamine, N. (2018). Effect of excessive doses of oxytetracycline on stress-related biomarker expression in coho salmon. Environmental Science and Pollution Research (international). 25(8): 7121-7128.

OECD. (2019). Pharmaceutical Residues in Freshwater: Hazards and Policy Responses, OECD Studies on Water, OECD Publishing, Paris.

Reda, R.M., Ibrahim, R.E., Ahmed, E.N., Eli-Bouhy, Z.M. (2013). Effect of oxytetracycline and florfenicol as growth promoters on the health status of cultured *Oreochromis niloticus*. Egyptian Journal of Aquatic Research. 39(4): 241-248.

Reda, R.M., Mahmoud, R., Selima, K.M., El-Araby, I.E. (2016). Effects of dietary acidifiers on growth, hematology, immune response and disease resistance of *Nile tilapia*, *Oreochromis niloticus*. Fish Shellfish Immunology. 50: 255-262.

Reitman, S. and Frankel, S. (1957). A colorimetric method for the determination of serum glutamic oxalacetic and glutamic pyruvic transaminases. American Journal of Clinical Pathology. 28(1): 56-63.

Sampaio, F.G., Carra, M.L., Jonsson, C.M., Goncalves, V.T., Dal'Bo, G., Nunes, K.S.D., Valim, J.H., Lima Dallago, B.S., do Nascimento de Queiroz, S.C, Reyes, F.G.R. (2016). Effects of dietary exposure to sulfamethazine on the hematological parameters and hepatic oxidative stress biomarkers in *Nile tilapia* (*Oreochromis niloticus*). Bulletin of Environmental Contamination and Toxicology. 97(4): 528-535.

Soltan, M., Agouz, M., Mohamed, M.G. (2013). Effect of oxytetracycline and florfenicol drugs on the physiological activities and its residues of *Oreochromis niloticus*. Egyptian Journal of Aquatic Biology and Fisheries. 17(4): 25-36.

Udomkusonsri, P., Arthitvong, S., Klangkaew, N., Kusucharit, N. (2007). Pharmacokinetics of enrofloxacin in koi carp (*Cyprinus carpio*) after various routes of administration. Kasetsart Journal (Natural Science). 41: 62-68.

Vutukuru, S.S. (2003). Chromium induced alterations in some biochemical profiles of the Indian major carp, *Labeo rohita* (Hamilton). Bulletin of Environmental Contamination and Toxicology. 70(1): 118-23.