RESEARCH ARTICLE Indian Journal of Animal Research, Volume 57 Issue 6: 714-721 (June 2023)

Antimicrobial and Anti-inflammatory Activity of *Thespesia populnea* Mediated Nanoparticles in Murine Mastitis Model

A. Jayasri[1], P. Eswara Prasad[2], B.D.P. Kala Kumar[3], D. Madhuri[4], K. Padmaja[2], B. Sampath Kumar[5], M. Sonali[6]

10.18805/IJAR.B-5083

ABSTRACT

Background: Bovine mastitis is a common inflammatory disease where bacterial resistance to antibiotics is a major concern in its treatment. Nanoparticles have been known in overcoming difficulties of treatment therapies including multi drug resistant bacterial infections but research on their role in mastitis treatment is limited. Nowadays Green synthesis of nanoparticles is gaining importance to overcome problems associated with chemical synthesis. Therefore, the present study was conducted to evaluate the ameliorative action of *Thespesia populnea* (*T. populnea*) mediated synthesized silver and zinc oxide nanoparticles in mastitis induced mice.

Methods: A total of 48 mice were divided into six groups: where Group I served as control, groups II to VI were inoculated with *Staphylococcus aureus* (*S. aureus*) culture for mastitis induction. After mastitis induction, groups III, IV, V and VI received *T. populnea* methanolic extract (TPE), *T. populnea* methanolic extract mediated silver nano particles (TPSN) (≈95 nm size), *T. populnea* methanolic extract mediated ZnO nanoparticles (TPZN) (≈ 85 nm size) and Ceftriaxone respectively. Whole blood was collected to analyze inflammatory indicators haptoglobin (Hp) and C reactive protein (CRP). The mammary gland weights, bacterial load and changes in tissue samples were studied.

Result: The formation of brown colour solution and white crystalline precipitate indicated the formation of TPE mediated silver and zinc oxide nanoparticles respectively. The sizes of these TPSN and TPZN when characterized by SEM, were found to be 95 and 85 nm respectively. The values of mammary gland weight, bacterial load, Hp and CRP were elevated significantly in group II mice when compared to other treatment groups. Histopathological examination of mammary gland revealed bacterial clumps, severe leucocytic infiltration along with congestion and necrotic changes in group II. The ameliorating changes in damaged tissues of the experimental groups remained in the decreasing order of TPSN, ceftriaxone, TPZN and TPE respectively. Therefore, phytogenic nanoparticles can be effectively used to control the mastitis.

Key words: Bacterial load, C-reactive protein, Haptoglobin, Murine mastitis, TPSN, TPZN.

INTRODUCTION

Mastitis is a chronic disease which is influenced by many factors, involving interaction between host, pathogens and environment (Kinfe, 2017). Bovine mastitis is the inflammation of mammary gland (Bradley, 2002) in cattle which is characterized by physical, chemical and bacteriological changes in milk and pathological abnormalities in glandular tissues of the udder ultimately affecting quality and quantity of milk (Naranjo and Slowey, 2022). The most common causative agents of bovine mastitis are *Staphylococcus aureus, Streptococcus agalactiae, Streptococcus uberis* and *Escherichia coli* (Krishnamoorthy *et al*., 2021). In high-yielding dairy cattle, mastitis is mainly caused due to *S. aureus* colonisation, frequently resulting in subclinical infections that become chronic (Sears and McCarthy, 2003). Due to *S. aureus* self-defence mechanisms, the conventional antimicrobial therapy becomes ineffective in the treatment of infection brought on by *S. aureus* (Zaatout *et al*., 2020). Failure of antimicrobials in aiding the immune system to overcome Staphylococcal mastitis poses a significant problem for dairy producers.

Nanomedicines have emerged as promising therapeutic agents in treating *S. aureus* infections (Park *et al*., 2017). Metal nanoparticles are hypothesised to be effective in killing

[1]Department of Veterinary Biochemistry, College of Veterinary Science, Rajendranagar, PVNRTVU, Hyderabad-500 030, Telangana, India.
[2]Department of Veterinary Biochemistry, College of Veterinary Science, Sri Venkateswara Veterinary University, Tirupati-517 502, Andhra Pradesh, India.
[3]Department of Veterinary Pharmacology and Toxicology, College of Veterinary Science, Mamnoor, PVNRTVU, Hyderabad-500 030, Telangana, India.
[4]Department of Veterinary Pathology, College of Veterinary Science, Korutla, PVNRTVU, Hyderabad-500 030, Telangana, India.
[5]Department of Veterinary Biochemistry, College of Veterinary Science, Mamnoor, PVNRTVU, Hyderabad-500 030, Telangana, India.
[6]Department of Veterinary Microbiology, College of Veterinary Science, Rajendranagar, PVNRTVU, Hyderabad-500 030, Telangana, India.

Corresponding Author: A. Jayasri, Department of Veterinary Biochemistry, College of Veterinary Science, Rajendranagar, PV Narsimha Rao Telangana Veterinary University, Hyderabad-500 030, Telangana, India. Email: jayasri.biochem@gmail.com

How to cite this article: Jayasri, A., Prasad, P.E., Kumar, B.D.P.K., Madhuri, D., Padmaja, K., Kumar, B.S. and Sonali, M. (2023). Antimicrobial and Anti-inflammatory Activity of *Thespesia populnea* Mediated Nanoparticles in Murine Mastitis Model. Indian Journal of Animal Research. 57(6): 714-721. doi: 10.18805/IJAR.B-5083.

Submitted: 16-01-2023 **Accepted:** 05-05-2023 **Online:** 31-05-2023

bacteria because of their particle size and high surface-to-volume ratio. They engage directly with bacterial membranes than having an impact purely due to the release of metal ions (Morones *et al*., 2005). Among all the synthesised nanoparticles silver and zinc oxide nanoparticles have been shown to have antibacterial action against a variety of gram positive and gram negative bacteria, including multidrug resistant strains (Aparna *et al*., 2018). Nanoparticles inhibit the formation of biofilm (Park *et al*., 2017) and can also penetrate it (Yazar *et al*., 2012). In addition, plant-mediated biosynthesis of nanoparticles is considered as being superior to other chemical and physical methods due to their lower toxicity, low cost, eco-friendly nature, controlled particle size and stability. Biosynthesised nanoparticles also have greater bactericidal activity than chemically synthesised colloidal nanoparticles (Suresh *et al*., 2014).

T. populnea, commonly known as the Indian tulip tree or Portia tree belongs to family*, Malvaceae.* Various phytochemicals such as flavonoids, tannins, steroids, glycosides, saponins, phenols, terpenoids and alkaloids are found in *T. populnea* methanolic leaf extract (Krishnamoorthy *et al*., 2014; Jayasri *et al*., 2019) which are responsible for the medicinal properties of *T. populnea*. The extracts of *T. populnea* have been found to be effective against many gram positive and gram negative bacteria (Shekshavali and Hugar, 2012) including multidrug resistant *S. aureus* (Archana *et al*., 2010). Shah and Alagawadi, (2011) has revealed the anti-inflammatory property of *T. populnea.* Although many studies have evaluated the antimicrobial properties of green synthesised nanoparticles, studies evaluating their efficacy in treating drug resistant mastitis are limited. Therefore, the present study was aimed to evaluate the antimicrobial and anti-inflammatory properties of silver and zinc oxide nanoparticles which are biosynthesised using *T. populnea* leaf extract in mastitis induced mice.

MATERIALS AND METHODS

Preparation of methanolic leaf extract

The leaves of *T. populnea* were obtained from Tirupati and its surrounding places of Chittoor district in Andhra Pradesh, India. Cold maceration method was used for TPE preparation. Dried leaves of *T. populnea* were coarsely powdered and 100 g of this powder was soaked in 500 ml of 95% methanol (v/v) for 72 h with random stirring. The concentrated filtrate was air dried. Finally, with reference to the air-dried material, the percentage yield was calculated after the extract was weighed.

Synthesis of TPE mediated silver and ZnO nanoparticles

For synthesis of TPE mediated silver nanoparticles, 10 ml of 2% TPE was added to 90 ml of 0.1 M $AgNO_3$ solution at 95°C and mixed vigorously.

For synthesis of TPE mediated ZnO nanoparticles, 0.5% of zinc acetate was added drop wise to 4 ml of TPE while stirring. NaOH was used to adjust the pH of the solution to 12. This precipitate was washed with water and filtered. The filtrate was dried at 60°C to get zinc oxide nanoparticles.

Animals

Female albino mice weighing 25-35 g were procured from JEEVA life sciences, Hyderabad, Telangana, India. The mice were given ad libitum feed and water. Permission to conduct animal experimentation was obtained from the Institutional Animal Ethics Committee (I/2018-3/IAEC/C.V.Sc., Hyd). The present experiment was carried out at College of Veterinary Science, Rajendranagar, PVNRTVU, Telangana, India in the year 2020.

Experimental design

Forty-eight swiss albino female mice between 10-15 days of lactation were divided randomly into six groups (n=8) where group I was served as normal control group and mastitis was induced in groups II to VI by intra mammary (L4 teat) inoculation of *S. aureus* culture (4.0×10^4 organisms) as per method of Chandler, (1970) with slight modifications. Six hours after inoculation, group I received PBS, group III received 20 µl of TPE (dissolved in 1% aqeous DMSO solution), group IV was treated with 20 µl of TPSN and group V was administered with 20 µl of TPZN and mice in group VI were treated with 20 µl of Ceftriaxone (Intacef-4, INTAS pharmaceuticals Limited, India) by intra mammary route (L4 teat). Status of mastitis affected mammary glands was evaluated at 42 h post drug treatment. Prior to the terminal sacrifice (42 h post treatment), animals were anaesthetized with ketamine and blood was collected *via* cardiac puncture in heparin coated tubes for analysis of biochemical parameters.

Weights of mammary glands and evaluation of bacterial load

At the end of experimental period (42 h post treatment) animals were euthanized and the mammary glands were collected aseptically and weighed. 10% homogenate of each mammary gland was prepared by using sterile PBS solution followed by making serial dilutions to 10^{-3}, 10^{-5} and 10^{-7} in sterile PBS. A volume of 100 µl was plated on nutrient agar plates in triplicate for each dilution. The plates were incubated for 24 h at 37°C. The plates showing <300 colonies were counted using colony counter and expressed in $\log_{10}$ values.

Estimation of Haptoglobin and C-reactive protein

1.0 ml of whole blood was collected in clot activator tube and the tube was centrifuged at 3000 rpm for 10 minutes to separate the serum. The serum was utilized for the estimation of Hp and CRP by ELISA (Kinesis Dx, USA).

Histopathology

The mammary glands of murine model of mastitis were collected in 10% neutral buffered formalin for histopathological studies. 4-7 µm of sections from tissue samples were cut and stained with heamatoxylin and eosin (H&E) and examined under light microscope.

Statistical analysis

The obtained experimental data for different treatments from the experimental animals have been analyzed by one way ANOVA using statistical package for social sciences (SPSS) Version-20. Differences between means were tested by using Duncan's multiple comparison tests and significance level was set at P<0.01(Snedecor and Cochran, 1994).

RESULTS AND DISCUSSION

Synthesis and characterization of TPE mediated silver and ZnO nanoparticles

A change of colour from pale yellow to brown was observed on incubation of TPE with silver nitrate solution indicating the formation of TPE mediated silver nanoparticles. Similar change in colour was observed by Thakur *et al.* (2022). The formation of zinc oxide nanoparticles was observed by the formation of white crystalline precipitate which was in correspondence to result obtained by Naseer *et al.* (2020). The synthesized particles were characterized using SEM where the spherical shaped agglomerated silver nanoparticles are in the range of 83 to 597 nm with an estimated average size of approximately 95 nm which corresponds to the result obtained by Prasannaraj *et al.* (2017) where SEM analysis of TPSN was reported as spherical shaped particles with a size range of 47-97 nm. However, average particle size of 273.5 nm for *Boswillia ovalifoliolata* mediated silver nanoparticles and 126.6 nm for *Cinnamomum verum* mediated silver nanoparticles was reported by Aparna *et al.* (2018) and Sree Vani *et al.* (2016) respectively. The SEM image analysis of TPZN revealed spherical shaped particles with an average particle size of approximately 85 nm which is in agreement with the results of Lopez-Miranda *et al.* (2023) where the size of ZnO nanoparticles synthesised with sargassum extract was found to be in between 80 and 100 nm. However the results obtained were contrary to the ones obtained by Sundrarajan *et al.* (2015) who reported spherical morphology and average size of 100 nm for *Pongamia pinnata* leaf extract mediated nano ZnO.

Mammary gland weights and bacterial load

The mammary gland weights (grams) and the bacterial load (log_{10} CFU/gm of tissue) (Fig 1) in mastitis treated group *i.e* Group II was found to be significantly ($p<0.01$) higher when compared to Group I as shown in Table 1. The groups treated with TPSN and Ceftriaxone groups (Group IV and VI) showed

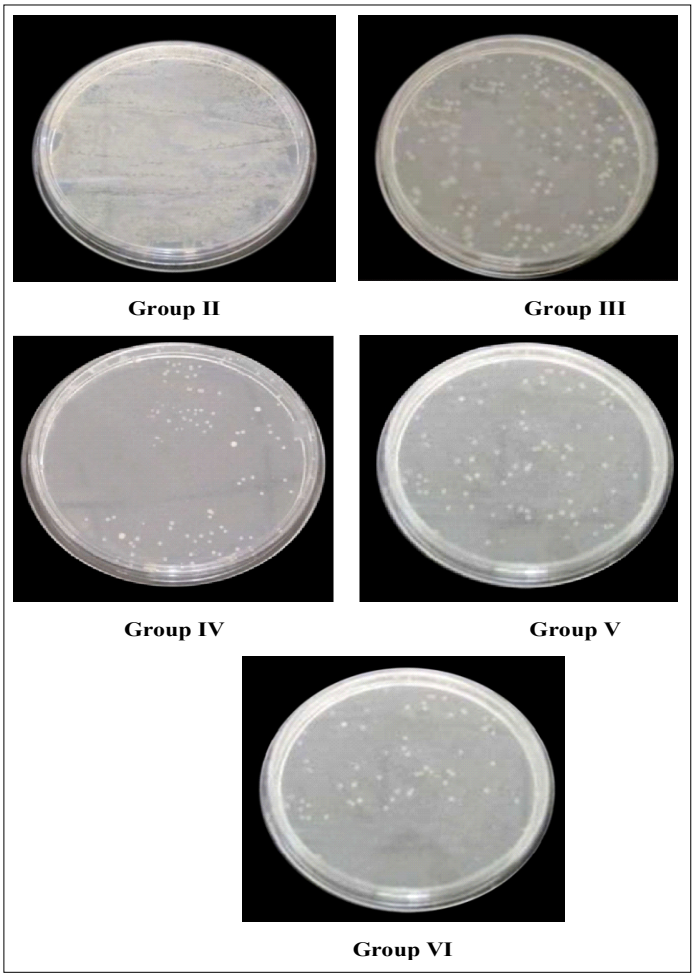

Fig 1: Effect of different treatments on total plate count of bacteria in different experimental groups.

a significant reduction in mammary gland weight as well as bacterial load when compared to groups II, III and V respectively. However, Group IV and VI showed no significant difference between them. The results indicated that the bactericidal action of TPSN and TPZN is significantly (P<0.01) higher compared to TPE alone, indicating herbal mediation with nanoparticles is more effective than using herbal extract alone. Kaoud and Yosseif, (2013) reported that intramammary infusion of silver nanoparticles showed effective antibacterial activity in curing of mastitis infected buffaloes. Aparna *et al.* (2018) reported that herbal mediated silver nanoparticles is much more effective than herbal extract alone. The increased mammary gland weight in group II may be due to the inflammatory process, congestion and infiltration of inflammatory cells. Similar observations were reported by Geng *et al*. (2020) and Krishnamoorthy *et al.* (2018) after inoculation with *S. aureus* by intramammary route in mice. However, the decrease in the values in the treatment groups were in agreement with results reported by Chaitanya *et al.* (2013) and Muralidhar *et al.* (2017) where they observed a decrease in mammary gland weight and bacterial load in mastitis induced mice 18 h, after administration of aloin mediated silver nanoparticles and acetyl-11-α-keto-β boswellic acid mediated silver nanoparticles respectively.

Estimation of Haptoglobin and C-reactive protein

Positive acute phase proteins like Hp and CRP are released by hepatocytes after cytokine (IL-1, IL-6 and TNF-α) stimulation (Heinrich *et al*., 1998) within few hours after infection and hence estimation of these proteins is considered as indicators of inflammation. Significant (P<0.01) difference was observed in Hp and CRP values in serum of experimental groups. There was a significant restoration of Hp and CRP values in all the treated groups as compared to group II (Table 1). A higher decrease of Hp and CRP levels in group IV and a lower decrease in group III was observed indicating that TPSN was effective in restoring the acute phase response that got elevated due to experimental induction of mastitis. Higher restoration of Hp and CRP was in order of group IV, VI and V while a lower restoration in group III was observed indicating the greater anti-inflammatory effect of TPSN compared to ceftriaxone, TPZN and TPE alone. The cytokine production caused by the bacterial pathogens trigger the release of the neutrophils and macrophages which stimulate the production of acute phase proteins (Ozkanlar *et al*., 2012). This acute phase proteins have been reported to be early biomarkers of *S. aureus* mastitis (Aitken *et al*., 2011).

Results obtained were in agreement with Chaitanya *et al*. (2013) and Muralidhar *et al*. (2017) who noticed a similar amelioration in CRP values in serum of mice treated with aloin mediated silver nanoparticles and acetyl 11 α keto β boswellic acid mediated silver nanoparticles respectively in mastitis induced mice. Significant (P<0.01) reduction in CRP values in plasma of rats treated with topical application of *Trianthema portulacastrum* mediated zinc oxide nanoparticles compared to untreated rats in induced wound model were observed by Yadav *et al*. (2018). This reduction of acute phase proteins can be attributed to the reduction in the levels of cytokines by nanoparticles (Nagajyothi *et al*., 2015).

Histopathology

The Histological sections from mammary gland of Group I revealed mammary gland with normal architecture of alveoli with intact alveolar epithelium and few alveoli were distended with secretory material suggestive of milk Fig 2 (a) and (b). Secretory acini were appeared to be normal with interlobular septa. Sections from Group II animals revealed areas of necrotic changes and complete loss of structure of secretory epithelial cells Fig 2 (c) and (d). Some of the sections showed severe infiltration of inflammatory cells comprising of mainly neutrophils and mono nuclear cells in the alveolar lumen with vacuolar changes of alveolar epithelial cells. Few sections revealed acute purulent reactions characterized by well demarked focal necrosis and congestion of leucocytes in between and within the acini. Similar results were reported by Taifa *et al.* (2022) and Muralidhar *et al.* (2017) where mastitis was induced using *S. aureus*. Severe infiltration of neutrophils occurs in response to the intramammary infection of bacteria which in due course leads to damage to epithelial cells and tissue injury.

Sections from Group III animals showed slight reduction of inflammatory signs Fig 2 (e) and (f). Alveolar epithelium appeared to be normal. Some of the sections revealed areas of moderate infiltration of neutrophils and congestion in interalveolar space.

Sections from Group IV animals presented a marked reduction of all the inflammatory signs Fig 2 (g) and (h). Most of the acini were showing normal architecture except some portions with small foci of leucocytic infiltration in interalveolar space. Lesions reverted back to normal architecture.

Table 1: Mean±SE values of Weight of mammary gland (gms), bacterial load (log_{10}CFU/g of tissue), Hp (mg/dl) and CRP (mg/dl).

Parameters	Group I	Group II	Group III	Group IV	Group V	Group VI
Weight of Mammary gland (gms)	0.18^{a}±0.01	0.45^{e}±.01	0.35^{d}±.01	0.22^{b}±0.01	0.31^{c}±.01	0.25^{b}±.01
Bacterial load (log_{10} CFU/g of tissue)	0.0^{a}	>9.48^{e*}	9.03^{d}±0.03	8.34^{b}±0.07	8.89^{c}±0.04	8.44^{b}±0.03
Haptoglobin (mg/dl)	0.61^{a}±003	1.89^{f}±0.001	1.36^{e}±0.001	0.94^{b}±0.002	1.12^{d}±0.001	0.99^{c}±0.001
CRP (mg/dl)	0.015^{a}±0.001	0.067^{f}±0.001	0.042^{e}±0.00	0.022^{b}±0.001	0.032^{d}±0.001	0.026^{c}±0.001

Means with different superscripts in column are significantly (P<0.01) different.

*Bacterial counts could not be performed in the mastitis group (Group II) because of formation of mat even at highest dilution of 10^{-7}. Hence, the count is assumed to be >300×10^{8} CFU/g.

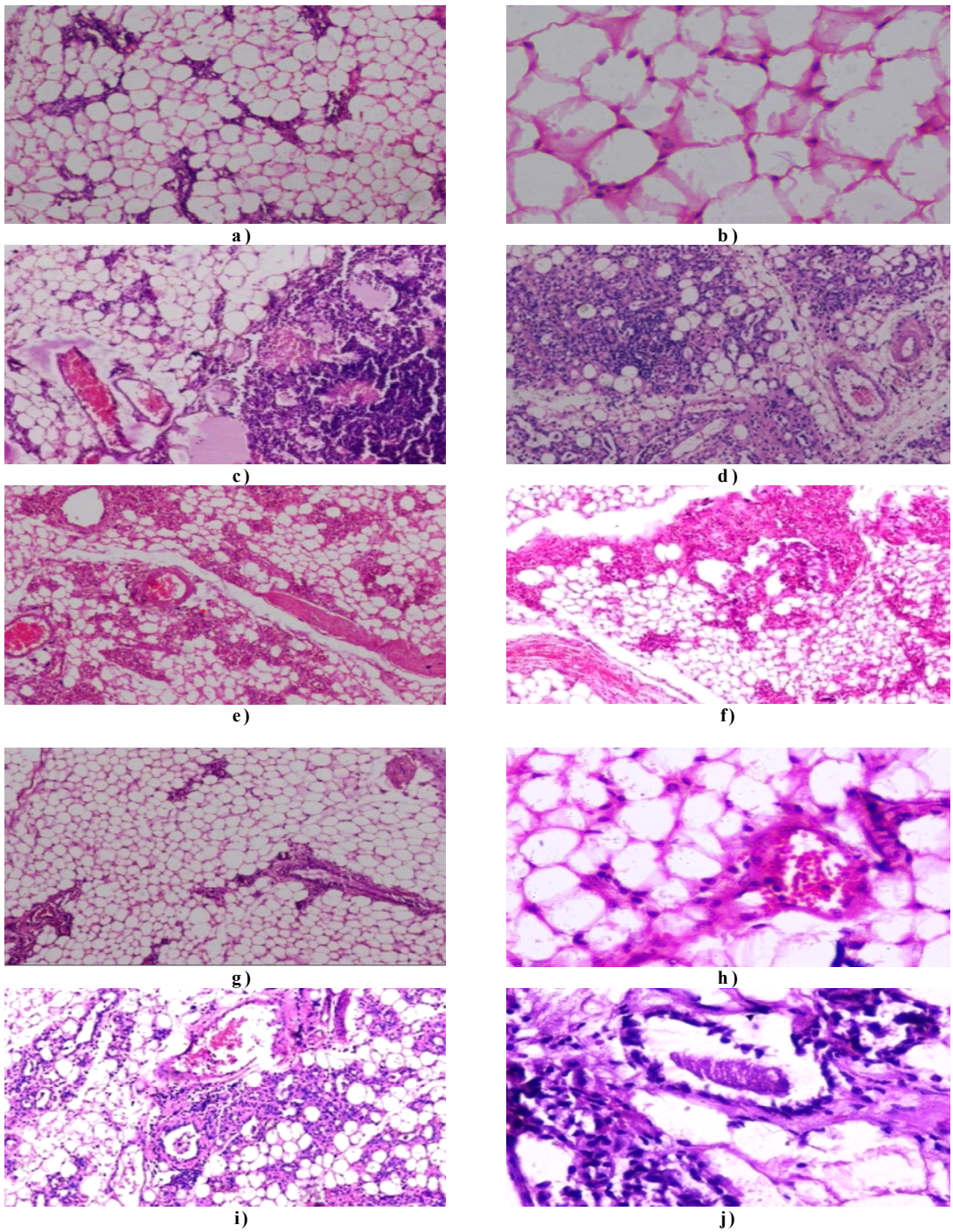

(a) Normal secretory acini with interlobular septa of mammary gland (G-I) H&E 10X. (b) Few alveoli distended with eosinophilic secretory material (G-I) H&E 40X. (c) Most of acini showing necrotic changes and severe congestion along with infiltration (G-II) H&E 10X. (d) Severe leucocytic infiltration in acini and congestion in interlobular connective tissue (G-II) H&E 10X. (e) Moderate infiltration of inflammatory cells in inter alveolar space and congestion (G-III) H&E 10X. (f) Moderate infiltration of inflammatory cells (G-III) H&E 10X. (g) The acini showing normal architecture (G-IV) H&E 10X. (h) Lesions reverted back to normal except for mild congestion (G-IV) H&E 40X. (i) Mild congestion and infiltration of inflammatory cells (G-V) H&E 10X. (j) Mild congestion and desquamation of ductal epithelium (G-V) H&E 40X. (k) Normal architecture of acini except for mild congestion (G-VI) H&E 10X. (l) Mild leucocytic infiltration in few acini and congestion (G-VI) H&E 10X.

Fig 2: Histopathology of mammary gland.

Sections of group V animals Fig 2 (i) and (j) revealed marked reduction of all the inflammatory signs except for some portions showing leucocytic infiltration, mild congestion and desquamation of ductal epithelium.

Sections of Group VI Fig 2 (k) and (l) had normal architecture of the acini except few areas showing leucocytic infiltration in few acini and mild congestion.

The histological changes that occurred during repair of the damaged tissues of the treated groups suggested that group IV was more efficient as compared to other treated groups. The ameliorating changes in damaged tissues of the experimental groups remained in the decreasing order of TPSN, ceftriaxone, TPZN and TPE respectively. These results can be corroborated with restoration of the positive acute phase proteins in blood by the nanoparticles. Similar reports were presented in studies by Sree Vani *et al.* (2016) where the superior wound healing capacity of *Cinnamomum verum* mediated silver nanoparticles was attributed to combined effect of antimicrobial and antioxidant properties of phytochemical constituents of *Cinnamomum verum* and nanoparticles. The reduction in the pathological changes by silver nanoparticles were in agreement to the study conducted by Chaitanya *et al.* (2013) and Muralidhar *et al*. (2017) where aloin mediated silver nanoparticles and acetyl-11-α-keto-β-boswellic acid mediated silver nanoparticles were used in treatment of murine mastitis. In intramammary infection of *S. aureus,* the toxins released by bacteria react with various cell types leading to the inflammatory response in which the release of neutrophils by various chemoattractants such as cytokines occurs (Chinchali and Kaliwal, 2014). However, persistent bacterial infection causes extensive mammary cell damage and tissue injury by neutrophils via reactive oxygen metabolite generation (Paape *et al*., 2002). Several studies have reported that nanoparticles have enhanced antimicrobial activity because of their size, surface positive charge (Besinis *et al*., 2014; Seil and Webster, 2012) which causes easy adherence and penetration into bacterial cell. Further the induction of oxidative stress and inhibition of biofilm formation by nanoparticles (Yazar *et al*., 2012; Dizaj *et al*., 2014) leads to bactericidal action thereby decrease in the inflammatory indicators and reversing the damaging effects of the bacterial pathogen as indicated by the results of the present study.

CONCLUSION

Nanoparticles have been known to possess various properties such as antibacterial, antifungal, anti-inflammatory, antioxidant and wound healing activities. Green synthesized nanoparticles have been known to show a potent antibacterial activity against *S. aureus* and other methicillin resistant organisms. Mastitis is caused due to multiple factors with *S. aureus* as the chief etiological agent in cattle and buffaloes. In the present study, it is shown that the overall antibacterial activity of TPSN was higher as compared to TPZN and TPE. Sero-biochemical studies in murine mastitis model concluded that TPSN is superior in controlling *S. aureus* induced mastitis as evidenced by decrease in values of positive acute phase proteins. The effect was confirmed with the histopathological studies of the mammary tissue. These ameliorative changes due to nanoparticles can be attributed to their easy penetration into bacterial cell due to their smaller size and induction of oxidative stress in the bacteria. Further, the enhanced antimicrobial and anti-inflammatory effect of TPE mediated nanoparticles when compared to TPE extract might be attributed to the combined action of bioactive compounds of TPE and the nanoparticles. Further safety studies are required for parenteral use of TPE mediated silver nanoparticles as an effective anti-inflammatory and antimicrobial agent.

Conflict of interest: None.

REFERENCES

Aparna, R.N., Eswara Prasad, P., Padmaja, K. and Adilaxmamma, K. (2018). Evaluation of wound healing efficacy of *Boswillia ovalifoliolata* mediated silver nano particles. The Blue Cross Book. 38: 60-63.

Archana, M., Khan, A. and Bharat, J.W. (2010). Antibacterial potential of *Thespesia populnea* (Linn.) Sol. ex Corr. leaves and its corresponding callus against drug resistant isolates. Indian Journal of Natural Products and Resources. 1: 444-449.

Aitken, S.L., Corl, C.M., Sordillo, L.M. (2011). Immunopathology of mastitis: Insights into disease recognition and resolution. Journal of Mammary Gland Biology and Neoplasia. 16: 291-304.

Bradley, A.J. (2002). Bovine mastitis: An evolving disease. Veterinary Journal. 164: 116-128.

Besinis, A., De Peralta, T. and Handy, R.D. (2014). The antibacterial effects of silver, titanium dioxide and silica dioxide nanoparticles compared to the dental disinfectant chlorhexidine on Streptococcus mutans using a suite of bioassays. Nanotoxicology. 8: 1-16.

Chaitanya, K.T.V., Muralidhar, Y., Prasad, P.E., Prasad, T.N.V.K.V and Alpha Raj, M. (2013). Evaluation of therapeutic potential of nanosilver particles synthesised using aloin in experimental murine mastitis model. IET Nanobiotechnology. 7: 78-82.

Chandler, R.L. (1970). Ultrastructural pathology of mastitis in the mouse: A study of experimental staphylococcal and streptococcal infections. British Journal of Experimental Pathology. 51: 639-645.

Chinchali, J.F. and Kaliwal, B.B. (2014). Effect of mastitis on mammary gland biochemical and oxidative stress parameters in experimentally induced lactating mice. Indo American Journal of Pharmacetical Research. 4: 1607-1614.

Dizaj, S.M., Lotfipour, F., Barzegar-Jalali, M., Zarrintan, M.H. and Adibkia, K. (2014). Antimicrobial activity of the metals and metal oxide nanoparticles. Materials Science and Engineering: C. 44: 278-284.

Geng, H., Zou, W., Zhang, M., Xu, L., Liu, F., Li, X. and Xu, Y. (2020). Evaluation of phage therapy in the treatment of *Staphylococcus aureus*-induced mastitis in mice. Folia Microbiologica. 65: 339-351.

Heinrich, P.C., Behrmann, I., Müller, N.G., Schaper, F. and Graeve, L. (1998). Interleukin-6-type cytokine signalling through the gp 130/Jak/STAT pathway. Biochemical Journal. 334: 297-314.

Jayasri, A., Prasad, P.E., Padmaja, K., Kalakumar, B., Gnanaprakash, M., Adilakshmamma, K. and Prasad, T.N.V.K.V. (2019). Phytochemical analysis of methanolic leaf extract of *Thespesia populnea*. Journal of Pharmacognosy and Phytochemistry. 8(5): 2418-2421.

Kaoud, H.A. and Yosseif, S. (2013). Anolyte-the innovative method for the treatment of mastitis in dairy animals. The Journal of Veterinary Science. 114: 240-244.

Kinfe Kibebew. (2017). Bovine mastitis: A review of causes and epidemiological point of view. Journal of Biology, Agriculture and Healthcare. 7: 1-14.

Krishnamoorthy, P., Satyanarayana, M.L., Shome, B.R. and Rahman, H. (2018). Pathological changes in experimental intramammary infection with different Staphylococcus species in mice. Journal of Microscopy and Ultrastructure. 6(2): 93-98.

Krishnamoorthy, S., Raj, G.A. and Chandrasekaran, M. (2014). Antibacterial and antifungal activity of leaves of *Thespesia populnea*. International Journal of Pharmacy and Pharmaceutical Sciences. 6: 404- 411.

Krishnamoorthy, P., Suresh, K.P., Jayamma, K.S., Shome, B.R., Patil, S.S. and Amachawadi, R.G. (2021). An understanding of the global status of major bacterial pathogens of milk concerning bovine mastitis: A systematic review and meta-analysis (Scientometrics). Pathogens. 10: 545. https://doi.org/10.3390/pathogens10050545.

Lopez-Miranda, J. L., Molina, G.A., Gonzalez-Reyna, M.A., Espana-Sanchez, B.L., Espara, R., Silva, R. and Estevez, M. (2023). Antibacterial and anti-inflammatory properties of ZnO nanoparticles synthesized by a green method using sargassum extracts. International Journal of Molecular Sciences. 24: 1-15.

Morones, J.R., Elechiguerra, J.L., Camacho, A., Holt, K., Kouri, J.B., Ramírez, J.T. and Yacaman, M.J. (2005). The bactericidal effect of silver nanoparticles. Nanotechnology. 16: 2346-2353.

Muralidhar, Y., Alpha Raj, M., Prasad, T.N.K., Chaitanya Kumar, T.V., Adilaxmamma, K., Srilatha, C. and Aparna, N. (2017). Antibacterial, anti inflammatory and antioxidant effects of acetyl 11 α keto β boswellic acid mediated silver nanoparticles in experimental murine mastitis. IET Nanobiotechnology. 11(6): 682-689.

Nagajyothi, P.C., Cha, S.J., Yang, I.J., Sreekanth, T.V.M., Kim, K.J. and Shin, H.M. (2015). Antioxidant and anti-inflammatory activities of zinc oxide nanoparticles synthesized using *Polygala tenuifolia* root extract. Journal of Photochemistry and Photobiology B: Biology. 146: 10-17.

Naranjo-Lucena, A. and Slowey, R. (2022). Invited review: Antimicrobial resistance in bovine mastitis pathogens: A review of genetic determinants and prevalence of resistance in European countries. Journal of Dairy Science. 106: 1-23.

Naseer, M., Aslam, U., Khalid, B. and Chen, B. (2020). Green route to synthesize zinc oxide nanoparticles using leaf extracts of cassia fistula and melia azadarach and their antibacterial potential. Scientific Reports. 10: 1-10.

Ozkanlar, Y., Aktas, M.S., Kaynar, O., Ozkanlar, S., Kirecci, E. and Yildiz, L. (2012). Bovine respiratory disease in naturally infected calves: Clinical signs, blood gases and cytokine response. Revue de Medecine Veterinaire. 163: 123-130.

Paape, M., Mehrzad, J., Zhao, X., Detilleux, J. and Burvenich, C. (2002). Defense of the bovine mammary gland by polymorphonuclear neutrophil leukocytes. Journal of Mammary Gland Biology and Neoplasia. 7: 109-121.

Park, C., Lee, J., Kim, Y., Kim, J., Lee, J. and Park, S. (2017). 3D-printed microfluidic magnetic preconcentrator for the detection of bacterial pathogen using an ATP luminometer and antibody-conjugated magnetic nanoparticles. Journal of Microbiological Methods. 132: 128-133.

Prasannaraj, G., Sahi, S.V., Benelli, G. and Venkatachalam, P. (2017). Coating with active phytomolecules enhances anticancer activity of bio-engineered Ag nanocomplex. Journal of Cluster Science. 28: 2349-2367.

Sears, P.M. and McCarthy, K.K. (2003). Management and treatment of staphylococcal mastitis. Veterinary Clinics of North America, Food Animal Practice. 19: 171-185.

Seil, J.T. and Webster, T.J. (2012). Antimicrobial applications of nanotechnology: Methods and literature. International Journal of Nanomedicine. 7: 2767-2781.

Shah, A.S. and Alagawadi, K.R. (2011). Anti-inflammatory, analgesic and antipyretic properties of *Thespesia populnea* Soland ex. Correa seed extracts and its fractions in animal models. Journal of Ethnopharmacology. 137: 1504-1509.

Shekshavali, T. and Hugar, S. (2012). Antimicrobial activity of *Thespesia populnea* soland. excorrea bark extracts. Indian Journal of Natural Products and Resources. 3: 128-130.

Snedecor, G.W. and Cochran, W.G. (1994). Statistical Methods, 8th Edition, IOWA State University Press, Amer, IOWA, USA, 217-268.

Sree, V.P., Adilaxmamma, K., Raj, M.A., Muralidhar, Y., Eswara Prasad, P. and Prasad, T.N.V.K.V. (2016). Evaluation of the wound healing efficacy of chemical and phytogenic silver nanoparticles. IET Nanobiotechnology. 1: 1-9.

Sundrarajan, M., Ambika, S. and Bharathi, K. (2015). Plant-extract mediated synthesis of ZnO nanoparticles using *Pongamia pinnata* and their activity against pathogenic bacteria. Advanced Powder Technology 26: 1294-1299.

Suresh, G., Gunasekar, P.H., Kokila, D., Prabhu, D., Dinesh, D., Ravichandran, N. and Siva, G.V. (2014). Green synthesis of silver nanoparticles using *Delphinium denudatum* root extract exhibits antibacterial and mosquito larvicidal activities. Spectrochimica Acta Part A: Molecular and Biomolecular Spectroscopy. 127: 61-66.

Taifa, S., Muhee, A., Bhat, R.A., Nabi, S.U., Roy, A., Rather, G.A. and Mallick, J. (2022). Evaluation of therapeutic efficacy of copper nanoparticles in *Staphylococcus aureus*-induced rat mastitis model. Journal of Nanomaterials. 2022: 1-12.

Thakur, M., Prasad, H., Samanta, A.K. and Kalia, A. (2022). Herbal essential oils along with its amelioration with silver nanoparticles for curing the canine demodicosis. Indian Journal of Animal Research. 56(11): 1402-1406.

Yadav, E., Singh, D., Yadav, P.K. and Verma, A. (2018). Ameliorative effect of biofabricated ZnO nanoparticles of *Trianthema portulacastrum* Linn. On dermal wounds *via* removal of oxidative stress and inflammation. Frontiers in Pharmacology. 9: 1-18.

Yazar E, Bas, A.L., Birdane, Y.O., Yapar, K., Elmas, M. and Tras, B. (2012). Determination of intracellular (neutrophil and monocyte) concentrations of free and liposome encapsulated ampicillin in sheep. Veterinarni Medicína. 51: 51-54.

Zaatout, N., Ayachi, A. and Kecha, M. (2020). *Staphylococcus aureus* persistence properties associated with bovine mastitis and alternative therapeutic modalities. Journal of Applied Microbiology. 129(5): 1102-1119.