RESEARCH ARTICLE Indian Journal of Animal Research, Volume 57 Issue 7: 915-921 (July 2023)

A Comparative Study of Conventional Suture and Stapler Anastomosis for Gastro-intestinal Surgery in Dogs

M. Gokulakrishnan[1], Ramya[2], Mohamed Ali[1]

10.18805/IJAR.B-5092

ABSTRACT

Background: Gastro-intestinal anastomosis is mostly performed to correct the gastro-intestinal surgical disorders like gastro-intestinal obstruction, abdominal trauma, perforated bowel, intussusception and intestinal neoplasia *etc*. In early periods conventional intestinal anastomosis was followed which evolved into a seromuscular pattern of suture technique in recent years. Stapled anastomosis have a higher tensile strength than sutured anastomosis, since they heal by primary intention with minimal inflammation. Taking above facts into consideration, this study was undertaken to compare the conventional suture with stapler anastomosis of gastro-intestinal surgery in dogs.

Methods: Clinical cases of dogs which were reported to Small Animal Out-Patient (Surgery Unit) of Madras Veterinary Teaching Hospital, Chennai, with the symptoms of gastro-intestinal obstruction due to multifactorial causes formed the study material that were randomly divided into two groups of 6 dogs each. Group I Cases were treated with conventional suture, Group II were treated with gastrointestional anastomosis staplers. Plain and contrast radiography, ultrasonography, intestional anastomosis time, resumption of oral feeding, matrix metalloproteinase were performed.

Result: Stapler technique was found to be superior, accurate and most effective than the conventional technique in terms of anastomotic constructing time, less bowel manipulation, tissue trauma, anaesthetic exposure, risk of peritoneal contamination, early resumption of gastro-intestinal motility and oral feeding, rapid healing at the anastomotic site and reduced hospital stay. Moreover the procedure was easy to perform and simple.

Key words: Anastomosis, Canine, Conventional suture, Gastro intestional surgery, Intestional, Staplers.

INTRODUCTION

Gastro-intestinal anastomosis is mostly performed to correct the gastro-intestinal surgical disorders like gastro-intestinal obstruction, abdominal trauma, perforated bowel, intussusception and intestinal neoplasia *etc*. Perforated gastro-intestinal tract, Chronic Inflammatory Bowel Disease and colonic cancer are the major indications for gastro-intestinal resection and anastomosis (Johnson *et al*., 2007). Conventional intestinal anastomosis dates back to 1000 B.C. the era of Sushruta, followed by Lembert 1826, who introduced the seromuscular pattern of suture technique. In recent years, most of the surgical gastro-intestinal anastomosis in human are performed with staplers. Stapled anastomosis have a higher tensile strength than the sutured anastomosis, since they heal by primary intention with minimal inflammation. In addition to the above, this type of anastomosis creates a larger intestinal luminal stoma when compared to the original (Ballantyne *et al*., 1985). Conventional suture results in post-operative illeus due to over manipulation, delays oral intake, healing and comparatively increases the surgical duration (Braga *et al*., 2001 and Vora *et al*., 2014). In comparison, Stapler technique takes less anastomotic construction time, minimal manipulation, haemorrhage, reduces risk of peritonitis and dehiscence. Taking above facts into consideration, this study was undertaken to compare the conventional suture with stapler anastomosis of gastro-intestinal surgery in dogs with following objectives.

[1]Department of Clinics, Madras Veterinary College, Chennai-600 007, Tamil Nadu, India.

[2]Department of Veterinary Surgery and Radiology, Madras Veterinary College, Chennai-600 007, Tamil Nadu, India.

Corresponding Author: M. Gokulakrishnan, Department of Clinics, Madras Veterinary College, Chennai-600 007, Tamil Nadu, India. Email: drgocool_vet@yahoo.co.in

How to cite this article: Gokulakrishnan, M., Ramya and Ali, M. (2023). A Comparative Study of Conventional Suture and Stapler Anastomosis for Gastro-intestinal Surgery in Dogs. Indian Journal of Animal Research. 57(7): 915-921. doi: 10.18805/IJAR.B-5092.

Submitted: 28-01-2023 **Accepted:** 24-04-2023 **Online:** 01-06-2023

MATERIALS AND METHODS

Clinical cases of dogs which were reported to Small Animal Out-Patient (Surgery Unit) of Madras Veterinary Teaching Hospital, Chennai, with the symptoms of gastro-intestinal obstruction due to multifactorial causes formed the study material from 2019-21. The inclusive criterias were gastro intestional obstruction due to foreign bodies, intussuception, gastrointestional tumors with exclusion of peritonitis induced due to G.I. rupture, gastric dilatation and volvulus. A written medical consent was obtained from the owners preoperatively. Twelve cases selected for the study were randomly divided into two groups of six dogs each. Group I cases were treated with conventional suture, Group II were

treated with gastrointestional anastomosis- staplers. Routine pre and post operative hemato-biochemical profiles were performed.

Plain and contrast radiograph

Plain radiographs of lateral and dorsoventral view of the abdomen were taken pre-operatively to rule out gastro-intestinal foreign bodies and post-operatively on 5th day to asses anastomotic leakage in all the cases. Any ground glass appearance in the abdomen radiograph was classified as cases with peritonitis due to leakage from the intestional anastomosis. Contrast radiography was done with Barium sulphate at the dose rate of 10 ml/kg body weight to diagnose radiolucent foreign bodies pre-operatively as described by Orsher and Rosin (1993) Chiang and Chou *et al*. (2005).

Ultrasonography

Ultrasonography was performed to diagnose the gastro-intestinal foreign bodies, intussusception, tumour pre-operatively and to assess gastro-intestinal motility post-operatively on 4th day.

The time taken to perform intestinal anastomosis excluding the ligation of arcadian blood vessels were recorded for all cases. Post-operative convalescent time (duration from day of surgery to discharge) was recorded in both the groups for all cases. Resumption of oral feeding (hours) after surgery as reported by the owners in both groups.

Estimation of matrix metalloproteinase 13 (MMP 13)

Whole blood sample were collected post-operatively on (3rd, 5th and 7th day) for assessment of anastomotic healing in group I and group II.

Surgical technique

Conventional enterectomy and enteroanastomosis

Diseased or inflammed part of intestine was exteriorized and isolated from the abdomen. The intestinal contents (chime) were gently milked away from the inflamed part of the intestine. A non-crushing Doyens intestinal forceps was used to occlude the lumen of both the ends of the proposed enterectomy site. Intestinal viability was assessed by visualising the colour, peristaltic motility and arterial pulsation to determine the amount of intestine to be resected. Arcadian mesenteric vessels from the cranial mesenteric artery which supplied to the intestine were double ligated and transected using PGA 2-0. Terminal arcadian vessels and vasa recta vessels within the mesenteric fat at the place of the resected intestine was double ligated from the diseased bowel site. The diseased intestine was transected using scalpel (or) Metzenbaum scissors. A wide perpendicular (or) oblique incision at least 8cm in length was made on either sides for resection of intestinal tumour. Incised portion of the intestine was anastomosed using PGA 4-0 absorbable suture with swaged-on taper point needle. Intestinal anastomosis suture, started from the mesenteric border with single knot and another knot placed at the antimesentric border. Simple interrupted sutures were placed through all the layers of the intestinal wall not more than 2-3 mm apart. The knots were placed extraluminally (Fig 1, 2) in order to appose the edges of intestine as described by Nash (2006). The anastomotic site and the abdominal cavity was lavaged with one liter of warm NS and 100 ml of warm metronidazole. Routine closure of ventral midline coeliotomy incision was apposed with three layer closure.

Gastro-intestinal anastomosis using gastro intestinal anastomosis directional stapling (dst) technique linear cutter stapler

Gastro intestinal anastomosis (GIA) Directional Stapling Technique (DST) with linear cutter stapler. The GIA™ 60 stapler of 60 mm length which had reloadable titanium nonmagnetic staples placed in two double staggered rows was used in the present study (Mortenson and Ashraf, 2008).

GIA-DST cartridge

A 3.8 mm size disposable cartridge was used in the present study for stapling (Fig 3).

Surgical technique

For all cases in group II, entero-anastomosis was performed using GIA Linear cutter stapling gun using disposable



Fig 1: Conventional method of anastomosis.

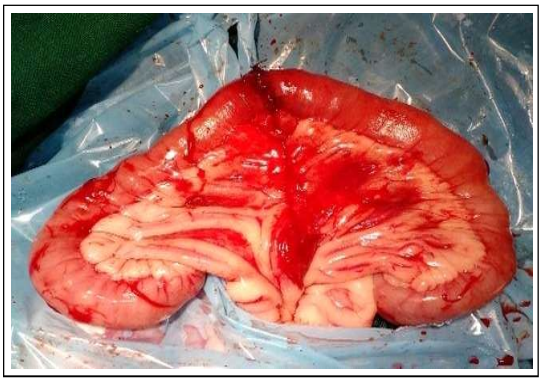

Fig 2: Simple interrupted pattern with knots positioned extraluminally.

reloaded stapling units (Multifire 3.8 mm GIA 60 Covedien). After the arcadian vessels was ligated, diseased (or) inflammed part of the intestine was transected. Each limb of the stapler was placed into each bowel (Fig 4); which created a stoma by dividing the anastomosed bowel between the two double staple lines. The stoma was examined for presence of haemorrhage (Fig 5). Stapled stoma was lifted for positioning the open lumen for next firing. The used staple cartridge from the gun was discarded and reloaded with a new cartridge. The forks of the stapler was positioned around the anastomosed bowel at 90 degree to its long axis and adjacent to its opening (Fig 6). The two limbs of the stapler were aligned and locked to ensure that the previously stapled edges of intestine were separated by atleast 1 cm (White 2008) (Fig 7). The anastomosis was completed after firing the stapler. The anastomosed staple line was examined for the evidence of haemorrhage (or) deployment (F) failure (Fig 8a, b). The anastomotic site and the abdominal cavity was lavaged with warm normal saline and 100 ml of warm Metronidazole. Routine closure of ventral midline coeliotomy incision was apposed with three layer closure.

RESULTS AND DISCUSSION

Among the 12 dogs in the clinical study the aetiology for gastro-intestinal obstructions were found to be linear foreign bodies (3), stone (3), intestinal tumour (2), intussusception (2), kernel (mango seed) (1) and megacolon (1). Among the 12 dogs which were operated during the study period, highest incidence of location of gastro-intestinal obstructions were observed in jejunum (33.33%) followed by ileocaecal (25.02%), duodenum (16.66%) and caecocolic, colon and stomach (8.33%). Plain radiograph was taken on 5th day post-operatively, to ascertain peritonitis due to anastomotic leakage in all cases and to visualise stapler pins (Fig 9, 10). Intestinal leak with peritonitis was observed in 2 dogs in conventional suture group which was depicted with diffuse ground glass appearance with loss of serosal details. Whereas no leakage was noticed stapled group. Intestinal anastomotic leakage of clinical suspicion were significantly higher in conventional suture group than the stapler group as also reported by Docherty *et al*. (1995): George (1991); Kracht *et al*. (1993).

3 cases of radiolucent linear foreign body, 2 cases of intestinal tumours and 1 case of megacolon were diagnosed through contrast radiograph. Kracht *et al*. (1993);

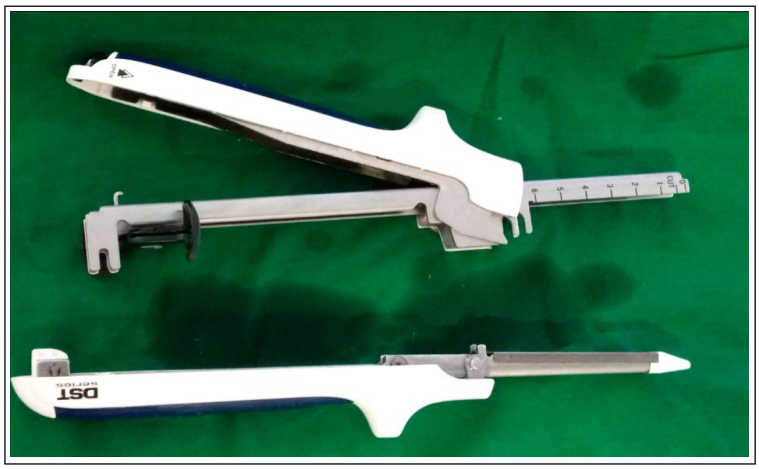

Fig 3: DST series GIA (Gastrointestinal Anastomosis Stapler).



Fig 4: Each limb of the stapler was placed into each bowel.

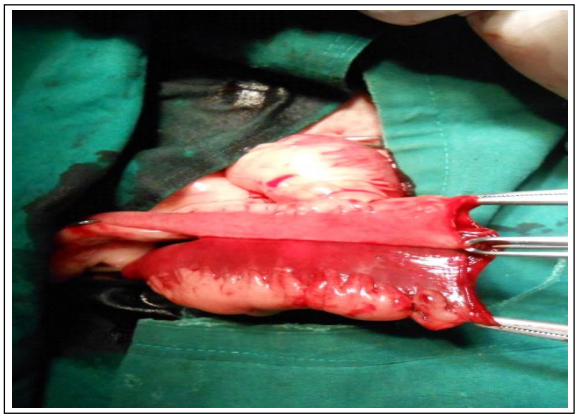

Fig 5: Stoma looked for haemorrhage.

Moran (1996) used contrast radiography and observed asymptomatic true radiological leakage in the stapled and sutured anastomotic patient (Table 1).

Table 1: Incidence of gastrointestinal foreign bodies (2019-21).

Incidence of GI FB	Total no. of. dogs	Dogs with GI FB
Numbers	10,260	76
Percentage (%)	100%	0.74%

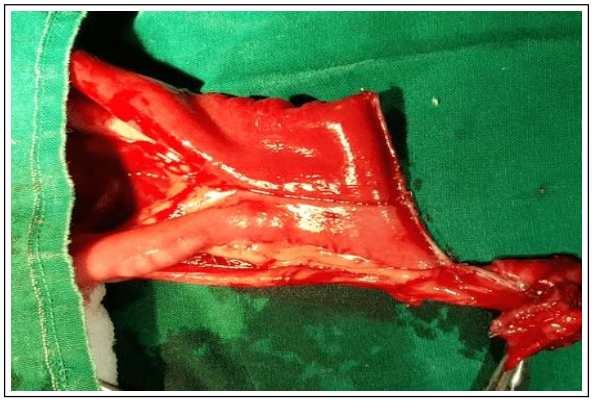

Fig 7: Stapler fired resulting the complete anastomosis.



Fig 6: Stapler fired resulting the complete anastomosis.

Ultrasound guided gastro-intestinal motility was observed 4th post-operative day in all cases to rule out any leakage and post healing complications, if any (Fig 11, 12). The mean±SE for time taken for the return of gastro-intestinal motility in suture group was 4.67±0.61 days and 3.33±0.33 days in stapler group. A statistically significant decrease was observed in stapler group compared with the suture group. A highly significant decrease ($p<0.05$) in time taken for anastomosis in stapled group compared with suture group was observed which concurred with the findings of Vora *et al*. (2014); Bin-wei Liu *et al*. (2014); Thakor *et al*. (2014).

Stapled method reduced the operating time, surgical trauma, intra-operative blood loss, minimized bowel manipulation, risk of peritoneal contamination and anaesthetic cost in the present study which was similar to the findings of Azevedo *et al*. (2008). A highly significant decrease ($p<0.05$) in post-operative convalescent time for stapled method was observed when compared to suture method which concurred with the findings of Weijan and Jianrong (2006). There was highly significant decrease in the time taken for resumption of oral feeding in stapled method ($p<0.05$), which coincided with the findings of Damesha *et al*. (2008). Less manipulation of bowel, anastomotic time, surgical trauma, anesthetic exposure and risk of peritoneal contamination reduced the time taken for resumption of oral feeding in stapled method (Table 2) as also observed by (Nichkaode *et al*., 2013). Antibiotic Sensitivity Test was performed on anastomotic leak fluid of 33% cases of group I which were found to be positive for peritonitis based on clinical symptoms and confirmation by abdominal radiograph. Cefotaxime and Gentamicin drugs were found sensitive and the same antibacterial were used for treatment at dose rate of 20 mg/kg i.v and 4 mg/kg i.m respectively for seven days post-operatively which were also opined to be effective by Papazoglou *et al*. (2001) Stapler anastomosis showed no complications even in

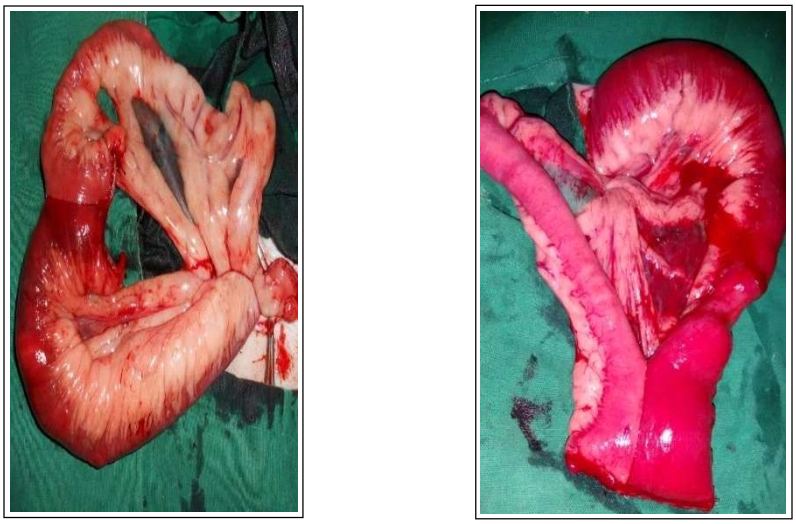

Fig 8a,b: Anastomosed staple line examined for haemorrhage (or) deployment (f) failure.

presence of confirmed bacterial peritonitis which was similar to the study of White *et al*. (2008). The level of MMP 13 negatively correlated with intestinal anastomotic wound healing. Progressive significant decline MMP 13 value on group II indicate rapid healing at the intestinal anastomotic site. The mean±SE of MMP 13 on 3rd, 5th and 7th day post-operatively were 0.065, 0.062, 0.060 in conventional suture group and 0.071, 0.042, 0.033 are in the stapler group (Table 3, 4).

These were in concurrence with the findings of Witte *et al*. (1998) who also demonstrated negative correlation between acute wound healing and MMP activity. Vagholkar (2001) reported that the MMP activity increased throughout the gastro-intestinal tract after transection and re-anastomosis by hand sewn suture method and Krarup *et al.* (2013) concluded that selective MMP inhibition enhanced anastomotic strength in colonic anastomotic site.

Jiborn *et al*. (1978) studied experimentally the effect of suture technic on collagen concentration in the colonic wall and concluded that collagen concentration was temporarily decreased close to anastomotic site which correlated with the results in the present study. MMPs has an important

Table 2: Post-operative parameters.

Parameters	Group-I	Group-II
	Mean±SE	Mean±SE
Time taken for intestinal anastomosis (Minutes)	33.33±6.30[a]	4.67±0.24[b]
Ultrasound guided GI motility (Days)	4.67±0.61[a]	3.33±0.33[b]
Post operative convalescent time (Days)	4.50±2.10[a*]	1.67±0.54[b**]
Resumption of oral feeding (Hours)	76.00±7.37[a]	32.00±5.05[b]

Table 3: Matrix metalloproteinase 13 (MMP 13) Analysis.

MMP13	Group I	Group II
3rd day	0.065	0.071
5th day	0.062	0.042
7th day	0.060	0.033

Table 4: Matrix metalloproteinase 13 (MMP 13).

Parameter	Group I	Group II
Estimation of MMP13	0.07±0.01[a]	0.05±0.08[b]



Fig 9: Postoperative radiograph- no serosal detail indicates peritonitis.



Fig 10: Radioopaque intact staple pin.

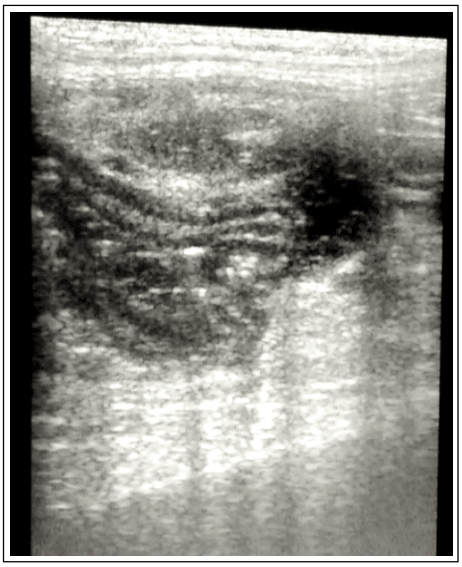

Fig 11: Ultrasound guided GI motility-contraction.

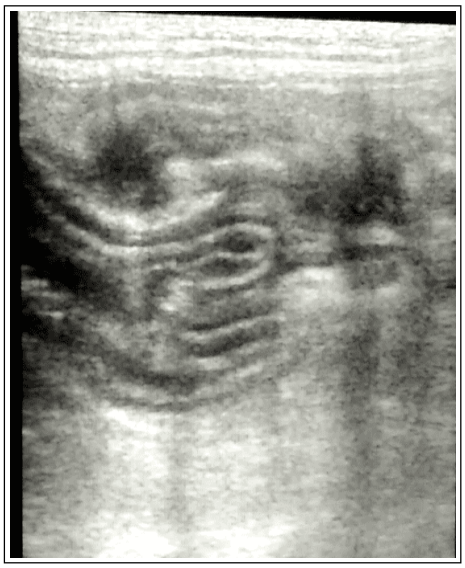

Fig 12: Ultrasound guided GI motility-relaxation.

role in the development, turnover and repair of different tissue Rawlings *et al*. (2012). During wound healing activation, MMPs was required for degradation of the provisional wound matrix thereby creating space for cell migration, angiogenesis and ECM remodelling. Since the stapler pins are made up of titanium which were non inflammatory, provided a high tensile strength and tissue holding capacity. It also reduced the trauma at the anastomotic site with less release of collagenase enzymes and resulted in less lytic action on the collagen (wound matrix) at the anastomotic site which led to reduction in rate of dehiscence and rate of leakage. Factors such as traumatic suturing, faecal contamination and infection all increased the amount of local collagenase produced at the wound and hence could increase the risk of infection.

CONCLUSION

The time taken for anastomosis in group I animal was significantly decreased when compared to suture group. A highly significant decreased post-operative convalescent time for stapled method was observed when compared to suture method.

Resumption of oral feeding for stapled method showed a statistically significant increase. An increase MMP activity was observed throughout the GI tract after resection and anastomosis by conventional suture method when compared to stapled method.

To conclude, stapler technique was found to be superior, accurate and most effective than the conventional technique in terms of anastomotic constructing time, less bowel manipulation, tissue trauma, anaesthetic exposure, risk of peritoneal contamination, early resumption of gastro-intestinal motility and oral feeding, rapid healing at the anastomotic site and reduced hospital stay. Moreover the procedure was easy to perform and simple.

On the economy aspect the stapler was more expensive than the suturing as this technique compensates the cost by reducing anaesthetic cost and hospital stay.

Conflict of interest: None.

REFERENCES

Azevedo, J.L.M.C., Hypolito, O., Azevedo, O.C., Becker, O.M. and Freire, D.F. (2008). Comparative Study of hand sewn single layer anastomosis of dogs bowel. Arq. Gastroenterol. 45(4): 319-322.

Ballantyne, G.H., Burke, J.B. and Rogers, G. (1985). Accelerated wound healing with stapled enteric suture lines. Ann. Surg. 201(3): 360-364.

Bin-wei, L., Yang, L., Jun-ru, L. and Zhong-xufeng, (2014). Comparison of hand Sewn and stapled anastomoses in surgeries of gastro-intestinal tumours based on clinical practice of Chinese surgeon. World Journal of Surg. Oncol. 12: 292 (1-6).

Braga, M., Gianotti, L., Gentilini, O., Parisi, V., Salis, C. and Di Carlo, V. (2001). Early post-operative enteral nutrition improves gut oxygenation and reduces costs compared with total parenteral nutrition. Crit. Care. Med. 29: 242-248.

Chiang, K.H. and Chou, A.S.B. (2005). Imaging of a gastro-intestinal foreign body in a feline. A case report. Tzu. Chi. Med. Journal. 17(3): 187-189.

Damesha, N., Lubana, P.S., Jain, D.K. and Mathur, R. (2008). A Comparative Study of Sutured and Stapled Anastomosis in Gastro-intestinal Operations. The Internet Journal of Surgery. 15(2).

Docherty, J.G., McGregor, J.R., Akyol, A.M., Murray, G.D. and Galloway, D.J. (1995). West of Scotland and Highland Anastomosis study group comparison of manually constructed and stapled anastomoses of colorectal surgery. Annals of Surgery. 221(2): 176-184.

George, W.D. (1991). Suturing or stapling in gastro-intestinal surgery: A prospective randomized study'. Br. J. Surg. 78(3): 337-41.

Jiborn, H., Ahonenand, J. and Zederfeldt, B. (1978). Healing of experimental colonic anastomoses. The effect of suture technic on collagen concentration in the colonic wall. Am. J. Surg. 135(3): 333-340.

Johnson, C.S., Williams, A.J.F., Reimer, S.B., Lotsikas, R.J. and Haynes, J.S. (2007). Fibrosing gastro-intestinal leiomyositis as a cause of chronic intestinal pseudo-obstruction in an 8 month old dog. Vet. Pathol. 44: 106-109.

Kracht, M., Hay, J.M., Fagniez, P.L. and Fingerhut, A. (1993). Illeocolonic anastomosis after right hemicolectomy for carcinoma: stapled or hand sewn? A prospective, multicenter randomized trial. Int. J. Colorectal Dis. 8: 29-33.

Krarup, P.A., Eld, M., Heinemeier, K., Jorgensen, L.N., Hansen, M.B. and Ågren, M.S. (2013). Expression and inhibition of matrix metalloproteinase (MMP)-8, MMP-9 and MMP-12 in early colonic anastomotic repair. International Journal of Colorectal Disease. 28(8): 1151-1159.

Moran, B.J. (1996). Stapling instruments for intestinal anastomosis in colorectal surgery. British Journal of Surgery. 83: 902-909.

Mortensen, N.J. and Ashraf, S. (2008). Intestinal anastomosis. ACS Surgery Principles and Practices. Decker Inc.

Nash, T. (2006). Gastro-Intestinal Foreign body management. Banfield. 16(6): 34-48.

Nichkaode, P.B., Kulshrestha, M., Akhtar, M.A., Gurjar, G. and Zamad, R. (2013). Comparative study of stapler anastomosis over hand sewn anastomosis in elective gastro-intestinal surgeries. Journal of Evolution of Medical and Dental Sciences. 2(19): 3408-3415.

Orsher, R.J., Rosin, E. (1993). Small Intestine In: Textbook of Small Animal Surgery-Slatter (2nd edn.), Saunders, W.B. Philadelphia. 2: 593-612.

Papazoglou, L.G. and Rallis, T. (2001). Diagnosis and surgical management of septic peritonitis in the dog and cat. Waltham Focus. 11: 09-14.

Rawlings, N.D., Barrett, A.J. and Bateman, A. (2012). MEROPS: The database of proteolytic enzymes, their substrates and inhibitors. Nucleic Acids Res. 40(1): 343-50.

Thakor, R.B., Kansal, S.S. and Salecha, P.A. (2014). A comparative study of hand suture verses stapler anastomosis gastro-intestinal surgeries. National Journal of Medical Research. 4(4): 354-356.

Vagholkar, K.R. (2001). Healing of Anastomosis in the Gastro-intestinal Tract: Retrospective Study of 35 Cases. The Bombay Hospital Journal. 43(2): 1-11.

Vora, D., Dave, R. and Shah, N. (2014). Comparative study of gastro -intestinal anastomosis stapler verses suture. Indian Journal of Applied Research. 4: 348-350.

White, R.N. (2008). Modified functional end to end stapled intestinal anastomosis: Technique and clinical results in 15 dogs. Journal of Small Animal Practice. 49: 274-281.

Weijan, W. and S. Jianrong, (2006). Comparative study of complications after mechanical suture and hand suture in surgical treatment of esophageal and gastric cardiac carcinoma. J. Regional. Anat. Operative. Surg. 15: 76-77.

Witte, M.B., Thornton, F.J., Kiyama, T., Efron, D.T., Schulz, G.S., Modalwar, L.L. and Barbul, A. (1998). Metalloproteinase inhibitors and wound healing: A novel enhancer of wound strength. 124(2): 464-470.