RESEARCH ARTICLE Indian Journal of Animal Research, Volume 57 Issue 11: 1485-1496 (November 2023)

Patho-morphological and Immunohistochemical Studies on Bovine Horn Core Carcinoma

Vivek Kumar[1], Dhananjay Kumar Jolhe[1], Ratan Chandra Ghosh[1], Rukmani Dewangan[2], Prashant M. Sonkusale[3], Sonu Sharma[4]

10.18805/IJAR.B-5206

ABSTRACT

Background: An investigation was carried out on twelve clinical cases of neoplasm of horn in Durg, Dhamtari and Rajnandgaon districts of Chhattisgarh, suspected of bovine horn core carcinoma (squamous cell carcinoma) revealed the cytology, pathomorphology and immunohistochemical (IHC) expression of Pan-cytokeratin (Pan- CK), p53 gene, epidermal growth factor receptor (EGFR) and p16 gene in tumourous growth at horn in bovines.

Methods: In this field-laboratory investigation conducted during January to June 2022, we explicate the cytological, pathological and immunohistochemical alterations in bovine horn core carcinoma from 12 tissue samples. Cytological studies includes special papaniculaou staining and immunohistochemistry was performed through Benchmark automated staining system.

Result: Eight out of 12 cases (66.66%) were confirmed as SCC of horn on the basis of histopathological and immunohistochemical analysis. Papanicolaou staining revealed variation in shape and size of cells and altered nuclear details. Grossly unilateral large cauliflower like neoplastic growth at the base of the horn was observed. Differentiation of tumours were based on histopathology and Immunohistochemistry. Well differentiated SCCs (n=4; 50%) were characterized by severe keratinization of horn epithelium with concentric arrangement forming keratin pearls also called as “cell nests”. Moderately differentiated SCCs (n=2; 25%) characterized by small keratin pearl formations and mitotic figures. Poorly differentiated SCCs of horn (n=2; 25%) revealed absence of distinctive keratin pearls although deep invasion from primary site was observed. Tissue samples revealed strong immunohistochemical staining of Pan-CK, p53 and EGFR and negative to p16. Highest immunohistochemical expression was observed in Pan-CK which confirmed the tumours were of epithelial origin and EGFR immunoexpression was confirmatory for malignancy and degree of metastasis.

Key words: Cell nests, EGFR, Immunohistochemistry, Keratin, p16, p53, Pan-CK, Papaniculaou, Squamous cell carcinoma.

INTRODUCTION

Bovine horn core carcinoma also called as Squamous Cell Carcinoma (SCC) of horn is one of the most common cancer capable of metastatic spread and is observed in various forms across many animals (Yan *et al*., 2011; Tsujita *et al*., 2010). Squamous Cell Carcinoma of horn, also known as horn cancer, is a prevailing type of cancer in cattle especially *Bos indicus*. Horn cancer is generally unilateral and is encountered in cattle between 5-10 years of age (Tyagi and Singh, 2006). In India, horn cancer affects approximately 1% of the cattle population and accounts for 83.34% of total tumours reported (Singh *et al*., 2005). Horn cancer is a sporadic, malignant neoplasm affecting the horn core epithelium and predominantly seen in aged zebu bullocks and rarely in buffaloes (Somvanshi, 1991; Kumar and Thilagar, 2000). The bullocks appear to be highly susceptible as compared to bulls and cows. It is one of the most commonly encountered neoplastic conditions of economic importance in zebu bullock (Udharwar *et al*., 2008).

Cytokeratin is one of the most important tumour markers for diagnosis of squamous cell carcinoma, high variations in expression patterns of cytokeratin have been correlated to different pathways of epithelial differentiation leading to the accurate diagnosis and classification of tumours of epithelial origin into different subtypes by immuno histochemistry (Sharma *et al*., 2020). The expression of simple epithelial or non-cornifying stratified squamous

[1]Department of Veterinary Pathology, Dau Shri Vasudev Chandrakar Kamdhenu Vishwavidyalaya, Anjora, Durg-491 001, Chhattisgarh, India.

[2]Department of Veterinary Surgery and Radiology, Dau Shri Vasudev Chandrakar Kamdhenu Vishwavidyalaya, Anjora, Durg-491 001, Chhattisgarh, India.

[3]Department of Veterinary Pathology, Nagpur Veterinary College, Maharashtra Animal and Fisheries Science University, Nagpur-440 007, Maharashtra, India.

[4]Dr. Lal Path Labs, Path Vets Veterinary Diagnosis, Chittranjan Park, New Delhi-110 019, India.

Corresponding Author: Vivek Kumar, Department of Veterinary Pathology, Dau Shri Vasudev Chandrakar Kamdhenu Vishwavidyalaya, Anjora, Durg-491 001, Chhattisgarh, India.
Email: vk561997@gmail.com

How to cite this article: Kumar, V., Jolhe, D.K., Ghosh, R.C., Dewangan, R., Sonkusale, P.M. and Sharma, S. (2023). Patho-morphological and Immunohistochemical Studies on Bovine Horn Core Carcinoma. Indian Journal of Animal Research. 57(11): 1485-1496. doi: 10.18805/IJAR.B-5206.

Submitted: 26-07-2023 **Accepted:** 10-08-2023 **Online:** 13-09-2023

epithelial cytokeratins in cutaneous SCCs may be a marker for their capability of invasion and metastatic potential (Watanabe *et al*., 1995). Mutations in the p53 gene may cause cancer cells to grow and spread in the body. The inactivation of this gene possibly results in oncogenesis (Kumar *et al*., 2023). SCCs commonly have mutations in p53 and positive immunolabeling for p53 has been reported in animals especially in SCCs of non-pigmented skin secondary to exposure to UV radiation (Anderson *et al*., 1991). The tumour suppressor gene p16 has gained widespread importance in cancer, frequent mutations and deletions of p16 in human cancer cell lines first suggested an important role for p16 in carcinogenesis (Liggett *et al*., 1998). SCCs have been shown to express p16 through immunolabeling. Antibodies targeting p53 and p16 have been used as prognostic factors in SCCs. Epidermal Growth Factor Receptor (EGFR) is a key factor in epithelial malignancies and its activity enhances tumour growth, invasion and metastasis (Lakshmi *et al*., 2020). EGFR plays an important role in maintaining normal cell function, dysregulation of EGFR signaling towards malignancy due to effects on cell cycle progression, inhibition of apoptosis, induction of angiogenesis and promotion of tumour cell motility and metastasis (Lakshmi *et al*., 2020). Occurrence of horn core carcinoma is sporadic in field conditions in Chhattisgarh, so keeping that in view, the study was undertaken with the following objectives:

- To study the cytology and histopathology of horn core cacinoma in affected bovines.
- To detect horn core carcinoma through tumour biomarkers (Pan-CK, p53 gene, EGFR and p16 gene) using immunohistochemical technique.

MATERIALS AND METHODS

The study was conducted in the Department of Veterinary Pathology, College of Veterinary Science and Animal Husbandry, Dau Shri Vasudev Chandrakar Kamdhenu Vishwavidyalaya, Anjora, Durg (Chhattisgarh) to explicate the cytology, pathology and immunohistochemical alterations in Squamous Cell Carcinoma of horn in bovines. The samples were collected from various gaushalas, dairy farms, Teaching Veterinary Clinical Complex (TVCC, Durg), College of Veterinary Science, Anjora and Government Veterinary Hospitals (GVH) of Durg, Dhamtari and Rajnandgaon districts of Chhattisgarh (Table 1). Tumour biomarkers such as p53 (Tumour suppressor gene), p16 (Tumour suppressor gene), Pancytokeratin (Pan-CK) and Epidermal Growth Factor Receptor (EGFR) in tissues were investigated by immunohistochemical technique. The study was conducted over a period of six months from January to June 2022. All the experimental procedures were carried out as per recommendations of the Institutional Animal Ethics Committee (IAEC).

Cytological studies

Cytology samples/tissue impression smears were processed and stained as per Papanicolaou staining procedure.

Papanicolaou staining

Staining techniques used to stain the cytological smears were as per the method by Papaniculaou and Traut, (1941).

Rapid-Pap nuclear staining

Papanicolaou staining was done using RAPID-PAP Kit. The staining procedure was followed as per manufacturer's instructions.

Papaniculaou staining (Pap EA-36 and Pap OG-6)

Papanicolaou's staining was used for cytological/ impression smears for cancer cells and stained for keratin as per the method prescribed by Doddagowda *et al*., (2017) and Raju, (2016).

Pathological studies

Gross pathology

Gross morphological features of tumours like location, shape, colour and consistency of the tumour were examined. Tumours observed at horn were suspected to have been squamous cell carcinomas on the basis of gross pathology. Unique case identity (Case ID) was given to each sample.

Histopathological examination

Tissue samples fixed in 10% formalin were processed for histopathological examination and stained as per standard H and E method of staining (Bancroft and Stevens, 1990). The sections were examined microscopically for histological changes.

Immunohistochemical studies

Preliminary diagnosis of squamous cell carcinoma was made on the basis of clinical examination and gross findings. Histopathological examination of twelve samples suspected of bovine horn core carcinoma, out of which eight selected tissue samples evident of the tumour were processed for immunohistochemistry (IHC) to detect biomarkers such as Pan-Cytokeratin (Pan-CK), p53, Epidermal Growth Factor Receptor (EGFR) and p16 with malignancy of tumours with reference to Kumar *et al*., (2023) at Dr Lal PathLabs, PathVets Veterinary Diagnosis, Chittranjan Park, New Delhi.

Tissue processing for immunohistochemical staining

Paraffin embedded tissues were sectioned in rotary microtome for further processing according to the protocol adopted by Fornazari *et al*. (2017).

Immunohistochemical staining

Deparaffinization, antigen retrieval and immunolabeling of sections were carried out in automated immunostainers. Immunohistochemical labeling for all markers (p53, p16, Pan-CK and EGFR) were carried out on the Bench Mark

Automated Staining System (Ventana Medical systems, Inc.). The antigen retrieval was performed for 60 minutes using Ventana Medical Systems Retrieval Solution CC1 according to the method prescribed by Fornazari *et al*. (2017) (Table 2).

Immunohistochemical Scoring (IHS)

Immunohistochemical scoring was performed by estimating the percentage of positive cells and labeling intensity given in Table 3 as per the method described by Baghla *et al*., (2012).

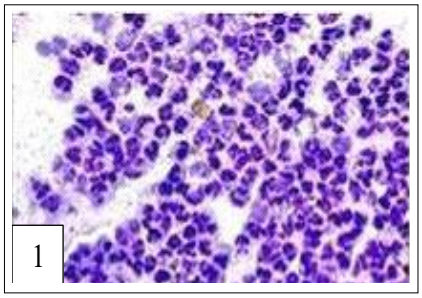

Fig 1: Hyperchromatic and pleomorphic tumour cells (Rapid PAP × 400).

RESULTS AND DISCUSSION

Cytological study

Cytological examination of tumours by rapid Papanicolaou nuclear staining revealed variation in shape and size of cells, as well as altered nuclear details (Fig 1 and 2). Papaniculaou (EA-36 and OG-6) stained cells from malignant tumours revealed pleomorphism, characterized by significant variation in shape of the cells and anisocytosis in SCC of horn (Fig 2), cluster of cells with great variation in cell sizes (Fig 3). Other major findings observed were anisokaryosis, characterized by variation in the size of the nucleus, multinucleated cells (Fig 3 and 4) with minute deep-purple granules seen in the cytoplasm (Fig 4).

Cytological findings such as hyperchromasia, anisonucleosis and multinucleated cell formation were in accordance with Hoffmann *et al*. (1978) and increased

Table 1: Details of collected samples suspected of bovine horn core carcinoma from different districts of Chhattisgarh.

Case ID	Age	Sex	Breed	Location of neoplasm	District
BovHC1	7 years	F	Kosli	Base of right horn	Dhamtari
BovHC2	6 years	F	Haryana	Base of right horn (unilateral), extending deep to frontal sinus	Dhamtari
BovHC3	4 years	F	Non-descript	Base of left horn, extending to frontal sinus and skull	Durg
BovHC4	10 years	M	Non- descript	Base of left horn	Dhamtari
BovHC5	9 years	M	Non- descript	Base of right horn	Durg
BovHC6	8 years	M	Non-descript	Base of right horn	Durg
BovHC7	7 years	M	Haryana	Base of right horn	Dhamtari
BovHC8	5 years	F	Non-descript	Base of left horn	Rajnandgaon
BovHC9	11 years	M	Kosli	Base of right horn	Rajnandgaon
BovHC10	8 years	F	Non-descript	Base of right horn	Durg
BovHC11	10 years	F	Non-descript	Base of left horn	Durg
BovHC12	2 years	M	Non-descript	Base of right horn	Durg

Table 2: Tumour markers and primary antibodies used in immunohistochemistry.

Tumour markers	Antibody	Clone	Catalogue no.	Make	Lab animal in which Ab raised with Ig class	Volume
Pan- Cytokeratin (Pan-CK)	Cytokeratin pan plus	AE1 and AE 3	MSG09 8	Zytomed system GmBH, Anhaltiner- stranbe 16, 14163 Berlin, Germany	N/A	6 ml Conc., RTU
p53	Anti- p53	D07	AM239-10 M	BioGenex Lab., Fremont, California (CA 94538) USA	Mouse, Ig class: IgG1	10 ml, RTU
Epidermal growth factor receptor (EGFR)	Anti-EGFR	Polycl-onal	AM335-10 RE	BioGenex Lab., Fremont, California (CA 94538) USA	Rabbit, N/A	10 ml, RTU
p16	Anti- p16	G175- 405	AM540-10 M	BioGenex Lab., Fremont, California (CA 94538) USA	Mouse, Ig class: IgG	10 ml, RTU

RTU: Ready to use, N/A: Not available.

nuclear- cytoplasmic ratio and deep purple granules in the cytoplasm of cells in SCC were also reported by Garma-Avina, (1994).

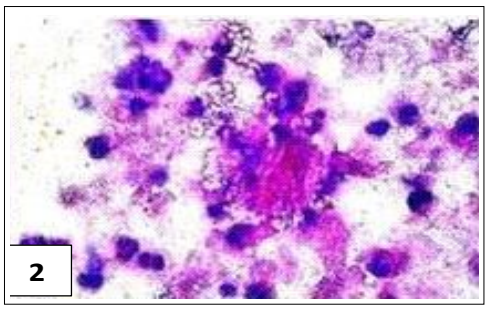

Fig 2: Significant pleomorphic cells and anisocytosis in SCC of horn (PAP EA-36 and OG-6 × 1000).

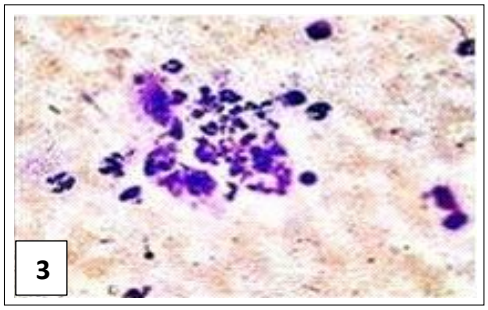

Fig 3: Cluster of cells with great variation in cell sizes (Pap EA-36, OG-6 stain × 1000).

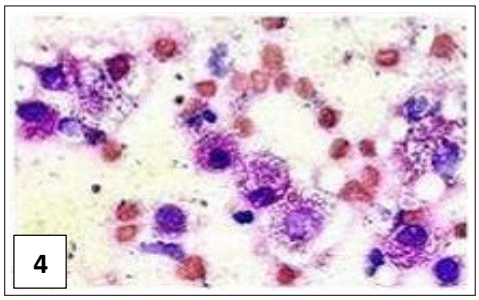

Fig 4: Large sized tumour cells with giant nucleus (megakaryosis) in OSCC (BovEC3; Pap EA-36, OG-6 stain × 1000).

Gross pathology

A total of twelve unilateral neoplastic growths at horn suspected of SCC were examined grossly, which revealed large, irregular masses at the base of horn. Cauliflower like growth at the base of horn were observed in most of the cases (n=9; Fig 5, 6 and 7). Two cases of large cauliflower like mass of about 20 cm diameter were seen (Fig 5b and 7). Cut surfaces of tumours were whitish yellow, greyish white, greyish red to light brown in colour with widespread haemorrhages and areas of necrosis (Fig 5b and 7). Surface of most tumours were rough and verrucous (Fig 8) with poor demarcation. Ulcerative masses with foul smelling purulent discharge were also observed in few cases (Fig 9).

Gross pathological findings of neoplasm of horn like unilateral growth observed in all cases examined was in accordance with Kalim *et al*. (2021), bleeding at the base of the horn were also reported by Giri *et al*. (2011), Kumar *et al*. (2013), Sharma *et al*. (2020) and Reddy *et al*. (2017). Foul smelling purulent discharge reported by Kumar *et al*. (2013). Poor demarcation of tumourous mass was reported by Baniadam *et al*. (2010).

Histopathology

Histopathological findings in SCC of horn were formation of numerous epithelial pearls with mineralization (Fig 10a), severe keratinization of horn epithelium with concentric arrangement forming keratin pearls also called as “cell nests” (Fig 10b). Large keratin pearl with numerous mitotic figures in moderately differentiated SCC (BovHC1; Fig 11). Characteristic epithelial pearl in well differentiated squamous cell carcinoma was observed (Fig 12b), Tumour islands of irregular shape were clearly observed in the horn epithelium invaded deep into dermis layer (BovHC3; Fig 12 a). More keratin deposition towards the center was observed in most of the cases of SCC of horn (Fig 12a and 17a). Distinctive epithelial pearls were clearly observed in tissue samples (BovHC3; Fig 12b, BovHC9; Fig 16b; BovHC6; Fig 17a; Fig 18 and 19). Hyperplasia of epidermis with hyperkeratosis and pleomorphic epithelial cells arranged as cords or islands with keratinized layer in centre (accumulated in concentric manner; Fig 10b and 13b). Distinctive keratin pearls were not seen in (BovHC2). Most severe haemorrhages were reported in BovHC4 (Fig 14). Moderately differentiated SCC



Fig 5: a); Large cauliflower like growth on the base of left horn in bullock (Case ID: BovHC4); b); Tumourous mass of about 20 cm diameter from the base of the horn in bullock (Case ID: BovHC4).



Fig 6: a); Large cauliflower like growth on left horn of cow (Case ID: BovHC3); b); Soft and friable cauliflower like growth at the base of left horn having rough and verrucous surface (BovHC3).



Fig 7: Large cauliflower like growth about 20 cm diameter on the base of right horn in bullock (Case ID: BovHC10).



Fig 8: Solid nodular growth at the base of horn with firm consistency having rough and verrucous surface (Case ID: BovHC11).



Fig 9: Firm nodular growth with foul smelling purulent discharge on the base of right horn (Case ID: BovHC2).

of horn was observed with presence of epithelial pearls (BovHC8; Fig 15). Layered keratinization was also observed in the present study (BovHC9; Fig 16). Non keratinizing type tumours were also seen and these cases were evident of squamous cell carcinoma (BovHC4). Numerous mitotic figures with variable number of nucleoli were observed (Fig 17b and 19), severe infiltration of inflammatory cells mostly neutrophils and lymphocytes in the stroma was also observed (Fig 17b). BovHC4 was established as poorly differentiated SCC however deep invasion from the primary site was observed.

Histopathological findings of the present study were consistent with the findings of earlier workers who had reported cell nests or keratin pearls in well differentiated squamous cell carcinoma of horn (Kalim *et al*., 2021; Sharma *et al*., 2020; Reddy *et al*., 2017; Kumar *et al*., 2013 and Joshi *et al*., 2009). Anaplasia and neovascularization observed in squamous cell carcinomas of horn were in accordance with (Sharma *et al*., 2020 and Giri *et al*., 2011).

Immunohistochemical study

Confirmation of horn core carcinoma was done by immunoexpression and Immunohistochemical scoring (IHS) (Table 4) Tissues were processed with 4 tumour markers (Pancytokeratin, p53, EGFR and p16) for the detection of degree of epithelial malignancy through immunoreaction of tumours to these markers.

Immunohistochemical scoring (IHS)

Interpretation of results (Table 3) was done on the basis of immunoreactivity which depends on the extent of immunoreactivity and immunohistochemical staining of tumour cells. Immunohistochemical scoring of different tumour markers for SCC of horn is given in Table 4.

Immunohistochemical findings

SCC of horn revealed strong immunohistochemical staining of Pan-CK (Fig 20, 21 and 22), p53 (Fig 30a and b), EGFR (Fig 28, 29a and b) and negative to p16 (Fig 33 and 34).

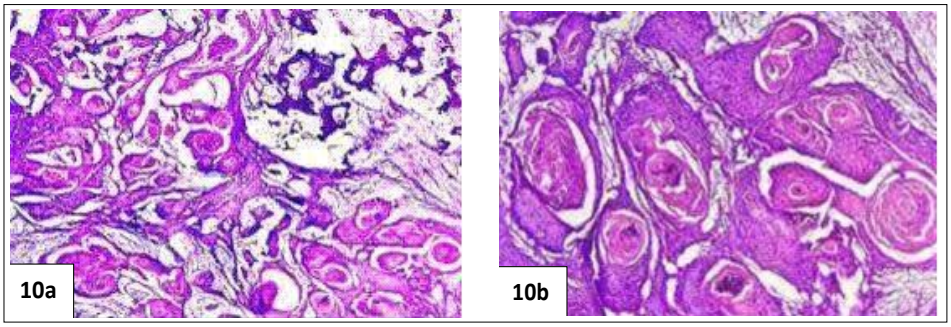

Fig 10: a); Well differentiated SCC of horn depicting formation of numerous epithelial pearls with mineralization (Case ID: BovHC6; H and E × 40).

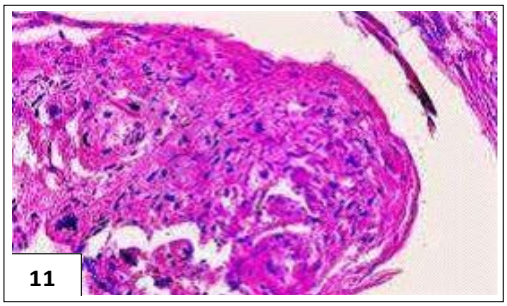

Fig 11: Moderately differentiated (Grade II) SCC showing large keratin pearl differentiated SCC (BovHC1; H and E × 100; 11 b) H and E × 400).

Immunohistochemical expression of pancytokeratin (Pan-CK) in bovine squamous cell carcinoma

Variations observed in the immunohistochemical reactivity of Pan-CK between SCC of horn in the present study. Most of the cases of SCC of horn showed positive Pan-CK immunoreactivity in >75% neoplastic cells and was given score of 4+ (BovHC3; Fig 20), 3+ (BovHC6; Fig 25). Well differentiated SCC of horn showed high cytoplasmic reactivity of Pan-CK in more than 50% of neoplastic cells. Pan-CK immunoexpression was more prominent in cell nests in well differentiated SCC of horn (Fig 21) and more intensely stained periphery/ border inside large keratin pearl (Fig 20), well differentiated SCC of horn depicted strong cytoplasmic

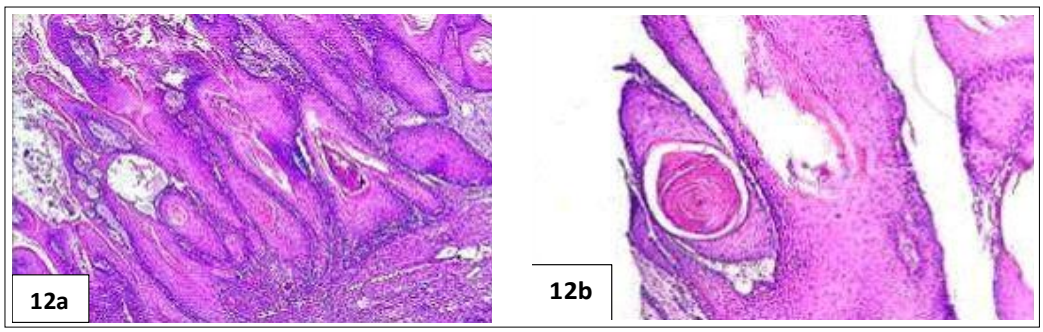

Fig 12: a); Grade III SCC of horn with irregular shaped tumour islands in the epidermis invading deep into dermis layer with keratin pearls (BovHC3; H and E × 100); b); Illustrating characteristic epithelial pearl of well differentiated squamous cell carcinoma (Case ID: BovHC3; H and E × 100).

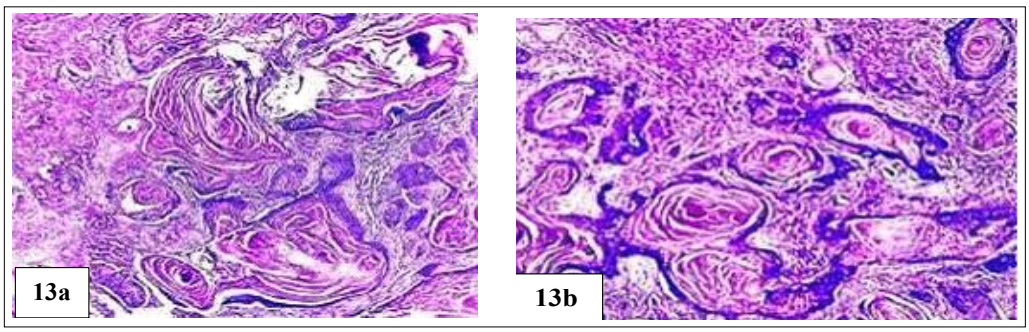

Fig 13: a); Multiple keratin pearls with formation of keratin microcyst in well differentiated SCC of horn (BovHC10; H and E × 100); b); Concentric keratin pearls in well differentiated SCC with mineralization (BovHC10; H and E × 100).

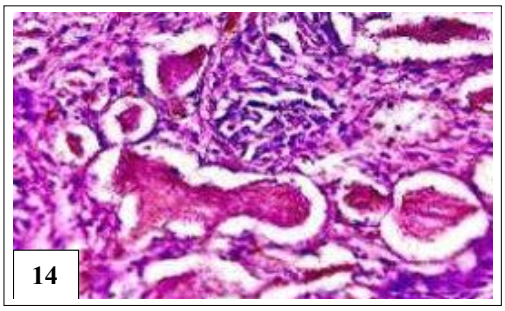

Fig 14: Poorly differentiated SCC of horn with severe haemorrhages (BovHC4; H and E × 400).

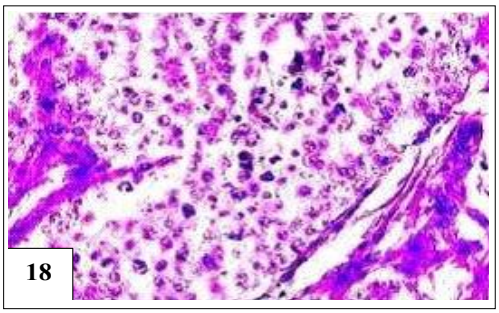

Fig 18: Moderately differentiated SCC with small keratin pearl (H and E X400) b) abundance of mitotic figures and cells exhibiting anaplasia.

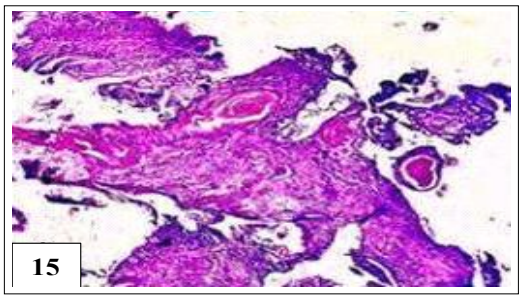

Fig 15: Moderately differentiated SCC of horn with presence of epithelial pearls (BovHC8; H and E × 100).

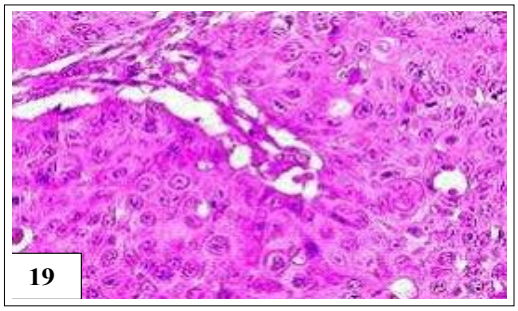

Fig 19: Poorly differentiated SCC of horn with anaplastic cells and mitotic figures (BovHC4; H and E × 400).

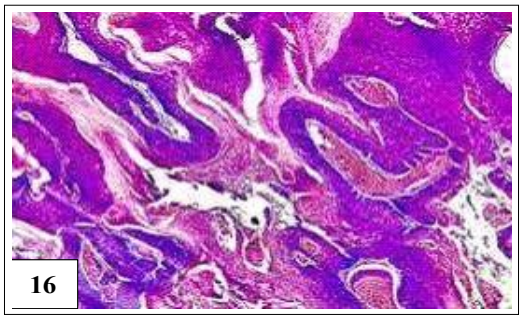

Fig 16: Well differentiated SCC of horn illustrating layered pattern of keratinization along with keratin deposition (BovHC9; H and E ×100).

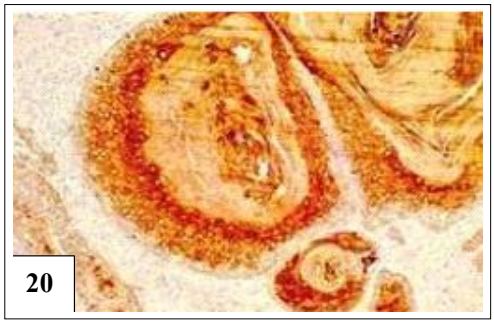

Fig 20: Very well differentiated SCC of horn with intense Pancytokeratin immunohistochemical staining with the score of 4+ (BovHC3; IHC × 100).

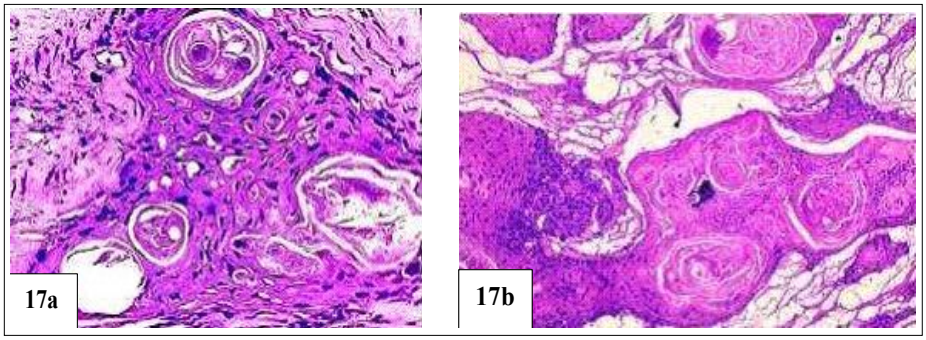

Fig 17: a); Well differentiated SCC of horn with keratin pearls as well as keratin cysts formation and numerous mitotic figures (BovHC6; H and E X 400); b); Showing large epithelial pearls with mononuclear cells infiltration (H and E × 100; BovHC6; H and E × 100).

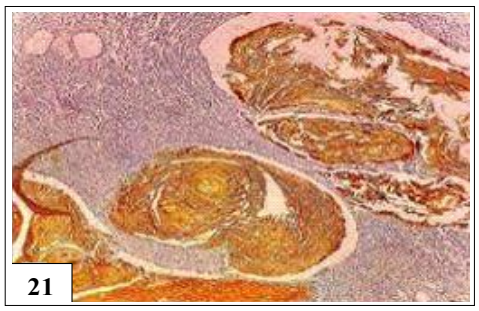

Fig 21: Pancytokeratin immunoexpression in cell nests in well differentiated SCC of horn (IHC × 400).



Fig 22: Intense staining of Pan-CK inside keratin pearls leaving the peripheral region around the pearls (IHC × 400).

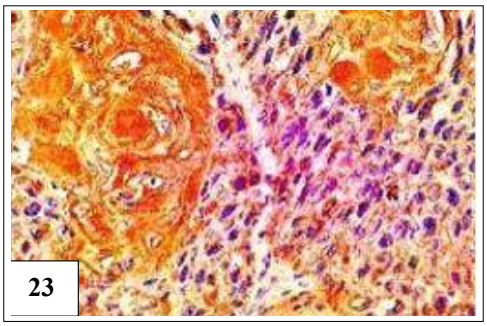

Fig 23: Strong Pan-CK immunoexpression inside the cell nest with 3+ score (BovHC10; IHC × 400).

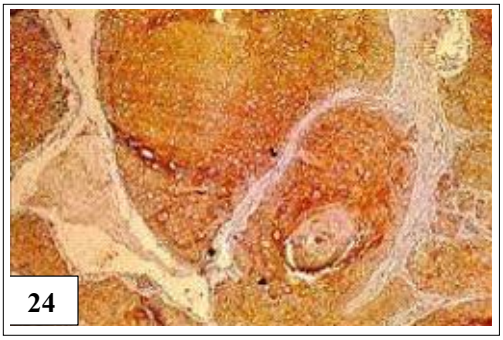

Fig 24: Well differentiated SCC of horn, strong Pan-CK immunoexpression inside keratin pearl with 3+ score; BovHC9; (IHC × 100).

staining in almost all neoplastic cells and was given the score of 4+ (Fig 20). Strong Pan-CK immunoexpression was observed inside the cell nest with 3+ score (BovHC10; Fig 23). Reddish brown staining of Pan-CK in layered keratinization and tumour islands of BovHC9 and strong Pan-CK immunoexpression inside keratin pearl with 3+ score were also found with clear demarcation observed (Fig 24 and 25). BovHC6 revealed strong Pan-CK immunoexpression showing distinctive staining in keratinized portion inside cell nests (Fig 25).

Immunohistochemical expression of EGFR in bovine squamous cell carcinoma

Variations among immunoreactivity towards EGFR were detected in the present study BovHC3 (Well differentiated SCC of horn) revealed strong immunopositive reaction against EGFR with the score of 4+ (Fig 26). Immunoexpression of EGFR was found in the surrounding tissue excluding large keratin pearls (BovHC3; Fig 27 and 29). BovHC4 revealed strong immunoreactivity towards EGFR with IHS of 3+ (Table 4) which signified highly malignant and invasive nature even after the absence of well differentiated epithelial pearls. mild immunexpression of EGFR was detected with 1+ score in BovHC10 (Fig 28).

Immunohistochemical expression of p53 gene in bovine squamous cell carcinoma

In the present study, Immunohistochemical reactivity scoring of p53 is based on number of positive tumour cells and intensity of staining of nuclei of tumour cells. Pattern of staining varied from moderate to intense. The concentration of p53 gene increased in response to the DNA damage inside the nucleus of tumourous cells and was responsible for its immunoexpression. Immunoexpression of p53 in tumour nuclei was more pronounced in well differentiated SCC of horn (Fig 30b). SCC of horn exhibited p53 nuclear staining of tumour cells with score of 4+ (BovHC3; Fig 30a and b) and scattered in connective tissue stroma and peripheral neoplastic cells of tumour islands (Fig 30a and 31a) showing intense nuclear staining of p53 with 4+ score (Fig 30b). One case of horn cancer (poorly differentiated) revealed high

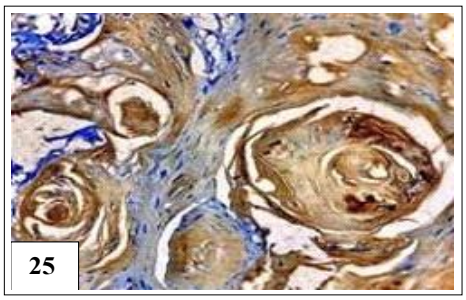

Fig 25: Well differentiated SCC of horn, strong Pan-CK immunoexpression showing distinct staining in keratinized portion inside cell nests (BovHC6; IHC × 400).



Fig 26: EGFR immunoexpression with intense staining of tumour islands showing score of 4+ (BovHC3; IHC × 100).

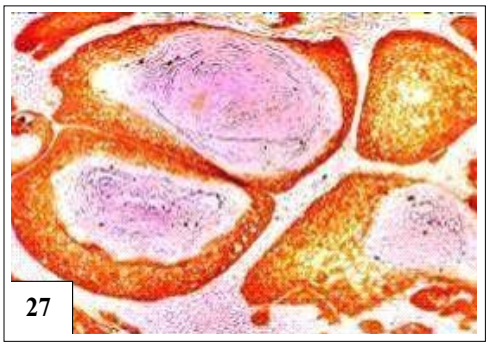

Fig 27: EGFR immunohistochemical staining in periphery of keratin pearls with absence of immunoexpression inside cell nests (BovHC3; IHC × 400).



Fig 28: Mild immunoexpression of EGFR with 1+ score (BovHC10; IHC × 400).

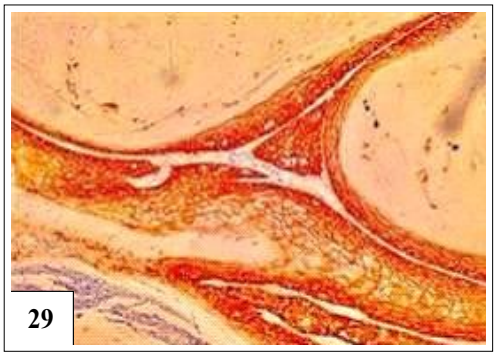

Fig 29: EGFR immunoexpression in the surrounding tissue excluding large keratin pearls (BovHC3; IHC × 400).

staining in more than 50% neoplastic cells in tumour islands (Fig 31a and b). Moderate immunoexpression of p53 in nuclei of tumour cells with 2+ score observed in BovHC6 (Fig 32a and b) and more immunoexpression was detected within the outer epithelial layer of keratin pearl (Fig 32a).

Immunohistochemical expression of p16 in bovine squamous cell carcinoma

Samples showed negative reaction/non-immunoreactive towards p16 (Fig 33 and 34) including both well differentiated (Fig 33a and b) and poorly differentiated SCC (BovHC4; Fig 34 and 35).

Immunohistochemical findings of the present study were partially in accordance with the findings of Sharma *et al*. (2020). They depicted strong cytoplasmic staining in almost all neoplastic cells in poorly differentiated SCC of horn and another case of poorly differentiated SCC of horn which showed moderate staining in about 75% of neoplastic cells, but the present study revealed highest immunoexpression and intense staining of Pan-CK in well differentiated SCC of horn (BovHC3) although high and moderate immunoexpression of Pan-CK was observed in poorly and moderately differentiated SCC are in accordance with Kumar *et al*. (2023). p53 immunoexpression in nuclei of tumour cells around periphery of keratin pearls, sparing the region of keratinization with p53 tumour marker was also reported by Carvalho *et al*. (2005), Fornazari *et al*. (2017) and Sharma *et al*. (2020) High immunoreactivity observed in well differentiated SCC of horn in the present study differed from the findings of Sharma *et al*. (2020) which stated strong immunopositive reaction of p53 in poorly differentiated SCC of horn. Fornazari *et al*. (2017) observed intense positive immunostaining of p53 and expression mostly within outer epithelial layer of the cell nests. The concentration of p53 increases in response to DNA damage in the nucleus of the cells and also inactivation of tumour suppressor (p53 gene) is the possible mechanism for oncogenesis. The present findings of immunoexpression of EGFR were in accordance with Lakshmi *et al*. (2020). They observed strong immunopositive reaction against EGFR in OSCC. High immunopositive reaction of EGFR confirmed the malignant tendencies of tumour of epithelial origin. Higher activity of EGFR signifies the increased growth, invasiveness and metastasis of squamous cell carcinoma (Lakshmi *et al*., 2020). Most of the tissue samples showed negative reaction/non-immunoreactive towards p16 gene. Strongest immunoreactivity was observed for pan-cytokeratin.

Table 3: Basis for immunohistochemical scoring of tumour cells.

Result	Score
Non immunoreactive	0
Immunoreactive in 1-25% cells	1+
Immunoreactive in 26-50% cells	2+
Immunoreactive in 51-75% cells	3+
Immunoreactive in 76-100% cells	4+

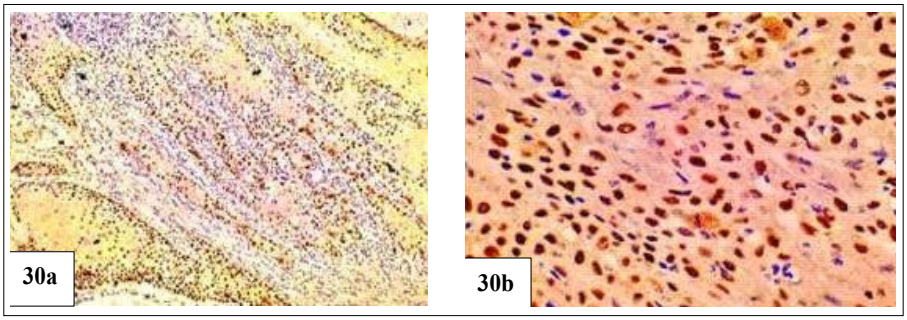

Fig 30: a); Well differentiated SCC of horn, p53 nuclear staining of tumour cells with 4+ score (BovHC3; IHC × 40); b): Higher magnification of fig. no. 30a showing intense nuclear staining of p53 with 4+ score (BovHC3; IHC × 400).

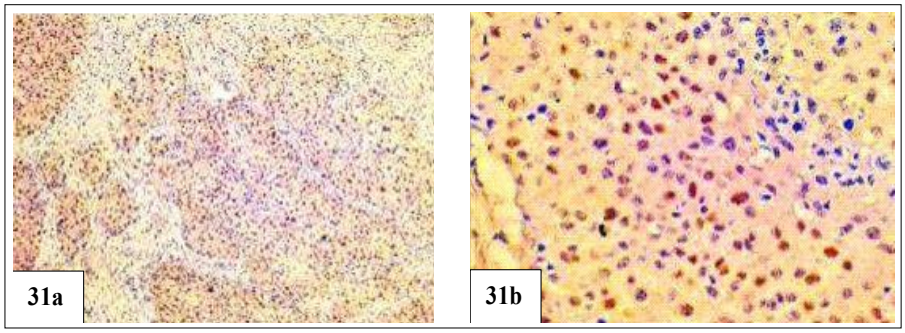

Fig 31: a); Poorly differentiated SCC of horn, p53 Immunoexpression in BovHC4 with 3+ score (IHC × 100); b); Higher magnification of fig. no. 31a) (BovHC4; IHC × 400).

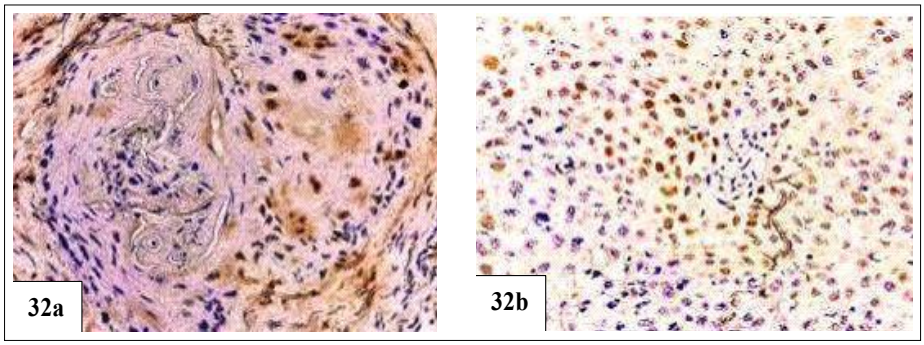

Fig 32: a); Moderate immunoexpression of p53 in nuclei of tumour cells with 2+ score (BovHC6; IHC × 400); b); p53 immunoexpression in BovHC6 with 2+ score (different field; IHC × 400).

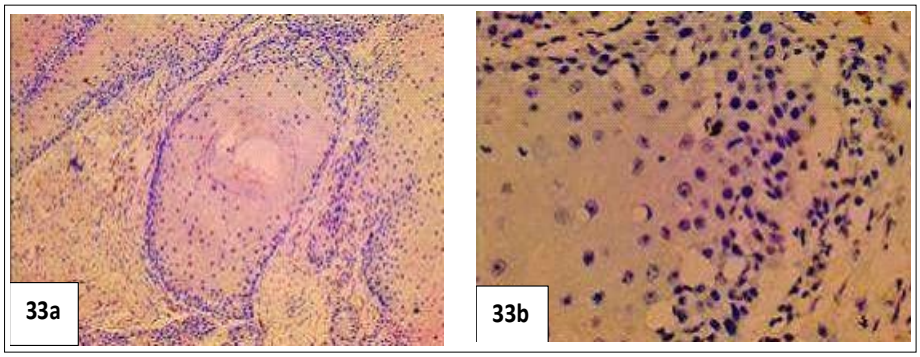

Fig 33: a); Well differentiated SCC of horn, negative immunoreaction of p16 (BovHC3; IHC × 100); b); Higher magnification of Fig 33a (IHC × 400).

Table 4: Immunohistochemical scoring of different tumour markers.

Case ID	Hispathological diagnosis	p53 scoring	Pan-CK scoring	EGFR scoring	p16 scoring
BovHC1	Moderately differentiated SCC	0	2+	0	0
BovHC2	Poorly differentiated SCC	0	1+	0	0
BovHC3	Well differentiated SCC	4+	4+	4+	0
BovHC4	Poorly differentiated SCC	3+	3+	3+	0
BovHC6	Well differentiated SCC	2+	3+	2+	0
BovHC8	Moderately differentiated SCC	1+	1+	0	0
BovHC9	Well differentiated SCC	1+	3+	2+	0
BovHC10	Well differentiated SCC	1+	3+	1+	0

Table 5: Grading of SCC on the basis of HP and IHC.

Grade of malignancy	SCC of horn
Grade I (Poorly differentiated SCC)	2
Grade II (Moderately differentiated SCC)	2
Grade III (Well differentiated SCC)	4
Total	8

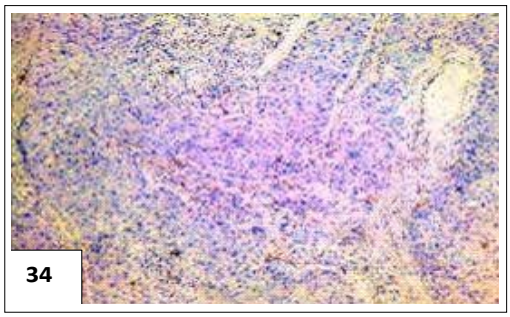

Fig 34: Poorly differentiated SCC of horn, negative immunoexpression of p16 with IHS 0 (BovHC4; IHC X 100).

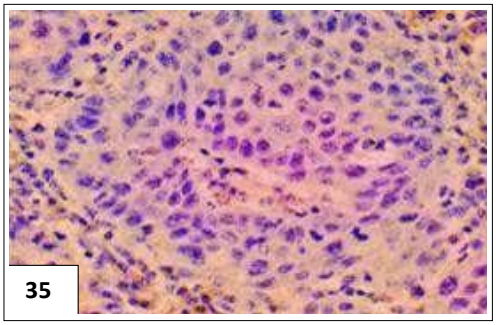

Fig 35: Negative immuhistochemical expression of p16 (BovHC10; IHC × 400).

Grading of SCC (horn) on the basis of histopathology and IHC revealed two cases of Grade I (poorly differentiated SCC); 2 cases of Grade II (moderately differentiated SCC) and four cases of Grade III (well differentiated SCC) (Table 5).

CONCLUSION

A total of Eight out of Twelve tissue samples collected were confirmed as horn core carcinoma on the basis of histopathology and Immunohistochemistry. Cytological examination revealed variation in shape and size of cells, altered nuclear details; tumour cells were observed with cells stained more intensely with hyperchromasia and anaplasia. Unilateral growth was observed in all the cases examined, grossly tumours suspected of SCC were large cauliflower like ulcerated growth with rough and verrucous surface. Histopathologicaly, cell nests or keratin pearls with high degree of keratinization and layered pattern of keratinization were reported in well differentiated SCC of horn with anaplasia, numerous mitotic figures and tumour islands with severe inflammation, neovascularization, hemorrhages etc. SCC of horn revealed strong immunohistochemical staining of Pan-CK, p53, EGFR and negative to p16. High Pan-Cytokeratin immunoreactivity confirmed the tumours of epithelial origin and EGFR immunoexpression was confirmatory for malignancy and degree of metastasis.

ACKNOWLEDGEMENT

The authors are thankful to the Dean, College of Veterinary Sciences, Dau Shri Vasudev Chandrakar Kamdhenu Vishwavidyalaya for providing necessary facilities for this research work.

Ethics approval consent to participate

This research followed the guidelines specified by Institutional Animal Ethics Committee (IAEC). All the experimental procedures were carried out as per the recommendations of the IAEC.

Consent for publication

All the authors consent to the publication of this manuscript.

Competing interest

All authors declare that they have no competing interests.

REFERENCES

Anderson, D.E. and Badzioch, M. (1991). Association between solar radiation and ocular squamous cell carcinoma in cattle. American Journal of Veterinary Research. 52(5): 784-788.

Baghla, A., Choudhry, S., Kataria, A. (2012). Immunohistochemical expression of cytokeratin 5/6 in gynaecological tumors. International Journal of Pathology. 13: 1-7.

Bancroft, J.D. and Stevens, A. (Eds.). (1990). Theory and Practice of Histological Techniques. Churchill Livingstone.

Baniadam, A., Moezzi, N., Mohammadian, B. (2010). Nasal squamous cell carcinoma in a cow. Turkish Journal of Veterinary and Animal Scences. 34(3): 303-305.

Carvalho, T. Vala, H. Pinto, C., Pinho, M., Peleteiro, M.C. (2005). Immunohistochemical studies of epithelial cell proliferation and p53 mutation in bovine ocular squamous cell carcinoma. Veterinary Pathology. 42: 66-73.

Doddagowda, S.M., Shashhidhar, H.A. and Prasad C.S.B.R. (2017). Leishman-Giemsa Cocktail - Is it an effective stain for air dried cytology smears. Journal of Clinical Diagnosis and Research. 11(3): EC16-EC18.

Fornazari, G.A., Kravetz, J., Kiupel, M., Sledge, D., Filho, IRDB, Montiani-Ferreira, F. (2017). Ocular squamous cell carcinoma in Holstein cows from the south of Brazil. Veterinary World. 10: 1413-1420.

Garma-Aviña, A. (1994). The cytology of squamous cell carcinomas in domestic animals. Journal of Veterinary Diagnostic Investigation. 6(2): 238-246.

Giri, D.K., Kashyap, D.K., Dewangan, G., Tiwari, S.K., Ghosh, R.C., Sinha, B. (2011). Squamous cell carcinoma of horn and its surgical management-a report of three cases. International Journal of Livestock Research. 1: 55-58.

Joshi, B.P., Soni, P.B., Ferar, D.T., Ghodasara, D.J., Prajapati, K.S. (2009). Epidemiological and pathological aspects of horn cancer in cattle of Gujarat. Indian Journal of Field Veterinarians. 5(2): 65-67.

Kalim, M.O., Tiwari, S.K., Sharda, R., Shakya, S., Sannat, C., Praveen, K., Deshmukh, S.K. (2021). Studies on prevalence, predisposing factors and microscopic evaluation of bovine horn cancer. The Pharma Innovation Journal. 10 (2): 268-270.

Kumar, V., Jolhe, D.K., Ghosh, R.C., Sonkusale, P.M., Sharma, S. (2023). Pathology and diagnosis of ocular squamous cell carcinoma in bovines. Indian Journal of Veterinary Sciences and Biotechnology. 19(4): 43-49.

Kumar, V., Mathew D.D., Kumar N., Arya, R.S. (2013). Horn cancer in bovines and its management. Intas Polivet. 14(1): 56-57.

Kumar, R. and Thilagar, S. (2000). An unusual case of bilateral horn cancer in a buffalo. Indian Veterinary Journal. 77: 48-49.

Lakshmi, M.P., Veena, P., Kumar, R.S., Prameela, R.D. (2020). Clinical, pathological and immunohistochemical studies on bovine eye cancer. The Pharma Innovation Journal. 9: 353-355.

Liggett Jr, W.H. and Sidransky, D. (1998). Role of the p16 tumour suppressor gene in cancer. Journal of Clinical Oncology. 16(3): 1197-1206.

Papaniculaou, G.N and Traut, H.F. (1941). The diagnostic value of vaginal smears in carcinoma of the uterus. American Journal of Obstetrics and Gynecology. 42: 193-206.

Raju, K. (2016). Evolution of pap stain. Biomedical Research and Therapy. 3(2): 490-500.

Reddy, K.J.M., Kumar, V.G., Ganesh, S., Raghavender, K.B.P. (2017). Unilateral horn cancer in cow and its surgical Management-A case report. International Journal of Current Microbiology and Applied Sciences. 6: 3349-52.

Sharma, S., Gupta, R.P., Jangir, B.L., Lather, D., Hazari, R. (2020). Pathomorphological studies and immunohistochemical expression of p53 and pancytokeratin in bovine epithelial tumors. Indian Journal of Veterinary Pathology. 44(1): 1-6.

Singh, S. and Singh, G. (2005). Important aspects of horn cancer. Scientific Economical Journal. 2(6): 32-9.

Somvanshi, R. (1991). Horn cancer in Indian cattle. Veterinary Bulletin. 61: 901-911.

Tsujita, H. and Plummer, C.E. (2010). Bovine ocular squamous cell carcinoma. Veterinary Clinics: Food Animal Practice. 26(3): 511-529.

Tyagi, R.P.S. and Singh, J. (2006). Ruminant Surgery, 1st edn., CBS Publisher and Distributors. New Delhi: 415-416.

Udharwar, S.V., Aher, V.D., Yadav, G.U., Bhikane, A.U., Dandge, B.P. (2008). Study on incidence, predisposing factors, symptomatology and treatment of Horn cancer in Bovine with special reference to Surgery and Chemotherapy. Veterinary World. 1(1): 7-9.

Watanabe, S., Ichikawa E., Takahashi, H., Otsuka, F. (1995). Changes of cytokeratin and involucrin expression in squamous cell carcinomas of the skin during progression to malignancy. British Journal of Dermatology. 132(5): 730-739.

Yan, W., Wistuba I.I, Emmert-Buck M.R., Erickson H.S. (2011). Squamous cell carcinoma-similarities and difference among anatomical sites. American Journal of Cancer Research. 1(3): 275-300.