RESEARCH ARTICLE Indian Journal of Animal Research, Volume 58 Issue 8: 1294-1302 (August 2024)

Ameliorative Effect of Naringenin in 5-Fluorouracil-Induced Hepatotoxicity: An Experimental Study on Albino Wistar Rats

Sravathi Vemula[1], Jeevanalatha Mylaram[1], Ravikumar Yadala[1], Anilkumar Banothu[1], Sanduri Aasritha[1], Kamishetti Mounika[1], Donga Durga Veera Hanuman[1]

10.18805/IJAR.B-5213

ABSTRACT

Background: Hepatotoxicity is an adverse complication in 5-Fluorouracil cancer treatment. Inflammation, oxidative stress, apoptosis and DNA damage are essential in the pathogenesis of liver damage. The present study evaluated the ameliorative effect of Naringenin (NG) in 5-FU at two different intervals in hepatic damage.

Methods: Total (n=48) Albino Wistar rats were divided into 4 groups (N=12), Control-normal saline (group-1) per oral, 5-FU (group-2) @ 20 mg/kg b.wt was injected intraperitoneal (IP) for first 5 days, NG (group-3) @100 mg/kg b. wt/day orally for 28 days. Another group-4 was concurrently treated with NG along with 5-FU for 28 days and sacrificed on the 14th and 28th day of the experiment.

Result: On exposure to 5-FU, biochemical variation of liver enzymes (ALT, AST, ALP and TP) were significantly increased while NG treatment significantly reduced these biomarkers in group 2 on 14th day and 28th day of the experiment. Furthermore, NG treatment significantly reduced lipid peroxidation and increases the antioxidant profile. It also significantly reduced elevated concentrations of pro-inflammatory cytokines like tumour necrosis factor (TNF-α), interleukin -1β (IL-1β), interleukin-6 (IL-6) with increased concentrations of interleukin-10 (IL-10) along with reduced immunohistochemical expression of nuclear factor kappa light chain enhancer of activated B cells (NF-κB) and Caspases -3 (Cas-3) by NG. On histopathology, pathological lesions were observed to support biochemical variations in group-2 rats. In group-4 rats, NG ameliorates liver enzymes, inflammatory cytokines and oxidative indices through an anti-oxidant, anti-inflammatory and anti-apoptotic property.

Key words: 5-flurouracil, Caspase-3, Liver enzymes, Naringenin.

INTRODUCTION

5-Fluorouracil (5-FU), a classified antineoplastic, pyrimidine antimetabolite second most frequently used, a powerful chemotherapeutic agent that has been used for decades to treat a variety of malignancies (Famurewa *et al*., 2019; Chelpuri *et al*., 2022). It has anticancer effects in a variety of ways, including suppression of the thymidylate synthase enzyme (Longley, 2003) and activation of the protein p53, as well as effects on cell cycle control and G1/S arrest and used in the treatment of various types of cancer, including colorectal, breast, skin, head, neck and liver cancer (Gelen *et al.,* 2017). Apart from its benefits, it has many side effects in a variety of organs including myelosuppression, emesis, mucositis, nausea and toxicity to other organs, particularly cardiotoxicity, hematotoxicity, nephro and hepatotoxicity (Muhammad, Sallam and El-Abhar, 2020) Cytotoxic consequences of 5-FU is mainly by two modes of action-its metabolic product 5-fluoro-2-deoxyuridine5-monophosphate (FdUMP) blocks thymidylate synthase, results in a deficit in thymidine, inhibits DNA synthesis. In addition, it incorporates into RNA, inhibits RNA synthesis and causes cell toxicity (Chibber, 2011). Approximately 90% of 5-FU drug catabolized by dihydropyrimidine dehydrogenase (DPD) into dihydrouracil mainly in the liver, results in degradation products of alpha-fluoro-beta-alanine (FBAL) in inactive form, thus responsible for hepatotoxicity (Badawoud, 2017; Rashid *et al*., 2014).

[1]Department of Veterinary Pathology, College of Veterinary Science, PV Narsimha Rao Telangana Veterinary University, Rajendranagar, Hyderabad-500 030, Telangana, India.

Corresponding Author: Anilkumar Banothu, Department of Veterinary Pharmacology and Toxicology, College of Veterinary Science, PV Narsimha Rao Telangana Veterinary University, Rajendranagar, Hyderabad-500 030, Telangana, India.
Email: anilvetpharma@gmail.com

How to cite this article: Vemula, S., Mylaram, J., Yadala, R., Alla, G.R., Banothu, A., Aasritha, S., Mounika, K., Hanuman, D.D.V. and Nagarjuna, G. (2024). Ameliorative Effect of Naringenin in 5-Fluorouracil-Induced Hepatotoxicity: An Experimental Study on Albino Wistar Rats. Indian Journal of Animal Research. 58(8): 1294-1302. doi: 10.18805/IJAR.B-5213.

Submitted: 31-07-2023 **Accepted:** 13-02-2024 **Online:** 28-03-2024

Several studies have been postulated on naturally available compounds to mitigate various toxicities with anti-oxidant, anti-apoptotic and anti-inflammatory properties, thereby decreasing cell death and increasing natural remedies for anticancer drugs side effects (Renushe *et al*., 2022; Yousef *et al.,* 2017).

NG -4,5,7-trihydroxy flavanone is a phytochemical present in citrus fruits (grapefruit and oranges) and tomatoes and synthesized from an aromatic amino acid, phenylalanine and present as glycosylated form (Moghaddam *et al.,* 2020). Biological properties of NG include anti-inflammatory (Leopoldini *et al.,* 2011), cardioprotective, hematoprotective,

hepatoprotective (Renugadevi and Prabu, 2009; Sravathi *et al*., 2022), nephroprotective and anti-carcinogenic properties (Ekambaram, Rajendran, Magesh and Sakthisekaran, 2008). In addition to a direct antioxidant property by free radical scavenging activity, NG can induce the endogenous anti-oxidant system. It has an anti-oxidant effect due to its OH substituent, which reacts highly against ROS. The OH can donate its H to free radicals to increase antioxidant capacity (Reddy *et al.,* 2008).

MATERIALS AND METHODS

All chemicals are procured from Qualigens Private Limited, India (Mumbai) and SRL Private Limited, India. 5-FU was procured from celon laboratories private limited, Hyderbad, India. Naringin (CAS No: 10236-47) was obtained from Sigma (SAC-St Louis, MO, USA).

Experimental animals

Healthy male albino *Wistar* rats (48), age-3 months, weighing 180-220 g, were bought from Jeeva Life Science (ISO 9001:2015 certified company), Hyderabad, India. They were acclimatized for 10 days and maintained at a temperature of 25±2°C, 12 hours (h) of a light-dark cycle (12:12) and humidity (45-55%) throughout the current experimental period. In addition, all the rats were given with standard pellet diet (low-fat and nutritionally balanced food) and *ad libitum* deionized water for 28 days.

Ethical statement

The Experiment was carried out according to the guidelines and prior approval of the Institutional Animal Ethics Committee (No.9/24/C.V.Sc., Hyd. IAEC-Rats/ 12.06.2021) and work is carried at Department of Pharmacology and Toxicology, P.V. Narsimha Rao Telangana Veterinary University, College of Veterinary Sciences, Rajendranagar, Hyderabad, India during 2021.

Experimental design

The Present experiment aimed to study the ameliorative effects of NG against 5-Fluorouracil-induced hepatotoxicity in rats on 14th and 28th day. A total of forty-eight (48) healthy adult male rats were separated into four groups, with twelve animals in one group (Fig 1).

Group-1: Control-treated as sham received normal saline orally for 28 days.

Group-2: Toxic group-5-FU at a dose rate of 20 mg/kg b.wt for first 5 days-IP.

Group-3: Served as ameliorative group-NG (100 mg/kg b. wt) per orally for 28 days.

Group-4: Served as combination group-5-FU (@ 20 mg/kg b. wt/day) for 1st 5 days, NG at a dose rate of 100 mg/kg b. wt/ day 28 days.

Blood sample collection

Blood was collected approximately 2 mL from each rat from retro-orbital plexus and allowed to clot for 3-4 h, later centrifuged at 8,000 revolutions per minute (rpm) for 10 min and collected serum stored at -20°C until further biochemical analysis by using semiautomatic ELISA reader (Thermo Scientific, USA) and Erba Mannheim biochemical kits (Transasia Biomedicals Ltd., Solan, Himachal Pradesh, India). After blood collection, rats were sacrificed on the 14th day and 28th day by using CO_2 chamber.

Liver enzymes estimation

ALT and AST were estimated as per the modified International Federation of Clinical Chemistry (IFCC)

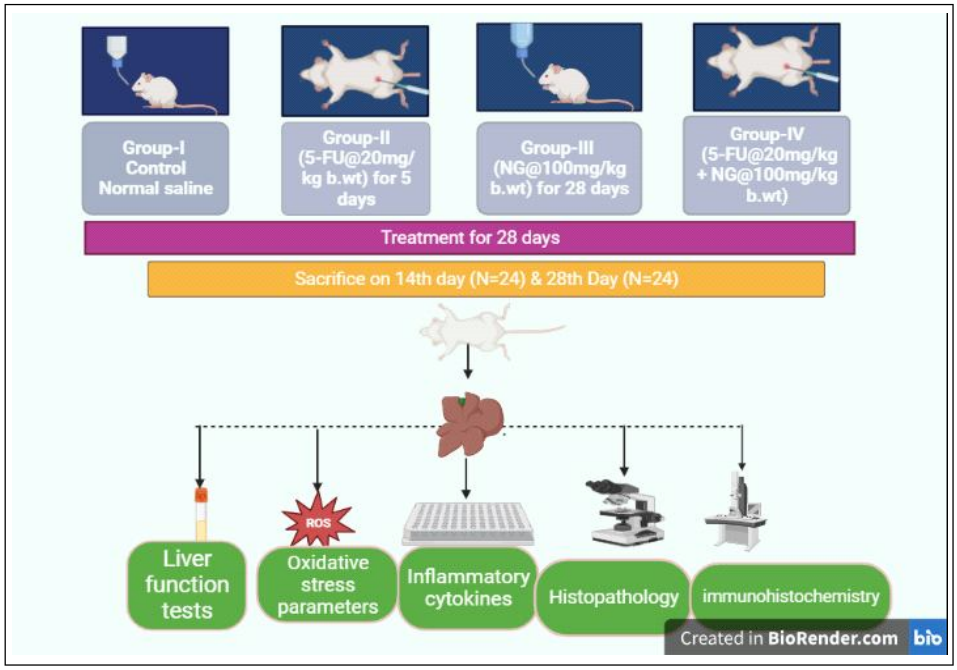

Fig 1: Experimental design of 5-FU induced hepatotoxicity.

method (Shaw *et al*., 1983). Alkaline phosphatase (ALP) was procured from Erba Diagnostics and determined by a sandwich enzyme-linked immunosorbent assay (ELISA technique by using ELISA kit).

Analysis of oxidative stress indices

Tissue samples were collected in liquid nitrogen and stored at -80°C to study oxidative stress parameters (GSH, SOD and TBARS). One gram of tissue sample (liver), along with 10 mL of Tris HCl buffer (pH 7.2), was placed into homogenizer to get homogenate, followed by centrifugation at 4,000 rpm for 2 minutes (min).

The LPO markers concentration was estimated usinga a standard protocol (Balasubramanian *et al*., 1988). Briefly, 100 µL of homogenate, 1 mL of 10% trichloroacetic acid (TCA) and 1 mL of 0.67% of TBA were taken to a tightly stoppered tube and samples were heated at 96°C for 45 min. Following cooling, the contents were centrifuged for 5 min and the supernatant was read at 535 nm against blank.

Reduced GSH was estimated according to Ellman's method (Ellman and biophysics, 1959) to know antioxidant status, by mixing tissue homogenate supernatant with 5, 5' dithiobis-2- nitrobenzoic acid (DTNB) and incubating for 10 min and absorbing light at 412 nanometers (nm).

For SOD estimation, tissue homogenate reaction involves the generation of superoxide by mixing pyrogallol autoxidation by scavenging superoxide anion radicals and expressed as SOD units (one unit of SOD is the amount in mg of protein required to inhibit the MTT reduction by 50%) (Madesh *et al.,* 1998).

Estimation of inflammatory cytokine storm

Inflammatory biomarkers were obtained using Enzyme-linked immune sorbent assay (ELISA) kit from Genelia, Krishgen Bio systems (Mumbai). Primary antibody-coated wells were washed five times with 200 µL of wash buffer. 100 µL of samples were added and incubated overnight. Add 100 µL of the secondary antibody and incubate, then add a biotin-labelled antibody and wash with wash buffer. Add Substrate solution to form (TMB) to microwells and absorbance is measured at 450 nm. Units are measured in pg/ mg protein.

Histopathology of heart tissue

Soon after sacrifice, liver tissues were collected and fixed in 10 per cent neutral buffer formalin (NBF) for 48 hours. Samples were washed under running water and subjected to ascending graded series of alcohol for dehydration, then cleared with xylene. Followed by buries with embedding medium (Paraffin), dyed with haematoxylin and eosin (H and E). The standard procedure described the sections observed under light microscopic examination (Luna, 1968).

Immunohistochemical analysis of heart tissues

For Immunoexpression, sections were deparaffinized in a hot air oven and cleared with xylene. Then, hydrated the sections in descending graded series of alcohol for each 5 min. For antigen retrieval, sections were placed in proteinase K (20 µg/mL) and blocked the sections with 3% BSA and washed with buffer solution. Sections were incubated with primary antibodies overnight. After 24 h, sections were washed with buffer and incubated for 30 min with diaminobenzidine (DAB) chromogen for 10 min. Stain with hematoxylin and observe immunoexpression intensity under light microscopic examination (Chelpuri *et al.,* 2022).

Statistical analysis

Data regarding the study were analysed statistically using a one-way Analysis of variance (ANOVA) using the statistical package for social sciences (SPSS) version 15.0. Duncan's multiple comparison tests were done for comparison among groups and the significance level was set at $P<0.05$ (Snedecor and Cochran, 1994).

RESULTS AND DISCUSSION

Serum biochemical parameters

Sustainable hepatotoxicity was observed by significantly elevated levels of ALT, AST, ALP and albumin (IU/L) recorded in group 2 by 5-FU in comparison with other groups. Treatment with NG considerably significantly reduced increase levels indicating a decrease in liver damage caused by 5-FU was recorded in group 4 rats on the 14th and 28th day of the experiment (Fig 2).

Oxidative stress parameters

Studies on tissue (liver) oxidative stress indices showed a significant ($P<0.05$) increase in TBARS levels in 5-FU group compared with other groups. There is no significant difference between group-1 and 3 rats. However there are significantly reduced TBARS levels with treatment with NG. The significantly ($P<0.05$) decreased concentrations of GSH and SOD in the 5-FU treated group on the 14th and 28th day of the experiment compared to the control group. However, the values were significantly increased in group-4 compared to group-2 rats, variation in the values of antioxidant levels helped suggest the reduction in 5-FU induced tissue damage by NG (Fig 3).

Cytokine profile

Pro-inflammatory cytokines levels (TNF-α, IL-1β, NF-κB and IL-10) and anti-inflammatory cytokines levels (IL-10) in the tissues of liver homogenate were estimated by using ELISA. Elevated levels of pro-inflammatory cytokine levels in 5-FU treated group were observed and while significantly (<0.0001) lowered in levels of anti-inflammatory cytokine concentrations-IL-10 levels were observed and it suggested that 5-FU has an inflammatory effect in the liver. Whereas, NG significantly decreased in group-4 compared with group-2 rats in levels of pro-inflammatory cytokine levels and significantly increased in levels in IL-10, indicating NG has boosted an anti-inflammatory response which helps to lesson decrease liver damage and reverse the negative response caused by 5-FU (Fig 4).

Histopathology

The liver sections of group 1 and 3 rats showed normal architecture of hepatic central vein (CV) and portal triad with the normal radiating appearance of hepatic cords with uniform sinusoids (Fig 5 A, D). The liver sections of group 2 on 14th day showed vascular changes, including moderate congestion of CV, dilatation and congestion of portal vein (PV), parenchymatous changes including vacuolar degeneration and necrosis of hepatocytes, dilatation of sinusoids, marked Mononuclear cells (MNCs) infiltration; hepatocytes showed a swollen to pyknotic nuclei (Fig 5 B,C). On 28th day of the experiment, the liver showed severe dilation of sinusoids, severe vascular degeneration in hepatic parenchyma, hepatocellular necrosis, a complete distortion of sinusoids, focal oedema, intense congestion of portal vein (PV) and mild hyperplasia of bile duct epithelium (Fig 5 F, G, H).

The liver sections of group 4 rats on 14th and 28th day of the experiment showed mild dilation and congestion of CV and PV, mild dilation of sinusoids with mild degenerated changes in the hepatic cord. The reconstructive appearance of hepatic lobules with radiating appearance of hepatic cords with uniform size of hepatic nuclei (Fig 5 E,I).

Immunoexpression of NF-κB and Caspaes-3

In the present study, strong immunopositive expression of inflammatory marker (NF-κB) and pro-apoptotic (Caspase-3) were observed in group-2, indicating the release of inflammatory cytokines and apoptotic protein. Whereas intensity in immunoexpression was reduced in group-4, indicating that NG has anti-inflammatory and apoptotic effects at the molecular level. There were no changes in immunoreactivity of NG group-3 gives information about the safety of the compound (Fig 6).

Although a number of studies have been conducted on the protective effect of natural agents against chemotherapeutic drugs, we believe that this is the first study to look into the potential protective effect of NG against 5-fluorouracil-induced chronic liver damage against oxidative stress, inflammation, apoptosis and DNA damage at two intervals that is on 14th and 28th day. Although 5-FU is a powerful anti-neoplastic medication, its hepatotoxic side effects may reduce its effectiveness in treating cancer. On the other hand, NG, a phytochemical used as an ameliorative agent against hepatoxicity through lowered oxidative stress, inflammation and apoptotic damage in various studies (Shirani *et al.,* 2020). We select NG among

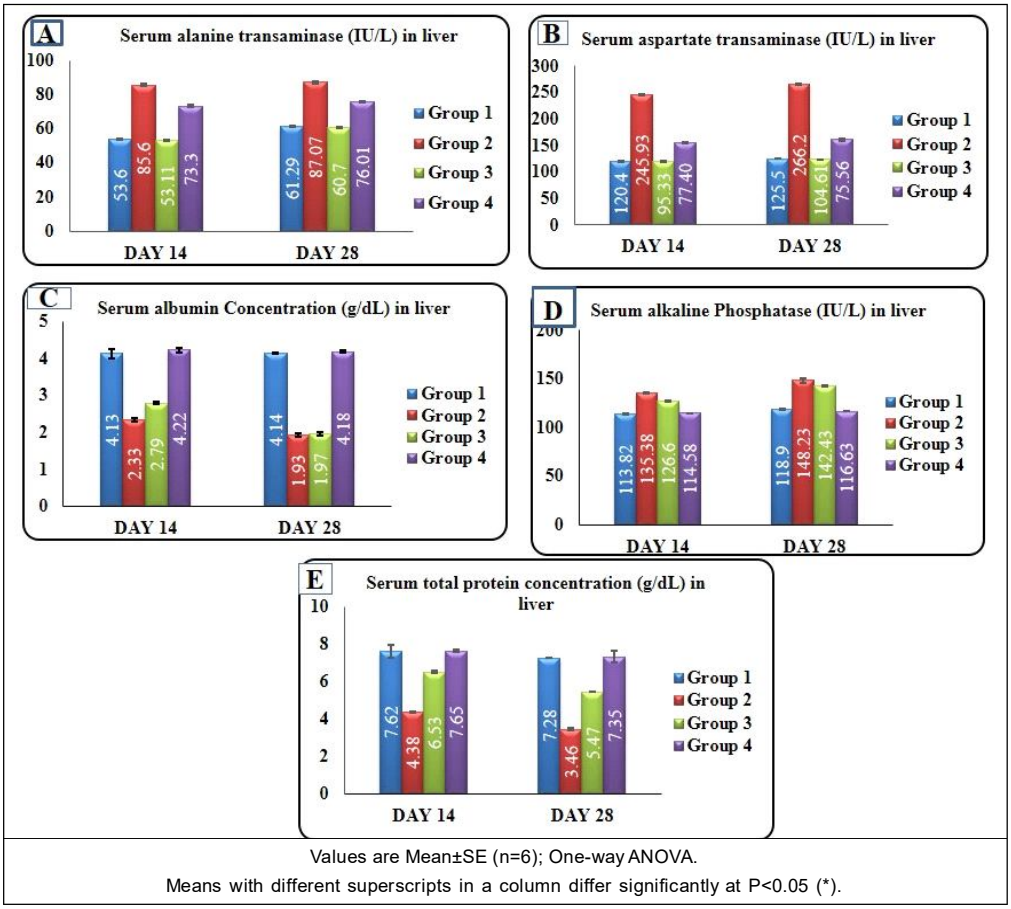

Values are Mean±SE (n=6); One-way ANOVA.
Means with different superscripts in a column differ significantly at P<0.05 (*).

Fig 2: Effect of NG on serum biochemical parameters at different time intervals. A-ALT, B-AST, C-Serum albumin D-ALP, E-total protein.

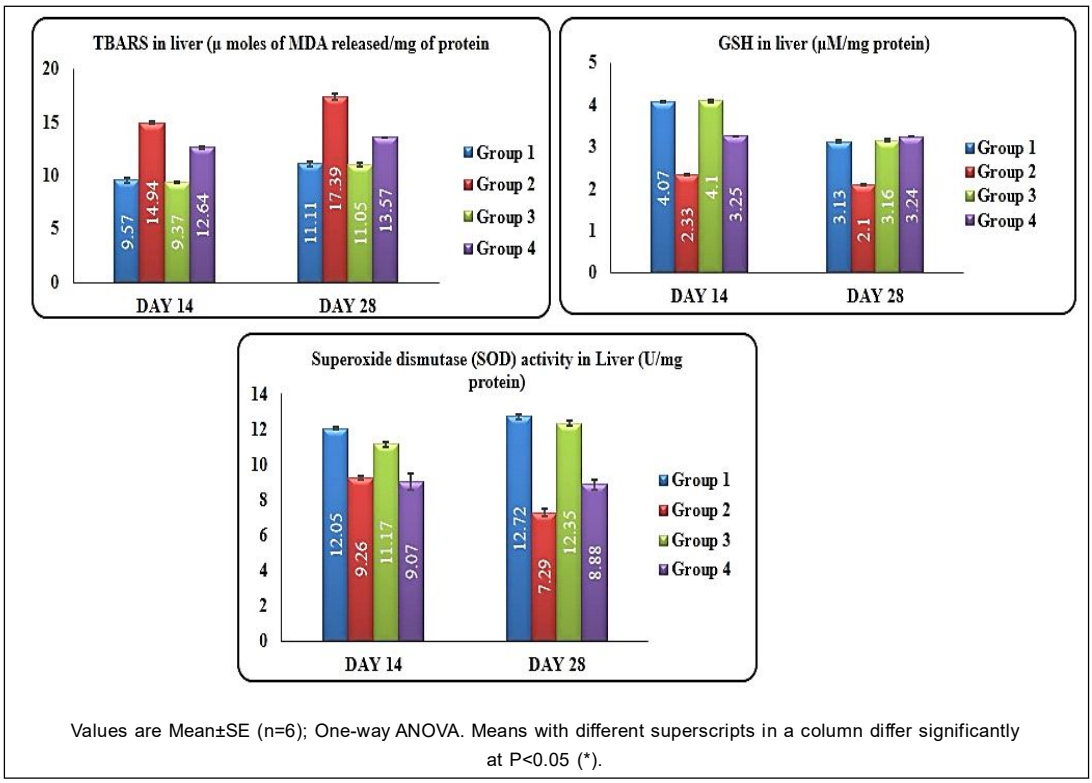

Values are Mean±SE (n=6); One-way ANOVA. Means with different superscripts in a column differ significantly at P<0.05 (*).

Fig 3: Ameliorative effect of NG on 5-FU induced oxidative stress, it increases anti-oxidants levels-GSH, SOD.

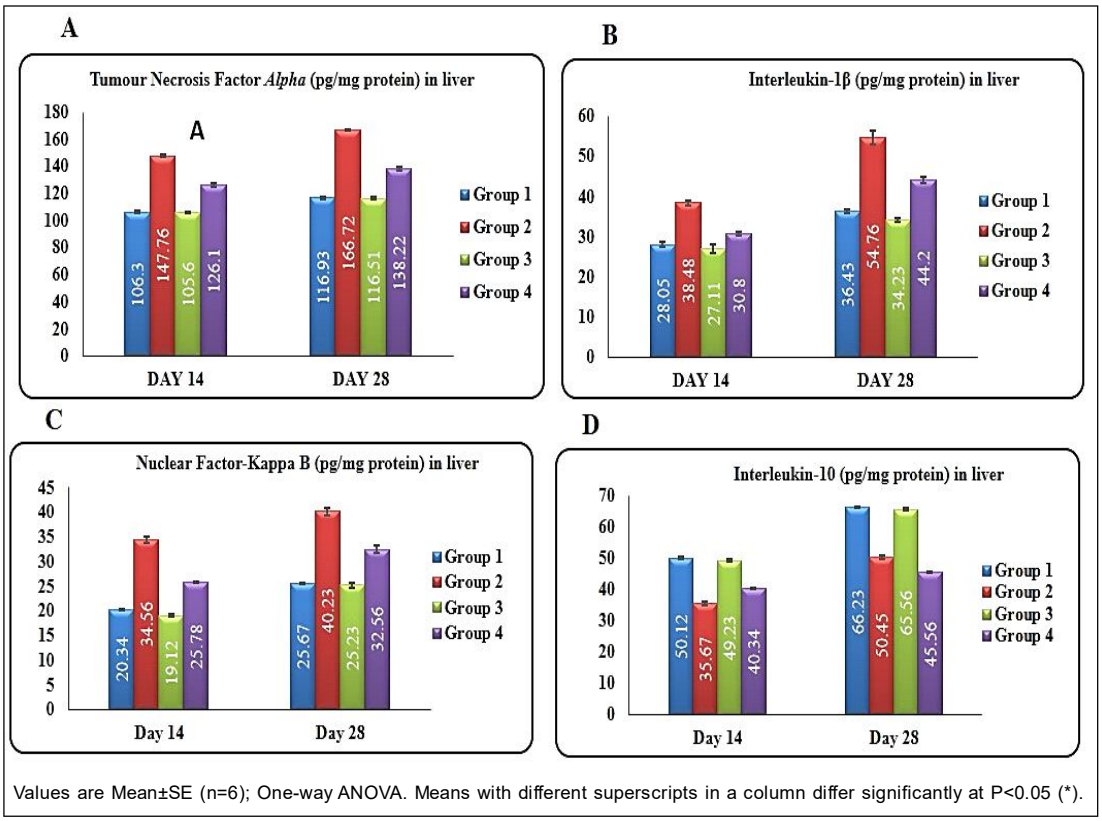

Values are Mean±SE (n=6); One-way ANOVA. Means with different superscripts in a column differ significantly at P<0.05 (*).

Fig 4: Effect of NG on 5-FU induced cytokine strom in liver by decreasing pro-inflammatory cytokines-TNF-α, IL-1β, NF-κB and increasing anti-inflammatory cytokines-IL-10.

many products because it has more absorption into the body with an increase in bioavailability than naringin powder (Massaro *et al.,* 2023). This study, therefore, evaluates the chronic effects of NG at different intervals.

ALT, AST and ALP are the most important biological markers of cellular damage and toxicity (Gelen *et al.,* 2017; Vanithasree *et al*, 2011). 5-FU is primarily metabolized in the liver to fluoro-beta-alanine, which is an inactive form that may be responsible for hepatic damage (Saif *et al.,* 2009). The liver injury further causes membrane damage, which allows enzymes to circulate and be detected in the serum. It might be caused by an excess production of free radicals and oxidation products in the liver, which cause damage to the membranes and endothelial lining of the hepatic vessels, resulting in liver dysfunction and a change in the permeability of the hepatocytes cell membrane, allowing them to enter into the bloodstream (Dimitriu *et al.,* 2015). A significant elevation of these enzyme activities has been used as an indicator of acute liver injury in agreement with the observations of Afolabi and Harish with an increase

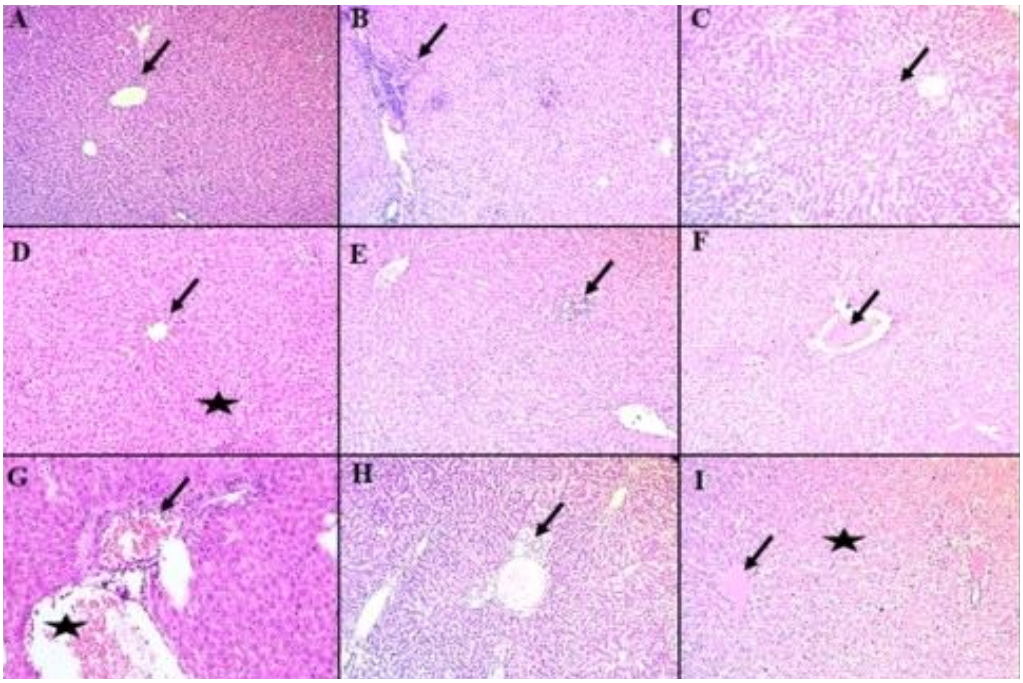

A, D. normal architecture of liver with central vein (Arrow), hepatic cords (star), B. focal infiltration of inflammatory cells of portal vein (arrow), C. vacuolar degeneration and necrosis of hepatocytes dilatation of sinusoids (arrow) on 14th day, E. Mild inflammatory cells (arrow), 14th day, F. Congestion of central vein, G. inflammatory cells (arrow) with congestion of portal triad (star), H. hyperplasia of bile duct (F-H-28th day), I. Mild regeneration of hepatic cords on the 28th day.

Fig 5: Microscopic picture of liver-10x.

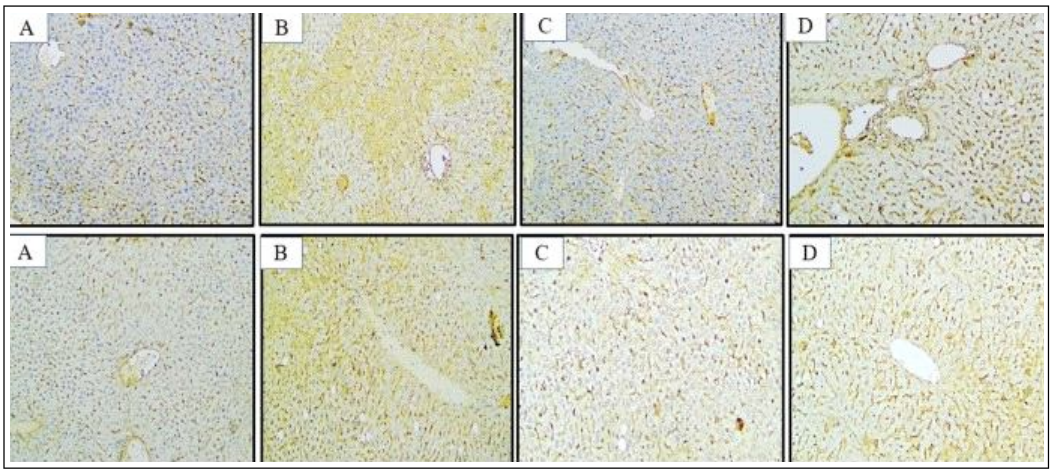

Fig 6: Effect of NG on immunoexpression of liver section TOP-1.NF-κB, down-Caspase-3.

in the concentration of serum enzymes by administering 5-FU (Harish *et al*., 2021; Tavakoli Pirzaman *et al*., 2023). In the present study, 5-FU might have suppressed the growth of cellular proteins and RNA synthesis, resulting in a low level of serum proteins due to oxidative stress. ROS may induce inflammation, causing protein damage and lowering the ability of the liver to synthesize new proteins, leading to decrease in these values as report by Badawoud and Harish, who stated that 5-FU caused a decrease a in TP due to oxidative stress in liver (Badawoud *et al.,* 2017; Harish *et al.,* 2021).

In group 4, the mean values of serum ALT, AST and ALP were significantly decreased and a significant increase in the mean values of TP and albumin was observed when compared to group 2 rats on the 14th and 28th day of the experiment, which could be due to ameliorative effect of NG by protecting sub-cellular damage and macromolecules (especially lipids) from oxidative injury (Caglayan *et al.,* 2018).

ROS directly affects various biological components, leading to cellular damage and necrosis in the liver (Sehitoglu *et al.,* 2015). Lipid peroxidation is one of the mechanisms involved in tissue damage through ROS formation. TBARS is one of the most widely used assay for measuring lipid peroxidation as MDA is a better predictor of oxidative damage (Al-Asmari *et al.,* 2016). In our current study, a significant increase in TBARS levels indicates that 5-FU causes oxidative stress and our results are consistent with previous findings (Du *et al.,* 2023).

The removal of ROS in normal healthy cells is achieved by a radical scavenging mechanism that includes catalase (CAT), superoxide dismutase (SOD) and reduced GSH. Oxidative stress can arise due to an increase in ROS production or a decrease in antioxidant defence (Ebrahimi *et al.,* 2023).

GSH is an antioxidant that protects against toxic damage by combating ROS via free radical production. The absence of GSH in tissues reduces the cell's defenses against oxidative stress. Our findings suggest that 5-FU precipitated GSH reservoirs, consistent with earlier findings (Manvitha *et al.,* 2019; Afolabi *et al.,* 2016).

SODs are a ubiquitous family of enzymes, efficiently catalysing the dismutation of superoxide anions to molecular oxygen which is transformed by catalase and GSH-Px into water, thus reducing free radical-mediated cell damage (Aikemu *et al.,* 2016). It is regarded as the first defence against superoxide anions, which are abundant during 5-FU redox cycling (Sengul *et al*., 2021). The reduction in the lung SOD values in the present study could be due to damage by disrupting the oxidant-antioxidant balance and increased inflammation (Arab *et al.,* 2018; Rashid *et al.,* 2014; Sengul *et al.,* 2021).

Cytokine secretion is an inflammatory mediator contributing pathogenesis of tissue injury (Laverty *et al., 2*010). Oxidant stress directly triggers a cascade of inflammatory pathways. The transcription factor, NF-κB is thought to be pivotal in this process. It up-regulates genes of pro-inflammatory cytokines TNF-α, IL-1β, NF-κB (Prisciandaro *et al.,* 2011) involved in liver toxicity (Refaie *et al.,* 2022).

In the present study, a significant (P<0.05) elevation was noticed in the concentration of inflammatory cytokines in homogenized tissue of group 2 rats when compared with group 1 and 4 rats on 14th and 28th day of the experiment. This might be due to 5-FU ability to cause excessive ROS generation, which stimulates multiple signaling pathways, including the redox-sensitive NF-κB transcription and MAPK pathway, resulting in various gene expressions for TNF-α (Elghareeb *et al.,* 2021; Famurewa *et al.,* 2019; Gelen *et al.,* 2017).

In group 4, the concentration of inflammatory cytokines was significantly (P<0.05) decreased and IL-10 significantly increased on the 14th and 28th day of experiment when compared with group 2, which might be due to the antioxidant and anti-inflammatory defense mechanism of NG against the production of ROS. NG decrease TNF-α and its associated abnormalities by interactions with intracellular signaling cascade *via* stimulation of Nrf_2 pathway (Zhang *et al.,* 2015), thus reducing phosphorylation of Caspase-3 to suppress apoptosis and NF-κB Toll like receptor 4 (TLR4) stimulation, thus inhibiting pro-inflammatory cytokines (Chen *et al.,* 2012). These findings are in accordance with the observations of earlier observations of Mahmoud (Mahmoud, 2013).

The microscopic changes of liver sections in group 2 rats revealed mild congestion of CV, vacuolar degeneration in the hepatic parenchyma, sinusoidal dilation and mild dilation and congestion of hepatic PV, infiltration of inflammatory cells in the portal triad were also observed on 14th day of the experiment. On 28th day liver section of group 2 showed severe dilatation of sinusoids, severe vacuolar degeneration in the hepatic parenchyma, mild bile duct hyperplasia, severe congestion of PV and complete distortion of sinusoids. These changes might be due to toxic accumulation of intermediate metabolites and ROS production. The microscopic findings correlate positively with the elevated mean values of liver biochemical profiles *viz*., ALT, AST and ALP. Similar results were observed in 5-FU and CCL_2 induced hepatotoxicity (Gelen *et al.,* 2017; Ayaz *et al*., 2017; Jyothi *et al.,* 2009).

In group 4 rats, the liver sections showed a mild degree of microscopic changes like mild congestion of CV and PV, mild dilation of sinusoids, mild infiltration of inflammatory cells and reconstructive appearance of hepatic cords on 14th and 28th day of the experiment. These ameliorative actions may be due to the antioxidant action of NG on hepatic cords (Mahmoud, 2013).

NF-κB is a crucial redox-sensitive transcription factor implicated in the formation of liver abnormalities(Luedde and Schwabe, 2011). In our study, the intensity of immunoexpression of NF-κB increased, which indicates that 5-FU will cause inflammation and lead to liver damage, coinciding with previous works. In addition, the level of

intensity increases in caspase-3 helps to know that 5-FU will cause damage through the apoptotic pathway (Gelen *et al.,* 2017). These results also suggest that the intensity of NF-κB and caspase-3 decrease gives an idea of anti-apoptotic and inflammatory effect of NG, which helps to regulate liver function (Muhammad *et al.,* 2020).

CONCLUSION

In conclusion, NG treatment could lessen liver damage caused by 5-FU in rats. Taken together, we conclude that 5-FU exposure on the 14th and 28th day causes severe liver damage through increased liver enzymes, oxidative enzymes and inflammatory cytokines, histopathology and immunohistochemistry. However, the intensity of lesions increases with an increase in time. At the same time, NG powder could improve the restoration of biochemical oxidative enzymes due to anti-apoptotic, anti-oxidant anti-inflammatory properties. The intensity of liver injury decreases on the 28th day, suggesting that chronic intake of natural flavonoid products will restore damage caused by various chemotherapeutic agents. Furthermore, future studies were required to understand the detailed mechanisms of ameliorative effect using molecular techniques.

ACKNOWLEDGEMENT

We would like to thank P.V. Narsimha Rao Telangana Veterinary University.

Conflict of interest

All the authors were hereby declared no conflict of interest.

REFERENCES

Afolabi, O.K., Adeleke, G.E., Ugbaja, R.N. (2016). Crocin alleviates 5-fluorouracil-induced hepatotoxicity through the abrogation of oxidative stress in male wistar rats. Asian Pacific Journal of Health Science. 3(2): 58-68.

Aikemu, A., Amat, N., Yusup, A., Shan, L., Qi, X., Upur, H.J.E. and Medicine, T. (2016). Attenuation effect of Abnormal Savda Munziq on liver and heart toxicity caused by chemotherapy in mice. Exp. Ther. Med. 12(1): 384-390.

Al-Asmari, A., Al-Zahrani, A., Khan, A., Al-Shahrani, H., Ali Al Amri, M.J.H. (2016). Taurine ameliorates 5-flourouracil-induced intestinal mucositis, hepatorenal and reproductive organ damage in Wistar rats: A Biochemical and histological study. Hum Exp. Toxicol. 35(1): 10-20.

Ayaz, N.O., Ramadan, K.S., Farid, H.E. and Alnahdi, H.S. (2017). Protective role and antioxidant activity of arabic gum against trichloroacetate-induced toxicity in liver of male rats. Indian Journal of Animal Research. 51(2): 303-309. doi: 10.18805/ijar.10976.

Badawoud, M.H., Elshal, E.B., Zaki, A.I. and Amin, H.A.J.F.M. (2017). The possible protective effect of l-arginine against 5-fluorouracil-induced nephrotoxicity in male albino rats. Folia Morphol. 76(4): 608-619.

Balasubramanian, K., Manohar, M., Mathan, V.I. and Metabolism, L. (1988). An unidentified inhibitor of lipid peroxidation in intestinal mucosa. Biochimica et Biophysica Acta (BBA) - Lipids and Lipid Metabolism. 962(1): 51-58.

Caglayan, C., Temel, Y., Kandemir, F.M., Yildirim, S., Kucukler, S.J.E.S. and Research, P. (2018). Naringin protects against cyclophosphamide-induced hepatotoxicity and nephrotoxicity through modulation of oxidative stress, inflammation, apoptosis, autophagy and DNA damage. Environmental Science and Pollution Research. 25: 20968-20984.

Chelpuri, Y., Pabbathi, S., Alla, G.R., Yadala, R.K., Kamishetti, M., Banothu, A.K. and Khurana, A. (2022). Tropolone derivative hinokitiol ameliorates cerulein-induced acute pancreatitis in mice. International Immunopharmacology. 109: 108915.

Chen, S., Ding, Y., Tao, W., Zhang, W., Liang, T., Liu, C.J.F. and Toxicology, C. (2012). Naringenin inhibits TNF-α induced VSMC proliferation and migration *via* induction of HO-1. Food Chem Toxicol. 50(9): 3025-3031.

Chibber, S., Farhan, M., Hassan, I. and Naseem, I.J.T.B. (2011). White light-mediated Cu (II)-5FU interaction augments the chemotherapeutic potential of 5-FU: An *in vitro* study. Tumour Biology. 32: 881-892.

Dimitriu, D.C., LUPUSORU, C.E., Cojocaru, I., Gafitanu, C., Palade, L. and Lupusoru, R.V.J.F. (2015). Assessing biochemical and oxidative stress parameters after vaginal and oral administration of 5-fluorouracil in laboratory animals. Farmacia. 63(2): 230-233.

Du, K., Wang, L., Wang, Z., Xiao, H., Hou, J., Hu, L., Pharmacotherapy. (2023). Angelica Sinensis polysaccharide antagonizes 5-Fluorouracil-induced spleen injury and dysfunction by suppressing oxidative stress and apoptosis. Biomedicine and Pharmacotherapy. 162: 114602.

Ebrahimi, M., Ahangar, N., Zamani, E. and Shaki, F. (2023). L-Carnitine prevents behavioural alterations in ketamine-induced schizophrenia in mice: Possible involvement of oxidative stress and inflammation pathways. J. Toxicol. 9093231.

Ekambaram, G., Rajendran, P., Magesh, V. and Sakthisekaran, D.J.N.R. (2008). Naringenin reduces tumor size and weight lost in N-methyl-N2 -nitro-N-nitrosoguanidine-induced gastric carcinogenesis in rats. Nutr. Res. 28(2): 106-112.

Elghareeb, M.M., Elshopakey, G.E., Hendam, B.M., Rezk, S., Lashen, S.J.E.S. and Research, P. (2021). Synergistic effects of *Ficus carica* extract and extra virgin olive oil against oxidative injury, cytokine liberation and inflammation mediated by 5-Fluorouracil in cardiac and renal tissues of male albino rats. Environ. Sci. Pollut. Res. Int. 28: 4558 -4572.

Ellman, G.L. (1959). Tissue sulfhydryl groups. Archives of Biochemistry and Biophysics. 82(1): 70-77.

Famurewa, A.C, Asogwa, N., Aja, P., Akunna, G.G., Awoke, J.N., Ekeleme-Egedigwe, C.A., Ekpono, E.U. (2019). Moringa oleifera seed oil modulates redox imbalance and iNOS/NF-κB/caspase-3 signaling pathway to exert antioxidant, anti-inflammatory and antiapoptotic mechanisms against anticancer drug 5-fluorouracil-induced nephrotoxicity in rats. South African Journal of Botany. 127(3): 96-103.

Gelen, V., Şengül, E., Gedikli, S., Atila, G., Uslu, H. and Makav, M. (2017). The protective effect of rutin and quercetin on 5-FU-induced hepatotoxicity in rats. Asian Pacific Journal of Tropical Biomedicine 7(7): 647-653.

Harish, B., Shivakumar, P., Kumar, B.K., Ramya, B., Rani, M.U., Kumar, B.A. and Rao, K.V.V. (2021). Evaluation and comparison of protective actions resveratrol and vitamin-e in 5-flourouracil induced hepatotoxicity. The Pharma Innovation Journal. 10(3): 22-26.

Jyothi, K., Reddy, A., Gopi, K., Kumar, B. and Reddy, G. (2009). A study on free radical-induced renal toxicity due to cyclophosphamide and its amelioration with N-acetyl cysteine. Toxicology International. 16(2): 137-139.

Laverty, H.G., Antoine, D.J., Benson, C., Chaponda, M., Williams, D. and Park, B.K. (2010). The potential of cytokines as safety biomarkers for drug-induced liver injury. Eur. J. Clin. Pharmacol. 66: 961-976.

Leopoldini, M., Russo, N. and Toscano, M. (2011). The molecular basis of working mechanism of natural polyphenolic antioxidants. Food Chemistry. 125(2): 288-306.

Longley, D.B., Harkin, D.P. and Johnston, P.G. (2003). 5-fluorouracil: Mechanisms of action and clinical strategies. Nature Reviews Cancer. 3(5): 330-338.

Luedde, T., Schwabe, R.F. (2011). NF-κB in the liver-linking injury, fibrosis and hepatocellular carcinoma. Nat. Rev. Gastroenterol Hepatol. 8(2): 108-118.

Luna, G.J.I.N.Y., Toronto, L. (1968). Manual of Histological and Special Staining Techniques. The Blakistone Division McGraw-Hill Book Company. 1(5): 9-34.

Madesh, M., Balasubramanian, K. and (1998). Microtiter plate assay for superoxide dismutase using MTT reduction by superoxide. Indian Journal of Biochemistry and Biophysics. 35(3): 184-188.

Mahmoud, A.M. (2013). Hematological alterations in diabetic rats-role of adipocytokines and effect of citrus flavonoids. Excli. J. 12: 647-657.

Manvitha, V., Reddy, A.G., Kumar, B.A., Jeevanalatha, M. and Priyanka, G. (2019). Protective role of ashwagandha and selenium against chlorpyrifos (cpf) induced haemato-biochemical and hepatic alterations in wistar rats. Int. J. Curr. Microbiol. App. Sci. 8(11): 941-949.

Massaro, L., Raguzzini, A., Aiello, P., Valencia, D.V. (2023). The potential role of naringin and naringenin as nutraceuticals against metabolic syndrome. Endocr. Metab. Immune. Disord. Drug. Targets. 23(4): 428-445.

Moghaddam, R.H., Samimi, Z., Moradi, S.Z., Little, P.J., Xu, S. and Farzaei, M.H. (2020). Naringenin and naringin in cardiovascular disease prevention: A preclinical review. Eur. J. Pharmacol. 887: 173535.

Muhammad, R.N., Sallam, N. and El-Abhar, H.S. (2020). Activated ROCK/Akt/eNOS and ET-1/ERK pathways in 5-fluorouracil -induced cardiotoxicity: Modulation by simvastatin. Sci. Rep. 10(1): 14693.

Prisciandaro, L.D., Geier, M.S., Butler, R.N., Cummins, A.G., Howarth, G.S. (2011). Evidence supporting the use of probiotics for the prevention and treatment of chemotherapy -induced intestinal mucositis. Crit. Rev. Food. Sci. Nutr. 51(3): 239-247.

Rashid, S., Ali, N., Nafees, S., Hasan, S.K., Sultana, S.J.F. and Toxicology, C. (2014). Mitigation of 5-Fluorouracil induced renal toxicity by chrysin via targeting oxidative stress and apoptosis in wistar rats. Food. Chem. Toxicol. 66: 185-193.

Reddy, T., Nagaraju, I., Kumar, K.H., Lokanatha, V., Reddy, C. and Jagetia, G.C. (2008). Cardioprotective effect of naringin in mice treated with doxorubicin. Planta Medica. 74(03): P-49.

Refaie, M.M., Shehata, S., Bayoumi, A.M., El-Tahawy, N.F.G., Abdelzaher, W.Y. (2022). The IL-6/STAT signaling pathway and PPARá are involved in mediating the dose-dependent cardioprotective effects of fenofibrate in 5-fluorouracil-induced cardiotoxicity. Cardiovasc Drugs Ther. 36(5): 817-827.

Renugadevi, J. and Prabu, S.M. (2009). Naringenin protects against cadmium-induced oxidative renal dysfunction in rats. Toxicology. 256(1-2): 128-134.

Renushe, A.P., Banothu, A.K., Bharani, K.K., Mekala, L., Kumar, J.M., Neeradi, D., Khurana, A. (2022). Vincamine, an active constituent of Vinca rosea ameliorates experimentally induced acute lung injury in Swiss albino mice through modulation of Nrf-2/NF-κB signaling cascade. Int. Immunopharmacol. 108: 108773.

Saif, M.W., Choma, A., Salamone, S.J. and Chu, E. (2009). Pharmacokinetically guided dose adjustment of 5-fluorouracil: A rational approach to improving therapeutic outcomes. J. Natl. Cancer. Inst. 101(22): 1543-1552.

Sehitoglu, M.H., Han, H., Kalin, P., Gülçin, İ., Ozkan, A., Aboul-Enein, H. and Chemistry, M. (2015). Pistachio (*Pistacia vera* L.) gum: A potent inhibitor of reactive oxygen species. J. Enzyme. Inhib. Med. Chem. 30(2): 264-269.

Sengul, E., Gelen, V., Gedikli, S. and Sciences, P. (2021). Cardioprotective activities of quercetin and rutin in sprague dawley rats treated with 5-fluorouracil. The Journal of Animal and Plant Sciences. 31(2): 423-431.

Shirani, K., Yousefsani, B.S., Shirani, M. and Karimi, G. (2020). Protective effects of naringin against drugs and chemical toxins induced hepatotoxicity: A review. Phytother. Res. 34(8): 1734-1744.

Snedecor, G.W. and Cochran, W.G. (1994). Statistical Methods. 8th edn East West Press Pvt. 313.

Sravathi, V., Jeevanalatha, M., Ravikumar, Y., Gopalareddy, A., Chandravathi, T. and Lakshman, M. (2022). 5-Flurouracil induced hematological alterations in wistar rats and its amelioration with naringenin. The Pharma Innovation Journal. 11(1): 1250-1254.

Tavakoli, P.A., Aghajanian, S., Mansoori, R., Al-e-Ahmad, A., Ebrahimzadeh, M., Moghadamnia, A.A. (2023). Interaction of quercetin and 5-fluorouracil: Cellular and pharmacokinetic study. Toxicol. Mech. Methods. 33(6): 502-511.

Vanisthasree, K., Reddy, A.G., Kalakumar, B., Haritha, C. and Anilkumar, B. (2011). Hepatotoxicity studies in the progeny of pregnant dams treated with methimazole, monocrotophos and lead acetate. Toxicology International. 18(1): 67-69.

Yousef, H.N., Aboelwafa, H.R. and Pathology, T. (2017). The potential protective role of taurine against 5-fluorouracil-induced nephrotoxicity in adult male rats. Exp. Toxicol. Pathol. 69(5): 265-274.

Zhang, N., Yang, Z., Yuan, Y., Li, F., Liu, Y., Ma, Z., Medicine, T. (2015). Naringenin attenuates pressure overload-induced cardiac hypertrophy. Exp. Ther. Med. 10(6): 2206-2212.