RESEARCH ARTICLE Indian Journal of Animal Research, Volume 58 Issue 8: 1283-1293 (August 2024)

A Clinical Study on Total Hip Replacement using Cemented Prosthetics for Management of Hip Dysplasia in Dogs

N. Venkatesh[1], K. Jagan Mohan Reddy[2], E.L. Chandra Sekhar[3], N. Rajendranath[4]

10.18805/IJAR.B-5217

ABSTRACT

Background: The current study was undertaken to evaluate the clinical efficacy of cemented prosthetics for total hip replacement for management of hip dysplasia in dogs. Total hip arthroplasty will eliminate pain and, restore function of hip joint.

Methods: The dogs with clinical signs of coxofemoral joint affections were diagnosed using standard hip extended ventrodorsal radiographs of pelvis. Those dogs which are not responded to the medical management, with severe degenerative changes and osteoarthritis were selected for surgical management for total hip replacement. The femoral stems used in this study were small (4) and Medium (2). The size of the acetabular cup used ranges from 20 to 22 mm outer diameter. The bone cement used was polymethyl methacrylate (PMMA) low viscosity type bone cement (Simplex-P). Clinical evaluation of the treated dogs on 2nd day post operatively indicated functional outcome (on the basis of WOMAC score) as excellent in four dogs and good in 2 dogs as the mean scores of parameters was 1.0±0.36, 0.83±0.65, 0.83±0.40, 1.0±0.68, 0.50±0.34, 0.66±0.33, 1.50±0.50, 1.16±0.47, 0.50±0.34, 1.50±0.42, 2.0±0.51 and over all mean of functional outcome is 11.33±4.06 out of 40 points, lower scores reflect better function than higher scores. Radiological and clinical assessment are excellent to good in four cases and poor in two cases, with mean score of 0, 0.83, 1.50±0.5,0,0,0, 1.16±0.40,0, 1.33±0.84. The mean score of radiological and clinical assessment was 4.88±1.85 out of 40 points, lesser score indicates effectiveness of the surgical procedure. The lamenessfrom grade V improved onby 45 days to grade I except one dog at grade II, by 60th day, all 5 dogs progressed to grade I and one dog to grade II. The post-operatively radiographic evaluation on day one revealed hip showing cup of the prosthesis into acetabulum.

Result: Total hip replacement using cemented prosthetics for management of Hip dysplasia in dogs was found to be effective in dogs with more than 20 kg body weight and returned to normal limb function after 45th post operative day in 4 out of 6-dogs, whereas in other two dogs, there is a complication of loosening of acetabullar cup after 60 days, the complications will be addressed with uncemented implants.

Key words: Canines, Cemented prosthetics, Hip dysplasia, Prosthetics, Total hip replacement.

INTRODUCTION

Canine hip dysplasia affects bone growth and remodelling, resulting in abnormal friction between both joint surfaces and, subsequently, joint deformity and degenerative joint disease (DJD) (Lohi and Nicholas, 2009).

Hip dysplasia is a disease with varying degree of laxity of hip joint and varying degrees of shallow acetabulum and flattening of femoral head, leading to osteoarthritis. (Smith *et al.,* 2012).

The clinical sign along with Ortolani test for assessing joint laxity were used for diagnosis (Corr, 2007). The first radiographic signs of canine hipdysplasia, seen as early as 7 weeks of age, are subluxation of the femoral head and under development of the craniodorsal acetabularrim (Smith *et al*., 2012).

Treatment of hip dysplasia include medical or surgical. Surgical treatment should be the option when the response to the conservative management was not satisfactory (Schulz and Dejardin, 2003).

Total hip arthroplasty consists of femur component the stem and the head is made of stainless steel or cobalt chrome or titanium, acetabular component is made of ultra high molecular weight polyethylene (UHMWPE) cup and for fixing polymethyl methacrylate (PMMA) bone cement is used (Olmstead *et al.*, 1983 and Hulse and Johnson, 2007).

[1]Department of Veterinary Surgery and Radiology, College of Veterinary Science, Rajendrangar, Hyderabad-500 030, Telangana, India.
[2]Department of Surgery and Radiology, College of Veterinary Science, Korutla, Jagytial-505 326, Telangana, India.
[3]Department of Veterinary Clinical Complex, College of Veterinary Science, Rajendrangar, Hyderabad-500 030, Telangana, India.
[4]Department of Anatomy, College of Veterinary Science, Rajendrangar, Hyderabad-500 030, Telangana, India.

Corresponding Author: N. Venkatesh, Department of Veterinary Surgery and Radiology, College of Veterinary Science, Rajendrangar, Hyderabad-500 030, Telangana, India.
Email: venkinvenkat@gmail.com

How to cite this article: Venkatesh, N., Reddy, K.J.M., Sekhar, E.L.C. and Rajendranath, N. (2024). A Clinical Study on Total Hip Replacement using Cemented Prosthetics for Management of Hip Dysplasia in Dogs. Indian Journal of Animal Research. 58(8): 1283-1293. doi: 10.18805/IJAR.B-5217.

Submitted: 07-08-2023 **Accepted:** 25-01-2024 **Online:** 19-03-2024

The surgical options recommended for each dog differ depending on age and clinical condition. Hence, the present work was to evaluate the clinical efficacy of cemented prosthetics in total hip replacement for repair of canine hip dysplasia.

MATERIALS AND METHODS

Anamnesis

A total of 98 clinical cases of canine hip dysplasia were recorded in dogs during the period of the study. The breed wise was Labrador retriever 26.5% (26), German Shepherd 20.4% (20), Goldenretriever 17.3% (17), Non-descript 8.1% (8), Great Dane 3.0% (3), Pomeranian 4.0% (4), Doberman 5.1% (5), Pug 5.1% (5), Rottweiler 4.0% (4), Saint Bernard 6.1% (6). The age distribution in dogs less than one year, one to four years, four to eight years and above eight years were 48.1% (48), 22.2% (22), 10.2% (10) and 18.3% (18) respectively. Gender distribution was 61.2% (61) and 38% (38) in males and females respectively. The 6 selected dogs for total hip replacement were males and average age ranges from 29.33±13.55 days and 27.5±1.80 kg and duration of lameness ranging from 54.6±13.31 days (Table 1).

Pre-operative observations

Among the 6 selected dogs for surgery, the signs of Bunny hopping gait (n=4), difficulty in rising (n=6), exercise intolerance and reluctance to walk or run (n=4), Hip asymmetry (n=4) and atrophy of thigh muscles (n=3) were noticed in dogs with hip dysplasia (Table 2). The dogs with hip dysplasia with hip subluxation test and Ortolani sign. (Table 3). These laxity measurements are calculated from radiographs for Norbergangle and the distraction index measured on the distraction radiograph (Table 4) were used for diagnosis. Norberg's angle were less than 105° and

Table 1: Details of dogs selected for the study.

Dog no.	Breed	Gender	Age (months)	Body weight (kg)	Limb involved	Duration of lameness	Etiolgoy of hip dysplaia
1	Labrador retriever	Male	14	25	Right	1 Month	Over weight
2	Labrador retriever	Male	11	28	left	2 Months	Over weight
3	Labrador retriever	Male	24	29	Right	20 Days	Over weight
4	Labrador retriever	Male	9	31	Left	3 Months	Overweight
5	Non-descriptive	Male	22	20	Left	5 Days	Slippery floor
6	Golden retriever	Male	96	32	Right	6 Months	Slippery floor
Mean±Standard error		Male=6	29.3±13.55	27.5±1.80	R=3, L=3	54.6±13.31	-

Table 2: Clinical signs exhibited by dogs selected for the study.

Dog no.	Limb involved	Lameness	Bunny hopping gait	Difficulty in rising	Reluctance to walk	Hip asymmetry	Atrophy of thigh muscle
1	Right	√	√	√	√	√	√
2	left	√	√	√	√	×	√
3	Right	√	√	√	×	×	×
4	Left	√	×	√	×	√	×
5	Left	√	×	√	√	√	×
6	Right	√	√	√	√	√	√

√- Present; ×- Absent.

Table 3: Physical examination findings of dogs selected for the study.

Case no.	Limb affected	Abduction external rotation test	Hip extension test	Hip subluxation test	Ortolani sign	Crepitation	Range of motion (ROM)
1	√	×	×	√	√	×	×
2	√	×	×	√	√	×	×
3	√	×	×	√	√	×	×
4	√	×	×	√	√	×	×
5	√	×	×	√	√	×	×
6	√	×	×	√	√	×	×

√- Positive; x- Negative; <- Reduced ROM.

distraction index of 0.71 is consistent with increased laxity and high risk for developing osteoarthritis. Pre-operatively all dogs with Hip dysplasia exhibited grade III to grade IV lameness (normal weight bearing at rest and favours the affected limb) Vasseur *et. al* (1995) (Fig 1).

Table 4: Norbergs angle and distraction index in all cases.

Dog no.	Norberg angle in degrees (°)		Distraction index (DI= D/R)
	Right hip	Left hip	
1	51.6	-	07
2	99.7	96	0.8
3	85.4	83.3	0.6
4	96	93.1	0.8
5	98.5	92.5	0.7
6	96.1	94.2	0.8

All dogs with hip dysplasia pre-operative radiographs showed moderate to severe periarticular osteophyte formation, osteophytes on the cranial and caudal acetabular margins with varying degree of subluxation (Fig 2).

Planning of surgery

The hip Joint is accessed through cranio lateral approach good visualization of the joint as described by Johnson (2014).

Anaesthesia

Xylazine hydrochloride at the rate of 1 mg/kg body weight and Ketamine hydrochloride @ 10 mg/kg intramuscularly were used for producing sedation, later induction was done



Fig 1: Pre-operative weight bearing of the dogs in all cases of dogs with hip dysplasia showing bunnyhop gait and pointing hind foot limb to ground.

with propofol at the rate of 5 mg/kg body weight intravenously and maintained with isoflurane anaesthesia with 100 per cent oxygen and maintained in IPPV with setting of respiration rate 15 minute, Inspiratory.

Implants

The femoral stem and acetabular cup was designed in different sizes *viz*. size- S, size- M and size- L. The size of the acetabular cup used ranged from 20 to 25 mm outer diameter. The head sizes used were small (4) and medium (2) in the study which were from ultra high molecular weight polyethylene (UHMWPE) (Fig 3).

Surgical procedure

Craniolateral approach for femoral neck and head and acetabulum. The superficial fascia of the biceps femoris muscle incised along the cranial border of the biceps and the biceps were retracted caudally to reveal the tensor fascia lata and superficial gluteus muscle. Exposure to the dorsal aspect of the joint capsule was enhanced by performing



Case 1. subluxation of the right hip joint with osteoarthritis.



Case 2. severe osteoarthritis with bilateral femoral periarticular osteophyte formation, osteophytes on the cranial and caudal acetabular margins.



Case 3 severe osteoarthritis with right femoral periarticular osteophyte formation, osteophytes on the caudal acetabular margins.



Case 4. severe osteoarthritis with bilateral femoral periarticular osteophyte formation, osteophytes on the cranial and caudal acetabular margin and subluxation.



Case 5. severe osteoarthritis with bilateral femoral periarticular osteophyte formation, osteophytes on the cranial and caudal acetabular margins.



Case 6. osteoarthritis with right femoral periarticular osteophyte formation, osteophytes on the cranial and caudal acetabular margins.

Fig 2: Shows hip dysplasia with moderate to severe periarticular osteophyte formation, osteophytes on the cranial and caudal acetabular margins with varying degree of subluxation.

tenotomy of the superficial gluteus at the greater trochanter. Partial tenotomy of deep gluteal muscle insertion (tag deep gluteal tendon with suture, aiding in retraction and identification of tendon for closure). Using an oscillating saw, the femoral head ostectomy was performed. The femoral canal was reamed with femoral reamer. The acetabulum was reamed with acetabular reamer to remove the remnants of tissues attached to the acetabular surface and to convert the acetabulum into hemisphere for the exact placement of the acetabular cup. Final reaming was made with finer acetabular reamer and was directed in such a way to achieve 20 to 30° of anteversion. The cranial and medial aspect of the acetabulum was reamed, with taking precaution not to over ream the dorsal rim. Three to four anchoring holes for keying of the PMMA to the acetabulum over the dorsal rim of acetabulum were made using drill bit of appropriate size. The PMMA- bone cement was prepared by mixing monomer and polymer in a sterile cup (First generation cement mixing technique) to come to doughy consistency by hand mixing and rolled into ball and was impacted into acetabulum. The acetabular cup was impacted with an acetabular cup impacter, the cup holds firmly in the acetabular cavity within 2 to3 minutes after fixation. After fixation, the cup was checked for integration and firmness for loosening. The stem was inserted in normoversion or slight retroversion to prevent luxation and improper wear on tear on the head and acetabular component. The head was fixed to the stem and then the femoral head was reduced into the acetabulum by slight flexion and internal rotation of the femur. The capsule was closed with PGA 1-0 by simple interrupted fashion. The muscle tenotomy performed was closed with PGA 1-0 in interrupted fashion. The muscle, subcutis and skin were closed as per standard methods as mentioned earlier (Fig 4).

RESULTS AND DISCUSSION

In the present study the out of 6 dogs, the etiology was overweight in 4-dogs and in 2-dogs it was due to slippery floor along with genetic predisposition which is in agreement with Krontveit *et al*. (2010) where as some other authors Madsen *et al*. (1991) reported that abnormal and delayed endochondral ossification in the coxofemoral joint has been identified in 15 day old dogs that developed CHD at the age of 12 months old and Fries and Remedios (1995) opined that excess dietary calcium and vitamin D may contribute to the development of canine hip dysplasia in genetically predisposed animals, Krontveit *et al*. (2012) reported that puppies ≤3 months of age should not be allowed access to stairs, but should be allowed outdoor exercise on soft ground in moderately irregular land to decrease the risk for developing hip dysplasia.

In the present study, the age distribution in dogs is in congruence with Arunprasad *et al*. (2012) and Srinivasamurthy (2015).

In the present study, gender wise distribution is in congruence with Arunprasad *et al*. (2012) and Srinivasamurthy (2015) contrary incidence in females are more by Coopman *et al*. (2008) where as others reported no difference in sex for incidence of hip dysplasia are Fries and Remedios (1995) and Stanin *et al*. (2011).

In the present study, all the dogs exhibited the signs with varying degrees of lameness is in congruence with Arunprasad (2009) Tobias and Johnston (2012) and Srinivasamurthy (2015).

The dogs with hip dysplasia were negative for the abduction external rotation test and hip extension test but positive for hip subluxation test and Ortolani sign. The Norberg's angle for both limbs for all cases were less than 105 degrees is considered abnormal and distraction index for all cases were more than 0.3. and diagnosis of canine hipdysplasia were based on subluxation (hiplaxity) and radiographic evidence of degenerative joint disease. These findings are in congruence with the findings of several authors like Schachner and Lopez (2015) and Peterson (2017).

The implant was made up of 316 L medical grade stainless steel. The bone cement used in this study was polymethyl methacrylate (PMMA). The acetabular cup and



Fig 3: Implants used in the present study.

corresponding femoral stem of small (4) and medium (2) size were used in 6 cases. This is in accordance with Arunprasad (2009).

The normal angle of anteversion was 20 to 27°. The acetabular cup used in this study ranged from 20 to 22 mm outer diameter with radio opaque wire for defining the lateral angle of the cup. The same procedure were used by several workers for cemented total hip replacement like Iwata *et al*. (2008); Arunprasad (2009); Minto *et al*. (2011); Fitzpatrick *et al*. (2012) whereas Ni *et al*. (2005) reported the

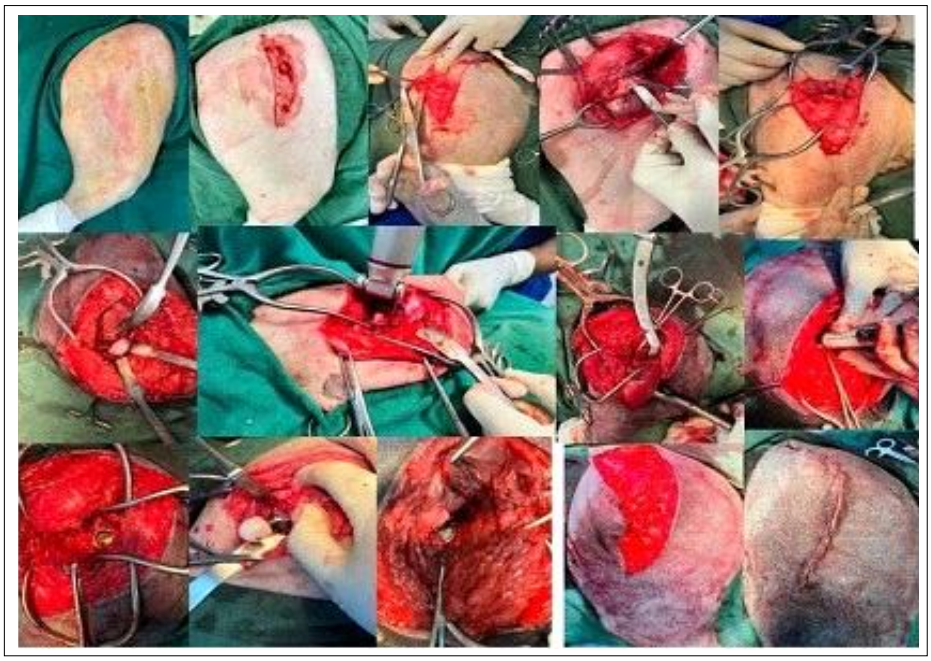

Fig 4: Surgical procedure for total hip replacement with cemented prosthetics in dog.



Fig 5: Post operative weight bearing on the dogs under gone total hip replacement.

Table 5: Functional assessment scoring by owners assessment questionnaire (WOMAC score) (Iwata *et al.,* 2008).

Case no.	Experience stiffness in the morning or after rest	Has trouble climbing stairs	Posture for toileting	Symmetry when sitting down	Sleep disruption	Vocalisation at rest	Exercise tolerance	Severity of limp	Off leash activity	Ease of jumping	Distance the pet walk on leash with comfort.	Total
1	1	0	0	0	0	1	0	0	2	1	1	6
2	2	1	2	2	1	2	3	2	0	3	2	20
3	0	0	1	0	0	0	1	0	0	1	1	3
4	1	0	0	0	0	0	1	1	1	2	3	9
5	2	4	2	4	2	1	3	3	0	2	4	27
6	0	0	0	0	0	0	1	1	0	0	1	3
Mean±Standard error	1.0±0.37	0.83±0.65	0.83±0.40	1.0±0.68	0.50±0.34	0.66±0.33	1.50±0.50	1.16±0.48	0.50±0.34	1.50±0.43	2.0±0.52	11.33± 4.06

Table 6: Clinical and radiological scoring for total hip replacement (WOMAC score) (Iwata *et al*., 2008).

Case no.	Canal fill of stem-score by number based on percentage canal fill	Cement mantle width-stem and cup	Presence of radiolucent line around the acetabular component	Cement porosity	Position of stem	Position of cup	Pain on deep palpation of the hip area	Early complication	Late complication	Total
1	0	0	0	0	0	0	1	0	0	0
2	0	2	2	0	0	0	2	0	4	10
3	0	0	2	0	0	0	1	0	0	3
4	0	1	2	0	0	0	0	0	0	3
5	0	2	3	0	0	0	2	0	4	11
6	0	0	0	0	0	0	2	0	0	2
Mean±Standard error	0	0.83	1.50±0.5	0	0	0	1.16±0.40	0	1.33±0.84	4.88±1.85

uncemented femoral fixation had better long term outcome, especially for younger patients and Iwata *et al*. (2008) carried out a retrospective study to compare outcomes between cemented and uncemented total hip arthroplasties and found that uncemented total hip replacement had better results.

Post-operative clinical observations

Clinical evaluation of the treated dogs on 2nd day post operatively indicated functional outcome (on the basis of WOMAC score) as excellent in four dogs and good in 2 dogs as the scores of different parameters like Experience stiffness in the morning or after rest, Has trouble climbing stairs, Posture for toileting, Symmetry when sitting down, Sleep disruption, Vocalisation at rest, Exercise tolerance, Severity of limp, Off leash activity, Ease of jumping, Distance the pet walk on leash with comfort, mean scores is 1.0±0.36, 0.83±0.65, 0.83±0.40, 1.0±0.68, 0.50±0.34, 0.66±0.33, 1.50±0.50, 1.16±0.47, 0.50±0.34, 1.50±0.42, 2.0±0.51 and over all mean of functional outcome is 11.33± 4.06 out of 44 points, Lower

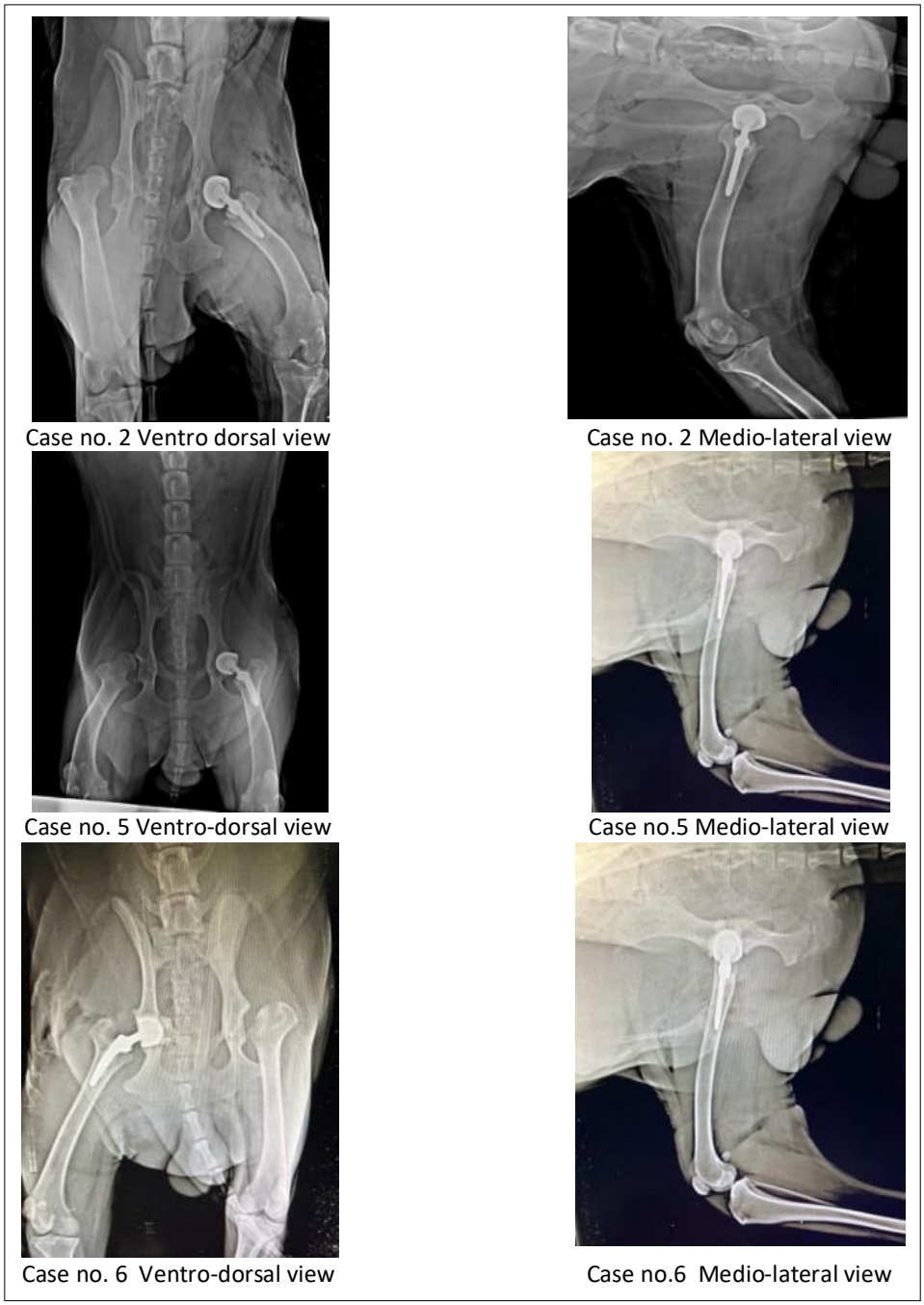

Fig 6: Immediate post operative radiographs of dogs showing postion of implant in total hip replacement technique.

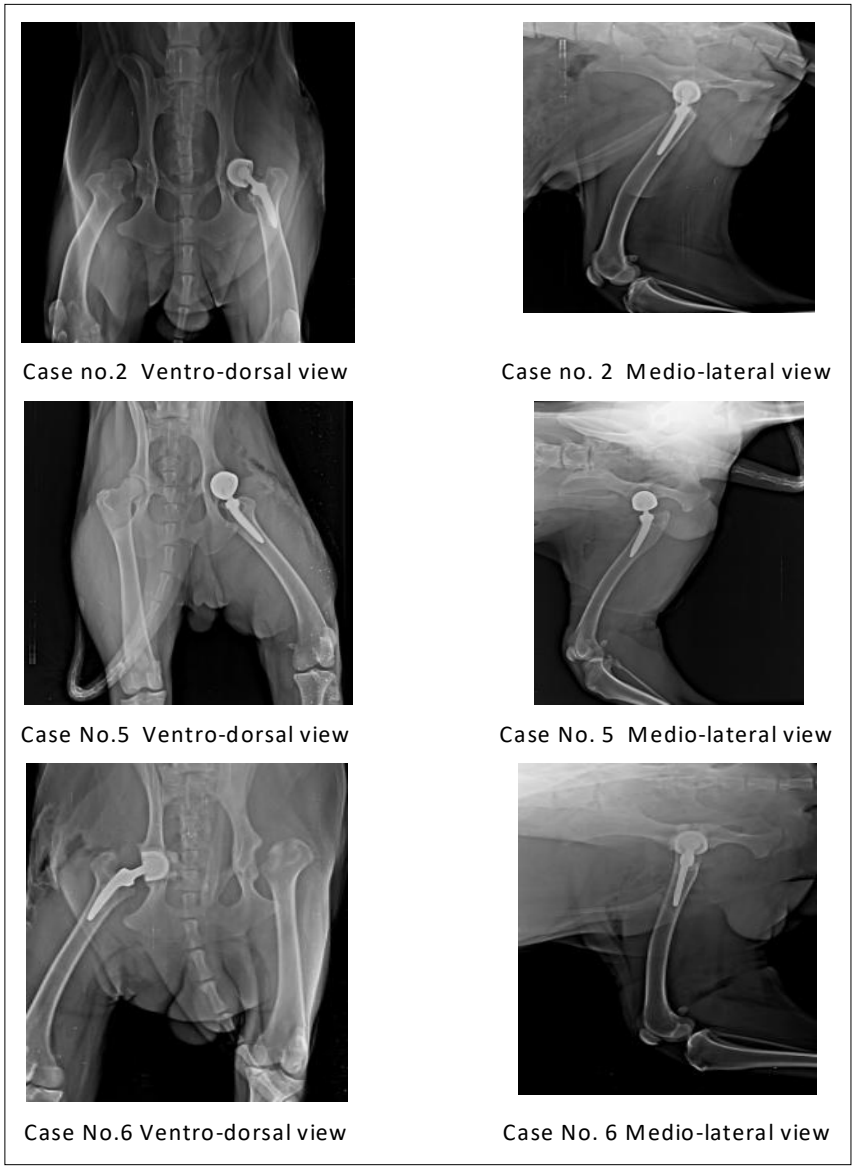

Fig 7: Post operative radiographs of dogs showing position of implant in total hip replacement technique on day 30.



Fig 8: Radiograph showing the acetubular cup loosening in case no-5.

scores reflect better function than higher scores (Table 5). Whereas WOMAC scoring index was by standard hip extended radiograph for radiological and clinical assessment performed as per, that included the mean score of canal fill, cement mantile width, presence of radiolucent line, cement porocity, postion of stem, position of cup, pain on deep palpation, early complication and late complication are excellent to good in four cases and poor in two cases. WOMAC scoring index was found to be mean scores of 0, 0.83, 1.50±0.5,0,0,0, 1.16±0.40,0, 1.33±0.84. The mean score of radiological and clinical assessment was 4.88±1.85 out of 40 points, lesser score indicates effectiveness of the surgical procedure (Table 6). The results were in congruence with other s like Iwata *et al.* (2008), Minto *et al*. (2011) and Arunprasad *et al.* (2015).

Table 7: Showing the pre and post operative grading of lameness in dogs subjected to total hip replacement (Vasseur *et al.,* 1995).

Case no.	Pre-operative	Post-operative					
		Day 1	Day 7	Day 15	Day 30	Day 45	Day 60
1	III	V	III	II	I	I	I
2	IV	V	II	II	II	I	I
3	III	V	II	II	II	I	I
4	III	V	II	II	I	I	I
5	IV	V	IV	III	III	II	II
6	III	V	II	II	II	I	I
Mean±standard error	3.33±0.21	5±0.0	2.5±0.34	2.16±0.16	1.83±0.30	1.16±0.16	1.16±0.16

Grade I- Normal weight bearing on all limbs at rest and while walking. Grade II- Normal weight bearing at rest, favors affected limb while walking. Grade III- Partial weight bearing at rest and while walking. Grade IV- Partial weight bearing at rest; does not bear weight on affected limb while walking. Grade V- Does not bear weight on limb at rest or while walking.

Lameness grading

In the present study, it is observed on post-operative day one, all the dogs showed lameness of grade V, evidenced by lifting of limb off the ground. Whereas by day 7, 4 dogs progressed to grade II and one dogs to grade III and another to grade IV, by day 15 all dogs progressed to grade II except dog 5. By day 45, all dogs progressed to grade I except one dog at grade II, by 60th day, all 5 progressed to grade I and one dog to grade II (Table 7) (Fig 5). Similar results were reported by Minto *et al*. (2011), Fitzpatrick *et al.* (2012) and Arunprasad *et al* (2015).

Post-operative radiographic observations

The radiographic evaluation post-operatively on day one revealed hip showing cup of the prosthesis into acetabulum (Fig 6). The stem of the prosthesis was fixed in the femoral canal and occupied the entire diameter of femoral canal till the end of study period, (Fig 7) whereas in two dogs, the where cup loosening of the acetabular cup was noticed after 60 days. This is in congruence with Ota *et al*. (2005) and Andrews *et al*. (2008).

Complications

The acetabular cup loosening was noticed for which the implant was removed and made to form pseudo arthrosis as in case of excision arthroplasty (Fig 8). The dogs showed partial weight bearing at rest and while walking. The complications reported by other workers are Andrews *et al.* (2008) also reported similar complications where as Vezzoni *et al*. (2013) also described the application of cementless acetabular component specifically designed for the treatment of cup loosening.

CONCLUSION

The present clinical study on total hip replacement using cemented prosthetics for management of Hip dysplasia in dogs was found to be effective technique in dogs with more than 20 kg body weight and in dogs over 20 kg, the complications of loosening of acetabullar cup after 60 days would be addressed with uncemented implants which are more costly and need surgeon's expertise and following standard procedure.

Conflict of interest

All authors declared that there is no conflict of interest.

REFERENCES

Andrews, C.M., Liska, W.D. and Roberts, D.J. (2008). Sciatic neuropraxia as a complication in 1000 consequetive canine total hip replacement. Vet. Surg. 37(3): 254-262.

Arunprasad, A. (2009). Studies on coxofemoral joint diseases in dogs. Ph.D Thesis, Tamil Nadu Veterinary and Animal Sciences University, Chennai.

Arunprasad, A., Shafiuzama, M.S., Ayyappan, R., Kumar, S. and Jayaprakash, R. (2012). Incidence of coxofemoral joint affections in dogs-A clinical study of 575 patients. Intas Polivet. (II): 281-283.

Arunprasad, A., Shafiuzama, M.S., Jayaprakash, R., Ayyappan, S., Ganesh, T.N. and Thilagar, S. (2015). Cemented total hip arthroplasty in dogs. IOSR-JAVS. 8(8). Ver.II: 36-42.

Coopman, F., Verhoeven, G., Saunders, J., Duchateau, L. and Van Breeh, (2008). Prevalence of hipdysplasia, elbow dysplasia and humeral head osteochondrosis in dog breeds in Belgium. Veterinary Record. 163: 654-658.

Corr, S. (2007). Hip dysplasia in dogs: Treatment options and decision making. In Practice. 29: 66-75.

Fitzpatrick, N., Nikolaou, C., Yeadon and Hamilton, M. (2012). String-of-pearls locking plate and cerclage wire stabilization of periprosthetic femoral fractures after total hip replacement in six dogs. Vet. Surg. 41: 180-188.

Fries, C. and Remedios, A. (1995). The pathogenesis and diagnosis of canine hip dysplasia: A review. Canadian Veterinary Journal. 36: 494-502.

Hulse, D.A. And Johnson, A.L. (2007). Management of Joint Disease. In: Small Animal Surgery, [Fossum, T.W. (eds)], 3rd edn, Mosby, St. Louis. 883-998.

Iwata, D., Broun, H.C., Black, A.P., Prestonand, C.A. anderson, G.I. (2008). Total hiparthroplasty outcome assessment using functional and radiographic scores to compare canine systems. Vet. Comp. Orthop. Traumatol. 21: 221-230.

Johnson, K.A. (2014). Approach to the Craniodorsal and Caudodorsal Aspects of the Hip Joint by Tenotomy of the Gluteal Muscles. In: Piermattei's Atlas of Surgical Approaches to the Bones and Joints of the Dog and Cat. 5th Edition Elsevers. 346-349.

Krontveit, R.I., Nodtvedt, A., Saevik, B.K., Ropstad, E., Skogmo, H.K., Trangerud, C. (2010). A breeds in Norway (1998-2001). Preventive Veterinary Medicine. 97(3-4): 252-263.

Krontveit, R.I., Nodtvedt, A., Bente, K.S., Erik, R., Cathrine, T. (2012). Housing and exercise related risk factors associated with the development of hip dysplasia asdetermined by radiographic evaluation in a prospective cohort of new foundlands, labrador retrievers, leonbergers and Irish wolfhounds in norway. American Journal of Veterinary Research. 73: 838-846.

Lohi, H. and Nicholas, (2009). Unlocking the genetic make-up of canine hip dysplasia. The Veterinary Journal. 181(2009): 77-78.

Madsen, J.S., Reimann, I., Svalstoga, E. (1991). Delayed ossification of the femoral head in dogs with hipdysplasia. Journal of Small Animal Practice. 32: 351-354.

Minto, B.W., Brandao, C.V.S., Pereira, G.J.C., Campagnol, D., Mamprim, M.J., Padovani, C.R., Ranzani, J.J.T. (2011). Modularhybrid total hip arthroplasty. Experimental study in dogs. Acta. Vet. Scand. 53: 46-52.

Ni, G.X., Lu, W.W., Chiu, K.Y. and Fong, D.Y.T. (2005). Cemented or uncemented femoral component in primary total hip replacement? A review from a clinical and radiological perspective. J. Orthop. Surg. 13(1): 96-105.

Olmstead, M.L., Hohns, R.B. and Turner, T.M. (1983). A five year study of 221 total hip replacement in the dogs. J. Am. Vet. Med. Assoc. 183: 191-194.

Ota, J., Cook, J.L., Lewis, D.D., Tomlinson, J.L., Fox, D.B., Cook, C.R., Schulz, L.G. and Brumilt, J. (2005). Short term septic loosening of femoral component in canine total hip replacement, effect of cementing technique on cement mantel grade. Vet. Surg. 34: 345-352.

Peterson, N.C. (2017). Canine hip dysplasia: Pathogenesis, phenotypic scoring and genetics. The Dulhut Journal of Undergraduate Biology. 4: 19-27.

Schulz, K.S. and Dejardin, L.M. (2003). Surgical Treatment of Canine Hip Dysplasia. In: Text Book of Small Animal Surgery 3rd Edition, W.B. Saunders Company, Philadelphia. 2029-2059.

Schachner, E.R. and Lopez, M.J. (2015). Diagnosis, prevention and management of canine hip dysplasia: A review. Veterinary Medicine Research and Reports. 6: 181-192.

Smith, G.K., Karbe, G.T., Kimbley, A., Agnello and Mischa, B., McDonald-Lynch, (2012). Pathogenesis, Diagnosis and Control of Hip Dysplasia In: Text book of Veterinary Surgery Small Animal Vol 1 Elsevier Publication. Pp 1028.

Srinivasamurthy, (2015). Studies on total hip replacement and excision arthroplasty for hip disorders in dogs, Ph.D Thesis, Karnataka Veterinary Animal and Fisheries Sciences University, Bidar.

Stanin, D., Pavlak, M., Vrbanac, Z. and Potocnjak, (2011). Prevalence of hip dysplasia in dogs according to official radiographic screening in Croatia. Veterinarski Arhiv. 81(2): 235-248.

Tobias, K.M., Johnston, S.A. (2012). Veterinary surgery: Small animal. St Louis (MO): Elsevier.

Vasseur, P.B., Johnson, A.L., Buderberg, S.C., Linwln, J.B., Toombs, J.P., Whitebain, J.G and Lentz, E.L. (1995). Randamized controlled trial of the efficiency of carprofen, a steroidal anti-inflammatory drug in the treatment of osteoarthritis in dogs. J. Am. Vet. Med. Assoc. 206: 807-811.

Vezzoni, L.V., Montinaro and Vezzoni, A.A. (2013). Use of a revision cup for treatment of zurich cementless acetabular cup loosening. Veterinary and Comparative Orthopaedics and Traumatology. 26(5): 408-415.