REVIEW ARTICLE Indian Journal of Animal Research, Volume 58 Issue 10: 1633-1641 (October 2024)

Developmental Anatomy of Gray Matter of Spinal Cord in Animals with Special Reference to Prenatal Goat: A Review

S. Maya[1]

10.18805/IJAR.B-5302

ABSTRACT

Spinal cord is the major nerve tract of vertebrates, extending from the brain through the vertebral canal. Primordium, the neural tube was initially with thick lateral walls having three layers: inner germinal/ependymal layer, middle mantle layer forming the gray matter and outer marginal layer forming white matter. It presented a diamond-shaped lumen with a sulcus limitans, alar, basal, roof and floor plates and limiting membranes. Gray matter of the cord occupies the central region of spinal cord and in amniotes has in cross section, the well-known 'H' or butterfly-like shape. The white matter forms a thick peripheral zone of the cord and is divided by the gray columns into dorsal, lateral and ventral funiculi. There are three coumns for the gray matter, *viz.* the dorsal, ventral and lateral horns, with ventral ones being wider at the enlargements of the cord. Lateral horn appears only at thoracic, anterior lumbar and middle sacral levels. The layers of gray matter were laminae I to X. Lamina I or marginal zone capped the dorsal horn. Lamina II represented substantia gelatinosa and covered the dorsal horn, beneath marginal zone. Lamina III was an area with loosely arranged larger cells, entering the substantia gelatinosa. Lamina IV was a poorly defined cell column with nucleus proprius. Lamina V was a broad zone extending across the cervix of the dorsal horn; had spinal reticular nucleus and reticular processes. The region showed small to medium-sized cells which were most numerous in the zone between the ventral part of the dorsal horn and the lateral funiculus of white matter. Lamina VI was broad with unclear boundaries, related medially to central canal. It had compact medial and less compact lateral zones. Lamina VII shows the intermediate gray matter, with intermediolateral and intermediomedial nuclei, cervical nucleus of Stilling and Clark's column. Lamina VIII had cells of small and medium size and was not sharply distinguished from lamina VII. Lamina IX had alpha and gamma type of neurons, which were larger at enlargements. Ventral horn had lateral and medial nuclear groups of multipolar neurons. Medial nuclear groups were seen in all regions and lateral groups only at enlargements. Medial nuclear group had dorsomedial and ventromedial nuclei; whereas the smaller lateral nuclear group had dorsolateral and ventrolateral nuclei. In addition, the enlargements also had central and retrodorsolateral nuclei. Lamina X was seen around the central canal. Laminae varied in cell size and thickness between regions of the cord. Development of laminae and nuclei of spinal gray in fetuses corresponded to the progressive growth of muscles and skeleton. All the ten laminae were together present in the spinal gray matter by the end of gestation.

Key words: Development, Gray matter, Laminae, Nuclear architecture, Spinal cord.

Evolution of spinal cord

Vertebrate nervous system plays three vital roles. It acquaints the organism with and enables the organism to orient itself favourably in the surrounding environment; it makes possible the integrated control of the internal environment and in higher vertebrates serves as a center for learning. These functions are accomplished by the nerves, spinal cord and brain in association with receptors (sense organs) and effectors (muscles and glands).

Spinal cord is the major nerve tract of vertebrates, extending from the brain through the vertebral canal. It is composed of nerve fibers that mediate reflex actions and transmit impulses to and from the brain. The circuits of neurons in spinal cord can mediate a variety of functions such as walking movements, withdrawal and postural reflexes and local vascular reflexes and gastro-intestinal movements. The brain always functions in company of the spinal cord.

Phylogenesis of spinal cord

In progressing from lower to higher phyla, there is increased complexity of neuronal activity with the higher animals possessing a complex neuronal circuitry which permits greater functional variability. Among invertebrates, Protozoa (unicellular animals) are able to survive without neurons where the protoplasm is capable of performing nervous activity. It is in the Phylum Coelenterata (*e.g.* hydra, jellyfish, sea anemone) that we first identify true nerve cells (neurons), a nerve plexus and the presence of synapses. The tissue

[1]Department of Veterinary Anatomy, College of Veterinary and Animal Sciences, Kerala Veterinary and Animal Sciences University, Pookode, Wayanad-673 576, Kerala, India.

Corresponding Author: S. Maya, Department of Veterinary Anatomy, College of Veterinary and Animal Sciences, Kerala Veterinary and Animal Sciences University, Pookode, Wayanad-673 576, Kerala, India. Email: maya@kvasu.ac.in

How to cite this article: Maya, S. (2024). Developmental Anatomy of Gray Matter of Spinal Cord in Animals with Special Reference to Prenatal Goat: A Review. Indian Journal of Animal Research. 58(10): 1633-1641. doi: 10.18805/IJAR.B-5302.

Submitted: 11-01-2024 **Accepted:** 10-04-2024 **Online:** 12-06-2024

level of organization is first observed in these aquatic diploblastic (ectoderm and endoderm) animals. In Platyhelminthes (flatworms), the central nervous system is introduced being composed of brain and two ventral longitudinal nerve cords connected at intervals in a ladder-type formation; with the introduction of head and sense organs and formation of mesoderm. The Phylum Annelida (*eg*. common earthworm) possesses a number of ganglia: two in head region and one for each body segment and all components of a simple reflex arc. In the Phylum Arthropoda (*eg*. crayfish, insects and spiders), the sense organs especially the eyes, are very well developed. The brain is more complex, as a compound ganglionic mass within the head and functions as more than a relay center. Among vertebrates, the highest animal phylum, Chordata possess a dorsal neural tube (precursor of the cord) protected by a vertebral column (Truex and Carpenter, 1969).

Variations between species

Adult spinal cord is usually a slightly dorsoventrally flattened rod; this flattening is very pronounced in cyclostomes, where a band-like cord lies on the notochord. Among mammals, in tetrapods, the cord presents cervical and lumbar enlargements, associated with the limbs. The enlargements are absent in fishes, reptiles and birds. In mammals and many teloests, the spinal cord is much shorter than the vertebral column, tapering caudally to a fine strand, the terminal filament (*filum terminale*). The spinal cord lumen is reduced to a very small central canal in the adult. Gray matter of the cord occupies its central region and in amniotes has in cross section, the well-known 'H' or butterfly-like shape, being actually a four- fluted cylinder. In anamniotes, the gray matter in section varies from a rounded or quandrangular shape to a figure somewhat like an inverted T and Y; in cyclostomes, it forms a broad band. The white matter forms a thick peripheral zone of the cord and is divided by the gray columns into dorsal, lateral and ventral funiculi. Columns and funiculi are less defined in anamniotes; and they also differ in shape and proportions at different levels of the cord.

In domestic animals, segmental organization of the cord is much related to segmentation of postcranial body. There are distinct differences in the number of spinal cord segments between species that reflect individual morphology. Long animals have many spinal cord segments, while short animals have only a few. Locomotor specialisations of the animal have direct relationship with the number of cord and body segments. Similarly, the specializations in the postcranial body also have been related to the size and internal structure of the spinal cord segments. The cervical and lumbar regions of the cord show distinct enlargements that reflect the accumulation of more neurons within the spinal cord at these levels. Hence size and character of the part of the body being served, will definitely have a reflection on the number of neurons within the related cord segment (Ulinski, 1997).

In vertebrates with abundant tail musculature, such as lower fishes, tailed amphibians and reptiles and also in birds, the adult cord extends to the caudal end of the vertebral column. In frogs, it ends anterior to the urostyle. In a few bony fishes, the cord is actually shorter than the brain. It is only an inch or so in length in one fish, several feet long. In other vertebrates, the embryonic vertebral column elongates at a greater rate over the cord, hence at birth the cord is shorter than the column. In human, the spinal cord terminates at third lumbar vertebra. In dog, it is at the level of seventh lumbar vertebra. In ungulates, it is at varying levels along the length of second sacral vertebra showing an evolution-related ascending trend in the level of termination as it climbs up towards a higher level of organization of nervous system (Jenkins, 1978).

Ontogenesis of the cord

Embryonic period is the period of most rapid growth in the life of an organism. The embryo increases in size over three million times as it evolves from the fertilized ovum to the newborn. As the embryonic pattern foreshadows structure of spinal cord in adults, to achieve an insight into the architecture of the adult nervous system, it is essential to know how nervous system develops during embryonic life.

The first indication of the central nervous system (CNS) appears as the neural plate in the presomite stage, neural folds formed at the first somite stage and a completely closed neural tube is formed in a pig embryo of 5 mm size (13-20 somites) at 17 to 18 days of gestation. The cells bordering the neurocoel or the central canal multiply very rapidly at the sides of the tube to form a thick wall, while the roof and floor remain thin. The thick lateral walls have three layers: inner germinal/ependymal layer, middle mantle layer forming the gray matter and outer marginal layer forming white matter. The primordium had three layers by 19 days in pig (Rugh, 1964), 21 days in cattle (Reddy, 1972), 25 days in human (Langman, 1981) and 24 days in dog (Engel and Draper, 1982) and goat (Maya *et al.,* 2014) in the first month of gestation.

The arrangement of nuclei in the primitive epithelium made it possible to differentiate three zones or layers (Larsell, 1951). The three layers were formed by mitosis in the periluminal area, by migration of cells and by outgrowth of axons (Bohme, 1988).

The cephalic part of neural tube (encephalon) expands into the brain and the remaining part (myelon) forms the spinal cord. The neural tube was located between the body wall dorsally and notochord ventrally, being flanked by paired dorsal root ganglia.

The vertebrate spinal cord provides the best example for the symmetric development of the neural tube by layers (De Lahunta, 1983). The manner in which the neural tube comes to take the shape of adult spinal cord is related to the fate of the tissue inside the neural tube. The relationship of the gray and white matter in the adult spinal cord corresponds to that of mantle and marginal layers respectively in the developing neural tube (Jenkins, 1978; Clark, 1984; Rizzo, 2006, Maya *et al.,* 2014).

The lumen at the anterior portion of spinal part of neural tube presented a lateral sulcus, the sulcus limitans, which divided the lateral walls or lateral plate into a dorsal alar plate and a ventral basal plate. The sulcus limitans appeared as a result of the proliferation of cells in the wall of the neural tube (Arey, 1957), indicating a greater degree of proliferation and differentiation at the anterior part of the spinal cord.

The dorsal and ventral margins were thin and were formed by the roof plate and floor plate respectively. Towards the lumen, the neural tube was bounded by an internal limiting membrane and peripherally its extend was marked by an external limiting membrane by fifth week of gestation in man (Keith, 1947; Arey, 1957), in pig embryos by 26 days (Rugh, 1964; and Huettner,1967) and by 24 days in prenatal goat (Maya *et al.,* 2014).

Bruny and Reddy (1987) found that the radially directed processes formed from the base of many of the cells of the neuroepithelium contributed to the formation of the external glial limiting membrane. Bohme (1988) also observed that while both the alar and basal plate were composed of multiple cell layers representing the developing spinal cord gray matter, the roof plate contained matrix (ependymal) cells only initially, the peripheral surface of which formed the glia limitans.

Gray matter

In prenatal goat, the tubular neural tube (Fig 1) was seen upto second month, by which inner gray matter and outer white matter became evident. Gray matter contained nerve cells, nerve fibres, neuroglia and blood vessels, and became arranged as dorsal, ventral and lateral horns along the cord (Maya *et al.,* 2014). In human, it was during the 11th week of development, the mantle zone differentiated into dorsal and ventral horns; and it was in the 13th week, that the form similar to that of adult was reached (Keith, 1947). The dorsal horns were evident from 20 days of gestation onwards in rabbit (Sturrock,1982).

When dorsal funiculi were formed, gray matter of dorsal alar plate, at first united by the roof plate, became widely separated to form the dorsal horns. The dorsal horn could be divided into a pointed apex, an expanded head, and a constricted cervix. Ventral horn contained the motor cells, which gave rise to ventral root fibres of spinal nerves. Ventral horn varied greatly in form and size at different levels of cord. Lateral horns projected sideways from lateral intermediate substance by middle of second month in prenatal goat and were prominent at thoracic, anterior lumbar and middle sacral levels. A similar basic histological structure was found in human (Larsell, 1951) and domestic mammals (Kappers *et al.*, 1967; Papez, 1967; Dellmann and Mc Clure, 1975; Jenkins, 1978; Clark, 1984; King, 1987; Maya *et al.,* 2014).

Lamination of gray matter

In all higher mammals, gray matter showed the zoning/ lamination and has become a widely used method for localizing axonal degeneration in the mammalian spinal cord (Rexed, 1952). Rexed's cytoarchitectonic organization of the gray had nine cell layers and the region ten surrounded the central canal. Some of the layers corresponded to recognized cell columns and nuclei and others were a regional admixture of cells and fibres. The ten laminae from different segment levels constituted regions with characteristic properties, but their boundaries were zones of transition as seen in adult human spinal cord (Truex and Carpenter, 1969).

The organization and relative positions of the laminae were not uniform throughout the cord in mammals (Jenkins, 1978).

The neurons of gray matter took up their permanent stations in the gray horns as nuclear aggregations (cell columns or nuclei) by second month (Fig 2) in foetal goat (Maya *et al.,* 2014) and by third month (Keith,1947) to fourteen weeks (Larsell,1951) in human embryos.

In transverse sections of the cord these nuclei were apparent as cell groups distinguishable by their location, the size and form of cells and their internal structure. The cell columns may also be recognized in longitudinal sections of cord, but the knowledge as to their topography and functional significance, is still incomplete, while terminology varied greatly with different investigators (Larsell, 1951).

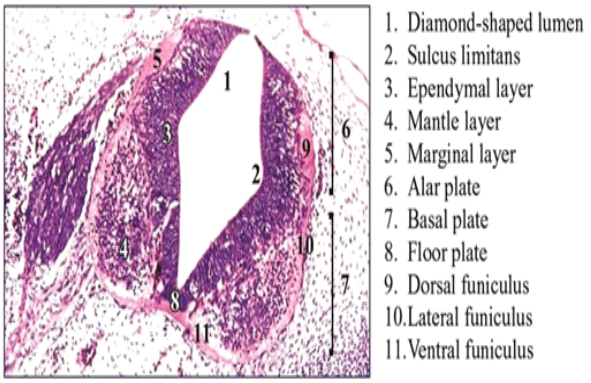

Fig 1: C.S. of neural tube at thoracic region (24 days).

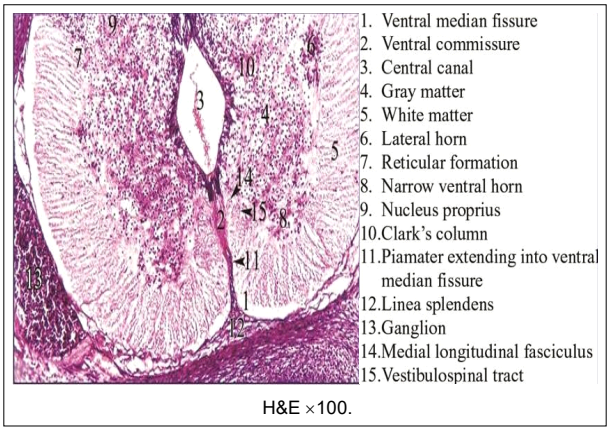

Fig 2: C.S. of at thoracic region (48 days).

By the end of gestation, neuropile network, consisted of nonmyelinated axons, oligodendrocytes, astrocytes and the neuroglial processes, as seen by the fifth month in prenatal goat (Maya *et al.,* 2014). In human foetus, it was in the 13th week, that a form similating that of adult was reached (Keith, 1947).

Dorsal horn

The dorsal horn of spinal gray in adult mammals presented three divisions, *viz.* marginal zone, substantia gelatinosa, and the body of the dorsal horn with nucleus proprius and Clark's column. In the groove between dorsal and ventral or lateral horns the reticular nucleus was also seen (Kappers *et al.,* 1967).

Dorsal horn consisted of receptive cells, which serve as a nucleus of termination of the afferent fibres of the spinal nerves. The fibres of the dorsal afferent nerve roots and collaterals from the fibres of the fasciculus gracilis and cuneatus terminated on the dorsal horn (Papez, 1967).

The dorsal horn was narrow in segments of thoracic region and wider at the enlargements in prenatal goat. Size of dorsal horn corresponded to the sensory field of distribution of dorsal roots and inversely to the length of cord segment. Correspondingly, the long thoracic segments had very narrow or short dorsal horn in human also. Most neurons in dorsal horn are relay neurons receiving primary peripheral afferent axons and sending their own axons to other spinal cells or to the higher centres in the brain stem or cerebellum. Most of them are also internuncial in function having connections with both primary relay and motor cells in the cord itself (Papez, 1967).

Eventhough the dorsal horns showed better differentiation towards the latter half of third month, their structure became similated that of adults only by end of gestation in buffalo calf (Rao, 1970), albino rat (Zargar *et al.*, 1975) and prenatal goat (Taluja *et al.,*1991; Maya *et al.,* 2014).

In prenatal goat, the adult structure of dorsal horn was seen between fourth and fifth months (Maya *et al.,* 2014). It appeared that development of dorsal horn eventhough happened at a later stage than that of ventral horn, makes the new born kid capable of sensory perceptions even at birth.

Lamina I

Lamina I or marginal zone covered the dorsal horn as cap by third month in prenatal goat (Maya *et al.,* 2014). Cells were scattered, arranged tangentially over dorsal horn throughout the cord. By fourth month, lamina I was seen as a layer (Fig 3). Cells were better differentiated by fifth month, (Fig 4) with lumbar enlargement having greater number of cells. In human also, neurons were most numerous in the lumbosacral segments, less so in cervical and lowest in the thoracic segments (Truex and Carpenter,1969).

Neurons of lamina I varied in size, shape and number between regions; and were with flattened disc-like dendritic domains. The largest of these elements, the marginal cells of Waldeyer, are responsive to nociceptive information involving tissue distruction, whether of mechanical or thermal nature. These cells are the association neurons of the dorsal gray column (Larsell, 1951). Their input appears to arise primarily from fine myelinated (and perhaps some unmyelinated) fibres of primary afferent source, and their axons project to the sagittal plane. Spines cover the dendrite branches of these propriospinal pathways (Clark, 1984).

Lamina II

Lamina II tallied with substantia gelatinosa (Clark,1984), covering the dorsal horn, beneath marginal zone (Fig 4). A long column extending the entire length of the cord (Jenkins, 1978), it receives an abundance of collaterals from the entering dorsal roots of the spinal nerves (Papez, 1967). Hence is the proper sensory nucleus, especially of cutaneous sensibility in spinal cord.

Organized into form with different shapes, it presented evident fibres and convolutions by third month in prenatal goat. It had two cell types (Todd and Lewis, 1986), which were very small with only a rim of perinuclear cytoplasm (Hannah and Nathaneil, 1975). The cells were closely packed till fourth month in prenatal goat. Later, the lamina was infiltrated by bundles of fibres with loosely packed cells in vertical/ radial orientation forming miniature palisades/ clumps (Maya *et al.,* 2014).

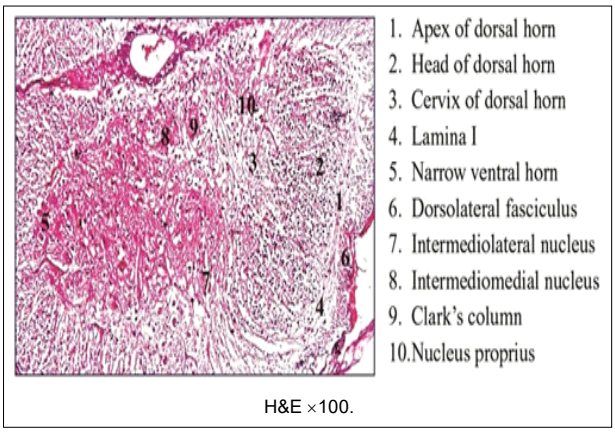

Fig 3: C.S. of T_8 (81 days).

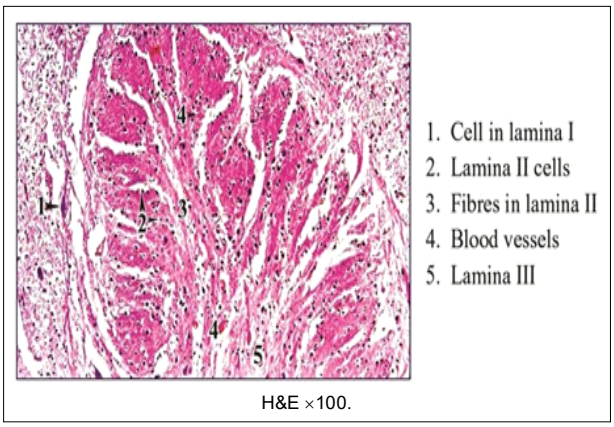

Fig 4: C.S. of T_{10} (142 days).

Lamina II had different shapes at different segments, with more size at enlargements A positive relationship between size of substantia gelatinosa and that of the spinal segments was evident as the largest substantia gelatinosa was seen in the largest segments.

Lumbar enlargement presented both substantia gelatinosa with maximum size and lamina I with more number of cells/unit area. It also indicated that Waldeyer's nucleus (marginal zone/Lamina I) is related in size to substantia gelatinosa. Cells in both Waldeyer's nucleus and substantia gelatinosa send their axons into the fasciculus proprius that surrounds the dorsal horn to transmit painful and thermal (pressor and depressor) sensibilities (Papez, 1967).

Lamina II presented convolutions by third month in some segments in the prenatal goat. By this age, the lamina II was organized into form with prominent fibres. According to advancement of age, convolutions also increased in frequency.

In mammals, especially in ungulates, the well-developed substantia gelatinosa presented convolutions. Since substantia gelatinosa forms a part of pathway for temperature and pain, the convolutions, which were surface extensions of gray matter and are considered typical, highly special sensory nuclei having distinct functions. Substantia gelatonosa varies in its degree of development in different mammals and there is reason to suppose that this variation is influenced to some extend by developing peripheral sensibility of organs principally that related with hairs (Kappers *et al.,* 1967).

Substantia gelatonosa is the principal sensory nucleus of the cord (Larsell, 1951), with the neurons being frequently bipolar in structure. Spines covered the dendritic branches of these cells, thereby marking them, with one exception, as the only spine-bearing neurons in spinal cord of adult mammals (Clark, 1984).

Lamina III

Lamina III was an area of loosely packed large cells, *viz.* large projection neurons and small interneurons (Rizzo, 2006). This zone appeared by the end of third month and entered into substantia gelatinosa near to the end of gestation in prenatal goat (Fig 4).

Lamina IV

Lamina IV appeared by third month and was unclear cell column, even by end of gestation. It had diffuse cell borders consisting of spindle-shaped and polygonal cells and showed nucleus proprius in prenatal goat (Fig 2, 3).

The neurons gave rise to spinotectal and spinothalamic tracts. These also gave rise to fibres, which entered the white matter on the same side. He also reported that the lateral base group of the posterior cell column consisted of Golgi type II cells. They were interneurons of gray matter (Larsell, 1951).

Nucleus proprius was proportional in size to substantia gelatinosa (Papez, 1967), had small to medium sized neurons, smallest in thoracic region and largest in lumbosacral enlargement in human (Truex and Carpenter, 1969).

The cells that formed nucleus proprius send their fibres into the lateral columns of same and of other side. These are concerned with the conduction of tactile sensibilities upwards to the brain-stem and thalamus (spino-thalamic) tract (Papez, 1967). Hence, in the prenatal goat also, smaller sized thoracic segments had small sized nucleus proprius and the segments of lumbar enlargement had a large nucleus proprius.

Lamina V

Lamina V was a broad zone extending across the cervix of the dorsal horn and appeared by second month in prenatal goat. It presented reticular processes and reticular nucleus (Fig 2) with small to medium-sized cells which were most numerous in the zone between the ventral part of dorsal horn and the lateral funiculus of white matter (Fig 5, 6, 7). From fourth month of gestation onwards, it presented medial and lateral divisions.

Bok designated this region as the spinal reticular nucleus (nucleus reticularis). The nucleus reticularis was found in the groove between the dorsal, ventral or lateral horns, which presented extensions of gray matter as reticular processes into the adjacent white matter. The gray matter and white matter became intermingled here as the reticular formation (Truex and Carpenter, 1969).

The reticular formation extended the entire length of the cord being well developed in anterior cervical segments in prenatal goat. Reticular formation (Jenkins, 1978) is the seat of consciousness making the animal aware about the changes in its surroundings (Dyce *et al*., 1996). The axons of the cells appeared to pass in part to the lateral and ventral funiculi of the opposite side by way of the ventral white commissure and in part to the lateral funiculus of the same side (Larsell, 1951).

Lamina VI

Lamina VI appeared as a broad layer with unclear margins lateral to the central canal and consisted of medial compact

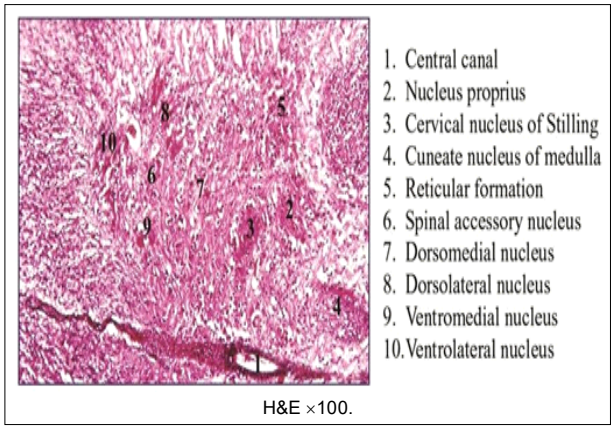

Fig 5: C.S. of Cervical region (81 days).

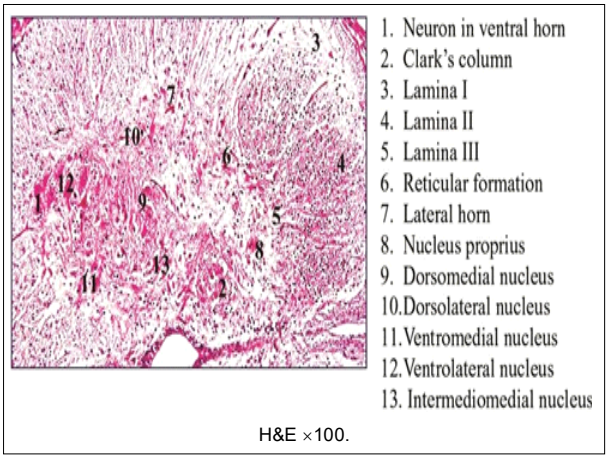

Fig 6: C.S. of T_1 segment (81 days).

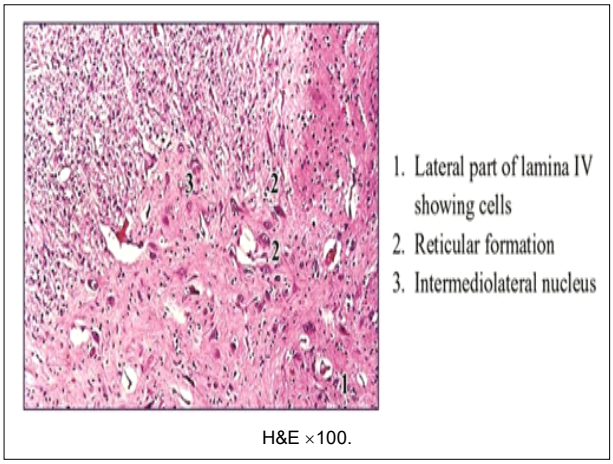

Fig 7: Middle lateral part of spinnal cord at T5 segment (124 days).

and lateral less compact zones by fourth month (Fig 8) in prenatal goat. It was typical only at enlargements (Larsell, 1951). Mostly, dorsal root group I sensory fibres to muscles end in medial zone and motor pathways terminate in neurons of lateral zone. Some axons (Truex and Carpenter, 1969) enter lateral white matter and fasciculus proprius.

Lateral horn

Lateral horn neurons were less differentiated than those of ventral horn. Lateral horn presents the nucleus of origin for general visceral efferent neurons of autonomic nervous system (Jenkins, 1978). These visceral efferent neurons are smaller than somatic motor cells (Truex and Carpenter, 1969). The cells of the lateral horn contribute (preganglionic) fibres that pass through the white rami communicans and terminate on cells of sympathetic (visceral) ganglia. This sympathetic column of cells is absent in cervical region. It is prominent in thoracic region, giving rise to cervical sympathetic chain, splanchnic nerves, white rami communicans of intercostal nerves and cardiac plexus. It appears again in lower sacral segments that supply hypogastric plexus (Papez, 1967).

Lamina VII

Lamina VII had most of intermediate zone of gray matter, with Clark's column, cervical nucleus of Stilling, intermediolateral nucleus and intermediomedial nucleus. Size of neurons in this zone was highly variable. Neurons of various centers of intermediate gray matter differed more with the range of their dendrites than with the size of their perikaryons (Grottel, 1979).

Substantia intermedia lateralis and centralis in lateral and medial aspects (respectively) of lateral horn are also seen in buffalo calf (Rao,1970), albino rat (Zargar *et al.,* 1975) and foetal goat towards end of gestation (Taluja *et al.,*1991).

Intermediolateral nucleus

In prenatal goat, intermediolateral nucleus was evident by second month at the thoracic segments. Lateral horn with intermediolateral nucleus was well developed in fifth month. It was surrounded by fibres in fourth month in prenatal goat (Maya *et al.,* 2014). Regular orientation of dendrites in intermediate region was seen in cat, forming elliptical/ circular gray matter (Rethelyi, 1976).

Lateral horn with intermediolateral nucleus (Fig 2, 3) extended from C8/T1 to anterior lumbar segments and also to sacral region in prenatal goat (Maya *et al.,* 2014) as in mammals (Jenkins, 1978). It extended from C8 to L3 segment in dog (Slawomirski *et al.,*1973), C8 to L4 level in cat (Okamoto, 1977) and at T1 to L3 in horse both in adults (Welento *et al*., 1979) and in prenatal period (Arciszewski *et al*., 1999b).

The intermediolateral nucleus was a clear cell column in lateral horn and had spindle-shaped cells by third month. The intermediate gray had shown two dispersed nuclei by fourth month in prenatal goat, *viz.* the medioposterior and intercornual columns.

The medioposterior column receives a large number of collaterals from the dorsal root zone that forms the lateral half of the fasciculus gracilis. The cells of this nucleus give off axons that form the large fasciculi proprii (reflex tracts) that surround the ventral horns of both sides. From this nucleus a large number of these fibres cross and form a prominent ventral commissure and ventral fasciculus proprius of the cord. For this reason, the medioposterior column is also called the commissural nucleus. The intercornual column gives rise to fibres that surround the lateral and ventral sides of the ventral horn and are known as the lateral faciculus proprius. These columns and fasciculi proprii are an essential part of the spinal mechanism for integration of spinal reflexes. The fibres of the fasciculi proprii terminate on the motor cells of the ventral horn and the cerebrospinal tracts end on the cells of the medioposterior column (Papez, 1967).

Intermediomedial nucleus

Intermediomedial nucleus (Fig 3) was seen ventral to Clarke's column first by 81 days in thoracic and lumbar segments. By 142 days, it was better developed, with fine

and uniformly distributed Nissl bodies in intermediomedial and intermediolateral nuclei in prenatal goat.

The nucleus intermediomedialis was observed in pig from C1 to Cy2 or Cy3 (Welento *et al.,* 1977). In prenatal horses it was an interrupted band from C1 to S5 (Arciszewski *et al.,* 1999a).

Dorsal dendrites of neurons of lateral horns in thoracic segments passed to lamina II, whereas ventral dendrites pass to lateral group of motor nuclei. Medial dendrites ran to medial zone of intermediate gray, while lateral ones run a short distance enter the lateral funiculus (Grottel and Teresa, 1979).

Cervical nucleus of stilling

This nucleus (Fig 5, 8) was seen by third month in cervical segments at base of dorsal horn in prenatal goat. During fourth month, in this same part at sacral segments, sacral nucleus of Stilling was presnt. It was with elongated cells in fifth month. Its position corresponded to that of the Clark's column in thoracic region. It becomes continuous with lateral cuneate nucleus of medulla (Larsell, 1951).

Clarke's column

This nucleus (Fig 2, 3) was seen laterally near central canal from first thoracic segment to anterior lumbar segments by 81 days in prenatal goat. Neurons had eccentrically placed nucleus by fourth month.

In cat, Clarke's column extended from T1 to L3 segment (Grant and Rexed, 1958). It was especially noticeable in T10 to T12 segments in human also (Truex and Carpenter, 1969). The column was well defined in C8 segment and extended through the thoracic and anterior lumbar regions being most prominent in T10, T12 and L1 regions in domestic animals (Dellmann and Mc Clure, 1975).

The nucleus was intimately related with fasciculus gracilis of dorsal funiculus in the white matter of spinal cord, which sends numerous collaterals into it. Neurons of this column give origin to crossed ventral spinocerebellar tract of other side; and dorsal spinocerebellar tract of same side. These tracts sent proprioceptive impulses into vermis of cerebellar cortex; and conduct deep/ muscular sensibility (Papez, 1967).

Ventral horn

Ventral horn presented lamina VIII and IX. Different regions showed varying shape and size of the horns, with the wider ones in the enlargements and narrow ones in anterior cervical and thoracic segments as found in human (Clark,1984) and prenatal goat (Maya *et al.,* 2014).

In mammals the ventral horn differentiated before the dorsal horn (Jenkins, 1978). In each lateral plate the neuroblasts became grouped from ventral to dorsal horn into: somatic motor, splanchnic motor (both in the basal lamina), splanchnic sensory and somatic sensory (both in the alar lamina).

Lamina VIII

By fourth month, this lamina was a mixture of small and medium-sized cells (Fig 9), not sharply distinguished from lamina VII in prenatal goat (Maya *et al.,* 2014) as found in human (Clark, 1984).

Lamina VIII excluded motor neurons and represented only interneurons. Their axons extend via propriospinal tracts to a number of spinal levels and serve as receptor sites for suprasegmental fibres, which synaptically transfer excitations to nearby motor neurons. The fibre tracts like vestibulospinal, pontine reticulospinal and tectospinal tracts and medial longitudinal fasciculus end on lamina VIII interneurons by synapse to affect, final common pathway in human. In cat, the lateral corticospinal tract synapsed on such cells, eventhough in primates and man the internuncial cell had been largely eliminated from the descending loop (Clark, 1984).

Lamina IX

Lamina IX had alpha and gamma neurons, which were larger at enlargements. In third month (Fig 3, 5, 6), multipolar neurons of ventral horn had eosinophilic cytoplasm and large eccentrically placed vesicular nucleus (Fig 9) in prenatal goat (Maya *et al.,* 2014). Larger alpha motor neurons among these somatic motor neurons, supplied striated (extrafusals) muscles and smaller gamma motor neurons supplied intrafusal fibres of muscle spindles. The alpha motor neurons are the largest cells of the spinal cord (Clark, 1984).

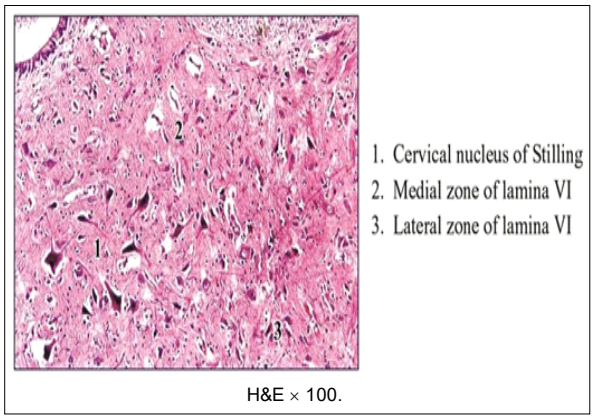

Fig 8: C.S. of C_1 segment showing grey matter ventral to substantia gelatinosa (124 days).

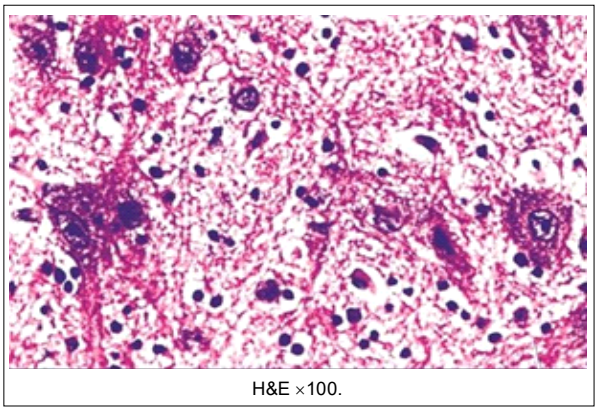

Fig 9: C.S. of laminane VIII and XI at L_4 segemt (102 days).

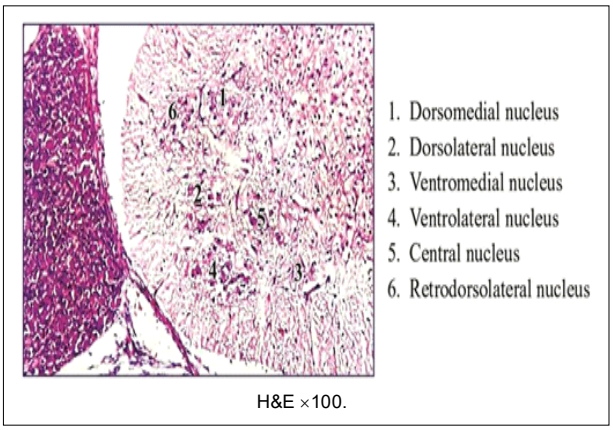

Fig 10: C.S. of lumbar enlargement (58 days).

The large (alpha) motor neurons of ventral horn were the largest in the enlargements of the spinal cord. Scattered among the large ventral horn cells were smaller cell bodies of gamma neurons. These neurons contribute axons to the ventral roots of the spinal nerves and had a transverse diameter of 30-70 mm and the cell body was 100 mm in length in human. Such elongated multipolar neurons had 3-20 dendrites and axons with diameter of 10-13 mm (Truex and Carpenter, 1969).

By second month in ventrolateral part of ventral horn, nuclear aggregations were seen (Fig 2) in prenatal goat (Maya *et al.,* 2014) as lateral and medial nuclei. Lateral nuclei had sharply limiting boundaries always at enlargements whereas medial nuclei were less defined with diffused borders with lamina VIII.

Medial nuclear group consisted of dorsomedial and ventromedial nuclei. The dorsomedial nucleus was smaller and most distinct in cervical and lumbar enlargements; and ventromedial nucleus extended throughout whole cord in buffalo calf (Rao, 1970), albino rat (Zargar *et al.*, 1975, 1979) and in goat foetuses (Taluja *et al.*, 1991; Maya *et al.,* 2014). Medial group innervated short and long muscles attached to axial skeleton. Lateral nuclear group became enlarged with a number of subgroups in enlargements, *viz.* dorsolateral and ventrolateral nuclei. This group innervated most distal portions of extremities (Truex and Carpenter, 1969).

In addition to this, enlargements presented central and retrodorsolateral nuclei (Fig 10) also (Rao, 1970; Zargar *et al.*, 1975, 1979; Taluja *et al.*, 1991; Maya *et al.,* 2014). Central nucleus innervates muscles attached to shoulder and pelvic girdle. Retrodorsolateral nucleus gives rise to motor fibres to distal muscles of digits (Larsell, 1951).

Number of cell groups in the cord is much smaller than number of muscles. So each cell group supply groups of muscles, which have a unity of action or whose actions are integrated to perform a common movement (Papez, 1967).

Based on the studies in cats, it was found that the ventral horn neurons smaller than 30 mm were connected with oxygen metabolism, while large cells were connected with glycogen metabolism (Rafalowska, 1977).

The volume of the cell body of the ventral horn neurons was proportional to the volume of its axon and the size of the motor unit being innervated (Fletcher, 1993).

Lamina X

Lamina X was seen around central canal. Towards end of gestation, the neurons were clear and their size did not vary between regions. The cells resembled the cells of reticular formation physiologically (Papez, 1967).

CONCLUSION

The differentiation of structures in the spinal cord proceeded from before backwards in domestic animals. The transformation of this embryonic organization into that of the mature spinal cord in domestic animals resulted from massive proliferation, asymmetric movement of immature neurons and development of neuronal processes. Thus, mantle layer was shaped like a butterfly with prominent dorsal and ventral horns. As limbs developed, the cervical and lumbosacral enlargements were formed at the corresponding levels of the cord. Also in the thoracic level, immature neurons migrated out of ventral horn to form the intermediate horn and these events were of almost the same sequence in all domestic animals.

All mammals show the same developmental pattern and therefore a 5 mm pig embryo was an exact replica of a four weeks-old human embryo; and a 10 mm pig embryo was an equivalent of a human embryo of the sixth week. In mammals, as exhibited by prenatal goat, the gray matter presented all ten laminae together, only towards the end of gestation as a result of gradual development. Hence, the development of nuclear aggregations probably corresponded to the progression of development of muscles and skeleton of foetus.

Thus, the spinal cord during its development in animals also proves the Recapitulation theory, which states that 'Ontogeny recapitulates phylogeny'.

Conflict of interest

The authors declare the existence of no conflict of interest.

REFERENCES

Arciszewski, M.B., Fleiger, S. and Zacharko, A. (1999a). Nucleus intermediomedialis in the spinal cord of the horse in the prenatal period. Medna Vet. 54: 1-9.

Arciszewski, M.B., Fleiger, S. and Zacharko, A. (1999b). Nucleus intermediolateralis in the spinal cord of the horse in the prenatal period. Medna Vet. 54: 11-17.

Arey, L.B. (1957). Developmental Anatomy- A Textbook and Laboratory Manual of Embryology. Sixth edition. W.B. Saunders Company, Philadelphia. p. 676.

Bohme, G. (1988). Formation of the central canal and dorsal glial septum in the spinal cord of domestic cat. J. Anat. 159: 37-47.

Bruni, J.E. and Reddy, K. (1987). Ependyma of the central canal of the rat spinal cord: A light and transmission electron microscopic study. J. Anat. 152: 55-70.

Clark, R.G., (1984). Anatomy of the Mammalian Cord. Hand Book of the Spinal Cord. (ed. Davidoff, R.A.). Marcel Dekker, New York. pp. 1-77.

De Lahunta, A. (1983). Veterinary Neuroanatomy and Clinical Neurology. Second edition. W.B. Saunders Company, Philadelphia. p. 471.

Dellmann, H.D. and Mc Clure, R.C. (1975). Central nervous system. Sisson and Grossman's The Anatomy of the Domestic Animals. Fifth edition. [Getty, R. (ed)]. W.B. Saunders Company, Philadelphia. pp. 1065-1080.

Dyce, K.M., Sack, W.O. and Wensing, C.J.G. (1996). Textbook of Veterinary Anatomy. Second edition. W.B. Saunders Company, Philadelphia. p. 856.

Engel, H.N. and Draper, D.D. (1982). Comparative prenatal development of the spinal cord in normal and dysraphic dogs: Embryonic stage. Am. J .Vet. Res. 43: 1729-1734.

Fletcher, T.F. (1993). Nervous System. Textbook of Veterinary Histology. Fourth edition. [Dellmann, D.H. (ed)]. Lea and Febiger, Philadelphia. pp. 87-107.

Grant, G. and Rexed, B. (1958). Dorsal spinal root afferents to Clark's column. Brain. 81: 567-576.

Grottel, K.Z. (1979). Topography of dendrites of neurons of substantia intermedia of spinal thoracic segment in cat. Folia Morph. 38: 157-166.

Grottel, K. and Teresa, H. (1979). Topography of dendrites of neurons of thoracic lateral horns in cat spinal cord. Folia Morph. 38: 327-334.

Hannah, R.S. and Nathaneil, E.J.H. (1975). Ultrastructural studies on postnatal differentiation of neurons in the substantia gelatinosa of rat cervical spinal cord. Anat. Rec. 183: 323-338.

Huettner, A.F. (1967). Fundamentals of Comparative Embryology of the Vertebrates. Second edition. The Mac Millan Company, New York. p. 309.

Jenkins, T.W. (1978). Functional Mammalian Neuroanatomy. Second edition. Lea and Febiger, Philadelphia. p. 480.

Kappers, C.U.A., Huber, G.C. and Crosby, E.C. (1967). The Comparative Anatomy of the Nervous System of Vertebrates, Including Man. Hafner Publishing Company, New York. p. 695.

Keith, A. (1947). Human Embryology and Morphology. Sixth edition. Williams and Wilkins, Baltimore. p. 690.

King, A.S. (1987). Physiological and Clinical Anatomy of the Domestic Mammals. Oxford University Press, New York. p. 325.

Langman, J. (1981). Medical Embryology. Fourth edition. Williams and Wilkins, Baltimore. p. 384.

Larsell, O.(1951) Anatomy of the Nervous System. 2nd edn, Appleton Century Crofts, New York. p. 520.

Maya, S., Chungath, J.J., Harshan, K.R. and Ashok, N. (2014). Lamination of spinal cord gray matter in goat foetii. Indian Journal of Veterinary Anatomy. 26(2): 72-75.

Okamoto, M. (1977). A cytoarchitectonic study of the intermediolateral nucleus in cat spinal cord. Med. J. Kobe Univ. 36: 73-84.

Papez, J.W. (1967). Comparative Neurology- A manual and Text for the Study of the Nervous System of Vertebrates. Hafner Publishing Company, New York. p. 518.

Rafalowska, J. (1977). On the relationship between the size of motor neurons of the anterior horn of spinal cord and the types of muscle fibres. Folia Morph. 36: 273-282.

Rao, G.S. (1970). Nuclear pattern of spinal gray matter in the buffalo. J. anat. Soc. India. 19: 5-11.

Reddy, V.K. (1972). Studies on the development of the neural crests in bovine embryos. Indian Vet. J. 49: 561-564.

Rethelyi, M. (1976). Central core cells in the spinal gray matter. Acta Morph. Hung. 24: 63-70.

Rexed, B. (1952). A cytoarchitectonic organization of the spinal cord in the cat. J. comp. Neurol. 96: 415-495.

Rizzo, D.C. (2006). Fundamentals of Anatomy and Physiology. 2nd edn, Thomson Delmar Learning, Australia. pp: 244-69.

Rugh, R. (1964). Vertebrate Embryology-The Dynamics of Development. Harcourt, Brace and World, New York. p. 600.

Slawomirski, J., Welento, J. and Fleiger, S. (1973). Sympathetic centres in the spinal cord of the dog. Polskie Archwm Wet. 16: 685-695.

Sturrock, R.R. (1982). A quantitative study of vascularisation of the prenatal rabbit spinal cord. J. Anat. 135: 89-96.

Taluja, J.S., Shrivastava, A.M., Malik, M.R. and Parmar, M.L. (1991). Nuclear architecture of spinal cord gray matter in goat foetuses. Indian J. Anim. Sci. 61: 1064-1065.

Todd, A.J. and Lewis, S.G. (1986). The morphology of Golgi- stained neurons in lamina II of the rat spinal cord. J. Anat. 149: 113-119.

Truex, R.C. and Carpenter, M.B. (1969). Human Neuroanatomy. Sixth edition. The Williams and Wilkins Company, Baltimore. p. 673.

Ulinsky, P.S. (1997). Vertebrate Nervous System. Comparative Physiology, Volume I. [Dantzler, W.H., (ed)]. Oxford University Press. New York. pp. 17-30.

Welento, J., Fleiger, S., Eustachiewicz, R. and Boratynski, Z. (1977). Structure and topography of the nucleus intermediomedialis of the spinal cord of the pig. Polskie Archwm Wet. 20: 155-160.

Welento, J., Fleiger, S., Eustachiewicz, R. and Boratynski, Z. (1979). Structure and topography of the nucleus intermediolateralis in the spinal cord of horse. Polskie Archwm Wet. 22: 395-404.

Zargar, R.K., Mehrotra, T.N. and Shinde, V.A. (1975). Nuclear pattern and extent of anterior horn cells in spinal cord of albino rats. J. Anat. Soc. India. 24: 49.

Zargar, R.K., Mehrotra, T.N. and Shinde, V.A. (1979). A study of the cytoarchitectonics and dendritic pattern in the neurons of the ventral gray column of the spinal cord of albino rat. J. Anat. Soc. India. 28: 94-99.