SHORT COMMUNICATION Indian Journal of Animal Research, Volume 59 Issue 6: 1075-1080 (June 2025)

Biochemical, Molecular, Postmortem and Histopathological Characterization of Bovine Theilerioses at Different Stages of Production and Reproduction

H. Dutta[1], S.K. Panda[1], S. Sathapathy[2], B.N. Mohanty[3], C. Mishra[4], G.R. Jena[5]

10.18805/IJAR.B-5400

ABSTRACT

Theilerosis is the most important common vector (Tick) born and hemoprotozoan diseases (TBDS) which pose a serious threat to the livestock population in terms of mortality, reduced milk yield and lowered draft power. The disease is having impact on biochemistry and systemic functions affecting at different stages of production and reproduction of dairy cattle as well as there is lack of accurate diagnosis of this disease. A total 1900 cases were suspected for theileriosis on the basis of clinical signs and total 950 cases were found positive for theileriosis on the basis of blood smear examination. As per the stages of pregnancy and lactation, the cases were classified as cows in early pregnancy, cows in late pregnancy, cows in post parturient stage, cows in early and late lactation period. Biochemical alterations like increased AST, ALT and BUN level indicating liver and kidney dysfunctions in all the groups and significantly higher in post parturient group. The serum phosphorus, calcium and magnesium level decreased in all the affected groups and mostly in late pregnancy period and post parturient stage indicating metabolic disturbances during the disease which were aggravated during theileriosis. Through molecular diagnosis 114 cows (65.51%) were found positive for *T. annulata* and 41 cows (22.9%) were found positive for *T. orientalis* and 19 cows (10.9%) were found positive for both *Theileria annulata* and *Theileria orientalis*. Phylogenetic analysis revealed the accession number for *Theileria annulata* was OQ230445 which is having 100% similarity with puri isolate and 98% similarity with Khorda isolate and the accession number for *T. orientalis* was OQ 230446 having 85% similarity with Khorda isolate. On necropsy, the animals were weak, debilitated with atrophy of the muscles. In some cases, the liver was enlarged, markedly congested and in some cases yellowish tinged surface and cut edges with distension of gall bladder was evident. Abomasal ulcers were distinct and considered as pathognomonic. On histopathological examination, the liver revealed necrosis of hepatocytes with sinusoidal congestion and infiltration of mononuclear cells. In lymphnode, there was depletion of lymphocytes in lymphoid follicles with congestion and haemorrhage. Pulmonary edema was also evident in few cases.

Key words: Biochemical, Cattle, Histopathological, Milk reduction, Molecular, Postmortem, Production, Reproduction, Theileriosis.

Theilerosis is the most important common vector (tick) born and hemoprotozoan diseases (TBDS), which poses a serious threat to the livestock population in terms of mortality, reduced milk yield and lowered draft power. High humidity and temperature are the main contributing factors. Bovine tropical Theileriosis is a tick-borne infection caused by *T. annulata*, an intracellular protozoan parasite. It is a lymphoproliferatve disease causing high mortality and morbidity in cattle. *T. sergenti*, *T. buffeli* and *T. orientalis* are the causative organism for bovine benign theileriosis in cattle. In India, bovine theileriosis was first reported in 1905 by Lingard as reported earlier (Mohan, 1972). Prompt efforts are required to screen theileria infected cattle, interpret systemic dysfunctions or pathological alterations to know and eliminate the etiology properly and so that the treatment can be given for increasing the production and productivity of the cattle. Keeping in view the above facts, the present biochemical, molecular, postmortem and histopathological studies were conducted in the bovine theilerioses at different production and reproduction stages.

Screening of animals was carried out in and around Bhubaneswar during 2021 February to December 2022. Blood samples were collected from suspected theilerioses cattle on the basis of clinical signs with complain of aneroxia,

[1]Department of Veterinary Pathology, CVSc. and A.H., Odisha University of Agriculture and Technology, Bhubaneswar-751 003, Odisha, India.
[2]Department of Veterinary Anatomy and Histology, CVSc. and A.H., Odisha University of Agriculture and Technology, Bhubaneswar-751 003, Odisha, India.
[3]Department of Veterinary Parasitology, CVSc. and A.H., Odisha University of Agriculture and Technology, Bhubaneswar-751 003, Odisha, India.
[4]Department of Animal Breeding and Genetics, CVSc. and A.H., Odisha University of Agriculture and Technology, Bhubaneswar-751 003, Odisha, India.
[5]Department of Veterinary Clinical Medicine, CVSc. and A.H., Odisha University of Agriculture and Technology, Bhubaneswar-751 003, Odisha, India.

Corresponding Author: S.K. Panda, Department of Veterinary Pathology, College of Veterinary Science and Animal Husbandry, Odisha University of Agriculture and Technology, Bhubaneswar-751 003, Odisha, India. Email: skpanda@ouat.ac.in

How to cite this article: Dutta, H., Panda, S.K., Sathapathy, S., Mohanty, B.N., Mishra, C. and Jena, G.R. (2025). Biochemical, Molecular, Postmortem and Histopathological Characterization of Bovine Theilerioses at Different Stages of Production and Reproduction. Indian Journal of Animal Research. 59(6): 1075-1080. doi: 10.18805/IJAR.B-5400.

Submitted: 07-05-2024 **Accepted:** 28-05-2024 **Online:** 17-07-2024

drop in milk yield, non-remitting pyrexia, enlarged superficial lymphnodes, pale mucous membrane of oral mucosa and conjunctiva, nasal discharge and coughing signs suspected, which were referred by the Veterinary Clinician. Patient data regarding age, sex, stage of lactation, parturition and pregnancy history and clinical signs were recorded. A total of 1900 suspected cases were screened by blood smear examination and 950 cases found positive for theileria. In positive cases, there was presence of piroplasms in blood smear with different shapes like dot shape, round, ovoid, irregular cocci or bacilli, rod, stick, comma, fusiform, racquet shaped, signet ring shaped or pear shaped inside RBCs indicating *Theileria* species. In few positive cases, Koch's blue bodies were also found in the lymphocytes of lymphnode smear.

Clinical signs were observed in theileriosis positive cows at different stages of production and reproduction (Table 1). Serum samples from 213 affected cattle were taken and compared with normal ranges of biochemical parameters. These samples were analyzed for serum biochemical parameters like serum glucose, blood urea nitrogen, creatinine, AST, ALT, serum calcium, magnesium and phosphorus. For histopathological examination, formalin fixed tissues were processed for routine paraffin techniques and routine H and E techniques as per the standard paraffin methods, stained and viewed for histopathological interpretation. Out of the collected total number of 200 samples, the 100 samples were found positive in Geimsa stain and were kept at -20°C temperature for doing routine PCR. During the research period, total six numbers of cases were subjected for postmortem examination. The average value we got for different parameters in infected and healthy groups were analyzed by analysis of variance (ANOVA) with post hoc analysis by Duncan's multiple comparison test using SPSS22 soft ware and expressed as mean ± SE with $p<0.05$ considered statistically significant.

Serum biochemical analysis

Serum samples were collected from 213 positive cases of cattle in different stages of production and reproduction. The serum glucose values of animals of group 1, 2, 3, 4 and 5 were (78.49±1.14) g/dl, (69.22±1.7) g/dl, (74.11±1.5) g/dl, (70.85±2.3) g/dl and (78.44±1.69) g/dl, respectively. The average value of serum glucose in these groups was 73.79 g/dl. In all the groups the average glucose value was significantly lower than the normal value (45-75 g/dl) as per the reports of Col and Uslu (2006) and Acharya *et al.* (2016) due to utilization of glucose by the parasites.

The BUN values of animals of group 1, 2, 3, 4 and 5 were (25.90±0.67) mg/dl, (28.14±0.79) mg/dl, (28.18±0.70) mg/dl, (29.35±1.08) mg/dl and (22.91±0.69) mg/dl, respectively. The higher values of BUN level might be due to liver and renal damage in the affected animals and increased protein catabolism due to anorexia in theileria positive animals or due to dehydration (Singh *et al.,* 1991). The creatinine levels of animals of group 1, 2, 3, 4 and 5 were (1.83±0.60) mg/dl, (1.96±0.98) mg/dl, (2.09±0.48) mg/dl, (2.28±0.69) mg/dl and (2.16±0.10) mg/dl, respectively. Statistically, there was significant ($p<0.05$) difference in the creatinine estimates of Gr-1 and Gr-4. There was increase in average creatinine value in all the groups (Col and Uslu, 2006).

The average values in Gr-1, Gr-2, Gr-3, Gr-4 and Gr-5 were (121.98±0.75) IU/L, (142.83±0.14) IU/L, (164.19±3.51) IU/L, (157.22±5.5) IU/L and (107.66±2.3) IU/L, respectively. The AST estimate in Gr-5 was found to be significantly ($p<0.05$) lower than Gr-2, Gr-3 and Gr-4. The average values in Gr-1, Gr-2, Gr-3, Gr-4 and Gr-5 were (28.55±0.96) IU/L, (33.66±1.96) IU/L, (41.34±0.83) IU/L, (37.05±1.55) IU/L and (26.68±0.71) IU/L, respectively. The ALT estimate in Gr-3 was found to be significantly ($p<0.05$) higher than Gr-1, Gr-2 and Gr-5. Recorded increase in the enzyme level indicated muscle trauma due to recumbent position of animals (Selim *et al*., 2022) and debility caused by the depressed liver function.

The average values in Gr-1, Gr-2, Gr-3, Gr-4 and Gr-5 were (7.99±022) mg/dl, (7.04±0.22) mg/dl, (7.39±0.12) mg/dl, (7.49±0.18) mg/dl and (7.66±0.13) mg/dl, respectively. But the estimated calcium value was lower than the normal range, which might be attributed to the hypoalbuminaemia in the affected animals (Ellah, 2015). The average values in Gr-1, Gr-2, Gr-3, Gr-4 and Gr-5 were (0.30±0.008) mmol/l, (0.28±0.009) mmol/l, (0.27±0.006) mmol/l, (0.25±0.007) mmol/l and (0.33±0.011) mmol/l, respectively. The serum Mg value was higher in Gr-5 than all other groups and there is statistically significant ($p<0.05$) difference of serum Mg value of Gr-5 with Gr-2, Gr-3 and Gr-4.

The average values of serum phosphorus in Gr-1, Gr-2, Gr-3, Gr-4 and Gr-5 were (0.41±0.011) mmol/l, (0.42±0.006) mmol/l, (0.37±0.009) mmol/l, (0.40±0.008) mmol/l and (0.42±0.006) mmol/l, respectively. The serum phosphorus estimate in Gr-2 and Gr-5 were significantly ($p<0.05$) different with Gr-3. The serum Ca, Mg and P level in all the groups were observed lower than the normal range, which might be due to the physiological stress in pregnancy and lactating stage leading to metabolic disturbances along with systemic dysfunction (Col and Uslu, 2006).

Molecular diagnosis through PCR

The DNA was extracted from 200 number of blood samples. Out of them 120 were clinically positive and 80 samples

Table 1: Different groups of cattle at different stages of production and reproduction.

Group	Different stages	Time
Group-1	Early pregnancy	Before 6 months
Group-2	Late pregnancy	After 6 months
Group-3	Post parturient	Day-1 to 7th week
Group-4	Early lactation	From 8th week to 15th week
Group-5	Late lactation	After 16th week to 45th week

were suspected cases (Fig 1). Polymerase chain reaction for 768 bp fragment for Tams1 gene and 776 bp fragment for MPSP gene was done and specific fragments were amplified in both primers using standard protocol. Then the PCR samples were sequenced by Sanger's sequencer and nucleotide sequences were obtained by FASTA format (Fig 2). The nucleotide sequences were interpreted using Finch TV Software. The Forward and Reverse sequences aligned to obtain 768 bp and 776 bp (Fig 3 and 4). The nucleotide sequences were submitted in GenBank and the accession numbers (OQ230445 and OQ230446) were obtained. The identification of *T. annulata* and *T. orientalis* from phylogenetic tree was based on the reports of Selim *et al.* (2022).

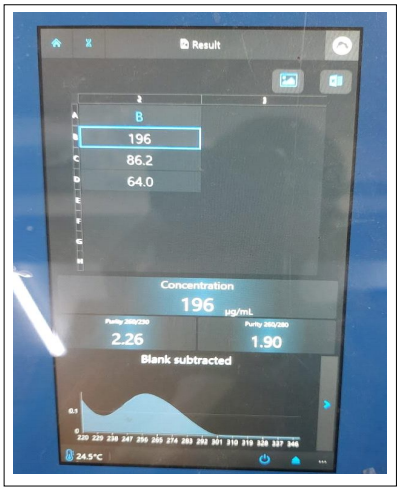

Fig 1: DNA purity test.

Total eight closely related nucleotide sequences from different places and two regions of Odisha were received from GenBank. Analysis of Tams 1 gene partial nucleotide sequence of *Theileria annulata* (OQ230445) showed similarity of 98%, 100%, 100%, 95% with MW12309, Khorda isolate, MF346012, MN818858 Puri isolate and *Theileria annulata* isolate OD2MF346013, respectively. Higher genetic divergence was found in between Khorda isolate and Puri isolate. The lower genetic divergence was found in Odisha and Jammu isolate (Fig 5). Phylogenetic relationship was estimated based on the partial nucleotide sequences (768 bp) of merozoite piroplasm surface antigen of *Theileria annulata* with available other variants in GenBank. *Theileria orientalis* partial MPSP gene (776 bp) found in this research with GenBank accession number OQ230446 showed 80% similarity with MW672060 Khorda isolate and 75% with JX648207 isolate of Wayanad (Fig 6). There was 57% cases *T. annulata* as found by PCR assays, which was similar to the findings of Acharya *et al.* (2016) and George *et al*. (2015) and 20.5% cases *T. orientalis* infection, which indicated the occurrence of tropical

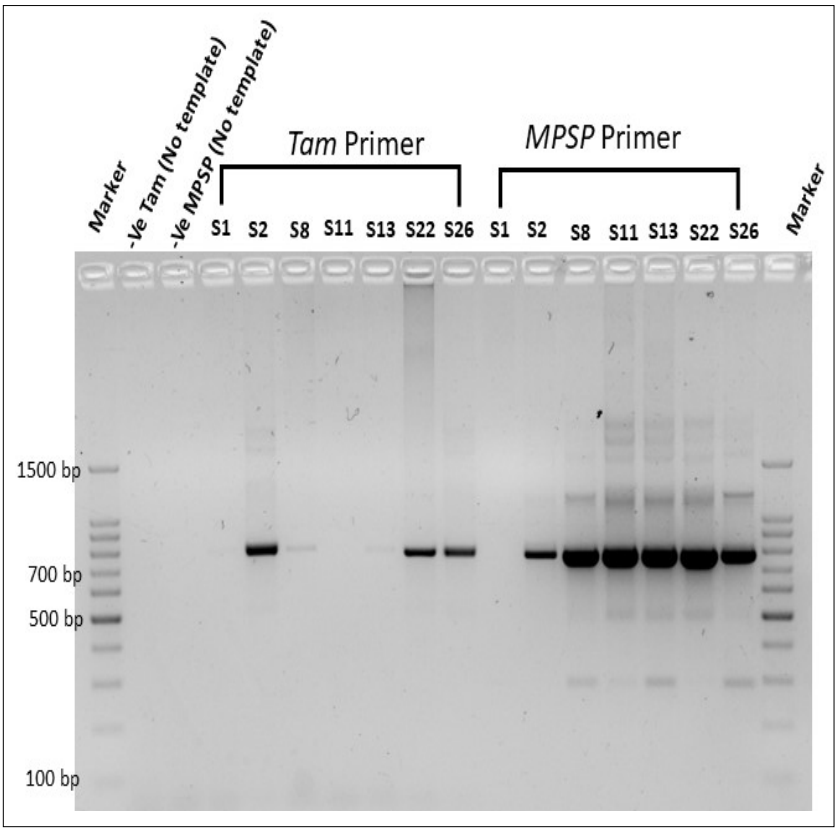

Fig 2: PCR of Tams1 and MPSP gene.

theileriosis. There was 9.9% of concurrent infection of both the organisms. Hence, the early detection is required to provide proper treatment to reduce the economic loss.

The melting curves of two primers for Tams 1 and MPSP showed single peak, which was suggestive of complete dissociation of primers and specificity of qPCR reactions. The cq values is cycle number above which fluorescence level becomes higher than the back ground fluorescence so that it can be detected. For our experiment, the Cq value for Tams 1 gene was almost 15 cycles and for MPSP gene it was almost 31 cycles. So, Tams 1 gene (*Theileria annulata)* can be identified earlier than MPSP gene (*Theileria orientalis)* in qPCR. Alternatively, the relative abundance of *Theileria annulata* was higher than *Theileria orientalis* (Fig 7). To the best of our knowledge, this is nearly a new phylogenetic study of *Theileria orientalis* and the occurrence of concurrent infection is also a new finding. Both PCR and qPCR are accurate techniques for the detection of this concurrent infection in bovine theileriosis. From molecular analysis, we found 174 positive cases

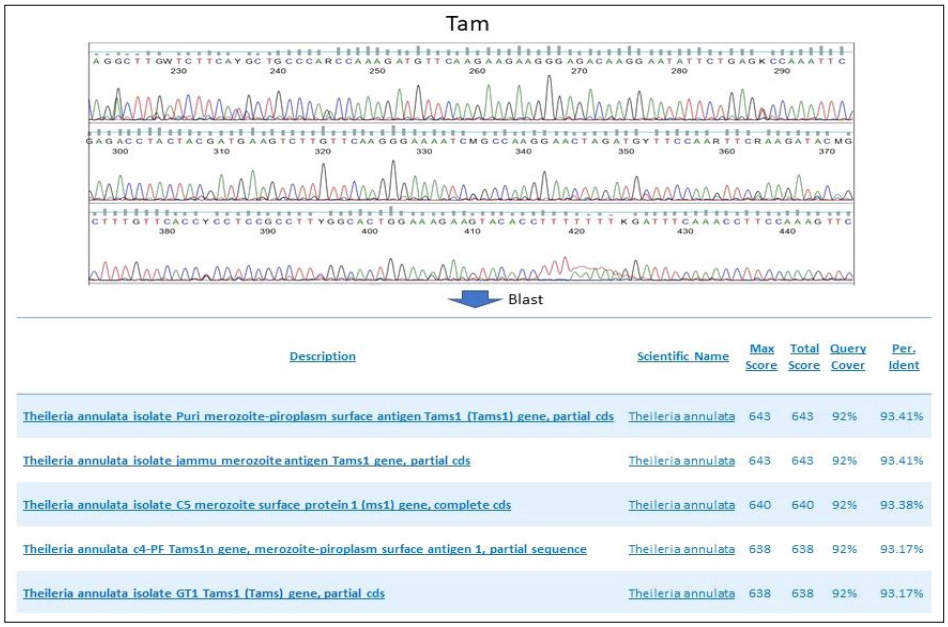

Description	Scientific Name	Max Score	Total Score	Query Cover	Per. Ident
Theileria annulata isolate Puri merozoite-piroplasm surface antigen Tams1 (Tams1) gene, partial cds	Theileria annulata	643	643	92%	93.41%
Theileria annulata isolate jammu merozoite antigen Tams1 gene, partial cds	Theileria annulata	643	643	92%	93.41%
Theileria annulata isolate C5 merozoite surface protein 1 (ms1) gene, complete cds	Theileria annulata	640	640	92%	93.38%
Theileria annulata c4-PF Tams1n gene, merozoite-piroplasm surface antigen 1, partial sequence	Theileria annulata	638	638	92%	93.17%
Theileria annulata isolate GT1 Tams1 (Tams) gene, partial cds	Theileria annulata	638	638	92%	93.17%

Fig 3: Nucleotide sequence of Tams 1.

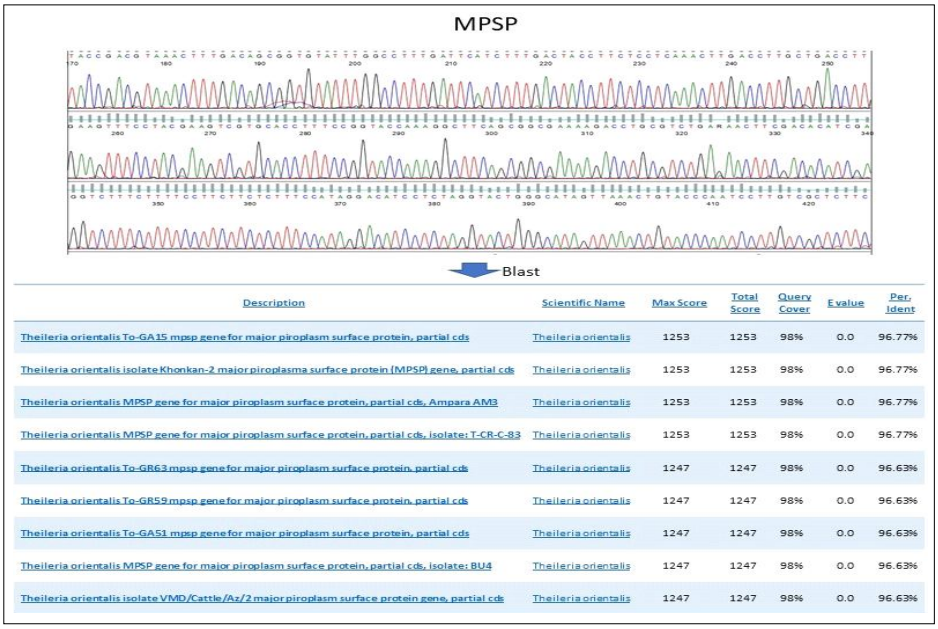

Description	Scientific Name	Max Score	Total Score	Query Cover	E value	Per. Ident
Theileria orientalis To-GA15 mpsp gene for major piroplasm surface protein, partial cds	Theileria orientalis	1253	1253	98%	0.0	96.77%
Theileria orientalis isolate Khonkan-2 major piroplasma surface protein (MPSP) gene, partial cds	Theileria orientalis	1253	1253	98%	0.0	96.77%
Theileria orientalis MPSP gene for major piroplasm surface protein, partial cds, Ampara AM3	Theileria orientalis	1253	1253	98%	0.0	96.77%
Theileria orientalis MPSP gene for major piroplasm surface protein, partial cds, isolate: T-CR-C-83	Theileria orientalis	1253	1253	98%	0.0	96.77%
Theileria orientalis To-GR63 mpsp gene for major piroplasm surface protein, partial cds	Theileria orientalis	1247	1247	98%	0.0	96.63%
Theileria orientalis To-GR59 mpsp gene for major piroplasm surface protein, partial cds	Theileria orientalis	1247	1247	98%	0.0	96.63%
Theileria orientalis To-GA51 mpsp gene for major piroplasm surface protein, partial cds	Theileria orientalis	1247	1247	98%	0.0	96.63%
Theileria orientalis MPSP gene for major piroplasm surface protein, partial cds, isolate: BU4	Theileria orientalis	1247	1247	98%	0.0	96.63%
Theileria orientalis isolate VMD/Cattle/Az/2 major piroplasm surface protein gene, partial cds	Theileria orientalis	1247	1247	98%	0.0	96.63%

Fig 4: Nucleotide sequence of MPSP.

from 200 samples out of which 114 cows found positive for *T. annulata* (57%) and 41 cows (20.5%) were positive for *T. orientalis* and 19 cows (9.9%) cows were positive for concurrent infection.

Gross pathological changes

Systemic post-mortem examination of six dead animals was carried out during the study. Some of the animals were weak, debilitated with atrophy of the muscles. There was distended abdomen and soiling of hind quarter due to diarrhea in two cases.

Skeletal muscles were pale in 3 cases. Skeletal muscles were yellowish tinged with atrophy of muscles and prominent ribs in 2 cases. Subcutaneous surface revealed yellowish discoloration indicating Jaundice. Gelatinization of subcutaneous fat and paleness of muscle was observed in 2 cases. In few cases, abdominal cavity revealed presence of straw-colored fluid (Acharya *et al.,* 2016). Liver was slightly enlarged with congestion in few cases. Hepatic surface was congested with pale patches and distended gallbladder in two cases (Sahoo *et al.,* 1991). Liver was firm and jaundiced with yellowish discoloration of the cut edges. In one case, the liver was pale with haemorrhagic patches on the surface of liver and with adjacent pale patches. Lungs were congested and edematous slightly and pleura was wrinkled in few cases. Pale with haemorrhagic patches was evident in two cases. In two cases, lungs were icteric with intense yellowish discoloration of the surface, parenchyma, bronchi and bronchioles with scanty yellowish tinged of exudates (Sastry and Rao, 2001). Pleura was thickened. In some cases, there was cardiac dilation with gelatinization of epicardial fat. In two cases heart was dilated with yellow discoloration of epicardial surface. Spleen surface was pale and yellow in two cases. Cut edges of the spleen revealed reddish yellow discoloration with oozing of reddish yellow fluid (Sastry and Rao, 2001). In few cases, intestine was slightly distended with yellowish discoloration of serosa. Intestinal wall was thickened with catarrhal exudates in the lumen. There were haemorrhagic and ulcerative patches in the intestinal mucosa. In some cases, cortical surface of kidney was pale with pale medullary area, gelatinization of renal fat. Abomasal mucosa was pale with punched out ulcers.

Histopathology

Liver showed necrosis of hepatocytes with infiltration of neutrophils and mononuclear cells. In some cases, marked sinusoidal congestion and necrosis of hepatocytes were observed (Sahoo *et al.,* 1991 and Acharya *et al.,* 2016). The disruption of myocardial fibres and haemorrhages were found. Kidney showed the necrosis of tubular epithelial lining cells and focal infiltration of mononuclear cells. Some cases lumen of tubule filled with necrotic debris and also necrosis in glomerular tuft. Lungs were showing edema in alveolar space filled with edematous fluid and interstitial congestion. There was also necrosis and disruption of pulmonary alveoli with marked congestion, edema and haemorrhage. In some cases, congestion, edema and haemorrhages were found.

There was depletion of lymphoid follicles of lymphnodes. Marked congestion and haemorrhage of lymphoid follicle were noted. There was depletion of lymphocytes with lymphoid follicles. Abomasum showed the presence of fibrinous material on the surface of mucosaand congestion of mucosa with focal infiltration of inflammatory cells.

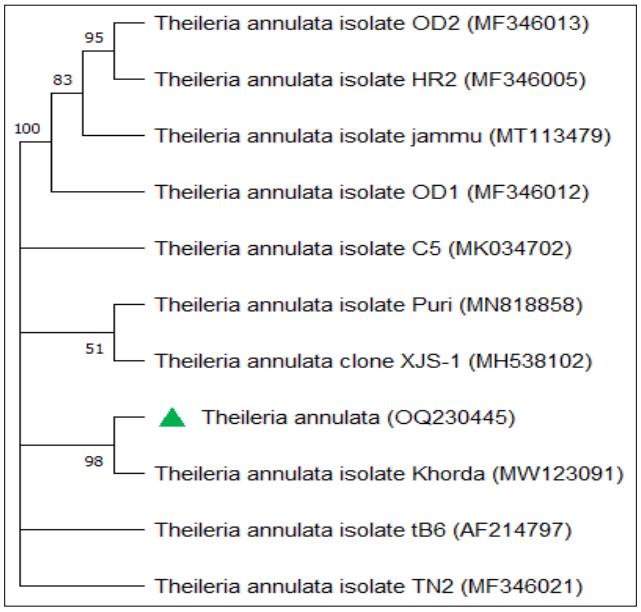

Fig 5: Phylogenetic tree *Theileria annulate.*

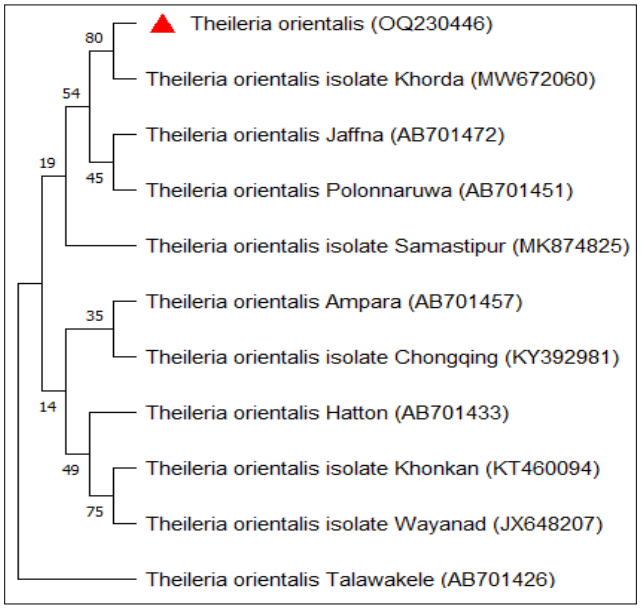

Fig 6: Phylogenetic tree *Theileria orientalis.*

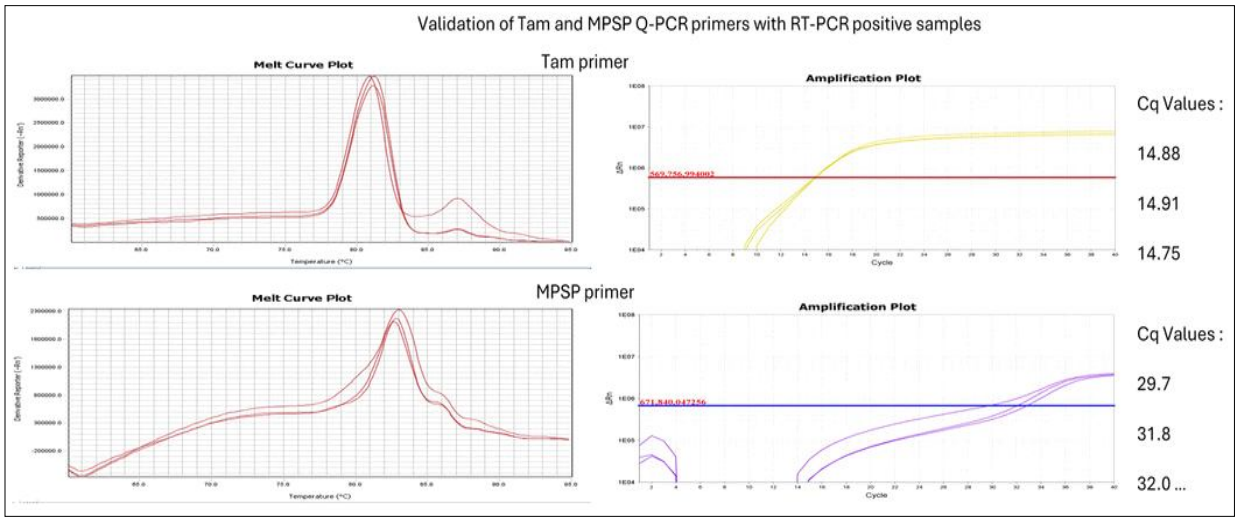

Fig 7: Melting curve of qPCR.

CONCLUSION

The biochemical alterations like increased AST, ALT and BUN level indicating liver and kidney dysfunctions in all the groups and significantly higher in post parturient group. The serum phosphorus, calcium and magnesium level decreased in all the affected groups and mostly in late pregnancy period and post parturient stage indicating metabolic disturbances during the disease which were aggravated during theileriosis. Through molecular diagnosis 114 cows (65.51%) were found positive for *T. annulata* and 41 cows (22.9%) were found positive for *T. orientalis* and 19 cows (10.9%) were found positive for both *Theileria annulata* and *Theileria orientalis*. The postmortem findings and histopathological findings revealed systemic dysfunction like anemia, debility, icterus, hepatitis, pulmonary edema, cardiac dilatation, abomasal ulcer which are used as supportive diagnostic findings of theileriosis.

ACKNOWLEDGEMENT

The authors are very much grateful to the Dean, College of Veterinary Science and Animal Husbandry OUAT, Bhubaneswar for providing necessary facilities for successful completion of this research work in time.

Conflict of interest

There is no conflict of interests among the authors.

REFERENCES

Acharya, A.P., Panda, S.K., Das, R.K., Panda, M.R., Das, S., Gupta, A.R. (2016). Prevalence of Bovine tropical theileriosis in cattle reared in and around Bhubaneswar. Indian Journal of Veterinary Medicine. 36(1): 20-22.

Col, R. and Uslu, (2006). Haematoloigical and coagulation profiles during severe tropical theileriosis in cattle. Turkish Journal of Veterinary and Animal Science. 30: 577-582.

Ellah, M.R.A. (2015). Studying the correlations among hematological and serum biochemical constituents in cattle theileriosis. Journal of Parasitological Diseases. 39(2): 134-139.

Mohan, R.N. (1972). Bovine theileriasis detected in 1905. Haryana Veterinarian. 11: 26.

Sahoo, B.K. (1991). Studies on bovine tropical theileriosis and its control, MVSc. thesis submitted to Orissa University of Agriculture and Technology, Bhubaneswar.

Sastry, G.A. and Rao, R.P. (2001). Veterinary Pathology, 7th edn., Chapter 30, Theileriosis. pp: 703-705.

Selim, A., Weir, W., Khater, H. (2022). Prevalence and risk factors associated with tropical theileriosis in Egyptian dairy cattle. Veterinary World. 15(4): 919-924.

Singh, D.K. (1991). Theileriosis in India. In: Orientation and Coordination of Research on Tropical Theileriosis. P. 23rd [(edn.) Singh, D.K. and Varshney, B.C.], National Dairy Development Board, Anand, India.