RESEARCH ARTICLE Indian Journal of Animal Research, Volume 59 Issue 6: 995-1003 (June 2025)

Clinicopathology and Ultrastructural Alterations of Experimentally Induced Necrotic Enteritis in Chickens

D. Behera[1], D.C. Pathak[2], A. Samal[3], M. Kumar[4], N. Debbarma[1], P. Goswami[5], P. Behera[6] 10.18805/IJAR.B-5408

ABSTRACT

Background: This study was designed to elucidate the clinicopathological and ultrastructural alterations in experimentally induced necrotic enteritis (NE) in chickens and the present study acknowledged pronounced clinical signs, gross, histopathological and ultrastructural lesions in the chickens infected by both *Clostridium perfringens* type A, type C and coccidia infection.

Methods: The day-old chickens were divided in to five groups including control. NE was induced by *Clostridium perfringens*, type-A and C with and without coccidia infection to the designated experimental groups in this study.

Result: The clinical signs, hematology and biochemical parameters were evaluated in this study. Clinical indicators included diarrhea, ruffled feathers, dehydration, depression and a drop in TEC, Hb% and PCV% were noticeable. There was also a large increase in TLC and DC, a significant increase in ALT, AST and a decrease in total protein. In the intestine and other organs, there were noticeable inflammatory gross lesions and histological lesions. Transmission electron microscopic (TEC) observation of intestine revealed disruption of intercellular junction complexes, delimitation of enterocytes, disintegration of nucleus, dilatation of endoplasmic reticulum and cristeolysis of mitochondria. The present work will be an admiring contribution to inclusive study of the NE in chicken in terms of clinicopathology and ultrastructural lesions.

Key words: Chicken, *Clostridium perfringens*, Necrotic enteritis, Pathology, Ultrastructural alterations.

INTRODUCTION

Poultry farming has witnessed a paramount boost in terms of production of meat and eggs to meet the demands for increased and growing world population but infectious diseases engender hostility and uncertainty in the prospects of poultry production. The necrotic enteritis (NE) is accountable for high morbidity, mortality and significant economic loss (Agunos *et al*., 2013; Paiva and McElroy, 2014). Both type A and type C strains of *Clostridium perfringens* were responsible for NE in chickens (Immerseel *et al*., 2009) and are normally found in the gut microbiota of healthy chickens (Yang *et al*., 2018; Kiu *et al*., 2019) and therefore, makes it difficult to determine the virulence and pathogenesis (Cooper *et al*., 2013). The indiscriminate use of antimicrobials in feedstuffs, indigestible diets and gut mucosal damage due to coccidiosis are the predisposing factors (Goossens *et al*., 2020). The major toxins of *C. perfringens* are α-toxin, beta2, NetB, delta, theta, kappa, lambda, mu, nu, gamma, eta, neuraminidase, urease and enterotoxin (Petit *et al*., 1999). Clinical signs were poor appetite, depression, ruffled feathers, wet litter, diarrhea, reduced feed efficiency and high mortality *etc*. (Crespo *et al*., 2013). The gross lesions revealed erosion, ulceration, hyperemia, mucosal fibrin, necrosis, diphtheritic pseudo-membrane in intestine and multifocal necrotic foci of liver (Savva *et al*., 2013). Histopathology showed congestion, coagulative necrosis, heterophil infiltration and bacterial colonization (Olkowski *et al*., 2006) and histopathology displayed as cytoplasmic vacuolations, pyknosis, karyorrhexis and karyolysis of nuclear material of the enterocytes (Olkowski *et al*., 2008). The ultrastructural lesions were vesiculations, blebbing and degenerative changes of cytoplasm organelles of intestines (Kaldhusdal *et al*., 1995). The diagnosis of NE was based on clinical signs, necropsy, entero-histopathological findings and by the detection of alpha toxin, *net*B, T*pel* genes and predisposing factors (Aktar *et al*., 2022).

[1]Department of Veterinary Pathology, College of Veterinary Sciences and Animal Husbandry, Khayerpur-799 008, West Tripura, India.
[2]College of Veterinary Science, Assam Agricultural University, Guwahati-781 022, Assam, India.
[3]College of Veterinary Science and Animal Husbandry, OUAT, Bhubaneswar-751 003, Odisha, India.
[4]Bihar Veterinary College, Bihar Animal Sciences University, Patna-800 014, Bihar, India.
[5]ICAR-National Research Centre on Mithun, Medziphema-797106, Nagaland, India.
[6]College of Veterinary Sciences and Animal Husbandry, Selesih, Aizawal-796 014, Mizoram, India.

Corresponding Author: D. Behera, Department of Veterinary Pathology, College of Veterinary Sciences and Animal Husbandry, R.K. Nagar, Khayerpur-799 008, West Tripura, India.
Email: behera.debasish1@gmail.com

How to cite this article: Behera, D., Pathak, D.C., Samal, A., Kumar, M., Debbarma, N., Goswami, P. and Behera, P. (2025). Clinicopathology and Ultrastructural Alterations of Experimentally Induced Necrotic Enteritis in Chickens. Indian Journal of Animal Research. 59(6): 995-1003. doi: 10.18805/IJAR.B-5408.

Submitted: 18-05-2024 **Accepted:** 19-07-2024 **Online:** 07-08-2024

The pathogenesis of NE is not meticulously understood and challenging to produce NE experimentally. An attempt has been made to develop an *in vivo* model of experimental production of necrotic enteritis in chickens. Further studies on pathomorphology, hematological, biochemical and ultrastructural alterations would be encouraging to the investigators for its decisive diagnosis and also for the developing of an effective preventive strategy.

MATERIALS AND METHODS

The present research work was carried out in the Department of Veterinary Pathology, College of Veterinary Science, AAU, Guwahati, Assam during the period 2018 to 2022 with recommendation of Institutional Animal Ethics Committee. Total 30 numbers of one day old broiler chicks (unsexed) were procured and were properly vaccinated against RD and IBD and randomly divided into five groups of six in each group. All birds were fed with antibiotic-free starter diet containing 22% protein for 20 days. On day 21, the feed was replaced by a protein-rich feed, a formulated wheat-based grower diet containing 48% fishmeal. *C. perfringens* toxin type A and C isolated from the field subjected for preparation of inoculum (Bollela *et al*., 1999). Isolates were cultured in 5% sheep blood agar under anaerobic environment at 37°C for 24 hours were determined by cultural, morphological examination showing double zone of hemolysis (Koneman *et al*., 1988). The PCR was performed for confirmation with oligonucleotide primers such as forward 5′GCTAATGTTACT GCCGTTGA3′ and reverse 5′CCTCTGATACATCGTGTAAG3′ with band size of 324 bp (Titball *et al*., 1989) and forward 5′GCGAATATG CTGAATCATCTA3′ and reverse 5′GCAGG AACATTAGTATATCTTC3′ with band size of 180 bp (Hunter *et al*., 1993) for *cpa* and *cpb* toxin genes respectively (Plate 1).

The final concentration of inoculum 3×10^8 colony forming units (CFUs)/ml was prepared by the methods as described by Atta *et al*. (2014). The anti-coccidia vaccine Livacox Q was used for induction of coccidia infection and one ml contains 30000 to 50000 oocysts each of *Eimeria tenella*, *E. acervulina*, *E. maxima* and 10000 oocysts of *E. necatrix*. The infective dose was calculated as: 10 times of the normal vaccine dose (Timbermont, 2009). The birds of control group were given sterile phosphate buffer saline and brain heart infusion broth. The birds of group 2 and group 3 were primed with live coccidia oocysts on 22nd day and *C. perfringens* type A and type C respectively and group 4 and 5 were given only *C. perfringens* type A and type C respectively on 26th, 27th, 28th and on 29th day. The blood samples were collected on 21st, 26th, 28th, 30th and 32nd day (Meskerem *et al*., 2013). Following CO_2 inhalation euthanasia of all chicken, a post mortem was performed. The representative tissue samples of intestine, liver, kidneys, heart, lungs, bursa of Fabricius, spleen and brain were processed and were stained with hematoxylin and eosin (Culling, 1974).

Total erythrocyte count, hemoglobin percent (Hb%), packed cell volume, total leucocyte count and differential leucocytes count were analyzed in automated hematological cell counter. Serum alanine aminotransferase (ALT), serum aspartate amino-transferase (AST) and total protein were also evaluated in all the groups at different day interval. The lesion score card was prepared on the severity of gross lesions of small intestine (Van Waeyenberghe *et al*., 2016). The portions of intestine were immediately fixed in cacodylate buffer for transmission electron microscope examination (TEM). The steps taken in this process, as outlined by Hayat (2000), include collecting, preservation, transportation and processing. Data were subjected to statistical analysis and analyzed by SAS System using one way analysis of variance (ANOVA). Means were presented as mean±standard error (SE) and were compared by the Duncan test at the 0.05 level of probability.

RESULTS AND DISCUSSION

Clinical observations

The clinical signs were recorded as diarrhea, dehydration, depression, loss of appetite, ruffled feathers *etc*. and these signs were in corresponding with the earlier studies (Suryakanth *et al*., 2019). He *et al*. (2022) reported 8 times higher chance of NE in birds challenged with coccidia vaccine. Bird mortality was recorded in the group 2 and 4 but no mortality was observed in group 3 and 5. But, study revealed that necrotic enteritis challenge suppressed the body weight gain significantly, via inoculation of 50,000 oocysts of mixed strains of Eimeria species on 14 days of age followed by *C. perfringens* (10^7 cfu/ml) on 17, 18 and 19 days of age (Koli *et al*., 2017). Further similar studies by Suryakanth *et al*. (2019) and El-Sheikh *et al*. (2018) also recorded reduction in body weight.

Hematological studies

Haemoglobin (%) level showed significant difference ($P<0.05$) among different groups at different day interval and decrease in group 2 and 3 in comparison to the birds of group 4 and 5. The packed cell volume showed significant difference ($P<0.01$) in the groups at different day interval (Table 1) and are inconformity with Belih *et al*. (2015) and El-Sheikh *et al*. (2018). The TLC was recorded as significantly high ($P<0.01$). The differential leucocyte counts of granulocytes such as heterophil (%), eosinophils (%) and agranulocytes like lymphocyte (%) were recorded to be significantly different ($P<0.01$) in the groups at different days interval (Table 2) and these types of clinical findings with respect to differential leucocyte count were documented by El-Sheikh *et al*. (2018). But, the basophils (%) count did not demonstrate any deviations ($P>0.05$) in the present studies and similar findings was also recorded by Belih *et al*. (2015).

Serum biochemical studies

The alanine transaminase (ALT) showed significant increase ($P<0.01$) among all tests groups but significant

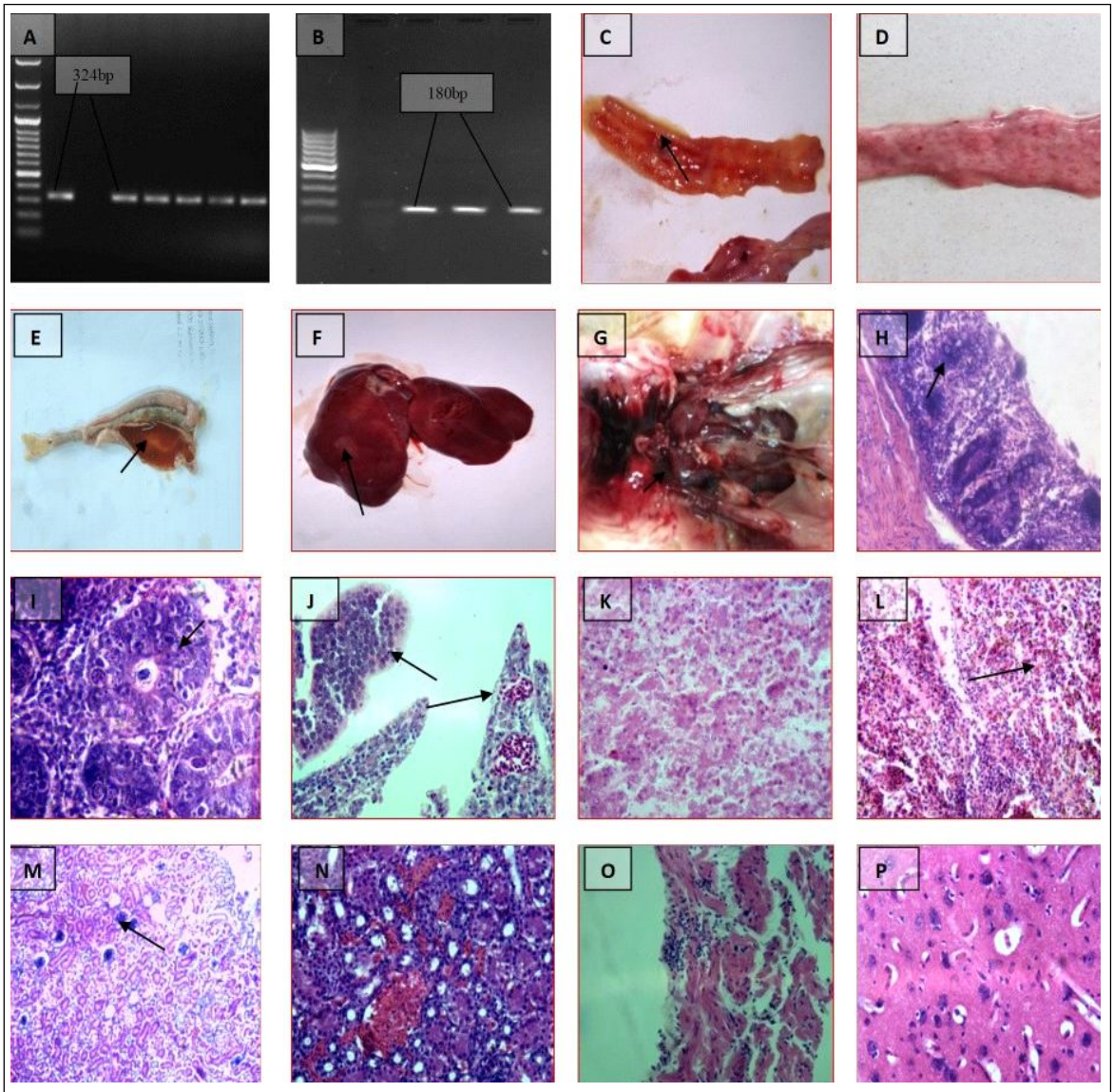

A: Detection of *cpa* gene encoding for alpha toxin (324 bp) of *C. perfringens* by PCR Lane 1-100 bp DNA ladder, 2- positive control, 3- negative control, 4,5,6 and 7 samples collected from the birds of group2 and 4. **B:** Detection of *cpb* gene encoding for beta toxin (180 bp) of *C. perfringens* by simplex PCR, Lane 1-100 bp DNA ladder, 2-negative control, 3- positive control and 4 and 5 samples collected from the birds of group3 and 5. **C:** Congestion, haemorrhages and necrosis intestine in group 2. **D:** Jejunum showing haemorrhages and necrosis in group-2. **E:** Hemorrhagic typhlitis bird of group 4. **F:** Liver showed enlargement, congestion, haemorrhages and necrotic foci in group-2. **G:** Kidneys showed moderate to severe degrees of congestion and haemorrhages in group-2. **H:** Photomicrograph intestine showed coccidia and infiltration of mononuclear cells in birds of group-2 (H&E, × 100). **I:** Photomicrograph intestine showing invasion of coccidia in glandular epithelium in the bird of group-2 (H&E, × 400). **J:** Photomicrograph of intestine showing coccidia oocysts and capillary congestion in the villi, group-3 (H&E, × 400) **K:** Photomicrograph liver showed fatty changes of hepatocytes in birds of group-2 (H&E, × 400). **L:** Photomicrograph lungs showing congestion of the capillaries and infiltration of mononuclear cells in alveoli in the birds of group 3 (H&E, × 400). **M:** Photomicrograph kidney showing focal areas of inters tubular congestion and constriction of glomerular tuft in group-2 (H&E, ×100). **N:** Photomicrograph kidney interstitial congestion in the birds of group-4 (H&E, × 400). **O:** Photomicrograph heart showing focal areas of mononuclear cells infiltrations in sub epicardium (H&E, × 400). **P:** Photomicrograph brain neuronal degeneration, necrosis and neuronophagia in group-3 (H&E, × 400).

Plate 1: Photographs of PCR confirmation, clinical signs, gross lesions and photomicrographs of histopathology in experimentally induced NE in chickens.

decrease was recorded in group 2 and 3 in different days intervals (Table 3) and the rise of ALT enzyme due to damage of hepatocytes and was also documented by Suryakanth *et al.* (2019). There was significantly high (P<0.01) aspartate transaminase (AST) level at different days interval in the groups (Table 3) and it could be attributed to hepatic degeneration, necrosis and was comparable with the findings and significant decrease of total protein (P<0.01) at different days in groups (Table 3) and were in agreement with Suryakanth *et al.* (2019). In the present study, there was enhanced level of AST and ALT and decrease level of total protein and this serum biochemical findings might have been due to enteritis, intestine malabsorption and degeneration of endoplasmic reticulum of hepatocytes of liver by the toxins released by *Clostridium perfringen* type A and type C and similar findings were observed by Shane *et al.* (1985).

Gross pathology

Post mortem examination of group 2 and 3 birds revealed congestion and hemorrhages in the intestine and fibrino-pseudomembrane on mucosa of the duodenum (Plate 1). There were diffuse hemorrhages with areas of necrosis over mucosa of the jejunum and hyperemia, hemorrhages, brownish to greenish loosely adherent debris were observed in the intestine (Plate 1) and similar lesions were also documented by Olkowski *et al.* (2006) and Suryakanth *et al.* (2019) respectively. The results of earlier studies revealed that the birds that were infected experimentally by *Clostridium perfringens* had manifested no lesions or hemorrhages after administration of antibiotic, probiotic and prebiotic or symbiotic (Al-Sagan and Abudabos, 2018). The liver showed enlargement, congestion, hemorrhages, necrotic foci and distension of the gallbladder. The kidneys revealed moderate to severe degrees of congestion and hemorrhages. The heart was enlarged with reasonable grade of congestion (Asaduzzaman *et al.*, 2011). In group 4 and 5 necrosis, diffuse hemorrhages, pseudo-membrane, hemorrhagic typhlitis were predominant gross lesions (Suryakanth *et al.*, 2019). Liver was enlarged, necrotic foci with congestion and hemorrhages (Plate 1). The congestion and hemorrhages of kidneys, pericarditis, petechiae on epicardium and mild to moderate degree of congestion and hemorrhages in lungs were consistent gross lesions (Plate 1). The spleen and bursa of Fabricius showed enlargement and congestion. *C. perfringens* type A infected group displayed more severe gross lesions and Belih *et al.* (2015) reported the same outcome in the similar experimental study.

Histopathology

Intestine of group 2 and 3 chickens showed, congestion, hemorrhages, with mononuclear and polymorhonuclear cells infiltration (Plate 1) with necrosis, sloughed off villi, vacuolations of intestine and coccidia in the lamina propria, villi and also in the glandular epithelium and comparable lesions were documented by Cooper and Songer, (2010) and Asaduzzaman *et al.* (2011) respectively. Liver revealed

Table 1: Values of total erythrocyte count, haemoglobin, packed cell volume and total leucocyte count.

	Groups	21st Day	26th Day	28th Day	30th Day	32nd Day
Total erythrocyte count	Group:1	$4.03\pm0.25_{ab}$	$4.52\pm0.31^{A}{}_{a}$	$4.56\pm0.17^{A}{}_{a}$	$4.52\pm0.37^{A}{}_{a}$	$3.52\pm0.19^{A}{}_{b}$
	Group:2	$5.01\pm0.43_{a}$	$2.06\pm0.14^{B}{}_{b}$	$2.40\pm0.09^{B}{}_{b}$	$2.40\pm0.13^{B}{}_{b}$	$2.44\pm0.08^{B}{}_{b}$
	Group:3	$4.01\pm0.24_{a}$	$2.04\pm0.16^{B}{}_{b}$	$2.42\pm0.23^{B}{}_{b}$	$2.24\pm0.15^{B}{}_{b}$	$2.60\pm0.07^{B}{}_{b}$
	Group:4	$4.65\pm0.36_{a}$	-	$2.57\pm0.22^{B}{}_{b}$	$2.52\pm0.23^{B}{}_{b}$	$2.72\pm0.15^{B}{}_{b}$
	Group:5	$3.84\pm0.35_{a}$	-	$2.62\pm0.16^{B}{}_{b}$	$2.46\pm0.11^{B}{}_{b}$	$2.43\pm0.08^{B}{}_{b}$
Haemoglobin	Group:1	$12.12\pm0.37_{a}$	$11.38\pm0.37^{A}{}_{ab}$	$10.16\pm0.43_{c}$	$10.10\pm0.42_{c}$	$10.68\pm0.26_{bc}$
	Group:2	$12.24\pm0.45_{a}$	$7.72\pm0.42^{B}{}_{c}$	$9.82\pm0.48_{b}$	$9.32\pm0.24_{b}$	$9.66\pm0.35_{b}$
	Group:3	$11.94\pm0.32_{a}$	$7.92\pm0.52^{B}{}_{c}$	$10.28\pm0.25_{b}$	$9.72\pm0.29_{b}$	$10.52\pm0.37_{b}$
	Group:4	$12.06\pm0.09_{a}$	-	$9.60\pm0.27_{c}$	$9.88\pm0.21_{c}$	$10.84\pm0.52_{b}$
	Group:5	$12.54\pm0.37_{a}$	-	$11.02\pm0.44_{b}$	$10.26\pm0.45_{b}$	$10.52\pm0.26_{b}$
Packed cell volume	Group:1	35.23 ± 1.10	33.53 ± 1.06^{A}	30.64 ± 1.31	30.85 ± 1.58	31.93 ± 0.86
	Group:2	$35.12\pm1.62_{a}$	$23.08\pm1.44^{B}{}_{c}$	$27.96\pm2.49_{bc}$	$28.28\pm1.11_{b}$	$28.12\pm1.06_{bc}$
	Group:3	$34.76\pm1.12_{a}$	$23.97\pm1.73^{B}{}_{c}$	$32.34\pm0.45_{ab}$	$29.94\pm1.36_{b}$	$31.37\pm0.68_{ab}$
	Group:4	$35.53\pm0.45_{a}$	-	$29.58\pm1.01_{b}$	$29.70\pm0.86_{b}$	$32.16\pm1.51_{b}$
	Group:5	$36.64\pm1.20_{a}$	-	$32.68\pm1.24_{b}$	$30.60\pm1.15_{b}$	$30.68\pm0.93_{b}$
Total leucocyte count	Group:1	$44.72\pm0.96_{a}$	$42.26\pm0.69_{ab}$	$42.50\pm0.61^{D}{}_{ab}$	$41.86\pm0.83^{C}{}_{b}$	$44.67\pm0.73^{C}{}_{a}$
	Group:2	$44.01\pm1.28_{c}$	$42.30\pm1.01_{c}$	$54.50\pm0.91^{A}{}_{a}$	$47.80\pm0.85^{AB}{}_{b}$	$51.33\pm1.27^{B}{}_{a}$
	Group:3	$43.24\pm1.19_{c}$	$42.66\pm0.88_{c}$	$48.27\pm0.61^{C}{}_{b}$	$46.33\pm0.67^{B}{}_{b}$	$51.77\pm1.51^{B}{}_{a}$
	Group:4	$44.06\pm1.27_{c}$	-	$51.03\pm0.92^{B}{}_{b}$	$49.05\pm0.74^{A}{}_{b}$	$55.98\pm1.30^{A}{}_{a}$
	Group:5	$44.60\pm1.07_{b}$	-	$51.86\pm0.88^{B}{}_{a}$	$49.42\pm1.17^{A}{}_{a}$	$50.88\pm0.86^{B}{}_{a}$

The values of parameters are expressed: Total erythrocyte count $\times10^{6}$/µl, haemoglobin gm/dl, packed cell volume % and total leucocyte count $\times10^{3}$/µl. Values represent mean±SD of three replicates and values within the same row with different letters are significantly different (P<0.05). The superscripts of the upper case represent column and subscripts of lower case represent rows.

Table 2: Differential leucocyte count (%) in the different groups of chicken and in different days interval.

	Groups	21st Day	26th Day	28th Day	30th Day	32nd Day
Heterophil	Group:1	$24.14\pm0.76^{B}_{b}$	$28.94\pm1.62_{a}$	$23.02\pm0.78^{C}_{b}$	$28.26\pm0.77^{AB}_{a}$	$30.17\pm1.86^{BC}_{a}$
	Group:2	$32.34\pm3.41^{A}_{a}$	$24.64\pm1.63_{b}$	$27.16\pm1.02^{AB}_{ab}$	$23.48\pm0.51^{D}_{c}$	$28.16\pm0.76^{BC}_{ab}$
	Group:3	$30.40\pm2.06^{A}_{a}$	$28.46\pm1.17_{a}$	$24.00\pm0.87^{C}_{b}$	$27.22\pm1.51^{B}_{ab}$	$30.66\pm1.15^{B}_{a}$
	Group:4	$23.84\pm0.99^{B}_{c}$	-	$28.68\pm0.83^{A}_{b}$	$23.24\pm0.70^{C}_{c}$	$33.46\pm1.22^{A}_{a}$
	Group:5	$28.24\pm0.71^{AB}_{ab}$	-	$24.88\pm0.72^{BC}_{c}$	$30.64\pm0.98^{A}_{a}$	$26.46\pm1.15^{C}_{bc}$
Eosinophil	Group:1	$1.16\pm0.21_{c}$	$1.36\pm0.26_{bc}$	$1.46\pm0.23_{bc}$	$3.12\pm0.32^{A}_{a}$	$2.28\pm0.51^{A}_{ab}$
	Group:2	$1.18\pm0.21_{b}$	$1.04\pm0.14_{b}$	$2.34\pm0.29_{a}$	$1.38\pm0.44^{B}_{b}$	$1.40\pm0.24^{B}_{b}$
	Group:3	1.30±0.20	1.26±0.31	1.32±0.28	0.90 ± 0.31^{B}	1.18 ± 0.21^{B}
	Group:4	1.30±0.20	-	1.36±0.50	1.28 ± 0.30^{B}	0.70 ± 0.19^{B}
	Group:5	1.40±0.24	-	1.00±0.29	1.14 ± 0.22^{B}	0.58 ± 0.15^{B}
Basophil	Group:1	0.54±0.12	0.50±0.13	0.70±0.21	0.32±0.04	1.10±0.40
	Group:2	0.50±0.22	0.78±0.23	1.00±0.28	0.78± 0.15	0.56± 0.19
	Group:3	0.54±0.25	0.58± 0.14	0.60±0.16	0.66± 0.21	0.46±0.23
	Group:4	0.64±0.15	-	0.72±0.36	0.54±0.20	0.64± 0.15
	Group:5	0.34± 0.18	-	0.48±0.19	0.50±0.18	0.22±0.15
Lymphocyte	Group:1	$70.30\pm0.86^{A}_{a}$	$65.76\pm1.51_{b}$	$71.50\pm1.00^{A}_{a}$	$64.92\pm1.19^{C}_{b}$	$63.40\pm2.45^{B}_{b}$
	Group:2	$65.44\pm1.18^{B}_{c}$	$70.04\pm1.70_{b}$	$66.04\pm1.24^{B}_{c}$	$80.74\pm0.54^{A}_{a}$	$66.38\pm0.65^{AB}_{c}$
	Group:3	$66.88\pm1.38^{B}_{ab}$	$65.56\pm1.37_{ab}$	$69.78\pm1.02^{A}_{a}$	$67.58\pm1.80^{C}_{a}$	$63.22\pm1.11^{B}_{b}$
	Group:4	$70.60\pm0.87^{A}_{a}$	-	$65.54\pm0.91^{B}_{b}$	$70.92\pm0.75^{B}_{a}$	$54.02\pm1.46^{C}_{c}$
	Group:5	$66.64\pm0.45^{B}_{b}$	-	$69.76\pm0.76^{A}_{a}$	$64.22\pm0.68^{C}_{c}$	$68.90\pm0.97^{A}_{a}$
Monocyte	Group:1	3.90±0.19	3.44±0.20	3.44±0.20	4.10±0.08	3.78±0.38
	Group:2	3.80±0.34	3.54±0.29	4.02±0.33	3.66±0.29	3.74±0.23
	Group:3	4.10±0.33	4.14±0.17	3.76±0.27	3.70±0.15	4.10±0.13
	Group:4	3.80±0.25	-	4.10±0.19	4.02±0.17	4.46±0.20
	Group:5	3.70±0.20	-	4.06±0.16	3.50±0.18	4.10±0.17

The values of parameters are expressed: All the cells of leucocytes are expressed in per cent (%). Values represent mean±SD of three replicates and values within the same row with different letters are significantly different (P<0.05). The superscripts of the upper case represent column and subscripts of lower case represent rows.

Table 3: The values of serum alanine transaminase (ALT), aspartate transaminase (AST) and total protein (TP).

	Groups	21st Day	26th Day	28th Day	30th Day	32nd Day
ALT	Group:1	$20.80\pm0.37^{AB}_{a}$	$19.06\pm0.48^{C}_{a}$	$19.62\pm0.31^{BC}_{b}$	$19.90\pm0.47^{ABC}_{b}$	$21.18\pm0.43^{A}_{a}$
	Group:2	$19.44\pm0.38^{A}_{b}$	$13.66\pm0.24^{C}_{b}$	$12.84\pm0.14^{D}_{d}$	$13.72\pm0.24^{C}_{e}$	$15.04\pm0.18^{B}_{d}$
	Group:3	$20.04\pm0.46^{A}_{ab}$	$16.50\pm2.90^{A}_{ab}$	$15.96\pm0.34^{A}_{c}$	$16.32\pm0.22^{A}_{d}$	$18.80\pm0.19^{A}_{b}$
	Group:4	$19.38\pm0.38^{AB}_{b}$	$18.98\pm0.46^{AB}_{a}$	$19.62\pm0.24^{A}_{b}$	$18.58\pm0.21^{B}_{c}$	$19.28\pm0.24^{AB}_{b}$
	Group:5	$20.40\pm0.42^{A}_{ab}$	$18.84\pm0.45^{B}_{a}$	$20.74\pm0.29^{A}_{a}$	$21.34\pm0.24^{A}_{a}$	$17.52\pm0.24^{C}_{c}$
AST	Group-1	$144.18\pm5.53^{A}_{a}$	$145.84\pm4.54^{B}_{a}$	$154.46\pm7.07^{A}_{a}$	$157.08\pm5.88^{B}_{a}$	$155.90\pm6.06^{B}_{a}$
	Group:2	$140.66\pm5.34^{A}_{b}$	$137.58\pm5.77^{B}_{b}$	$138.94\pm5.61^{B}_{b}$	$164.22\pm3.69^{B}_{a}$	$171.42\pm4.66^{A}_{a}$
	Group:3	$144.64\pm5.14^{A}_{b}$	$135.04\pm4.60^{B}_{b}$	$134.86\pm5.07^{B}_{b}$	$171.84\pm4.70^{AB}_{a}$	$179.26\pm4.47^{A}_{a}$
	Group:4	$145.10\pm3.30^{A}_{b}$	$144.78\pm5.29^{B}_{b}$	$156.72\pm5.80^{A}_{b}$	$172.34\pm6.13^{AB}_{a}$	$180.04\pm5.39^{A}_{a}$
	Group:5	$146.42\pm4.09^{A}_{c}$	$162.74\pm5.39^{A}_{b}$	$148.46\pm5.51^{AB}_{bc}$	$181.88\pm4.69^{A}_{a}$	$181.24\pm5.30^{A}_{a}$
TP	Group:1	3.54±0.07	$3.84\pm0.07_{ab}$	$3.72\pm0.11_{ab}$	$3.58\pm0.07_{c}$	$3.66\pm0.05_{a}$
	Group:2	3.54 ± 0.09^{AB}	$3.46\pm0.14^{ABC}_{bc}$	$3.92\pm0.45^{A}_{a}$	$2.94\pm0.09^{BC}_{d}$	$2.80\pm0.14^{C}_{c}$
	Group:3	3.14 ± 0.21^{BC}	$4.06\pm0.17^{A}_{a}$	$4.10\pm0.05^{A}_{a}$	$3.44\pm0.09^{B}_{c}$	$3.02\pm0.07^{C}_{bc}$
	Group:4	3.64 ± 0.15^{AB}	$3.54\pm0.09^{B}_{bc}$	$3.10\pm0.11^{C}_{b}$	$3.94\pm0.09^{A}_{b}$	$3.56\pm0.06^{B}_{a}$
	Group:5	3.48 ± 0.12^{B}	$3.12\pm0.20^{B}_{c}$	$3.14\pm0.07^{B}_{b}$	$4.22\pm0.09^{A}_{a}$	$3.10\pm0.11^{B}_{b}$

The values of parameters are expressed: the values of serum ALT, AST and TP are expressed in U/L, U/L and g/dl respectively. Values represent mean±SD of three replicates and values within the same row with different letters are significantly different (P<0.05). The superscripts of the upper case represent column and subscripts of lower case represent rows.

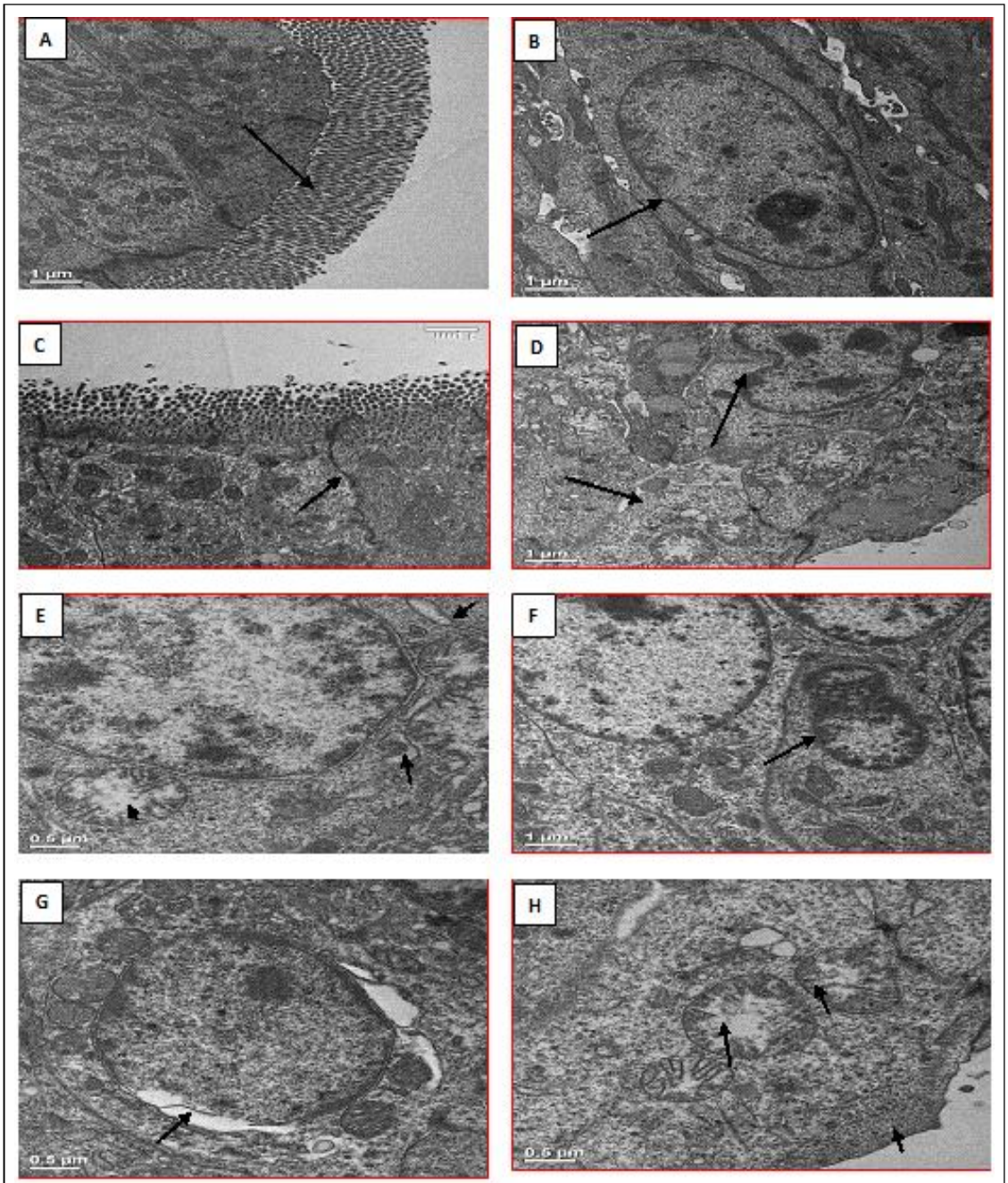

A: Duodenum (control): Ultrastructural architecture of normal and healthy enterocytes (TEM × 2000). **B:** Duodenum (control): Ultrastructural architecture of normal and healthy enterocytes showing normal nucleus with nucleolus (TEM × 4000). **C:** Duodenum (Group-2): disruption of intercellular junctional complexes, formation of gaps between enterocytes and boundary of individual enterocytes are clearly delimited by disruption of intra cellular junction and apparently normal apical domain of enterocytes (TEM ×2000). **D:** Duodenum epithelial cell (Group 2): fragmentation of nuclear material, disruption of cristae of mitochondria (TEM ×2000). **E:** Duodenum epithelium (Group 2): Cristolysis of mitochondria, swelling nuclear membrane and dilatation of endoplasmic reticulum (TEM ×4000). **F:** Duodenum epithelium (Group 2): Swollen mitochondria with disruption of cristae (TEM ×2000). **G:** Duodenum (Group 2): Disruption of nuclear membrane (TEM ×4000). **H:** Duodenum epithelium (Group 2): Disruption of cristae of mitochondria and complete loss of microvilli of enterocytes (TEM ×4000).

Plate 2: Transmission electron microscope (TEM) ultrastructural lesions in the cells of intestine of control group chickens and experimentally induced NE chickens.

marked fatty changes, sinusoidal congestion, hemorrhages and hemosiderin pigments in the hepatic sinusoids were found to be congruent with the findings of Asaduzzaman *et al*. (2011) and Immerseel *et al*. (2004) respectively. Kidneys revealed focal areas of inter tubular congestion, glomeruli constrictions with wide Bowman's space (Plate 1) and Immerseel *et al*. (2004) and Belih *et al*. (2015) documented similar lesions in kidneys. The heart and lungs demonstrated hemorrhages and focal areas of mononuclear cell infiltration (Asaduzzaman *et al*., 2011). The spleen showed depletion of the lymphoid tissue, congestion, sub-capsular heterophil infiltrations, hyperplasia and bursa of Fabricius of group 2 birds revealed depletion of lymphoid cells, necrosis and infiltration of polymorphonuclear cells (Immerseel *et al*., 2004). The brain tissues showed neuronal degenerations, necrosis and neuronophagia (Plate 1).

The intestine of group 4 and 5 birds showed necrosis, sloughing, flattening, shortening of villi, hyperemia, infiltration of inflammatory cells (Belih *et al*., 2015; Suryakanth *et al*., 2019). Liver revealed mild fatty changes, congestion in sinusoid and coagulative necrosis with nuclear degenerations (Sasaki *et al*., 2000). Kidney showed focal areas of coagulative necrosis, inter tubular congestion (Plate 1). Heart showed hemorrhages and focal areas of mononuclear cells infiltrations and lungs revealed congestion, hemorrhages and thickening of alveolar septa and spleen and bursa of Fabricius showed moderate depletion of the lymphoid tissue (Immerseel *et al*., 2004). The intestine showed substantial histopathological changes and it witnessed strong inflammatory reactions (Olkowski *et al*., 2006). The congestion, haemorrhages on the tip and core of villi might be attributed to the inflammatory changes initiated by *Clostridium perfringens* and production of inflammatory mediators like leukotrienes, prostacyclin, platelet activating factor and thromboxane, resulted contraction of blood vessels and aggregation of platelets (Titball *et al*., 1993). Smedley III. *et al*. (2004) reported about marked histopathological lesions caused by coccidia and α toxin of *C. perfringens* and the findings were in accordance to this present study. In the earlier similar studies, it has been revealed that, the partially purified enterotoxins of type A and C of *C. perfringens* displayed cytopathic effects (CPE) and death of cells in Vero cell line (Haque *et al*., 2017).

Ultrastructural lesions

The transmission electron microscopic (TEM) of control bird showed normal ultrastructural architecture of enterocytes and integrity of cell organelles were well preserved (Plate 2). TEM of group 2 and group 3 birds showed disruption of intercellular junctional complexes, formation of gaps between enterocytes. The boundaries of individual enterocytes were found to be delimited, the basal and lateral domains of enterocytes were disrupted while the apical domain remained intact. There was moderate cytoplasmic vacuolization and complete loss of microvilli. The lateral aspects of enterocytes boundaries were absent, disintegration of nuclear material and disruption of cristae of mitochondria (Plate 2) and these ultrastructural lesions were in conformity with Olkowski *et al*. (2008). Cristeolysis and disruptions of cristae of mitochondria, disruption of nuclear membrane, disintegration of nuclear materials with partial to complete loss of microvilli were observed. Besides that, vesiculation, single membrane bound structures, cell extension with condensation of cytoplasm and cellular prominence were recorded in group-3 (Plate 2) and were in agreement with Kaldhusdal *et al*. (1995). The primary ultrastructural lesions in the intestine villi arise at the level of basement membrane and lateral domain of the enterocytes and it might have been due to toxin derived inflammatory reactions of *C. perfringens*.

CONCLUSION

The experimental reproduction of NE in chicken would be helpful to evaluate the *in-vivo* model, virulence of the infectious organism, pathogenesis and pathology. It would provide the better understanding of predisposing factors in reproduction of NE. In this study, coccidia settled haemorrhagic enteritis and provided conducive anaerobic environment for growth and multiplication of *C. perfringens* among experimentally infected groups of chickens and hence those birds displayed substantial clinical signs, gross, histopathological and ultrastructural lesions. Therefore, it established that, the birds infected with *C. perfringens* type A were more virulent in terms of pathogenesis, clinical signs, gross, microscopic and ultrastructural lesions. These observations warrant further evaluation of toxin producing genes and associated predisposing factors in order to put together formidable prevention strategies for NE in chickens.

ACKNOWLEDGEMENT

The authors are greatly thankful to the DEAN, College of Veterinary Science, AAU, Guwahati, for providing facilities and we acknowledge Indian Council of Agricultural Research (ICAR), New Delhi for the award of Senior Research Fellowship (ICAR-SRF) and also for providing fund for research works.

Authors' contributions

D. Behera: Conceived and designed research experiments, authored the initial draft of the manuscript. D.C. Pathak: Performed research experiments and supervised the project. A. Samal: Assisted in re-isolation and molecular detection. M. Kumar: evaluated clinical signs and pathology of the test birds. N. Debbarma: Reviewed/edited the manuscript and assisted in histopathology. P. Goswami: revised the manuscript and evaluation of ultrastructural alterations. P. Behera: Analyzed research data and helped in the haemato-biochemical data interpretation. All the authors read and approved the final manuscript.

Funding

This research did not receive any specific grant from funding agencies in the public, commercial, or not-for-profit sectors.

Availability of data and materials

All data generated or analyzed during this study are included in this manuscript.

Declarations

Ethics approval and consent

All animal experiments were assessed and approved after obtaining the recommendation of Institutional Animal Ethics Committee (IAEC). All methods were performed in accordance with the relevant guidelines and regulations. The study was carried out in compliance with the ARRIVE guidelines.

Consent for publication

Not applicable.

Conflict of interest

The authors declare that they have no competing interests.

REFERENCES

Agunos, A., Carson, C., Leger, D. (2013). Antimicrobial therapy of selected diseases in turkeys, laying hens and minor poultry species in Canada. Canadian Veterinary Journal. 54: 1041-1052.

Aktar, S., Rahman, S., Khaton, R., Khatun, A., Sadi, M.S., Gofur, M.R. (2022). Prevalence and Clinicopathological Investigation of Necrotic Enteritis at Rajshahi District in Bangladesh. South Asian Research Journal of Biology and Applied Biosciences. 4(1): 18-25.

Al-Sagan, Ahmed A., Abudabos, Alaeldein M. (2018). Effect of eubiotic administration to broiler's feed on intestinal morphology and microbiology under Clostridium perfringens challenge. Indian Journal of Animal Research. 52(6): 824-828. doi: 10.18805/ijar.10774.

Asaduzzaman, M., Miah, M.S., Siddika, A., Popy, N., Hossain, M.M. (2011). Experimental production of necrotic enteritis in broiler chickens. Bangladesh Journal of Veterinary Medicine. 9: 33-41.

Atta, A.H., Shalaby, M.A., Saifan, H.Y. (2014). Efficacy of *Commiphora molmol* extract against *Clostridium perfringens* experimental infection in chicken. World Journal of Pharmacy and Pharmaceutical Sciences. 3: 365-380.

Belih, S.S., Labib, Z.M., Ragab, A.M. (2015). Role of saltose probiotic for the control of the experimental infection of the *Clostridium perfringens* and the coccidia in chickens. Alexandria Journal of Veterinary Sciences. 46: 20-41.

Bollela, V., Sato, N.D., Fonseca, B.A.L. (1999). McFarland nephelometer as a simple method to estimate the sensitivity of polymerase chain reaction using *Mycobacterium tuberculosis* as a research tool. Brazilian Journal Medical and Biological Research. 32: 1073-1076.

Cooper, K.K. and Songer, G.J. (2010). Virulence of *Clostridium perfringens* in an experimental model of poultry necrotic enteritis. Veterinary Microbiology. 142: 323-28.

Cooper, K.K., Songer, J.G., Uzal, A.F. (2013). Diagnosing clostridial enteric disease in poultry. Journal of Veterinary Diagnostic and Investigation. 25: 314-327.

Crespo, R., Franca, M., Shivaprasad, H.L. (2013). Ulcerative enteritis-like disease associated with *Clostridium sordellii* in quail. Avian Diseases. 57: 698-702.

Culling, C.F.A. (1974). Handbook of Histopathological and Histochemical Technique Including Museum Techniques. 3rd Edition, Butterworth and Heinemann (Publishers) Ltd., Elsevier, Oxford, UK.

El-Sheikh, S.M., Khairy, M.H., Eleiwa, N.Z., Abdalla, O.E., Abd El-Monsef, A.G. (2018). Effect of sanguinarine phytobiotic, sodium butyrate compared to ampicillin on controlling necrotic enteritis in broiler chickens. Slovenian Veterinary Research. 55: 405-414.

Goossens, E., Erum, J.V., Gussem, M.D., Limbergen, T.V., Callens, C., Zutter, L.D., Ducatelle, R., Immerseel, F.V. (2020). Incidence and associated risk factors of necrotic enteritis in Belgian layer pullet flocks. Avian Pathology. 49(5): 476-485.

Haque, S., Sharma, R.K., Barman, N.N., Laishram, B.D., Barkalita, M.L., Hussain, I. (2017). Characterization of enterotoxin producing Clostridium perfringens isolated from foods of animal origin. Indian Journal of Animal Research. 52(1): 111-115. doi: 10.18805/ijar.v0iOF.9129.

Hayat, M.A. (2000). Principles and Techniques of Electron Microscopy: Biological Applications. 4th Edn., Cambridge University Press, Cambridge, UK.

He, W., Goes, E.C., Wakaruk, J., Barreda, D.R., Korver, D.R. (2022). A poultry subclinical necrotic enteritis disease model based on natural *Clostridium perfringens* uptake. Frontiers in Physiology. 13: 788592.

Hunter, S.E.C., Brown, J.E., Oyston, P.C.F. (1993). Molecular genetic analysis sequence homology with alpha-toxin, gama-toxin and leukocidin of *Staphylococcus aureus*. Infection and Immunity. 61: 3958-3965.

Immerseel, F.V., Buck, J.D., Pasmans, F., Huyghebaert, G., Haesebrouck, F., Ducatelle, R. (2004). *Clostridium perfringens* in poultry: An emerging threat for animal and public health. Avian Pathology. 33: 537-549.

Immerseel, F.V., Rood, J.I., Moore, R.J., Titball, R.W. (2009). Rethinking our understanding of the pathogenesis of necrotic enteritis in chickens. Trends Microbiology. 17: 32-36.

Kaldhusdal, M., Evensen, O., Landsverk, T. (1995). *Clostridium perfringens* necrotizing enteritis of the fowl: A light microscopic, immune-histochemical and ultrastructural study of spontaneous disease. Avian Pathology. 24: 421-433.

Kiu, R., Brown, J., Bedwell, H., Leclaire, C., Caim, S., Pickard, D., Dougan, G., Dixon, R.A., Hall, L.J. (2019). Genomic analysis on broiler-associated *Clostridium perfringens* strains and exploratory caecal microbiome investigation reveals key factors linked to poultry necrotic enteritis. Animal Microbiome. 1(1): 12-14.

Koli, D., Kadam, M., Gole, M., Patil, A., Hajare S., Yeskal, A., Kolte, S., Kurkure N. (2017). Efficacy of bacillus subtilis (GalliPro) supplementation in clostridium perfringens challenged necrotic enteritis of broiler chicken. Indian Journal of Animal Research. 52(4): 619-622. doi: 10.18 805/ijar.B-3253.

Koneman, E.W., Auen, S.D., Dowell, V.R., Sommers, H.M. (1988). Color Atlas and Text Book of Diagnostic Microbiology 2nd Edn., J.B. Lip. Co. New York, London.

Meskerem, A., Chaiwat, B., Nirat, G., Montakan, V. (2013). Haematological, biochemical and histopathological changes caused by coccidiosis in chickens. Kasetsart Journal (Nat. Sci.). 47: 238-246.

Olkowski, A.A., Wojnarowicz, C., Chirino-Trejo, M., Drew, M.D. (2006). Responses of broiler chickens orally challenged with Clostridium perfringens isolated from field cases of necrotic enteritis. Research in Veterinary Science. 81: 99-108.

Olkowski, A.A., Wojnarowicz, C., Chirino-Trejo, M., Laarveld, B., Sawicki, G. (2008). Subclinical necrotic enteritis in broiler chickens: Novel etiological consideration based on ultrastructural and molecular changes in the intestinal tissue. Research in Veterinary Science. 85: 543-553.

Paiva, D. and McElroy, A. (2014). Necrotic enteritis: Applications for the poultry industry. Journal of Applied Poultry Research. 23: 557-566.

Petit, L., Gilbert, M., Popoff, M.R. (1999). Clostridium perfringens: Toxinotype and genotype. Trends in Microbiology. 7: 104-110.

Sasaki, J., Goryo, M., Okada, K. (2000). Cholangiohepatitis in chickens induced by bile duct ligations and inoculation of *Clostridium perfringens*. Avian Pathology. 29: 405-410.

Savva, C.G., Fernandes da Costa, S.P., Bokori-Brown, M., Naylor, C.E., Cole, A.R., Moss, D.S., Titball, R.W., Basak, A.K. (2013). Molecular architecture and functional analysis of NetB, a pore forming toxin from *Clostridium perfringens*. Journal of Biological Chemistry. 288: 3512-3522.

Shane, J.E., Gyimah, K.S., Harrington, Snider, T.G. (1985). Etiology and pathogenesis of necrotic enteritis. Veterinary Research Communications. 9: 269-287.

SmedleyIII, J.G., Fisher, D.J., Sayeed, S., Chakrabarti, G., McClane. B.A. (2004). The enteric toxins of *Clostridium perfringens*. Reviews of Physiology, Biochemistry and Pharmacology. 152: 183-204.

Suryakanth, K.C., Sathyanarayan, M.L., Mallinath, K.C., Narayanaswamy, H.D., Kumar, S., Sugunarao, G., Upendra, Shridhar, N.B. (2019). Study on pathomorphological and biochemical changes in experimentally induced necrotic enteritis in broiler chicken. International Journal of Current Microbiology and Applied Sciences. 8: 2795-2810.

Timbermont, L., Lanckriet, A., Gholamiandehkordi, A.R., Pasmans, F., Martel, A., Haesebrouck, F., Ducatelle, R., Immerseel, F.V. (2009). Origin of *Clostridium perfringens* isolates determines the ability to induce necrotic enteritis in broilers. Comparative Immunology, Microbiology and Infectious Diseases. 32: 503-512.

Titball, R.W., Hunter, S.E.C., Martin, K.L., Morris, B.C., Shuttleworth, A.D., Rubidge, T. anderson, D.W., Kelly, D.C. (1989). Molecular cloning and nucleotide sequence of the alpha-toxin (phospholipase C) of *Clostridium perfringens*. Infection and Immunity. 57: 367-376.

Titball, R.W. (1993). Bacterial phospholipases C. Microbiology Review. 57: 347-366.

Van Waeyenberghe, L., De Gussem, M., Verbeke, J., Dewaele, I., De Gussem, J. (2016). Timing of predisposing factors is important in necrotic enteritis models. Avian Pathology. 45: 370-375.

Yang, W.Y., Chou, C.H., Wang, C. (2018). Characterization of toxin genes and quantitative analysis of netB in necrotic enteritis (NE)-producing and non-NE-producing *Clostridium perfringens* Isolated from Chickens. Anaerobe. 54: 115-120.