RESEARCH ARTICLE Indian Journal of Animal Research, Volume 57 Issue 6: 777-782 (June 2023)

Protective Effect of Naringenin on Cadmium-induced Toxicity in Rat Liver

Ke Wang[1], Lulu Ding[1], Congying Kou[1], Ruxue Huang[1], Pengli Zhao[1], Zijun Yang[1], Jicang Wang[1] 10.18805/IJAR.BF-1425

ABSTRACT

Background: Cadmium (Cd) is a widespread environmental toxic heavy metal. Naringin (Nar) is reported to have a protective effect on Cd-induced liver injury. This study aimed to explore the hepatic injury induced by Cd and the protective effects of Nar on Cd-induced oxidative stress and apoptosis in rat liver.

Methods: In accordance with groups, male SD rats were injected intraperitoneally with Cd and orally with Nar every day. The treatment period was 3 weeks. Body weight, the morphological changes in liver, the activity of antioxidant indices and expression of the apoptotic genes caspase-3 and -9 were assessed.

Result: Results showed that the body weight of Cd-exposed rats decreased, the superoxide dismutase and catalase activities in liver decreased, the glutathione content decreased and the malondialdehyde content increased. Further, Cd-induced hepatic structural damage and cell apoptosis were observed. However, Nar could alleviate liver damage caused by Cd. Therefore, Cd caused oxidative damage and cell apoptosis in rat liver, while Nar had preventive and ameliorative effects on these injuries.

Key words: Apoptosis, Cadmium, Liver, Naringenin, Oxidative damage.

INTRODUCTION

Cadmium (Cd) is a common environmental toxicant that has harmful effects on plants, animals and humans (Nisha *et al*., 2009). In 1993, the International Agency for Research on Cancer classified Cd as human carcinogen I and the National Toxicology Program identified Cd as human carcinogen (Xiong *et al*., 2020). Cd is one of the most toxic heavy metals and a common industrial pollutant present in the environment (Adefegha *et al*., 2015). At present, the main sources of Cd are smoking tobacco and drinking contaminated water pollution (Soisungwan *et al*., 2013). Other sources include fertilizers, glass and batteries (Claudio *et al*., 2011). The biological half-life of Cd in the human body is up to 10-30 years (Kazuhiro *et al*., 2016) and the absorbed Cd mainly accumulates in the liver and kidney of the organism. The toxicity of Cd is mainly attributed to its damage to the redox system of the body (Stohs *et al*., 2000). Cd exposure leads to the change in mitochondrial membrane permeability, intensifies the occurrence of various apoptotic pathways and leads to apoptosis (Rahman *et al*., 2017). Naringenin (Nar) is a dihydroflavonol active ingredient found in Ruta plants. It is Fruits, vegetables, tea and red wine are rich in Nar (Manchope *et al*., 2017). In addition, Nar has various biological activities, such as antioxidant, anti-inflammatory and liver protection (Zhu *et al*., 2015). Therefore, some studies have found that Nar is an important ingredient for effective treatment of Cd poisoning (Manchope *et al*., 2017). However, no relevant report is available about the regulation of Nar on the caspase-dependent apoptosis pathway.

In this study, an acute Cd poisoning rat model was established via intraperitoneal injection of $CdCl_2$ solution. The liver antioxidant index, liver pathological section and mRNA expression of caspase-3 and -9 were detected using real-time quantitative PCR (qRT-PCR) to evaluate the effect of Cd on the structure and function of rat liver and the preventive effect of Nar on liver toxicity caused by acute Cd-exposure. The results showed that subsequent use of plant polyphenol extract Nar could prevent and ameliorate Cd poisoning.

[1]College of Animal Science and Technology, Henan University of Science and Technology, Luoyang, China.

Corresponding Author: Jicang Wang, College of Animal Science and Technology, Henan University of Science and Technology, No. 263, Kaiyuan Avenue, 471023, Luoyang, PR China.
Email: wangjicang@126.com

How to cite this article: Wang, K., Ding, L., Kou, C., Huang, R., Zhao, P., Yang, Z. and Wang, J. (2023). Protective Effect of Naringenin on Cadmium-induced Toxicity in Rat Liver. Indian Journal of Animal Research. 57(6): 777-782. doi: 10.18805/IJAR.BF-1425.

Submitted: 13-08-2021 **Accepted:** 06-10-2021 **Online:** 07-11-2021

MATERIALS AND METHODS

Chemicals

Anhydrous $CdCl_2$ was purchased from Aladdin Industrial Corporation. Nar (purity: > 98%) was obtained from Beijing Bailingwei Technology Co., Ltd (Beijing, China). Superoxide dismutase (SOD), catalase (CAT), glutathione (GSH) and malondialdehyde (MDA) kits were from Nanjing Jiancheng Bioengineering Institute, (Nanjing, China). TRIzol isolation kit and PCR primers were obtained from Sangon Biotech Co., Ltd (Shanghai, China). SYBR Premix Taq II kit was purchased from Takara (Beijing, China). All other routine chemicals and solvents were of pure analytical grade.

Animal treatment

The experiment was conducted from August to December 2020 at the Environmental Animal Product Safety Laboratory of Henan University of Science and Technology, Luoyang, China. Adult male Sprague Dawley (SD) rats weighing 160-180 g were housed in polypropylene cages maintained at room temperature (24°C±2°C) on a 12-h light/12-h dark cycle throughout the experiment. They were fed with a commercial standard diet, with free access to drinking water under standard laboratory conditions. The grouping and processing methods is shown in Table 1. All animal experimental processes were approved by the Institute of Zoology and Medical Ethics Committee of Henan University of Science and Technology and they were strictly designed under the consideration of animal welfares (approval number HAUST 19013).

Every weekend, the rat's body weight was recorded. The experiment lasted for 3 weeks. The rats were sacrificed by cervical decapitation 24 h after the last treatment. Liver tissues were removed from the sacrificed rats and washed in PBS. The tissues were fixed with 10% formalin for histopathological studies, frozen for qRT-PCR and crushed, homogenized (10%, w/v) in PBS solution (pH 7.4) and centrifuged (3000 rpm for 10 min) for various biochemical estimations.

Histopathological studies

Tissue samples of the liver was fixed in 10% formalin at 4°C for 24 h. Then, different concentrations of ethanol were used as a dehydrating agent for step-by-step dehydration. The dehydrated liver tissues were embedded in paraffin. The paraffin blocks were sliced into 4-6 µm thick with a microtome. The obtained tissue sections were stained with hematoxylin-eosin and observed using an optical microscope.

Table 1: Grouping and processing methods (n=6).

Groups	Processing methods
Control group	Given redistilled water + i. p. with 0.9% NaCl
0.5 mg/kg Cd group	i. p. with 0.5 mg/kg b.w. of $CdCl_2$
1 mg/kg Cd group	i. p. with 1 mg/kg b.w. of $CdCl_2$
2 mg/kg Cd group	i. p. with 2 mg/kg b.w. of $CdCl_2$
Nar group	Administered with Nar (100 mg/kg b.w.)
Nar + Cd group	Administered with Nar (100 mg/kg b.w.) + i. p. with 2 mg/kg b.w.

Antioxidant analysis

SOD, MDA, CAT and GSH activities were measured using the diagnostic kits in accordance with the manufacturer's protocol. These results were measured spectrophotometrically.

mRNA expression

Total RNA was extracted from the rat liver tissue by using a TRIzol reagent and the total RNA was reverse transcribed to synthesize cDNA. The primers were designed using Primer Premier 6 (Table 3). The instructions in the SYBR Premix Taq Gamma II Kit for qRT-PCR were followed. β-actin was used as endogenous control and the relative mRNA levels were analyzed using $2^{-\Delta\Delta CT}$ method.

Statistical analysis

The data obtained under different experimental conditions were analyzed by one-way variance method in SPSS version 17. When $P<0.05$ or $P<0.01$, the difference was considered significant or highly significant, respectively.

RESULTS AND DISCUSSION

Effect of Nar on Cd-induced changes in body weight

Compared with the control group, the Cd groups decreased showed body weight. The body weight of the 1 mg/kg Cd group decreased significantly ($P<0.05$), while that of the 2 mg/kg Cd group decreased highly significantly ($P<0.01$), as shown in Table 2. However, after treatment with Nar (100 mg/kg) and Cd exposure for 2 and 3 weeks, the body weight significantly increased compared with that of the 2 mg/kg Cd group ($P<0.05$).

Histological assessment of liver tissues

The results showed that the structure of liver tissues in the control group (Fig 1A) was complete and normal, the shape was clear and the arrangement of hepatocytes was orderly. The Cd groups (Fig 1B-D) showed Cd-induced pathological changes in the liver tissue and irregular arrangement of hepatic cords, atrophic and necrotic hepatocytes, indistinct in space and extensively denatured and necrotic and some cell nuclei showed pyknosis. In the Nar group (Fig 1E), the morphology of liver tissue cells was normal and without any pathological phenomenon.

In the Nar + Cd group, a small amount of tissue showed slight hyperplasia or degeneration and the degree of damage was relieved compared with the Cd group (Fig 1F).

Table 2: Effects of Nar on Cd-induced changes in body weight (g) (n=6).

Treated	Week 0	Week 1	Week 2	Week 3
Control group	164.5±5.9	222.3±8.4	277.7±9.2	322.7±12.9
0.5 mg/kg Cd group	177.3±6.3	227.7±5.9	265.3±3.5	308.8±3.8
1 mg/kg Cd group	170.5±7.4	207.7±9.5	245.8±6.4*	291.2±10.7*
2 mg/kg Cd group	176.3±2.7	180.0±2.6*	213.8±3.4**	235.5±7.0**
Nar group	172.7±3.9	223.3±4.6	274.3±4.8	312.5±7.8
Nar + Cd group	177.7±6.9	183.3±5.3	248.2±5.2*##	269.0±6.5*#

Date are presented as mean±SEM deviation. *$P<0.05$ or **$P<0.01$ represents a significant difference or highly significant difference compared with the control group. #$P<0.05$ or ##$P<0.01$ represents a significant difference or highly significant difference compared with the 2 mg/kg Cd group.

Effect of Nar on liver oxidative stress

As shown in Fig 2, a significant (P<0.05) decrease in the activities of enzymatic antioxidants (SOD and CAT) and the GSH content were observed in the Cd-treated rats. However, the MDA content was significantly higher (P<0.05) and the 2 mg/kg Cd group demonstrated a highly significant difference compared with the control group (P<0.01). Compared with the 2 mg/kg Cd group, the Nar + Cd group showed that the activities of SOD and CAT increased highly significantly (P<0.01) and the GSH content significantly increased (P<0.05). However, the MDA content of the Nar + Cd group decreased highly significantly (P<0.01). No significant difference was found on these indicators between the Nar group and the control group (P<0.05).

Effect of Nar on caspase-9 and -3 mRNA expression

The qRT-PCR results showed that Cd exposure induced an increase in the mRNA expression of caspase-9 and -3 and the mRNA expression increased with the increase in Cd

Table 3: Primer sequences of real-time PCR target genes.

Target gene	Primers sequences (5′→3′)	Temperature
Caspase-9	F: TGCACTTCCTCTCAAGGCAGGACC	66
	R: TCCAAGGTCTCCATGTACCAGGAGC	
Caspase-3	F: GGGATGCCTTTGTGGAACTATATG	60
	R: TGAGCAGCGTCTTCAGAGACA	
β-actin	F: GGAGATTACTGCCCTGGCTCCTA	63
	R: GACTCATCGTACTCCTGCTTGCTG	

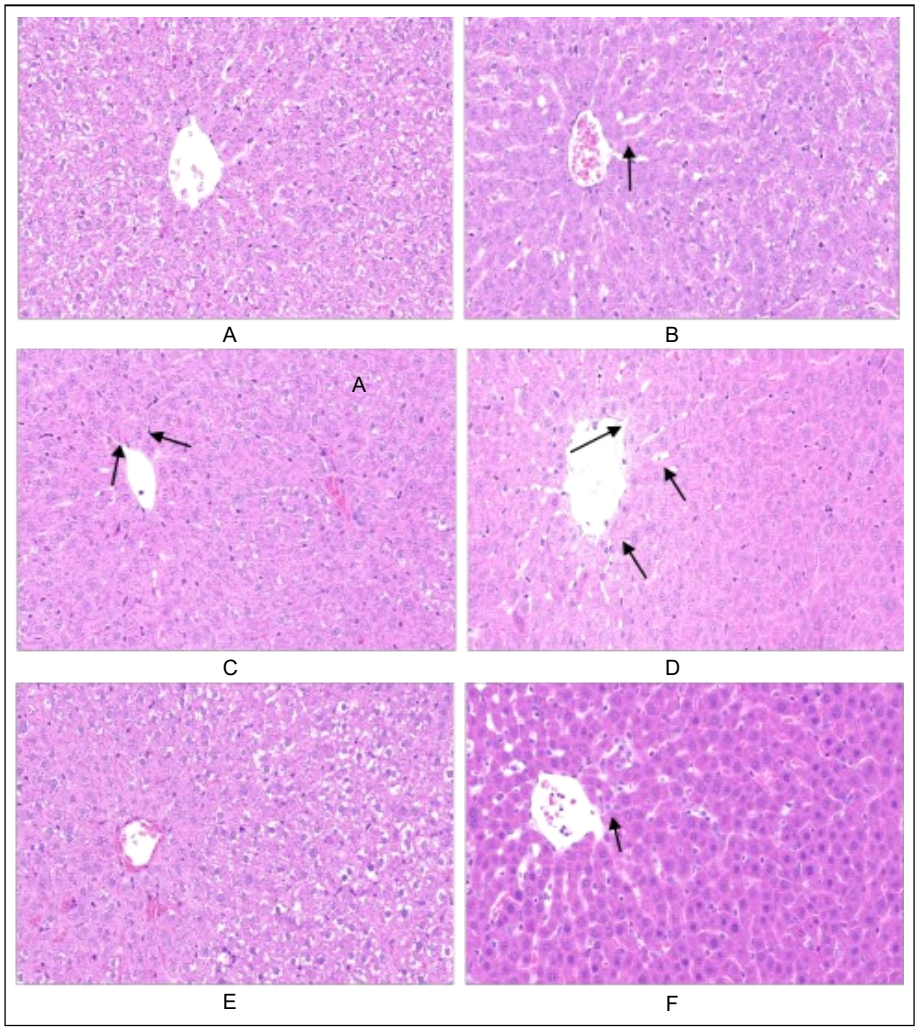

Fig 1: Pathological changes in liver tissue were observed by staining (40×).
A (control), B (Cd, 0.5 mg/kg b.w.), C (Cd, 1 mg/kg b.w.), D (Cd, 2 mg/kg b.w.), E (Nar, 100 mg/kg b.w.) and F (Nar, 100 mg/kg + Cd, 2 mg/kg b.w.).

concentration (Fig 3). However, the level of caspase-9 and -3 mRNA expression was significantly lower (P<0.05) in the Nar + Cd group than in the 2 mg/kg Cd group.

Cd is one of the most widely used heavy metals in the contemporary world and its effect on the environment and humans are well known. Under Cd exposure, various organs of the body are affected to varying degrees, with liver being the most affected (Dkhil *et al*., 2014).

Body weight is regarded as an important indicator of animal health and weight gain depends on the supply and absorption of nutrients (Bhattacharya and Haldar, 2012). Cd exposure could lead to intestinal mucosal cell damage, thereby reducing the absorption and retention of nutrients. In addition, heavy-metal exposure may damage the glucocorticoid system and glucocorticoid system disorders could lead to weight changes (Akomolafe *et al*., 2016). In the present study, the fur of SD rats in the Cd-induced group was messy and dull. As shown in Table 2, the body weight of Cd-induced rats was significantly reduced compared with that of rats in the control group. These results are consistent with those of a previous study (Wang *et al*., 2019). The weight loss of rats may be due to the damage in the intestinal mucosa and the disorder of glucocorticoid system caused by Cd.

Histopathological changes could directly reflect liver injury. Cd exposure caused significant liver pathological changes and a comparable finding was made by (Gong *et al*., 2019). This finding may be due to the accumulation of free radicals caused by Cd exposure, which eventually leads to organ damage (Skipper *et al*., 2016). Oxidative damage is the most representative of Cd-induced liver damage; the Cd in the body induces tissues to produce reactive oxygen species (ROS), which reduces the organ's ability to respond to oxidative stress (Branca *et al*., 2018). In the past few years, Nar is one of the most popular antioxidants and it has shown that antioxidants could resist the toxicity of heavy metals (Zhang *et al.,* 2012). In the present study, the levels of SOD, CAT, GSH and MDA were determined to illustrate the toxicity of Cd to the liver and the effect of Nar.

GSH resists oxidation by combining sulfhydryl groups with ROS and inhibiting the formation of ROS is the first line of defense for non-enzymatic antioxidants (Loro *et al*., 2012). SOD has the function of scavenging oxygen free radicals produced in the body. CAT is an important enzyme in the body's redox system and it could protect cells from the oxidative damage from H_2O_2 and OH^- (Shahat *et al*., 2017). In the present study, the activities of CAT and SOD and the GSH content in the Cd-induced group were lower than those in the control group, indicating that Cd remarkably weakened the antioxidant capacity of the rat liver and the activities of CAT and SOD and the GSH content decreased in a dose-dependent manner in liver treated with Cd. Then, the rats

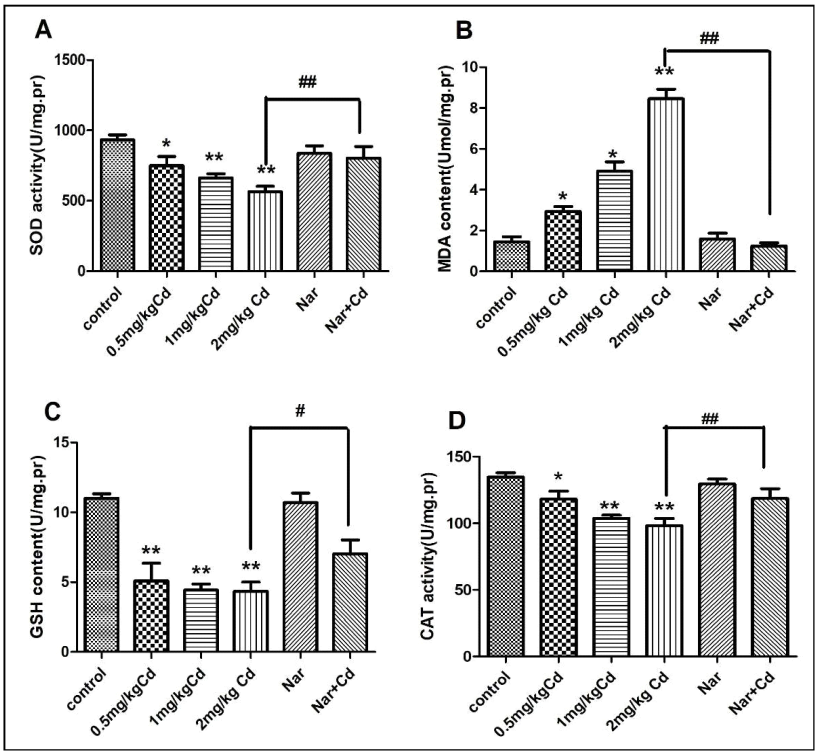

Fig 2: Effect of Nar on liver oxidative stress.

(A) SOD, (B) MDA, (C) GSH and (D) CAT. Date are presented as mean±SEM deviation. *P<0.05 or **P<0.01 represents a significant difference or highly significant difference compared with the control group. $^{\#}P$<0.05 or $^{\#\#}P$<0.01 represents a significant difference or highly significant difference compared with the 2 mg/kg Cd group n=6 in each group.

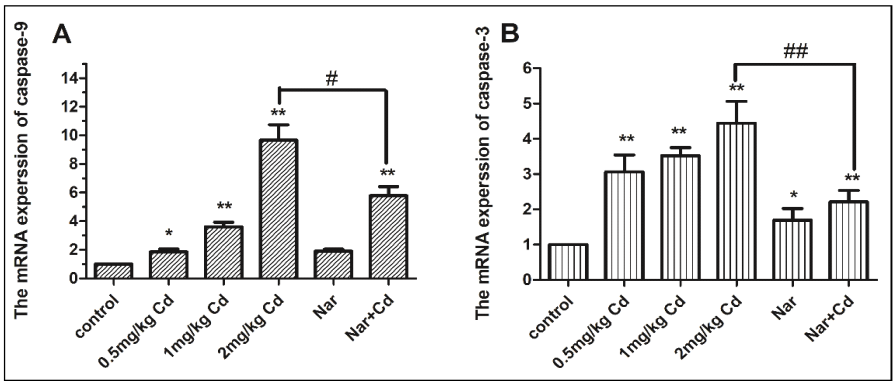

Fig 3: Expression of mRNA of caspase-9 (A) and caspase-3 (B) in the mitochondrial apoptosis pathway. Date are presented as mean±SEM deviation. **P*<0.05 or ***P*<0.01 represents a significant difference or highly significant difference compared with the control group. #*P*<0.05 or ##*P*<0.01 represents a significant difference or highly significant difference compared with the 2 mg/kg Cd group n=6 in each group.

were administrated with Nar and Cd. As shown in Fig 2, the activities of SOD and CAT between the Nar + Cd group and the 2 mg/kg Cd group were highly significantly different (*P*<0.01). The GSH content was also significantly different (*P*<0.05). MDA is considered one of the biomarkers of oxidative stress (Zhang *et al*., 2014). Fig 2 shows that compared with the control group, the Cd-exposed group had significantly increased MDA content and with the increase in Cd concentration, the difference became more significant. After Nar was administered, the MDA content in the Nar + Cd group decreased highly significantly compared with that in the 2 mg/kg Cd group (*P*<0.01). The above results indicated that Cd could cause oxidative damage to the liver and as an antioxidant, Nar could protect the liver and reduce Cd damage.

Several studies have reported that Cd induced mitochondrial caspase-dependent apoptotic gene expression, leading to cell apoptosis (Banik *et al*., 2019). However, whether Nar could inhibit Cd-induced liver cell apoptosis was unclear. Therefore, the mRNA expression levels of related apoptotic genes were analyzed in the present study. Cd-induced mitochondrial superoxides preferentially accumulate, leading to mitochondrial dysfunction and rupture of the outer membrane; cytochrome c (cyt-c) is released by the mitochondria and caspase-9 is activated and then cascades to activate caspase-3, causing caspase-dependent apoptosis (Kim *et al*., 2015). Caspase-9 is an essential executor of the mitochondrial pathway to induce apoptosis and caspase-3 is the key final executive molecule of various apoptotic methods and an important marker of apoptosis (Wu *et al*., 2020). In the present study, the mRNA expression levels of caspase-9 and -3 in the Cd groups markedly increased compared with those in the control group, while those in the Nar + Cd group were significantly lower than those in the 2 mg/kg Cd group. Therefore, Cd could induce apoptosis in rat liver cells and increase the mRNA expression of caspase-9 and -3, while Nar suppresses Cd-induced apoptosis. In the mitochondrial apoptosis pathway, oxidative stress plays a key role in Cd-induced apoptosis (Wang *et al*., 2009). Therefore, as an antioxidant, Nar inhibits Cd-induced apoptosis by reducing oxidative stress.

ACKNOWLEDGEMENT

This study was supported by grants from the National Nature Science Foundation of China (No.31972753).

REFERENCES

Adefegha, S.A., Omojokun, O.S., Oboh, G, Fasakin, O, Ogunsuyi, O. (2015). Modulatory effects of ferulic acid on cadmium-induced brain damage. Journal of Evidence-Based Complementary and Alternative Medicine. 214: 56-61.

Akomolafe, R.O., Imafidon, C.E., Olukiran, O.S., Oladele, A.A. and Ajayi, A.O. (2016). Livolin Forte ameliorates cadmium-induced kidney injury in wistar rats. Serbian Journal of Experimental and Clinical Research. 17: 107-116.

Banik, S., Akter, M., Corpus, B. S., Saito, T., Hosokawa, T., Kurasaki, M. (2019). Carvacrol inhibits cadmium toxicity through combating against caspase dependent/independent apoptosis in PC12/cells. Food and Chemical Toxicology. 134: 110835.

Bhattacharya, S. and Haldar, P. (2012). Trichosanthes dioica fruit ameliorates experimentally induced arsenic toxicity in male albino rats through the alleviation of oxidative stress. Biological Trace Element Research. 148: 232-241.

Branca, J., Morucci, G., Maresca, M., Tenci, B., Cascella, R., Paternostro, F., Ghelardini, C., Gulisano, M., Mannelli, L., Pacini, A. (2018). Selenium and zinc: Two key players against cadmium-induced neuronal toxicity. Toxicology *In vitro*. 48: 159-69.

Claudio, L., Rosalia, S., Alessandra, L. (2011). Cadmium as a transcriptional modulator in human cells. Critical Reviews in Toxicology. 411: 75-82.

Dkhil, M.A., Al-Quraishy, S., Diab, M.M.S., Othman, M.S., Aref, A.M., Moneim, A.E.A. (2014). The potential protective role of *Physalis peruviana* L. fruit in cadmium-induced hepatotoxicity and nephrotoxicity. Food and Chemical Toxicology. 74: 98-106.

Gong, Z.G., Wang, X.Y., Wang, J.H., Fan, R.F., Wang, L. (2019). Trehalose prevents cadmium-induced hepatotoxicity by blocking Nrf2 pathway, restoring autophagy and inhibiting apoptosis. Journal of Inorganic Biochemistry. 192: 62-71.

Kazuhiro, N., Yasushi, S., Masao, I., Keiko, A., Rie, O., Muneko, N., Hideaki, N., Teruhiko, K. (2016). Attenuation of urinary cadmium in inhabitants of the environmentally exposed jinzu river basin determined by applying a mixed linear model. Bulletin of Environmental Contamination and Toxicology. 96: 699-703.

Kim, S., Park, K., Choe, J. (2015) Oxidative stress by monosodium urate crystals promotes renal cell apoptosis through mitochondrial caspase-dependent pathway in human embryonic kidney 293 cells: Mechanism for urate-induced nephropathy. Apoptosis. 201: 38-49.

Loro, V.L., Jorge, M.B., Silva, K.R., Wood, C.M. (2012). Oxidative stress parameters and antioxidant response to sublethal waterborne zinc in a euryhaline teleost fundulus heteroclitus: Protective effects of salinity. Aquatic Toxicology. 110: 187-93.

Manchope, M.F, Casagrande, R., Verri, W.A. (2017) Naringenin: An analgesic and anti-inflammatory citrus flavanone. Oncotarget. 83: 3766-3767.

Nisha, A.R., Nair, A.M.C., Gopakumar, N. and Joy, A.D. (2009). Assessment of cadmium concentration and its relation with serum biochemical parameters in cattle in cadmium industrial effluent contaminated area. Indian Journal of Animal Research. 43: 206-208.

Rahman, M., Ukiana, J., Uson-Lopez, R., Sikder, M., Saito, T. and Kurasaki, M. (2017). Cytotoxic effects of cadmium and zinc co-exposure in PC12 cells and the underlying mechanism. Chemico-Biological Interactions. 269: 41-49.

Shahat, A.N.E., Azeem, A.M.A., Mekawey, H.M.S., El-megid, M.H.M.A. (2017). Studying the effect of g-irradiated celery leaves on antioxidant status and cardiac enzymes in hypercholesterolemic rats. Indian Journal of Animal Research. DOI: 10.18805/ijar.v0iOF.9146.

Skipper, A., Sims, J., Yedjou, C., Tchounwou, P. (2016). Cadmium chloride induces DNA damage and apoptosis of human liver carcinoma cells *via* oxidative stress. International Journal of Environmental Research and Public Health. 13: 88. doi: 10.3390/ijerph13010088.

Soisungwan, S., Witaya, S., Werawan, R., Muneko, N., Patricia, R. (2013). Modeling cadmium exposures in low- and high-exposure areas in Thailand. Environmental Health Perspectives. 121: 531-536.

Stohs, S.J., Bagchi, D., Hassoun, E., Bagchi, M. (2000). Oxidative mechanisms in the toxicity of chromium and cadmium ions. Journal of Environmental Pathology, Toxicology and Oncology. 19: 201-213.

Wang, L., Cao, J., Chen, D., Liu, X., Lu, H., Liu, Z. (2009). Role of oxidative stress, apoptosis and intracellular homeostasis in primary cultures of rat proximal tubular cells exposed to cadmium. Biological Trace Element Research. 1271: 53-68.

Wang, J., Zhu, H., Zhang, C., Wang, H., Yang, Z. (2019) Baicalein ameliorates cadmium-induced hepatic and renal oxidative damage in rats. Indian Journal of Animal Research. 53: 523-527.

Wu, P., Song, Q., Yu, Y., Yu, H., Luo, H., Tan, S. (2020). Effect of metformin on mitochondrial pathway of apoptosis and oxidative stress in cell model of nonalcoholic fatty liver disease. Chinese Journal of Hepatology. 281: 64-68. Chinese.

Xiong, X, Zhang, Y., Xing, H., Xu, X. (2020) Ameliorative effect of selenomethionine on cadmium-induced hepatocyte apoptosis *via* regulating pi3k/akt pathway in chickens. Biological Trace Element Research. 195: 559-568.

Zhang, H., Cai, C., Shi, C., Cao, H., Han, Z., Jia, X. (2012). Cadmium-induced oxidative stress and apoptosis in the testes of frog Rana limnocharis. Aquatic Toxicology. 15: 67-74.

Zhang, H., Pan, L., Tao, Y. (2014). Antioxidant responses in clam venerupis philippinarum exposed to environmental pollutant hexabromocyclododecane. Environmental Science and Pollution Research International. 113: 8206-8215.

Zhu, L., Wang, J., Wei, T., Gao, J., He, H., Chang, X., Yan, T. (2015). Effects of Naringenin on inflammation in complete freund's adjuvant-induced arthritis by regulating Bax/Bcl-2 balance. Inflammation. 38: 245-251.