RESEARCH ARTICLE Indian Journal of Animal Research, Volume 57 Issue 2: 245-248 (February 2023)

Observation of Inherently Contaminated *Oncorhynchus mykiss* Walbaum, 1792 by *Aeromonas veronii* with MALDİ-TOF and Culture Methods and Specification of Antibiotic Sensitivity Profiles of Agent in a Commercial Farms

Filiz Özcan[1]

10.18805/IJAR.BF-1444

ABSTRACT

Background: The Rainbow trout, *Oncorhynchus mykiss* (Walbaum, 1792) is commercially farmed in the Southeastern Anatolia Region, Turkey. *Aeromonas spp.* is a widely found bacterium of aquatic ecosystems such as freshwater and coastal water. They are increasingly noticed as critical pathogens. The Rainbow trout causes acute death, that is characterized by internal organ hemorrhages, such as the spleen, kidney and liver body surface, ulcerations and congestion.

Methods: This study, investigated a total of 1,200 fish samples from commercial farms in the Southeastern Anatolia region. *Aeromonas veronii* was isolated from the kidney, liver and tissue of fish on the Blood Agar and McConkey Agar for bacteriological examinations. Isolated strains were identified by MALDİ-TOF.

Result: *A. veronii* infection was observed from 0% to 100% in fish farms that cover different regions of the Southeastern Anatolia region. The sensitivity of oxytetracycline, enrofloxacin, florfenicol, neomycin, erythromycin and amoxicillin were defined at chancing ratios.

Key words: *Aeromonas veronii*, MALDİ-TOF, *Oncorhynchus mykiss*, Rainbow trout.

INTRODUCTION

Aquaculture is one of the world's quickest developing food sectors to supply the growing nutritional requirements worldwide. Rainbow trout (*Oncorhynchus mykiss*) is a significant species in aquaculture with its production of approximately 848 million tons in the world of aquaculture in 2018 (FAO, 2020). This species is the most frequently farmed freshwater fish in Turkey and its production was 125 thousand tons in 2019 (TUİK, 2020). Cultured fish are weak to various bacterial diseases that often economically cause high prices for fish farmers (Pasqualetti *et al.,* 2021). Many opportunistic pathogens are present in the aquatic environment of fish farms. *Aeromonas* spp. naturally inhabit the aquatic environment such as freshwater, coastal water and sewage of which many are regarded pathogenic for aquatic animals (Han *et al.,* 2021). These bacteria were previously reported as the causative agent of bacterial hemorrhagic septicemia, motile aeromonad septicemia and epizootic ulcerative syndrome in many marine and freshwater fish species (Liu *et al.,* 2016). *Aeromonas veronii* is a dangerous opportunistic bacterium in terrestrial and aquatic milieus (Chen *et al.,* 2019). Presently, an increasing number of *A. veronii* infections causing epidemic diseases in diverse fish species have been described (Hoai *et al.,* 2019; Raj *et al.,* 2019). This pathogen in aquaculture, can infect a variety of aquatic animals, including freshwater goldfish, Nile tilapia, Chinese Longsnout catfish and catfish (Wang *et al.,* 2021) *A. veronii* is a Gram-negative bacterial pathogen and the clinical manifestation of contaminated fish mostly includes internal organ hemorrhage and skin ulcers (Tekedar *et al.,* 2019). Aeromonas species affect many fish species, thus the interest in understanding the role of the pathogen increases in fish farms (Guzman-Murillo *et al.*, 2000). This study aimed to define the potential pathogen, *A. veronii,* in diseased rainbow trout that may explain the high mortalities observed in the Southeastern Anatolia Region commercial farms. To this end, diseased fish were investigated from fish farms in varied zones of the Southeastern Anatolia Region.

[1]Department of Fisheries and Fisheries Diseases, Faculty of Veterinary, Dicle University, Diyarbakır, Turkey.

Corresponding Author: Filiz Özcan, Department of Fisheries and Fisheries Diseases, Faculty of Veterinary, Dicle University, Diyarbakır, Turkey. Email: felizozcan@gmail.com

How to cite this article: Özcan, F. (2023). Observation of Inherently Contaminated *Oncorhynchus mykiss* Walbaum, 1792 by *Aeromonas veronii* with MALDİ-TOF and Culture Methods and Specification of Antibiotic Sensitivity Profiles of Agent in a Commercial Farms. Indian Journal of Animal Research. 57(2): 245-248. doi: 10.18805/IJAR.BF-1444.

Submitted: 30-09-2021 **Accepted:** 15-03-2022 **Online:** 06-04-2022

MATERIALS AND METHODS

In January 2021, we visited to thirty commercial fish farms of the Southeastern Anatolia Region (Diyarbakır, Batman, Şanlıurfa, Adıyaman). We randomly collected 40 live fish that average live weight of 200-250 g per farm and macroscopically examined them to define the disease

prevalence. External clinical consultations regarded hemorrhage patches, open wounds, detached scales and dark discoloration as disease signs. Therefore the contaminated fish were determined with evident symptoms including hemorrhages below the pectoral fin and anal fin petechial hemorrhages in the skin surface, skin ulceration, intestinal fluid accumulation and liver hemorrhages (Fig 1). The liver and kidney, tissues were used for bacterial isolation. Blood Agar (BA) and McConkey Agar (McA) were employed for bacteria isolation for 24 h at 28°C and the dominant uniform bacterial colonies were purified by streaking three times onto the BA and McA plates (Fig 2). Then, the causative agents according to Gram staining and culture growing profiles were identified with MALDI-TOF mass spectrometry by Maldi Biotyper (Bruker, U.S.A) (Fig 3). Antibiotic susceptibility testing was performed using the Kirby - Bauer Disc Diffusion method, Mueller - Hinton medium and Bauer *et al.,* (1966) and was evaluated according to the procedures reported by the Clinical and Laboratory Standards Institute (CLSI, 2004), Ruangpan and Tendencia (Ruangpan, Tendencia 2004) and Becton Dickinson and Company (BD, 2011).

RESULTS AND DISCUSSION

Rainbow trout inherently contaminated with *A. veronii* mostly display subacute death in fish farm conditions. After 3-4 days of contamination, fish start to swim sluggishly leading to high mortality. Most of the infected fish exhibit big regions of body surface ulceration (Fig 1). After dissecting the fish with intestinal inflammation, internal organ hemorrhages were frequently observed (Fig 1). Additionally, some diseased fish were determined with ischemia, liver and kidney, hemorrhage and spleen darkening (Fig 1). The predominant disease symptoms include skin ulceration, skin surface, hemorrhages the and pelvic fin and anal fin. This study aimed to identify the potential pathogen *Aeromonas veronii* in fish farms of the Southeastern Anatolia Region. We visited commercial fish farms, covering different regions of the Southeastern Anatolia Region and observed *A. veronii* infection from 0% to 100%. Clinical darkening of color, irregular swimming tendency, stagnation, decreased feed consumption, formation of exophthalmos and respiratory distress were observed in rainbow trout taken from the farms. The macroscopic examination, revealed that the most common lesion was petechial hemorrhages and ulcers formed on the skin in different body parts. Other macroscopic findings on the skin include skin darkening increased mucus structure and shedding of scales, erosion and large-scale fluid-filled ulcer formations up to the deep muscle layers. The present study investigated a total of 1,200 samples and detected *A. veronii* in the liver, kidneys, tissues of the fish collected from 28 of the 40 farms. Fish deaths were found in some of the visited farms. Antimicrobial sensitivity testing indicated that the isolated strain *A. veronii* was sensible to enrofloxacine (5 µg) but was resistant to florfenicol, neomycin, amoxicillin, oxytetracycline and erythromycine. Therefore, we could select sensitive antibiotics for disease prevention (Table 1). Infectious epidemic diseases that are caused by aeromonads are one of the very important problems in trout farms that impact the aquaculture sector economy (Austin and Austin, 2012). The characteristic habitats for these bacteria include freshwater. *Aeromonas* spp. are significant pathogens that are considerably found in aquatic environments, causing infection in injured fish or individuals under stress conditions (Janda and Abbott, 2010).

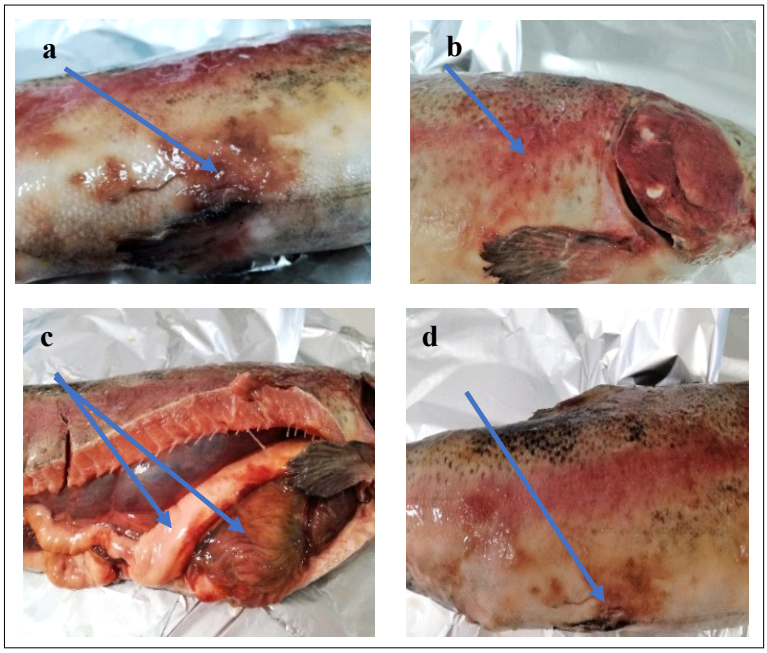

Fig 1: a) Skin ulceration b) hemorrhages in the skin surface c) Intestinal fluid accumulation and liver hemorrhages d) anal fin hemorrhages.

A. hydrophila has been considered the very detrimental pathogens for the enviroment of aquatic animals; however, *A. veronii* has increasingly affected the fishes in the last years (Chen *et al.,* 2019). *A. veronii* is a dangerous pathogen of human beings and aquatic animals and maybe frequently isolated from infected aquatic environments and aquatic animals (Weiss, 2019). *A. veronii* has been verified as a dangerous pathogen of ulcerative disease in loach (Zhu *et al.,* 2016), Nile tilapia (Raj *et al.,* 2019), Gibel carp (Chen *et al.,* 2019), guppy (Lazado and Zilberg, 2018) and catfish (Hoai *et al.*, 2019). Symptoms with fin rot and petechial hemorrhage on body surface were shown in the crucian carp (*Carassius auratus gibelio*) (Chen *et al.,* 2019), goldfish (*Carassius auratus*) (Shameena *et al.,* 2019), guppy (*Poecilia reticulata*) (Lazado and Zilberg, 2018), zebrafish Danio rerio and Nile tilapia (Song *et al.,* 2018), which were also observed in diseased fish in our study (Fig 1). The present study, examined *A. veronii* from various fish farms and was isolated from liver and kidney tissues of fish (Chen *et al.,* 2019; Raj *et al.,* 2019). *A. veronii* has a diversity of hosts and may live in habitat and in aquatic environments and aquatic animals, which might harm the aquaculture in the future (Wu *et al.,* 2019). Most fish species can be contaminated by *A. veronii*, including tilapia, rainbow trout, loach, European sea bass and a variety of catfish. These fish are cultured with variable production quantities in different countries (Han *et al.,* 2021). Thus, that the opportunist pathogen has a chance of host specificity and likely spread, which may induce extreme future problems for aquaculture. Bacterial resistance to antibiotics influences the environment and the health of humans and animals (Hoai *et al.,* 2019). Antibiotic resistant bacteria in aquacultures may be also human opportunistic pathogens and some fish pathogens. Thus, it has a particularly critical threat to public health. Resistant bacteria can be transferred to humans with infected fish or by direct contact with aquaculture ecosystems, *e.g.,* farm fish workers, fish scoops, hand fishing (Laukova *et al.,* 2018). Previous study results revealed that *A. veronii* was resistant to antibacterial drugs, including ampicillin, amoxicillin and oxacillin (Zhixiu *et al.,* 2016). These fast-spreading pathogens can then be transferred to the environment and eventually become contagious to humans (Romero *et al.,* 2012). Previous studies have indicated that *A. veronii* exposes high-level resistance to a diversity of antibiotics including kanamycin, neomycin, tetracycline, sulfamethoxazole, deoxycycline, penbritin, midecamycin, amikacin, tetracycline, azithromycin, tobramycin, cefadine, gentamycin and amoxicillin (Hoai *et al.,* 2019). The current study verified some of these conclusions and indicated that *A. veronii* species were further resistant to neomycin, amoxicillin, oxytetracycline and erythromycin. *A. veronii* exhibited antimicrobial resistance to six antibiotics; however, the pathogen could be regulated by the implementation of antibiotics such as enrofloxacine and florfenicol. Fishes that are successfully healed should be emphasized owing to the prescribed antibiotic treatment, thus no further mortality was reported in the commercial farm.

Table 1: Antimicrobial susceptibility of *A. veronii.*

Antimicrobial agent	Isolate 1	Isolate 2	Isolate 3
Enrofloxacin (5 µg)	S	S	S
Florfenicol (30 µg)	R	S	S
Neomycin (30 µg)	R	R	S
Amoxicillin (10 µg)	R	S	R
Oxytetracycline (30 µg)	R	S	R
Erythromycin (15 µg)	R	R	S

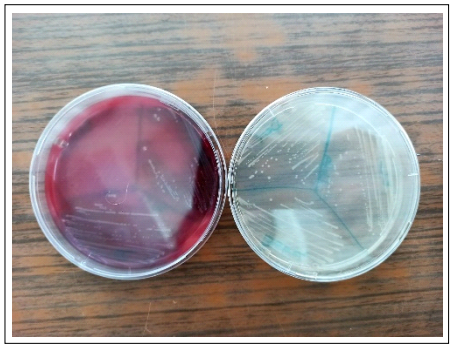

Fig 2: Colony morphology of *A. veronii* cultured on blood and Mcconkey plate at 24 h.

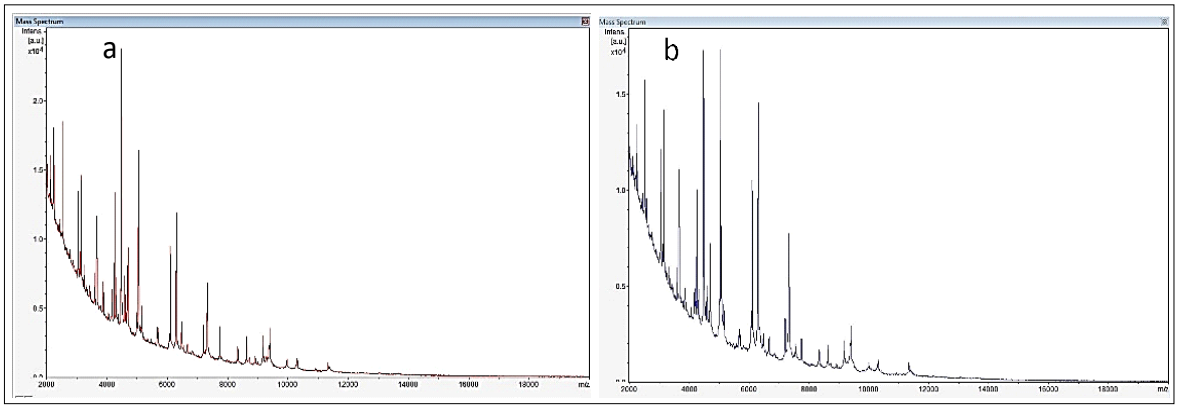

Fig 3: Spectrum images of MALDI-TOF (*A. veronii*).

CONCLUSION

The investigations made in the current study remind us that the occurrence of multiple antimicrobial resistant pathogens and their pathogenicity in fishes and aquaculture environments is unavoidable and timely follow-up coupled with sensible antibiotic use is required for sustainable commercial farming.

Conflict of interest: None.

REFERENCES

Austin, B. and Austin, D.A. (2012). Bacterial Fish Pathogens. Diseases of Farmed and Wild Fish (5th edn), Springer, Netherlands.

Bauer, A.W., Kirby, W.M.M., Sherris, J.C., Turck, M. (1966). Antibiotic susceptibility testing by a standardized single disk method. American Journal of Clinical Pathology. 45: 493-496.

Becton Dickinson and Company B.D. (2011). Antimicrobial Susceptibility Test Discs. 7 Loveton Circle Sparks, USA.

Chen, F., Sun, J.F., Han, Z.R., Yang, X.J., Xian, J.A., Lv, A.J., Hu, X.C., Shi, H.Y. (2019). Isolation, identification and characteristics of *Aeromonas veronii* from diseased crucian carp (*Carassius auratus gibelio*). Front. Microbiol. 10: 2742. DOI: 10.3389/fmicb.2019.02742.

Clinical and Laboratory Standards Institute (CLSI) (2004). Methods for Antimicrobial Disk Susceptibility Testing of Bacteria Isolated from Aquatic Animals; Proposed Guideline. M42-P, CLSI, Wayne, PA.

FAO (2020). The State of World Fisheries and Aquaculture, Food and Agriculture rg.

Guzman-Murillo, M.A., Merino-Contreras, M.L. and Ascem-cio, F. (2000). Interaction between *Aeromonas veronii* and epithelial cells of spotted sand bass (*Paralabrax macualto-fasciatus*) in culture. J. Appl. Microbiol. 88: 897-906.

Han, Z., Sun, J., Jiang , B., Hu , X., Lv , A., Chen , L., Guo, Y. (2021). Concurrent infections of *Aeromonas veronii* and *Vibrio cholerae* in koi carp (*Cyprinus carpio* var. koi). Aquaculture. 535: 736395. DOI: 10.1016/j.aquaculture. 2021.736395.

Hoai, T.D., Trang, T.T., Van Tuyen, N., Giang, N.T.H., Van, K. (2019). *Aeromonas veronii* caused disease and mortality in channel catfish in Vietnam. Aquaculture. 513: 734425. DOI: 10.1016/j.aquaculture.2019.734425.

Janda, J.M. and Abbott, S.L. (2010). The genus Aeromonas: Taxonomy, pathogenicity and infection. Clin. Microbiol. Rev. 23: 35-73.

Lauková, A., Kubašová, I., Kandrièáková, A., Strompfová, V.,Rudolf Žitòan, R., Simonová, M.P (2018). Relation to enterocins of variable Aeromonas species isolated from trouts of Slovakian aquatic sources and detected by MALDI-TOF mass spectrometry. Folia Microbiologica. 63: 749-755. DOI: 10.1007/s12223-018-0616-1.

Lazado, C.C. and Zilberg, D. (2018). Pathogenic characteristics of *Aeromonas veronii* isolated from the liver of a diseased guppy (*Poecilia reticulata*). Lett. Appl. Microbiol. 67: 476-483. DOI: 10.1111/lam.13057.

Liu, D., Geng, Y., Wang, K.Y., Chen, D.F., Huang, X.L., Ouyang, P., He, C.L., Zhong, Z.J., Lai, W.M., (2016). *Aeromonas veronii* infection in cultured channel catfish, *Ictalurus punctatus*, in Southwest China. Isr. J. Aquacult-bamid. 68: 1225.

Pasqualetti, C., Schmidt, J.G., Cafiso, A., Gammuto, L., Lanzoni, O., Sepulveda, D., Manfrin, A., Cecchi, LB., Olesen, NJ., Bazzocchi, C., Petroni, G. (2021). Double trouble: Could *Ichthyophthirius multifiliis* be a vehicle for the bacterium associated with red mark syndrome in rainbow trout, *Oncorhynchus mykiss*? Aquaculture. 533: 736230 DOI: 10.1016/j.aquaculture.2020.736230.

Raj, N.S., Swaminathan, T.R., Dharmaratnam, D.A., Raja, S.A., Ramraj, D., Lal, K.K. (2019). *Aeromonas veronii* caused bilateral exophthalmia and mass mortality in cultured Nile tilapia, *Oreochromis niloticus* (L.) in India. Aquaculture. 512: 734278. DOI: 10.1016/j.aquaculture.2019.734278.

Romero, J., Feijoó, C.G., Navarrete, P. (2012). Antibiotics in Aquaculture- Use, Abuse and Aalternatives. In: Health and Environment in Aquaculture. [Carvalho, E.D., David, J.S., Silva, R.J. (Eds.)], InTech Press, Rijeka, Croatia, pp. 159-198. (ISBN 978- 953-51-0497-1).

Ruangpan, L. and Tendencia, AE. (2004). Laboratory Manual of Standardized Methods for Antimicrobial Sensitivity Tests for Bacteria Isolated from Aquatic Animals and Environment. Aquaculture. Extension Manual No 37. Southeast Asian Fisheries Development Center, Tigbauan. 5021, Iloilo, Philippines.

Shameena, S.S., Kumar, K., Kumar, S., Kumar, S., Rathore, G. (2019). Virulence characteristics of *Aeromonas veronii* biovars isolated from infected freshwater goldfish (*Carassius auratus*). Aquaculture. 518: 734819. DOI: 10.1016/j. aquaculture. 2019.734819.

Song, M., Zhang, D., Zhang, H., Long, C., YuanHuan, K., Lei, Z. (2018). Research advances of virulence factors in *Aeromonas veronii*. Chin. Vet. Sci. 48: 1038-42. DOI: 10.16656/ j.issn.1673-4696.2018.0152.

Tekedar, H.C., Kumru, S., Blom, J., Perkins, A.D., Griffin, M.J., Abdelhamed, H. (2019). Comparative genomics of *Aeromonas veronii*: Identification of a pathotype impacting aquaculture globally. PLoS ONE. 14: e0221018. DOI:/10.1371/journal. pone.0221018.

TUİK (2020). Turkiye İstatistik Kurumu.

Wang, B., Mao, C., Feng, J., Li, Y., Hu, J., Jiang, B., Gu. Q., Su, Y. (2021). A first report of *Aeromonas veronii* infection of the sea bass, *Lateolabrax maculatus* in China. Front. Vet. Sci. 7: 1-12 DOI:/10.3389/fvets.2020.600587.

Weiss, G., Kovalerchick, D., Lieman-Hurwitz, J., Murik, O., De Philippis, R., Carmeli, S. (2019). Increased algicidal activity of *Aeromonas veronii* in response to *Microcystis aeruginosa*: Interspecies crosstalk and secondary metabolites synergism. Environ. Microbiol. 21: 1140-50. DOI: 10.1111/1462-2920.14561.

Wu, J., Su, Y., Deng, Y., Guo, Z., Mao, C., Liu, G. (2019). Prevalence and distribution of antibiotic resistance in marine fish farming areas in Hainan, China. Sci Total Environ. 653: 605-611. DOI: 10.1016/j.scitotenv.2018.10.251.

Zhixiu, Z., Xinhua, J., Shunzhou, D., Bei, W., Huihong, L. (2016). Isolation, identification and *in vitro* antimicrobial susceptibility of pathogenic *Aeromonas veronii* from soft-shelled turtles. Agric. Sci. Technol. 17: 804-809. DOI:10.16175/j.cnki. 1009-4229.2016.04.009.

Zhu, M., Wang, X., Li, J., Li, G., Liu, Z., Mo, Z. (2016). Identification and virulence properties of *Aeromonas veronii* bv. sobria isolates causing an ulcerative syndrome of loach *Misgurnus anguillicaudatus*. J. Fish Dis. 39 : 777-781. DOI:10.1111/jfd.12413.