RESEARCH ARTICLE Indian Journal of Animal Research, Volume 57 Issue 2: 207-210 (February 2023)

Effects of Green Oaks Acorns (*Quercus ilex*) based Diets Added of Calcium Bentonite on Health of Broilers Reared in the Cages and Ground Modes

Berkane Fethia[1], Bouderoua Kaddour[1], Ait-Saada Djamel[1], Selselet-Attou Ghalem[1] 10.18805/IJAR.BF-1487

ABSTRACT

Background: The use of natural resources and food additives rich in bioactive nutrients in poultry diets offer better digestive use and have a proven health impact. In this context, the use of green oak acorn added of calcium bentonite are better suited to to improve growth and enrich the meat with a some its nutrients limit the meat lipoperoxidation. In addition, the breeding battery mode compared to the ground mode offers better conditions and enhance productivity. This study evaluated the effects of diets based on green oak acorns supplemented with calcium bentonite on organ histology of broilers to ascertain the impact on the poultry health.

Methods: 300 broilers one day-old of the ISA F15 strain were divided into two groups, one raised on the ground and the other in cages. Each group was divided into three subgroups. Each subgroup receives either a standard diet without addition of acorn or bentonite constituting the diet control (DC).

Result: Analysis of the histological sections revealed that the addition of bentonite in the feed of poultry reared, particularly on the ground seems to preserve at the best histological level of certain internal organs; Fabricius bursa, liver, small intestines. Adding bentonite to the acorn diet nearly halved the intensity of follicular necrosis compared to the lesion appearance of controls. Follicular scarring expressed by the extent of fibrosis was extensive on the bursae. This study concluded that the use of green oak acorn in chicken feed along with 2% calcium bentonite shows the best beneficial effects on health status.

Key words: Battery, Bentonite, Broiler, Histology, Oak acorn, Organs, Soil.

INTRODUCTION

In modern diets, meat is the subject of debate and criticism in a society increasingly attentive to the dietary composition and health value of its diet. Product quality has therefore become one of the major concerns of the various links in the meat industry and the consumer. Among the factors likely to alter or improve this quality is often mentioned diet, even if other parameters have a much greater influence such as genotype and age (Berri and Jehl 2001).

In this context, several research carried out by Algerian researchers have shown the possibility of using the green oak acorn (GOA) (naturally rich in unsaturated fatty acids and bioactive compound) in the diet of broilers, without any alterations in the growth performance and body composition. Interesting results have been obtained by Bouderoua *et al*. (2003; 2009) on the productive performances and nutritional and dietetic qualities of white meats which are characterized by an acceptable slaughter yield. The breeding of broilers is practiced all over the world, in very variable conditions which can be done in three ways; 1) in battery, 2) on the ground and 3) Hybrid (ground and battery). The ground-based method of rearing is often observed in extensive village ranching and also in free-range ranching. In both of these cases, the ground is made up of greenery or dirt. In the industrial confined type, floor rearing is more used for fattening chicks intended for meat production, but also sometimes for laying eggs.

The battery breeding is oldest method and has the following advantages; Removal of the litter that can reduces the transfer of infectious agents, more favorable health status; because the droppings rejected through the wire mesh can reduce the risk of parasitism and infectious diseasesand, better growth because restricted locomotion helps in save energy and divert for accretion of meat.

For better control of breeding conditions, enhancing the feed quality using the few raw materials available locally is important. For example, bentonite is one of these raw materials, known for its richness in minerals and capable of being used in animal feed for binding the toxins.

The consumption of clay has been used for hundreds of years by animals and native cultures to promote internal healing and improved economic indicators and the use of marketing silicate minerals are recommended as an ingredient in the forage (Safaei *et al*., 2014). It is used as a

[1]Department of Agronomy, Higher School of Agronomy, University of Agronomy, Kharouba. Mostaganem, Algeria.

Corresponding Author: Berkane Fethia, Department of Agronomy, Higher School of Agronomy, University of Agronomy, Kharouba. Mostaganem, Algeria. Email: berkanefathia@gmail.com

How to cite this article: Fethia, B., Kaddour, B., Djamel, A.S. and Ghalem, S.A. (2023). Effects of Green Oaks Acorns (*Quercus ilex*) based Diets Added of Calcium Bentonite on Health of Broilers Reared in the Cages and Ground Modes. Indian Journal of Animal Research. 57(2): 207-210. doi: 10.18805/IJAR.BF-1487.

Submitted: 31-12-2021 **Accepted:** 25-04-2022 **Online:** 23-05-2022

feed additive in poultry feed and has no harmful effects on animal health (Prvulovic *et al*., 2008; Safaeikatouli *et al*., 2010).

Bentonite or montmorillonite is a clay belonging to the smectic family. Clays are differentiated by their absorbent and adsorbent properties. Absorption refers to the ability to mop up or even pump liquids. Adsorption refers to the ability to exchange particles, for example minerals against toxins (Bouderoua *et al*., 2016).

This is study, aims to monitor the effects of adding acorn and bentonite in the diet on the histopathological state of organs in broiler chickens reared under soil and battery modes.

MATERIALS AND METHODS

Three hundred day-old male Hubbard ISA 15 broilers were reared conventionally and fed until 12 days of age on a standard starter diet (3,100 kcal/kg, 22% protein) were allowed free access to water and food. The 12th day, birds with initial body weight (BW) 360 kg±23 g were divided into six groups, first group reared on the ground and fed without supplementation of acorn or bentonite. Apart from the similar rearing and diet in CG, the second groups was supplemented with acron (OAGS) and the third group was supplemented acorns (19. 8 g/kg) plus calcium bentonite (2 g/kg) (OAGBS). The fourth group was similar like CG but battery-matured (TB) whereas the fifth and sixth group were also battery-matured chicks but supplemented acron alone (GB) or, acron plus bentonite (GBB). The room temperature in experimental house was maintained at 38°C during the first days of experiment and decreased gradually by 3°C in the 2nd and 3rd week to be fixed at 22°C there'after. Chiks on 3rd and 30th day of age were vaccinated against New Castle disease *via* drinking water. Animals used in this experiment were reared and slaughtered in compliance with ethics regulations for the humane care and use of animals in research.

In order to assess the state of health of the chickens, histological sections were made on the Fabricius bursa, liver and small intestines after fixation. The sections made are observed under a light microscope (Luna, 1968).

RESULTS AND DISCUSSION

Histological sections of Fabricius bursa, liver and small intestines of chickens are shown in Fig 1 and Table 1.

Fabricius scholarships

Depending on the stage of the disease; lesions of hyperplasia, follicular atrophy and fibrosis were observed in control and experimental broilers. Follicular necrosis was especially dominant during the second sacrifice of broilers. During the experiment, the latter was also more intense in ground farming. Based on the diet and compared to the control lots, lymphoid follicle necrosis was moderate in the OAGS and GB group. Adding bentonite to the acorn diet nearly halved the intensity of follicular necrosis compared to the lesion appearance of CG or TB. The follicular scarring expressed by the extent of fibrosis was extensive on the

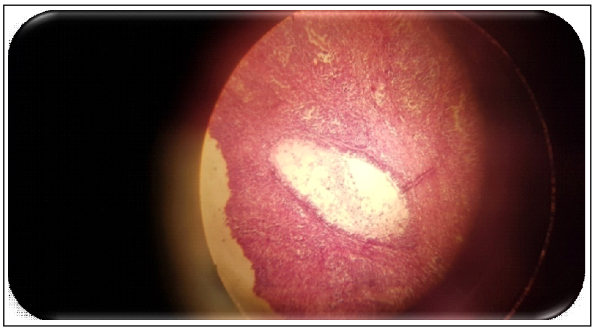

Fig 1: Follicular necrosis with presence of neutrophils (soil control TS: 2nd slaughter, 49 days).

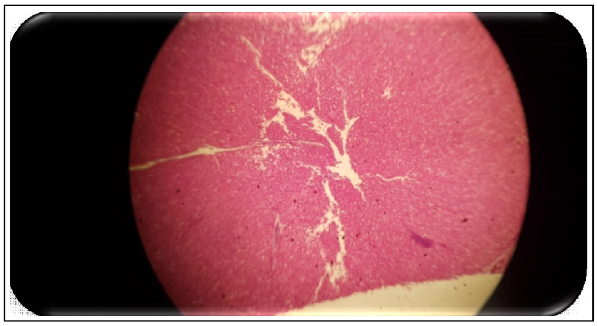

Fig 2: Slight fibrosis (acorn+bentonite battery GBB: 2nd slaughter, 49 days).

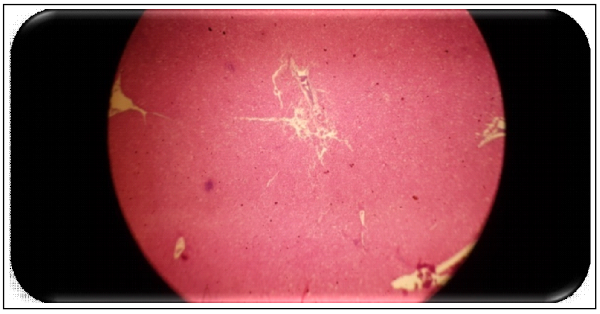

Fig 3: Moderate necrosis of lymphoid follicles (GB battery gland: 2nd slaughter, 49 days).



Fig 4: Heterogeneous perivascular hepatic infiltrates (Gland Battery GB: 1st slaughter).

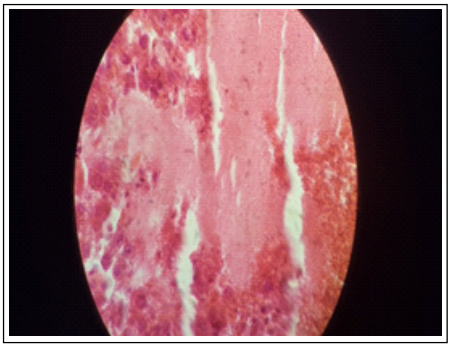

Fig 5: Lysis and degeneration of hepatocytes (gland + bentonite battery GBB: 1st slaughter).



Fig 6: Enteritis with slight infiltration of neutrophils in the crypts (TB battery witness: 2nd slaughter).

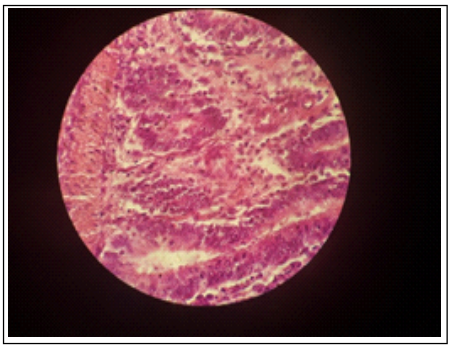

Fig 7: Enteritis with strong neutrophil infiltration in the crypts (gland soil GS: 2nd slaughter).

bursae from the second sacrifice. Throughout the experiment and depending on the type of breeding, fibrosis was slightly more widespread on the purses from cage breeding. On the other hand, the diet based on acorn and bentonite (OAGBS and GBB) showed extensive follicular healing compared to the controls and the groups fed with the acorn (Fig 2 and 3).

Livers

Neither control diet nor accron or benotnite supplemented diets failed to prevent the development of microscopic hepatic lesions (Fig 4 and 5) which included the presence of heterogeneous perivascular infiltrates, cytogresomes, megalocytosis, hepatic steatosis, hepatitis, lysis and degeneration of hepatocytes. Depending on the type of farm, the lesions of steatosis and megalocytosis were more evident in cage culture. In contrast, the presence of cytogresomes in the cytoplasm of hepatocytes was more intense in the soil culture. Lysis and degeneration lesions were often observed on lots reared in soil compared to those in cages.

Small intestines

The majority of transverse intestinal sections exhibited tissue changes at different grades of inflammatory activity. In fact, the severity of the enteritis lesions ranged from mild, localized in the lamina propria, then from the strong infiltration of neutrophils in the crypts until diffuse ulceration with the presence of granulation tissue at the level of the cell. epithelium of the intestinal mucosa.

According to the type of breeding, in general, the enteritis lesions showed in the submucosa and the mucosa infiltration of the crypts by neutrophils and local epithelial erosions more or less important in the lots raised on soil compared to those on cages. Depending on the diet, the CG and TB exhibited less inflammatory activity compared to the other groups. On the other hand, the group fed with acorns (OAGS and GB) showed a more marked transmural inflammationthan that of the CG or TB where it was less intense compared to the batch fed with acorn and bentonite (Fig 6 and 7).

The autopsy did not reveal any obvious macroscopic lesions on the different organs taken from the different groups of experimental animals, with the exception of those observed on the bursa of Fabricius which showed swelling associated with congestion and atrophy accompanied by grayish color. The involvement of these bursaries was accompanied by mild perihepatitis, congestion and intestinal petechiae, more marked in chickens fed the control and the acorn-based diet and less pronounced in the animals that consumed the diet supplemented with bentonite.Based on the diet consumed and compared to the control batch, histology revealed necrosis of the lymphoid follicles of the Fabricius bursa more moderate with the acornbased diet. Adding bentonite to the acorn di*et al*most halved the intensity of follicular necrosis compared to the lesion appearance of control animals. In addition, depending on the diet consumed, hepatic infiltrates were much less in the acorn and bentonite diet, which even reduced the occurrence of hepatocyte lysis and degeneration compared to other experimental diets. Intestinal microscopy also revealed that the control batch exhibited less transmural inflammatory activity in comparison especially with the batch fed with acorns and bentonite.

De Vries *et al*. (2006) reported that the laying hen reared in the open air consumed soil nearly 10% of the dry matter ingested.

Table 1: Microscopic characteristics of gumboro disease.

Group	1st Slaughter 42nd day		Number of hearth Necrotic	2nd Slaughter 56th day		Number of hearth Necrotic
	Grade			Grade		
	Necrosis	Fibrosis		Necrosis	Fibrosis	
CS	Moderate	Lighter than moderate	10	Moderate	Moderate to large	19
OAS	Light to wide	Lighter than wide	04	Large	More moderate than wide	08
OABS	Lighter than Moderate	Lighter than moderate	06	More moderate than wide	Moderate	15
CB	Light to wide	Mild than moderate	03	Moderate	Moderate	06
OAB	Large	Moderate than wide	06	Moderate to large	Moderate	12
OABB	Large	Moderate	04	Moderate	Large	03

Adding bentonite to broilers' feed strengthens the animal's immunity more and significantly reduces:

- The intensity of follicular necrosis of the bursa of Fabricius.
- Hepatic infiltrates, lysis and hepatocyte degeneration.
- Intestinal transmural inflammatory activity.
- The number of peri-arterial sleeves in the spleen.

Throughout the experiment and depending on the type of farming, the fibrosis was slightly more widespread on the purses resulting from cage farming as opposed to farming carried out on the ground. Steatosis and megalocytosis lesions, as well as lysis and degeneration lesions were also more evident in hepatocytes from battery-reared animals. On the other hand, only appearance of cytogresomes in the cytoplasm of hepatic cells was noted in the culture carried out in the soil.

At the intestinal level, enteritis lesions in the submucosa and mucosa, infiltration of the crypts by neutrophils and more or less significant local epithelial erosions were observed in the birds of the batches raised on the ground than those raised in cages.

These responses are undoubtedly due to a difference in the breeding density of which the cage breeding was carried out more suffering by the animals because of the high density of 20 subjects per square meter compared to the ground breeding. having been established according to the required standard of 10 subjects per square meter.

CONCLUSION

In view of the improvement in the health of chicken meat by the supplementation of holm oak accron and bentonite to chick diets was recommended at the dose of 19.8% and 2%. The improvement in the quality and health value of meat could be attributed to their richness in bioactive ingredients. The addition of bentonite to poultry feed remarkably reducedthe intensity of follicular necrosis of Fabricius bursa, hepatic infiltrates, as well as lysis and hepatocyte degeneration, intestinal transmural inflammatory activity in, particularly in broilers. We also conclude that the cage rearing as opposed to floor rearing showed slightly more extensive fibrosis on Fabricius bursa; lesions of steatosis and megalocytosis, as well as lesions of lysis and more marked degeneration.

Conflict of interest: None.

REFERENCES

Berri, C. and Jehl, N. (2001). Facteurs de Variation de la Qualité Technologique et Organoleptique des Viandes de Poulets. In : Quatrième Journée de la Recherche Avicole, Nantes, Frances. Pages 245-252.

Bouderoua, K., Selselet-Attou, G. et Mourot, J., (2003). Body Composition and Meat Sensory Properties of Broilers Fed Green Oak (*Quercus ilex*), Cork Acorn (*Quercus suber* L.) Based Diet. XVIth European Symposium on the Quality of Meat Poultry, Proceeding (2003). 312-317.

Bouderoua, Y., Attou, G.S. (2016). Impacts de l'utilisation de la bentonite calcique dans l'alimentation du poulet de chair sur les performances de croissance, état de santé, conditions générales d'hygiène et prévention contre les mycotoxines. 99-100.

De Vries, M., Kwakkel, R.P., Kijlstra, A. (2006). Dioxins in organic eggs: A review. NJAS. 54: 207. https://doi.org/10.1016/S1573-5214(06)80023-0.

Johns, T. and Duquette, M. (1991). Detoxification and mineral supplementation as functions of geophagy. Am. J. Clin. Nutr. 53(2): 448-456. doi: 10.1093/ajcn/53.2.448.

Luna, L.G. (1968). Manual of Histologic Staining Methods of the Armed Forces Institute of Pathology. McGraw Hill, New York. 258.

Prvulovic, D., Kojic, D., Lajsic, G.G. and Kosarcic, S. (2008). The effects of dietary inclusion of hydrated aluminosilicate on performance and biochemical parameters of broiler chickens. Turk. J. Vet. Anim. Sci. 32: 183-189.

Safaei, M., Boldaji, F., Dastar, B., Hassani, S., Mutalib, M.S.A. and R. Rezaei (2014). Effects of Inclusion Kaolin, Bentonite and Zeolite in Dietary on Chemical Composition of Broiler Chickens Meat. Asian J. of Ani. and Vet. Adv. 9: 56-66.

Safaeikatouli, M., Boldaji, F., Dastar, B. and Hassani, S. (2010). Effect of different levels of kaolin, bentonite and zeolite on broilers performance. J. Biol. Sci. 10: 58-62.