RESEARCH ARTICLE Indian Journal of Animal Research, Volume 58 Issue 5: 785-790 (May 2024)

Anatomical Computed Tomography and Magnetic Resonance Imaging Architecture of the Kidneys in the Chinchilla (*Chinchilla lanigera*)

Emine Karakurum[1], Rosen Dimitrov[2], Kamelia Stamatova-Yovcheva[2], Mehmet Erşen[3], Ömer Gürkan Dilek[1]

10.18805/IJAR.BF-1511

ABSTRACT

Background: Chinchilla is a laboratory animal used in anatomical urinary tract research. Computed tomography (CT) and magnetic resonance imaging (MRI) are tools methods used in the diagnosis and assessment of kidney diseases. The aim of this study is to determine the anatomical architecture of the kidneys in chinchillas by computerized tomography and magnetic resonance imaging.

Methods: A total of 12 chinchillas (6 male and 6 female) aged 18 months. After anesthesia computed tomography and magnetic resonance imaging was performed. CT and MRI were analyzed with a software program. 3D reconstruction of the obtained images was performed.

Result: Computed tomography showed that the right kidney starts at the midline of the 1st lumbar vertebra in the transversal plane and ends at the cranial end of the 4th lumbar vertebra and the left kidney ends at the cranial end of the 3rd lumbar vertebra and the caudal end of the 5th lumbar vertebra. Pelvis renalis had higher X-ray density compared to medulla and cortex renal. The left kidney was bean-shaped and the right kidney was oval-shaped. Anatomical images were obtained on T1 contrast magnetic resonance T2 magnetic resonance images showed the corticomedullar system and the pyelocalyx system better.

Key words: Anatomical architecture, Chinchilla, CT, Kidney, MRI.

INTRODUCTION

Chinchillas are increasingly popular pets; thus they reach geriatric status. Problems encountered in older animals are related to diet, infections and neoplasms (Jenkins 2012). Urolithiasis and purulent nephritis have been described in chinchillas. Obstructive disorders are manifested by irritation around the preputial opening, hematuria, pollakiuria and stranguria (Martel-Arquette and Mans, 2016).

Phylogenetic analysis was performed to determine variation in kidney morphology (size, relative thickness of the medulla, medulla-cortex ratio and relative medullary area) in South American rodents inhabiting arid regions (Diaz *et al.,* 2006; Diaz and Ojeda, 1999). Ultrasonographic study of the anatomical structure of the kidneys in chinchillas includes width, length, area of the organ, the thickness of the cortex and medulla and thickness, width and length of the renal pelvis (Ferrari *et al.,* 2013).

The right and left kidneys are visualized as low-density soft tissue findings that are clearly defined by adjacent soft tissue and bone structures. The imaging anatomical localization of the right kidney was found between the transverse planes through the caudal end of the 13th thoracic vertebra and the caudal end of the 2nd lumbar vertebra and the left - between the transverse planes through the caudal parts of the 2nd and 4th lumbar vertebrae. The renal hilus, in ventrodorsal projection, was located medially and in lateral projection - dorsally. The renal cortex and medulla are defined. The contact between the right kidney and the caudate processes of the liver was visualized as a striped finding with relatively low X-ray density. The renal pelvis is visualized as a cavity finding. Morphometric data prove that the left kidney is longer (craniocaudal size) and wider than the right. Excretory urography is a definitive method for anatomical investigation of the rabbit kidneys (Ferrari *et al.,* 2013).

Steorologically, the average volume and the average weight of the kidney in the chinchilla were studied. The weight of the kidney was 1.74±0.3 g for males and 1.70±0.2 g for females (Başaran *et al.,* 2013). The stereological study of the volume fractions of the kidney is an alternative way to

[1]Department of Anatomy, Faculty of Veterinary Medicine, Burdur Mehmet Akif Ersoy University, 15030 Burdur, Turkey.
[2]Department of Histology and Embryology, Faculty of Veterinary Medicine, Trakia University, 6000 Stara Zagora, Bulgaria.
[3]Department of Radiology, Bucak State Hospital, 15300 Bucak/ Burdur, Turkey.

Corresponding Author: Emine Karakurum, Department of Anatomy, Faculty of Veterinary Medicine, Burdur Mehmet Akif Ersoy University, 15030 Burdur, Turkey.
Email: ekarakurum@mehmetakif.edu.tr

How to cite this article: Karakurum, E., Dimitrov, R., Stamatova-Yovcheva, K., Erşen, M. and Dilek, Ö.G. (2024). Anatomical Computed Tomography and Magnetic Resonance Imaging Architecture of the Kidneys in the Chinchilla (*Chinchilla lanigera*). Indian Journal of Animal Research. 58(5): 785-790. doi: 10.18805/IJAR.BF-1511.

Submitted: 05-03-2022 **Accepted:** 26-05-2022 **Online:** 25-06-2022

assess the renal components, providing data necessary for the diagnosis of renal hypertrophy, atrophy and tumors (Pazvant *et al.,* 2009).

The imaging anatomical research involving the use of CT creates clinically significant 3D reconstructed virtual models that allow the visualization of anatomical structures with clinical significance (Cui *et al.,* 2016). Magnetic resonance imaging (MRI) shows an advantage, through the increased soft-tissue contrast, in the detection and characterization of renal lesions. Multidetector spiral CT is an essential method when examining the renal morphology, but MRI is more definitive, studying the renal function (Nikken and Krestin, 2007).

The cortico-medullary definition in humans is well marked in both types of images- T1 and T2. The renal adipose capsule and the adipose tissue located peripherally to the renal pelvis show a more intense signal than that of the cortex and medulla. The normal renal cortex shows a higher signal intensity than the medulla. The renal parenchyma shows a lower signal intensity than perirenal adipose tissue (Dilek *et al.,* 2019; Dilek *et al.,* 2020; Leung *et al.,* 1984).

The aim of this study is to establish some anatomical computed tomography and magnetic resonance imaging characteristics of the kidneys in chinchillas, with a view to their application in anatomical and diagnostic studies related to these organs.

MATERIALS AND METHODS

Ethical statement

The study protocol was approved by the Animal Ethics Committee for the University of Burdur Mehmet Akif Ersoy (14.10.2021 Date, Number 76892-818).

Materials

We used 12 chinchillas (6 male and 6 female), aged 18 months. The average weight was 0.6±0.051 kg. The chinchillas were housed in stainless steel cages in a controlled environment at temperatures of 20 to 25°C with a 12:12-h light-dark cycle and were fed a standard pellet diet and water *ad libitum*. The chinchillas were healthy and showed no signs of urinary tract diseases.

CT procedure

The radiological images were taken at a private center in Turkey in one month. The animals were in supine recumbency. They were anesthetized intramuscularly with 15 mg/kg Zoletil® 50 (Virbac, Carros-Cedex, France). 16-row multi-slice spiral CT scanner Alexion (Toshiba Medical Systems, Japan). Slice thickness, spacing between slices: 1 mm. Axial coronal sagittal images of the kidney were gained with 2 mg/kg iodinated contrast medium (Iohexol, 320 mg/50 ml). It was administered manually through the jugular vein. CT sections were obtained after a 10-second waiting period.

MRI procedure

Magnetic Resonance Imaging was performed with a 1.5 T Philips Achieva (Best, The Netherlands) MRI system. Axial T2-Weighted images (TR: 3027 ms, TE: 100 ms, slice thickness: 2 mm, spacing between slices: 2.7 mm), Axial and Coronal T1- and T2 - Weighted images (TR: 597 ms, TE: 15 ms, slice thickness: 2 mm, spacing between slices: 2.7 mm).

CT and MRI were analyzed with an FDA-approved software program (Vitrea Vital v6.3.2160, Vital Images, Inc.). 3D reconstruction of the obtained images was performed.

Statistical analysis

Statistical analyses were performed using SPSS software, version 19.0, for Windows. The data are reported as means, standard deviations. Two sample T-test was used to compare right-left kidney diameters, volume and Hounsfield unit.

RESULTS AND DISCUSSION

Computed tomography (CT)

CT localization of the right kidney, in chinchillas, was found (dorsoventral visualization) between the transverse planes passing through the middle of 1st lumbar vertebra (cranial) and the cranial end of the 4th lumbar vertebra (caudal) and the left - between the transverse planes passing through the cranial end of 3rd lumbar vertebra (cranial) and the caudal end of the 5th lumbar vertebra (caudal). The right kidney showed a relative medial and cranial localization compared to the left (Fig 1, Fig 2, Fig 4, Fig 5, Fig 6 and Fig 7).

The length of the right kidney was 2.66±0.28 cm, its width - 1.74±0.18 cm and in the left the length and width were 2.62±0.24 cm and 1.72±0.16 cm, respectively (Table 1 and Fig 2). The differences in diameters were not statistically significant (P<0.05).

In the native CT study, the renal pelvis showed a relatively high X-ray density, compared with the consistent

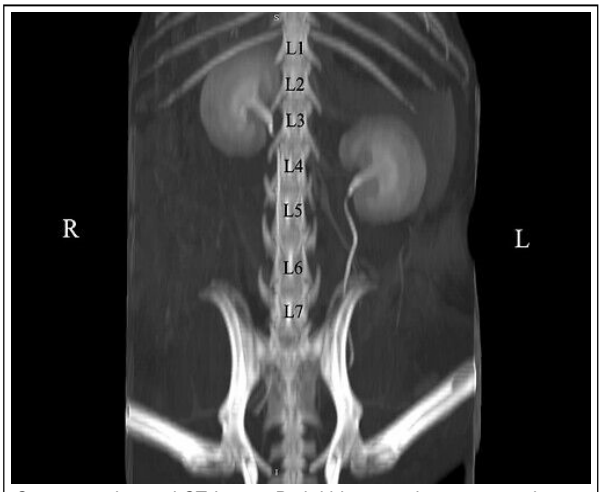

Contrast-enhanced CT Image. Both kidneys and ureters are shown. R- Right, L- Left, L1-L7 - Lumbar vertebrae.

Fig 1: Coronal MIP (Maximum intensity projection).

decrease of the density in the medulla and cortex. The adipose capsule was poorly defined (Fig 1).

Hyperdensity of the renal pelvis and renal medulla was detected by contrast CT imaging. The cortex showed relative hypodensity compared to the renal pelvis and medulla. Perirenal adipose tissue (adipose capsule) was relatively hyperdense to the renal cortex.

Imaging findings, visualizing the multipapillary structure of the kidneys of the chinchilla were observed (Fig 2 and Fig 7).

The volume of the right kidney was larger (3.03±0.31 ml), compared to the same of the left (3.00±0.29 ml) (Table 2). The differences in volume were not statistically significant (P<0.05). X-ray density (Hounsfield Unit - HU) of the right kidney was higher (589.1±175.3 HU) than that of the left-571.9±172.1 HU (Table 2, Fig 3). The differences in HU were not statistically significant (P<0.05).

Anatomical topographic CT contact was found on the right between the cranial pole of the right kidney and the caudal part of the liver and on the left - between the cranial pole of the left kidney and the spleen (Fig 1, Fig 2, Fig 4 and Fig 5).

The hilus of the right kidney had a medial localization and that of the left kidney was dorsomedial and caudal (Fig 4, Fig 5, Fig 6 and Fig 7).

The right kidney reached with its cranial part to the last rib and the left kidney was located completely extrathoracically and caudoventrally to the right (Fig 1, Fig 4 and Fig 6).

The left kidney was visualized as a laterally distanced finding from the spine, compared to the right, showing anatomical proximity to the left soft abdominal wall (Fig 4, Fig 5, Fig 6 and Fig 7).

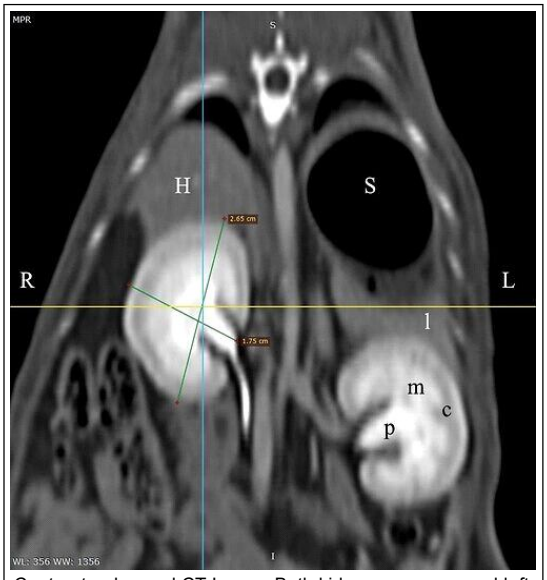

Contrast-enhanced CT Image. Both kidneys are seen and left kidney size is shown. R- Right, L- Left, H- Liver, S- Stomach, L- Lien, c- Cortex, M- Medulla, P- Pelvis renalis.

Fig 2: Coronal MPR (Multi planar reconstruction).

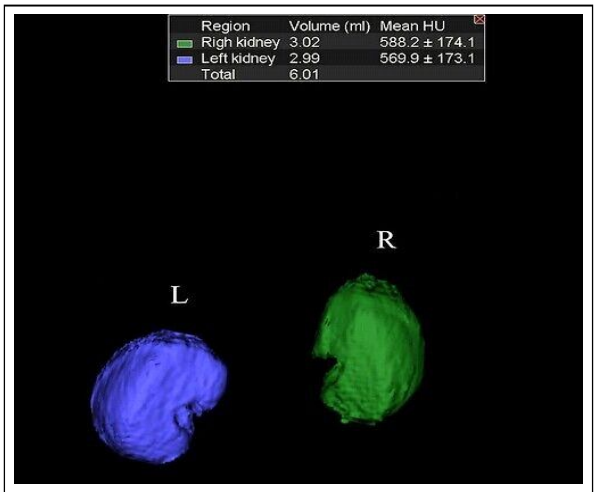

R- Right, L- Left.

Fig 3: Volumetric measurements of both kidneys obtained from CT images are shown.

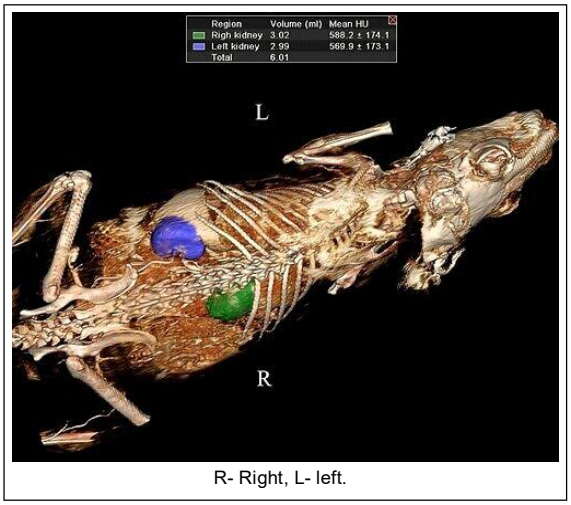

R- Right, L- left.

Fig 4: 3D volumetric images obtained from CT slices and colored images of both kidneys are shown.

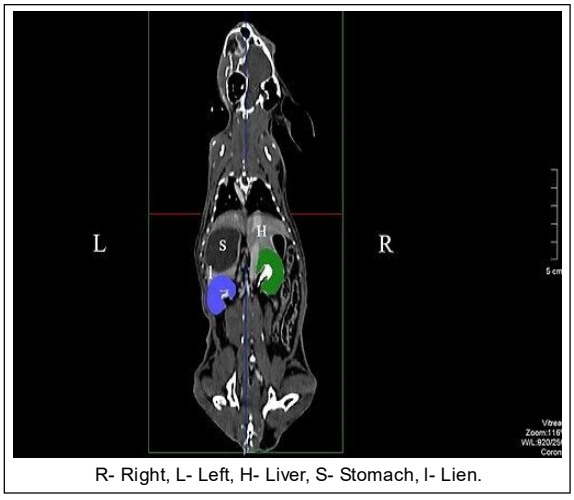

R- Right, L- Left, H- Liver, S- Stomach, l- Lien.

Fig 5: Whole body Coronal MPR Contrast-enhanced CT Image and colored kidneys showed.

The image of the medial edge of the right kidney was covered by the finding of the lumbar spine. The image of the medial edge of the left kidney was complete, well defined and distanced from the bone findings (Fig 4, Fig 5 and Fig 6).

The shape of the left kidney was typically bean-shaped, while the shape of the right kidney was oval. The left renal hilus was more definitively visualized. The cranial and caudal poles of the right kidney were relatively elongated compared to those of the left. The medial edge of the left kidney was relatively concave compared to the medial edge of the right kidney. The lateral edge of the left kidney was relatively convex, compared to the lateral edge of the right kidney and was craniolaterally convex (Fig 1-6).

Magnetic resonance imaging (MRI)

In T1 weighted MRI of the kidneys, in chinchillas, the contrast was anatomical. The renal findings showed a hypointense signal relative to the peripheral soft tissues. The right kidney was visualized as a soft-tissue hyposignal finding. It was in direct contact (without soft-tissue definition) with the is the signal finding of the cranially imaged liver. The left kidney was ventrocaudally imaged and better defined than the right kidney from the adjacent soft tissues. The peripheral contours of the renal parenchyma were well distinguishable. The definition of the individual parts of the kidney, such as the cortex, medulla and pelvis, was visualized. The adipose capsule was visible as a hyper-intensive finding. The right renal finding was relatively hyperintense compared to the left. The renal hilus was well distinguishable. The medial distance of the renal findings was greater and heterosignal on the left and the lateral distance was greater and hyper signal on the right. Soft tissue homosignal contact was observed on the right between the right kidney and the liver. The contact between the left kidney and the spleen was observed as a relatively hyposignal finding on the left and laterally (Fig 8, Fig 9 and Fig 10).

In T2 weighted MRI the contrast was hyposignal in the renal cortex and relatively hyper signal in the medulla.



Colored both kidneys are shown. R- Right, L- Left.

Fig 6: Coronal oblique 3D reformat image.

Table 1: The diameters of chinchilla kidneys.

Region	Length (cm)	Width (cm)
Right kidney (n:12)	2.66±0.28	1.74±0.18
Left kidney (n:12)	2.62±0.24	1.72±0.16
P	0.068	0.073

Values were shown as a mean±standard deviation. P<0.05.

Table 2: Volume and hounsfield init values for kidneys.

Region	Volume (ml)	Mean HU (Hounsfield unit)
Right kidney (n:12)	3.03±0.31	589.1±175.3
Left kidney (n:12)	3.00±0.29	571.9±172.1
P	0.18	0.174

Values were shown as a mean±standard deviation. P<0.05.

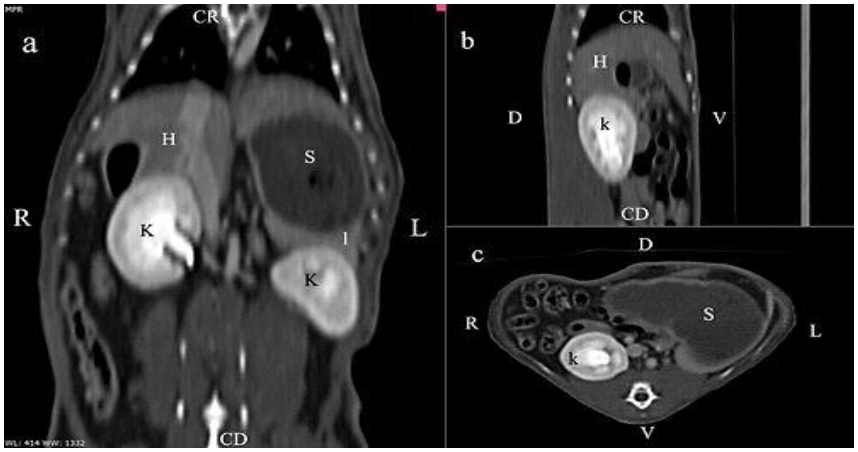

The right kidney and adjacent structures are shown. a: R- Right, L- Left, H- Liver, S- Stomach, I- Lien, K- Kidney; b: D- Dorsal, V- Ventral, CR- Cranial, CD- Caudal, k- Right kidney, S- Stomach; c: R- Right, L- Left, D- Dorsal, V- Ventral, k- Right kidney S- Stomach.

Fig 7: Contrast-enhanced coronal, sagittal and axial Multi planar reconstruction (MPR) images.

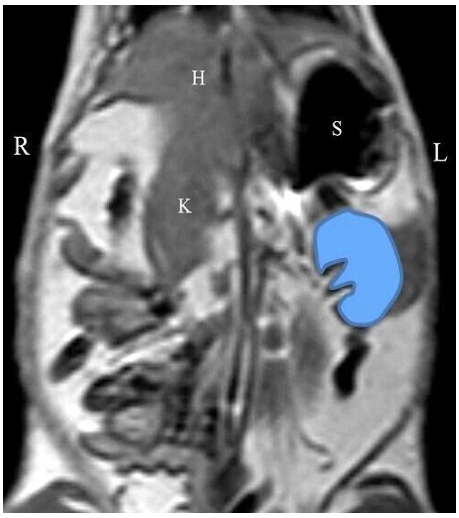

R- Right, L- Left, H- Liver, S- Stomach, K- Right kidney.

Fig 8: Coronal T1 weighted image shows the left kidney in blue color.

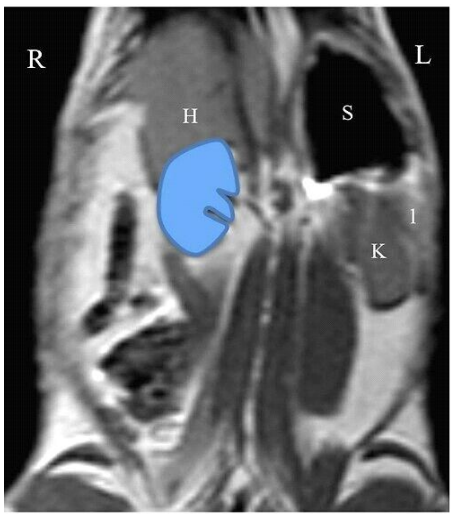

R- Right, L- Left, H- Liver, S- Stomach, K- Left kidney,

Fig 9: Coronal T1 weighted image shows the right kidney in blue color.

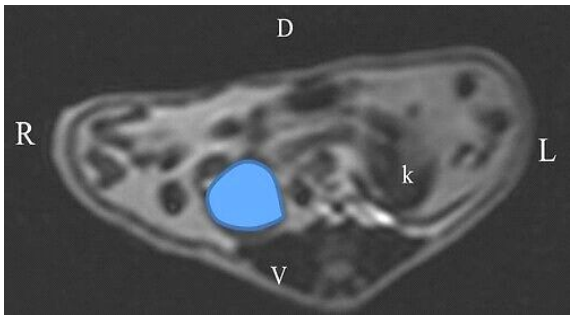

R- Right, L- Left, D- Dorsal, V- Ventral, k- Left kidney.

Fig 10: Axial T2 weighted MRI image shows the right kidney in blue color.

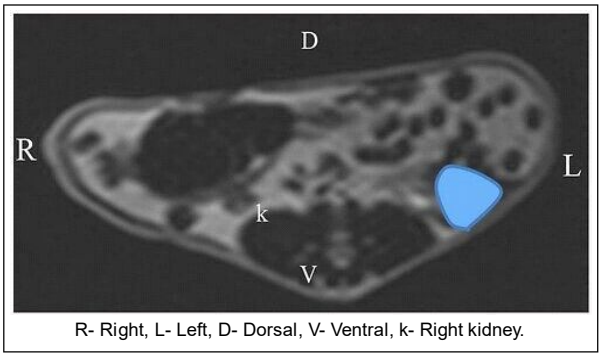

R- Right, L- Left, D- Dorsal, V- Ventral, k- Right kidney.

Fig 11: Axial T2 weighted MRI image shows the left kidney in blue color.

The renal pelvis was visualized as a cavity finding with the relatively most intensive signal from the renal structure. The adipose capsule was relatively hyper intensive compared to the renal parenchyma. The kidneys were distinguished by the peripheral soft tissues. The organs' boundaries demonstrated the typical shape of the kidneys. Contact between the right kidney and lumbar muscles was a clear hyper-signal finding and contact between the left and soft abdominal wall was hyperintense. The renal hilus was poorly defined. The transverse image of the right kidney was approximately oval and that of the left kidney was approximately triangular. Heterosignal findings were observed in the renal parenchyma, which has the characteristics of a multipapillary image of the pyelo-calyx system of the kidney (Fig 10 and Fig 11).

The obtained CT results demonstrate the medullary part of the kidneys in chinchillas as multipapillary and do not correspond to a previous study (Ferrari *et al.,* 2013), presenting its single-papillary structure.

The CT location of the kidneys in chinchillas shows caudal topographic positioning, compared to the topography of the kidneys in the rabbits. Similar to that found in the rabbit, in chinchillas the right kidney is located medially and cranially, compared to the left (Ferrari *et al.,* 2013).

The greater length and width of the right kidney in the chinchilla, compared to the left by CT do not correspond to the opposite found in the rabbit - the left kidney is larger than the right. In addition to its larger size, the right kidney in chinchillas shows a larger volume and higher X-ray density than the left. The resulting CT image of the medial edge of the right kidney, in chinchillas, is closer to the lumbar spine than in rabbits. The CT contact, on the left, between the cranial pole of the left kidney and the spleen, in chinchillas, does not correspond to the radiographically known in the rabbit. The CT imaged oval shape of the right kidney, in chinchillas and bean-shaped of the left kidney, are an essential species trait, in contrast to the rabbit, in which both kidneys are bean-shaped. The CT established close localization of the left kidney with the soft abdominal wall does not correspond to that found in the rabbit (Ferrari *et al.,* 2013).

The CT definition of the kidneys' size in chinchilla is not affected by the condition of the colon, unlike (Jones *et al.,* 2020)

finding the opposite. Compared with the localization of the kidneys in chinchillas was determined about the successive lumbar vertebrae used as bone markers. In our opinion, the use of soft tissue markers (aorta) to perform a morphometric and topographic assessment of the kidneys in chinchillas is a variable indicator that we do not present.

The CT sizes of the kidneys in chinchillas found by us support the stereological data of Başaran *et al.* (2013) presenting the right kidney as larger.

Similar to Cui *et al.* (2016) we obtained 3D reconstructed results that precisely define the topography, shape and cortico-medullary characteristics of the kidneys in chinchillas.

Our results from T1- weighted MRI of the kidneys in chinchillas show that the contrast is anatomical. The hypointense signal of the renal findings corresponds to that found in the human kidney (Nikken and Krestin, 2007). The soft tissue hyposignal finding (in T1-weighed MRI) of the right kidney in chinchillas showed relative cranial localization compared to the left.

The relative hypersignal image of the right kidney in chinchillas is probably due to its extensive contact with the liver. Our MRI investigation of the kidneys in chinchillas allows achieving a good tissue definition of the individual parts of the kidney, such as the cortex, medulla and pelvis.

The resulting hypersignal image of the renal pelvis and medulla (in T2-weighed MRI) better demonstrates the corticomedullary definition and the pyelocalyx system in chinchillas. Therefore, from what is known for the man (Nikken and Krestin, 2007), one can suggest chinchilla kidneys as an affordable and reliable model for MRI anatomical study of the urinary organs.

The magnetic resonance imaging of the kidneys of chinchillas corresponds to the anatomical structure of these organs and supports similar results for the rat (Morehouse *et al.,* 1995). The cortico-medullary MRI definition in chinchillas is better visible in the T2 sequence than in the human- in the T1 sequence (Leung *et al.,* 1984). The advantage of MRI in studying the soft tissue characteristics of the kidneys in chinchillas, based on the increased soft tissue contrast, supports what is known for the man (Nikken and Krestin, 2007).

Compared to Nikken and Krestin (2007), who studied mainly human kidney lesions, the results of our MRI investigation of the kidneys in chinchillas are a precise anatomical basis for assessing the renal status of chinchillas.

CONCLUSION

In conclusion, the results of the present study using post contrast CT, 3D reconstruction and MRI are comprehensive, detailed and with high resolution. We present data for the anatomical relationships of the studied organs, their shape and macrometric parameters. MRI is a relatively highly definitive method for characterizing the kidneys of chinchillas. In the future, clinicians may compare the qualitative quantitative pathological and anatomical alteration results of this study with kidney disease in chinchillas.

Conflict of interest

All authors declare that they have no conflict of interest.

REFERENCES

Başaran, E., Akosman, M.S. and Çevik Demirkan, A. (2013). Volumetric analysis of the total and subcomponents of the chinchilla kidneys. Eurasian Journal of Veterinary Science. 29: 171-175.

Cui, D., Lynch, J.C., Smith, A.D., Timothy, D.V. and Lehman, M.N. (2016). Stereoscopic vascular models of the head and neck: A computed tomography angiography visualization. Anatomical Sciences Education. 9: 179-185.

Diaz, G.B., Ojeda, R.A. and Rezende, E.L. (2006). Renal morphology, phylogenetic history and desert adaptation of South American hystricognath rodents. Funct Ecol. 20: 609-620.

Diaz, G.B. and Ojeda, R.A. (1999). Kidney structure and allometry of Argentine desert rodents. Journal of Arid Environments. 41: 453-461.

Dilek, Ö.G., Dimitrov, R. and Stamatova Yovcheva, K. (2019). The role of imaging anatomy in the contemporary anatomical studies of domestic rabbits in veterinary and agricultural science. Bulgarian Journal of Agricultural Science. 25: 575-580.

Dilek, Ö.G., Erden, H., Turan, E. and Karakurum, E. (2020). The qualitative and quantitative assessment of the renal cortex of the clinically healthy rabbits. Ankara Üniversitesi Veteriner Fakültesi Dergisi. 67: 381-386.

Dimitrov, R.and Chaprazov, T. (2012). An anatomic and contrast enhanced radiographic investigation of the rabbit kidneys, ureters and urinary bladder. Revue de Medecine Veterinaire. 163: 469-474.

Ferrari, M., Silva, W.A.C. and Monteiro, R.V. (2013). Ultrasonographic features of the chinchilla (*Chinchilla lanigera*) kidney. Journal of Exotic Pet Medicine. 22: 393-395.

Jenkins, J.R. (2012). Diseases of geriatric Guinea pigs and chinchillas. Veterinary Clinics of North America: Exotic Animal Practice. 13: 85-93.

Jones, K., Asselt, N.V., Mans, C., Hetzel, S. and Walller III, K.R. (2020). Use of radiographs and computed tomography for measurement of kidney size in healthy chinchillas (*Chinchilla lanigera*). Journal of Exotic Pet Medicine. 35: 106-111.

Leung, A.W.L., Bydder, G.M., Steiner, R.E., Bryant, D.J. and Young, I.R. (1984). Magnetic resonance imaging of the kidneys. American Journal of Roentgenology. 143: 1215-1227.

Martel-Arquette A.and Mans, C. (2016). Urolithiasis in chinchillas: 15 cases (2007 to 2011). Journal of Small Animal Practice. 57: 260-264.

Morehouse, H.T., Levee, E., States, L., Zimmerman, J., Newhouse, J.H. and Amis Jr, E.S. (1995). MRI anatomy of the rat kidney at 1.5 T in different states of hydration. Magnetic Resonance Imaging. 13: 81-88.

Nikken, J.J.and Krestin, G.P. (2007). MRI of the kidney-state of the art. European Radiology. 17: 2780-2793.

Pazvant, G., Sahin, B., Kahvecioglu, O. and Gunes, H. (2009). The volume fraction method for the evaluation of kidney: A stereological study. Ankara Üniversitesi Veteriner Fakültesi Dergisi. 56: 233-239.