RESEARCH ARTICLE Indian Journal of Animal Research, Volume 57 Issue 3: 360-365 (March 2023)

In vitro Adaptation, Molecular Characterization and Tissue Tropism of Foot-and-mouth Disease Virus in Guinea Pigs

Abeera Mubarak[1], Muhammad Yasin Tipu[2], Asim Aslam[2], Tahir Yaqub[3], Muhammad Ali[4] 10.18805/IJAR.BF-1537

ABSTRACT

Background: Foot-and-mouth disease is a highly contagious disease in cloven-footed animals. It is reported to be endemic in Pakistan.

Methods: Molecular characterization of FMD virus field isolate was carried out, followed by an investigation of the tissue tropism in guinea pigs' heart and respiratory organs. After calculating the biological titer of the virus and guinea pigs infectious $dose_{50}$, the virus was injected into the hind metatarsal feet pads of 30 guinea pigs to study the pathogenesis of the disease at different day intervals from day 1 to 28.

Result: Phylogenetic analysis showed that the isolate belonged to ME-SA topotype of serotype "O" with lineage Pan-Asia II. In pathological findings, hemorrhages and congestion in the heart and trachea and edema in the lungs were observed. Histopathological examination showed myocardial necrosis and tracheal epithelium sloughing along with bronchial edema. In Immunohistochemical studies, antigen load was detected in the heart, trachea and lungs up to 14 days post-inoculation. The study suggested that small experimental animals would be a better cost-effective replacement for large animals to study the pathogenesis of the disease as the virus did not change its behavior in these laboratory animals.

Key words: BHK-21 cell line, FMD virus, Guinea pigs, Pathogenesis.

INTRODUCTION

Infectious diseases are the widespread source of production fatalities in livestock-based economies like Pakistan. Foot-and-mouth disease (FMD) is a highly contagious and infectious disease of split-hooved animals with a high morbidity rate in adults and a high mortality rate in young calves. The disease is also reported in some wild animals like giraffes, blackbuck, kudu, impala, deer and elephant (Rout *et al.*, 2017). The disease's acute phase is characterized by vesicles formation on the oral cavity, snout, feet and teats in the affected ones. The aerosol route is considered the choice for virus dissemination in the host but fomites, vehicles and attendants are also the sources of spreading infection. Pharyngeal tonsils, heart and lungs are the virus-spreading sites after that they reach oral and pedal epithelial regions. According to OIE (2012), the incubation period of the disease is 1-14 days.

Being an endemic disease, three serotypes (A, O, Asia-1) of FMD have been reported till now in Pakistan and its neighboring countries like Iran and Afghanistan (Abubakar *et al.*, 2022). Within a serotype, co-circulation of diverse strains of FMDV has been reported. Vaccine selection and tracing of outbreaks can be facilitated by the isolation and characterization of the field virus. Different cell lines like BHK-21, IB-RS-2 and LFBK $\alpha V\beta_6$ are stable and sensitive cell lines to isolate field virus of FMD (Gray *et al.,* 2020). The main hurdle in research progression is the limited budget facilities as the cost of the study is much higher in natural target animals (Habiela *et al.*, 2014). Among experimental laboratory animals, mice and guinea pigs are the choice of researchers to study the pathogenesis of FMD. Guinea pigs are considered the best replacement to study the progression of FMD in large animals. FMDV was adapted in guinea pigs by Arkwright and Burbury (1925) after inoculating the virus in the metatarsal pad. These animals developed generalized lesions including vesicles formation on the lips and feet pads.

In the current study, field isolate of FMDV was isolated on BHK-21 cell line. After molecular characterization, the virus was adapted in guinea pigs to study the tissue tropism of FMDV in heart and respiratory organs, *i.e.*, trachea and lungs, through histopathology and immunohistochemistry. The study findings will highlight the use of laboratory experimental animals to study FMDV pathogenesis so the high cost of using large animals will be curtailed.

[1]Foot and Mouth Disease Research Center, Lahore-54000, Pakistan.
[2]Department of Pathology, University of Veterinary and Animal Science, Lahore-54000, Pakistan.
[3]Institute of Microbiology, University of Veterinary and Animal Science, Lahore-54000, Pakistan.
[4]College of Veterinary Sciences, BZU Bahadur Subcampus Layyah, 31200, Pakistan.

Corresponding Author: Abeera Mubarak, Foot and Mouth Disease Research Center, Lahore-54000, Pakistan.
Email: drabeera1@gmail.com

How to cite this article: Mubarak, A., Tipu, M.Y., Aslam, A., Yaqub, T. and Ali, M. (2023). *In vitro* Adaptation, Molecular Characterization and Tissue Tropism of Foot-and-mouth Disease Virus in Guinea Pigs. Indian Journal of Animal Research. 57(3): 360-365. doi: 10.18805/IJAR.BF-1537.

Submitted: 28-04-2022 **Accepted:** 06-07-2022 **Online:** 16-07-2022

MATERIALS AND METHODS

Research station

FMDV isolate was collected from field outbreaks reported in cattle from October 2021 to April 2022 in high prevalence areas of Lahore, Pakistan. The virus was adapted to baby hamster kidney (BHK-21) cell line using Dulbecco's Modified Eagles Medium (DMEM, Caissons Labs, USA) with 2% fetal calf serum (Caisson Labs, USA). Glasgow Minimum Essential Medium (GMEM, Caissons Labs, USA) with 10% fetal calf serum (Caisson Labs, USA) was used to maintain the cell line. Research was carried out in FMD Research Center, Lahore, Pakistan and Histopathology Laboratory at the Department of Pathology, University of Veterinary and Animal Sciences, Lahore, Pakistan.

RT-PCR and phylogenetic analysis

The extraction of viral RNA from the cell-isolated virus was done using AccuZol™ RNA Extraction Kit Bioneer, Korea. After cDNA synthesis, the sample was subjected to the standard method of RT-PCR (Reid *et al.,* 2014). The VP1 coding region (1D) was amplified using specific primers for Serotype O (Kanwal *et al.,* 2014). VP1 coding sequencing was done according to Sanger dideoxy method and subjected to evolutionary analyses using MEGA X software.

Calculation of tissue culture infectious dose$_{50}$ (TCID$_{50}$)

The virus was titrated in two-fold dilution in 96- well flat-bottom cell culture plates with some modifications and TCID$_{50}$ (Reed and Muench, 1938).

Calculation of guinea pigs infectious dose$_{50}$ (GPID$_{50}$)

Different dilutions of BHK-21 cell line adapted virus *i.e.*, 10^{-2}, 10^{-3}, 10^{-4} were injected intradermally in the right footpad of guinea pigs (n=20) to calculate GPID$_{50}$ (Reed and Muench, 1938).

Experimental design

For this study, two groups of guinea pigs A and B were taken weighing 250-300 gm (n=30). GPID$_{50}$ calculated virus was inoculated intradermally in one hind foot of guinea pigs (group A) and the control animals (group B) were injected with PBS. The lesions development were recorded for 28 days. Necropsy of the dead animals was conducted on 1, 2, 4, 14 and 28 days post-inoculation for organ collection.

The organs *i.e.*, heart, lungs and trachea, were preserved in 10% neutral buffered formalin for histopathology (Suvarna *et al.,* 2019). Mouse and rabbit-specific HRP/DAB (ABC) detection Kit, Abcam®, Austria (ab64264) was used for Immunohistochemical studies (Alsulami *et al*., 2021).

RESULTS AND DISCUSSION

Adaptation of foot-and-mouth disease virus (FMDV) on BHK-21 cell line

After ten continuous passages, the field isolate showed typical cytopathic effects on cell line like cell swelling, rounding and detachment from the surfaces of the culture flasks. These results were in accordance with the findings of Shahiduzzaman *et al.,* (2016), who isolated the field virus on the BHK-21 cell line with the same cytopathic effects observed in the current study (Fig 1a and 1b).

Phylogenetic analysis

The RT-PCR results were found positive by amplifying the product size (639 bp) (Fig 2a). VP1 coding regions were submitted to the GenBank database and the accession number MW601226 was received. The phylogenetic analysis suggested that the under study FMD isolate was classified as lineage O/ME-SA/PanAsia-II (Fig 3). In the world, Pakistan is in pool 3 regarding the division of FMD epidemics with major serotypes reported in different outbreaks are Asia-1, O and A. Among these three serotypes, in the region of Middle-East and Eurasia, the most common lineage identified is O lineage and the sublineage is Pan-Asia II (Bachanek-Bankowska *et al.*, 2019). The active animal's mobility from neighboring countries for example from Southern Asia into Eastern countries (Afghanistan, Pakistan and Iran) has increased the incidence of FMD in Pakistan. FMDV O topotype ME-SA and lineage PanAsia-II is the extensively distributed lineage in Iran, Afghanistan and Pakistan.

Calculation of tissue culture infectious dose$_{50}$ (TCID$_{50}$) biological titer

TCID$_{50}$ was calculated on 96-well micro titration plates which was $10^{6.56}$/ml. The results in this study were in line with the results of Mahmud *et al.,* (2018) who observed $10^{6.5}$/ml titer of FMDV isolated on the BHK-21 cell line (Fig 1c).

Calculation of guinea pigs infectious dose$_{50}$ (GPID$_{50}$)

GPID$_{50}$ of the virus was recorded as $10^{5.3}$/ml. The results are in agreement with the findings of De Vleeschauwer *et al.,* (2016) who used guinea pigs to access antiviral compound activity against FMD.

Clinicopathological findings

After 24 hours of experimental infection, five animals were anorexic with hyperthermia (106°F-107°F). After 2 days post infection (dpi), seven animals showed oral and feet lesions. After 3 dpi, two animals died and eight animals showed oral lesions. After 4 dpi, one guinea pig died of oral and feet lesions (Fig 2b and 2c). After that up to 14 days, three animals died and three animals showed recovery. Up to 28 days, only two animals showed small lesions around the commissure of lips, but no death was recorded. Núnez *et al.,* (2007) adapted the FMD virus in guinea pigs and observed that the virus produced the same lesions in guinea pigs as in large animals. The authors also claimed that the nature of the virus did not change in the experimental hosts.

Grossly, the heart was enlarged with congestion on the 4th dpi (Fig 2d). No lesions in the heart were noticed after 14 dpi (Table 1). The trachea showed congestion after 2 dpi and after four days, the trachea was severely hemorrhagic

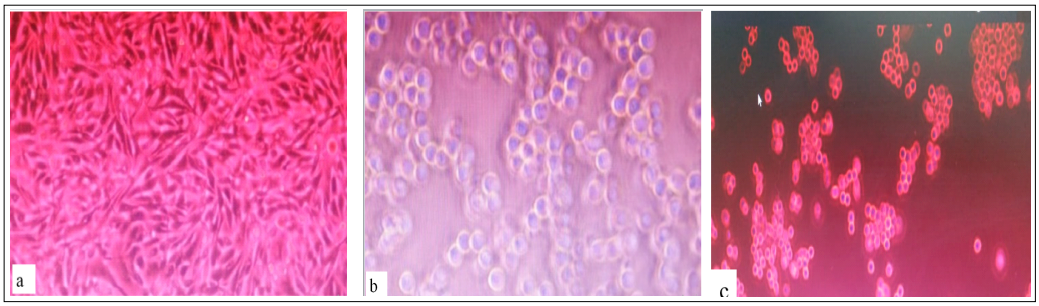

Fig 1: Adaptation of FMDV on BHK-21 cell line. a: Normal BHK-21 Cell line. b: Cytopathic effects of FMDV on BHK-21cell line *i.e.* swelling and rounding of cells. c: Cytopathic effects of FMDV on BHK-21 cell line in microtitration plate.

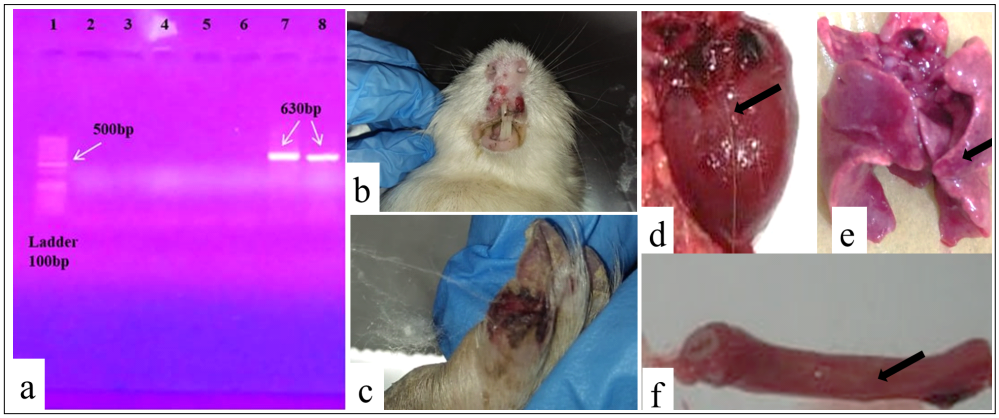

Fig 2: Molecular detection of FMDV and gross lesion examination of different rgansin guinea pig. a: PCR positive bands of FMDV Serotype O. well 1. DNA Ladder 100 bp (GeneDireX). Well 7. Positive sample. Well 8. Control positive. b: Oral lesions. c: Foot lesions. d: Congested heart. e: Edematous lungs. f: Haemorrhages on trachea at 4th day post infection.

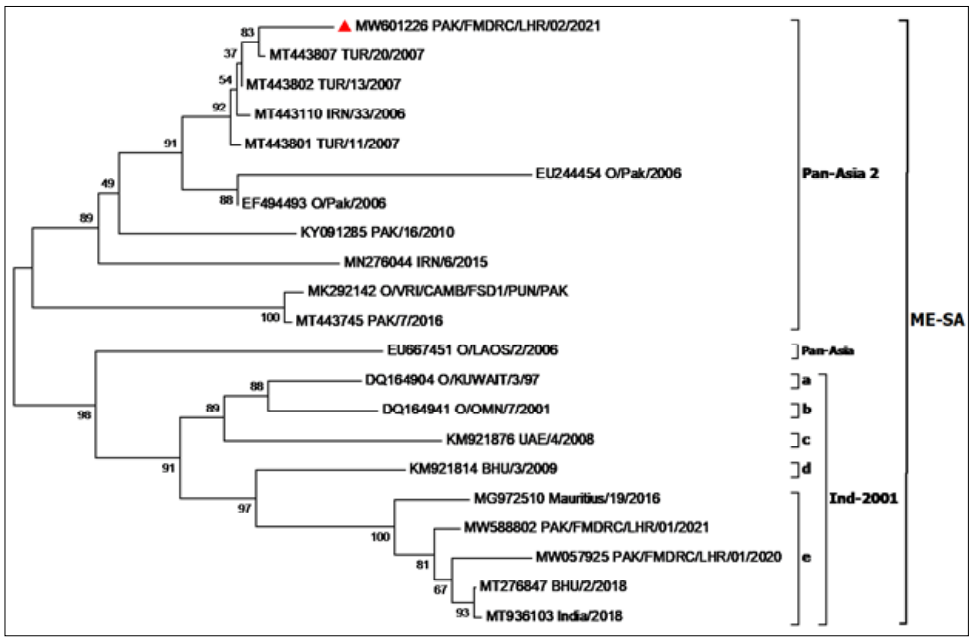

Fig 3: Neighbor-Joining method was used to construct the tree. Red triangle showed the under study isolate. The optimal tree is shown. The Tamura-Nei method was used to compute the evolutionary distance. This analysis involved 22 nucleotide sequences.

(Fig 2f). The trachea also showed no noticeable lesions after 14 dpi (Table 2). On the second day of inoculation, the lungs were congested and hemorrhagic (Fig 2e). On the 3rd dpi, the lungs showed enlargement and edema. The same lesions were observed up to 7th dpi, but up to 14 days, the lungs were only congested and up to 28 days, no lesions were observed after postmortem of the diseased guinea pigs (Table 3). Lung lesions of guinea pigs in this study were in accordance with the results of Brown *et al.,* (1991) but no data was available on the heart and tracheal lesions in guinea pigs. To the best of our knowledge, this is the first study on the pathological lesions of heart and trachea of FMD in guinea pigs. Eight guinea pigs did not show any signs and symptoms. Out of 30 experimental animals, six deaths (20%) were recorded. Knudsen *et al.,* (1979) recorded 5% death in guinea pigs in a research trial. In this current study death percentage was more and would be due to the difference in virus dose rate, age and weight of the animals. Using the ordinal method, lesion scoring was done as 0, 1, 2 and 3 based on the severity of different gross lesions observed (Gibson-Corley *et al.,* 2013) (Table 4). Animals of the control group showed no symptoms.

Histopathological observations

Myocardial inflammation was noted after 48 hours post-infection and after 4 dpi, the heart was severely hemorrhagic, myocardial necrosis was observed up to day 14 and slight congestion was recorded with no remarkable changes up to 28 days (Fig 4a). Severe inflammation was observed after 2 dpi in the lungs. After four days, the lungs of guinea pigs were edematous and interstitial pneumonia was present. Some lung tissues also showed mononuclear cells infiltration after 4 and 14 dpi (Fig 4b). On the 3rd dpi, the trachea showed congestion and on the fourth-day post-challenge, the tracheal epithelium sloughed off and inflammatory cells were present in the muscularis mucosa. The trachea showed histopathological changes up to 14 days after that no considerable change was observed throughout the procedure (Fig 4c). During the study up to 28 days, congestion was observed as a permanent lesion of the affected lungs. The microscopic observations in different vital organs of guinea pigs *i.e.* hemorrhages, inflammation and necrosis of the cardiac muscles, edema and alveolar emphysema of lungs and sloughed up epithelium of trachea, showed that these lesions were similar to those discussed by different researchers in large animals. The myocarditis of the heart in guinea pigs and inflammatory lesions of the lungs up to 14th dpi were in accordance with the studies of the pathogenesis of FMD in cattle and pigs as described by Arzt *et al.,* (2011). The histopathological results in this study were compared with large animal lesions because no relevant data was available about guinea pigs. These microscopic observations also suggested that the virus produced the same lesions in guinea pigs as in natural hosts.

Table 1: Gross lesion scoring in heart of guinea pig based on Table 4.

Organs	Days post infection	Gross lesions scoring			P-value
		Congestion/hemorrhage	Discoloration	Edema	
Heart	1	0	0	1	
	2	1	1	2	
	4	2	2	1	0.003
	14	1	1	1	
	28	0	0	0	

Table 2: Gross lesion scoring in trachea of guinea pig based on Table 4.

Organs	Days post infection	Gross lesions scoring		P-value
		Congestion	Hemorrhage	
Trachea	1	0	0	
	2	1	2	0.002
	4	2	2	
	14	1	2	

Table 3: Gross lesion scoring in lungs of guinea pig based on Table 4.

Organs	Days post infection	Gross lesions scoring			P-value
		Congestion/hemorrhage	Discoloration	Edema	
Lungs	1	1	1	0	
	2	2	2	1	
	4	3	2	2	0.003
	14	2	1	1	
	28	1	1	0	

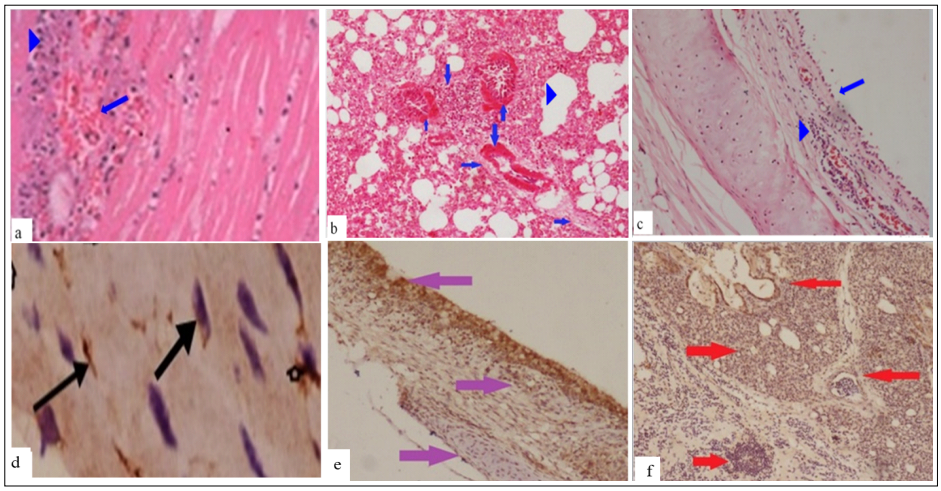

Fig 4: a: Longitudinal section of heart. Congestion (arrow) and infiltration of inflammatory cells (arrow head) myocarditis at 4th day post infection (dpi). b: Longitudinal section of trachea showed deciliated epithelium (arrow) and polymorphs infiltration (arrow head) in mucosa and lamina propria after 4 dpi. c: Longitudinal section of lung showed edema, interstitial pneumonia (arrow) and alveolar emphysema (arrow head) at 4 dpi (H&E stain, 10x10X). d: FMD virus load in myocardial tissues of guinea pig. e: Virus detection in deciliated epithelium and muscularis mucosa of trachea. f: Antigen presence in bronchiolar and alveolar epithelium and bronchiolar lumen along with infiltration of inflammatory cells in lungs of guinea pigs (IHC, 10x10X).

Table 4: Lesion scoring.

0	No change or <25%
1	26-50%
2	51-75%
3	76-100%

Immunohistochemical observations

After 2-3 dpi, antigen (virus) presence was observed in the trachea and heart. Antigen was present in the tracheal epithelium, mucosa and submucosa of trachea (Fig 4e) and cardiac muscles (Fig 4d) for up to 14 days. The antigen spread was rapid in the lungs after 2 dpi. On 4th dpi, the antigen load was observed in the bronchial and alveolar epithelium of lungs (Fig 4f). The antigen load was observed up to the 14th days in the lungs, but up to the 28th days, no viral antigen was observed in the lungs. Alexandersen *et al.* (2005) could not detect the antigen in the vital organs except epithelium of tongue and buccal mucosa of cattle but Arzt *et al.* (2011) found virus load in alveolar lumen and septal walls of lungs in cattle. Immunohistopathological studies in guinea pigs have not been studied in the past and to the best of our knowledge this is the first study to target FMD antigen in different organs of guinea pigs.

Statistical analysis

Mann-Whitney test was applied to lesion scoring using Minitab 17 Software. The results were satisfactory, with a P-value of less than 0.05 with a 95% confidence interval.

Ethical statement

The guidelines provided by the ORIC division, University of Veterinary and Animal Sciences, Lahore were followed and permission was granted vide# 54 dated 10-01-2020 for the ethical handling of animals to conduct this study.

CONCLUSION

Pan-Asia II is the most commonly reported lineage in Pakistan and its neighboring countries. The current data showed that the guinea pigs were cost-effective experimental animals to study foot-and-mouth disease pathogenesis. These animals could replace the natural target animals for further investigations of vaccine efficacy testing, serum neutralization assays and studies of anti-FMD serum preparation. The project's statistics will be further used to study the immuohistopathology of other vital organs of guinea pigs and hormonal changes in pregnant animals. Being a transboundary, economically important and endemic disease, seroprevalence, isolation and molecular characterization of FMDV field isolates are effective tools for reduction and control of the disease.

ACKNOWLEDGEMENT

Authors acknowledge the cooperation of Additional Director Foot and Mouth Disease Research Center, Lahore, Pakistan and Department of Pathology, UVAS, Lahore, Pakistan to provide laboratory facilities.

Conflict of interest: None.

REFERENCES

Abubakar, M., Syed, Z., Manzoor, S., Arshed, M.J. (2022). Deciphering molecular dynamics of foot and mouth disease virus (FMDV): A looming threat to Pakistan's dairy industry. Dairy. 3: 123-136.

Alexandersen, S. and Mowat, N. (2005). Foot-and-mouth disease: Host range and pathogenesis. Current Topics in Microbiology and Immunology. 288: 9-42.

Alsulami, M. and Mohamed, K. (2021). Immunohistochemical changes of liver fasciolosis in cattle and sheep in Jeddah, Saudi Arabia. Indian Journal of Animal Research. 55: 1484-1490.

Arkwright, J.A. and Burbury, M. (1925). Observations on Foot-and-Mouth Disease. Section I.-Transmission of Foot-and-Mouth Disease to Rodents. Journal of Comparative Pathology and Therapeutics. 38: 229-55.

Arzt, J., Juleff, N., Zhang, Z., Rodriguez, L.L. (2011). The pathogenesis of foot and mouth disease I: Viral pathways in cattle. Transboundary and Emerging Diseases. 58: 291-304.

Bachanek-Bankowska, K., Wadsworth, J., Henry, E., Ludi, A.B., Bin-Tarif, A., Statham, B., King, D.P., Afzal, M., Hussain, M., Manzoor, S., Abubakar, M., Knowles, J. (2019). Genome sequences of antigenically distinct serotype O foot-and-mouth disease viruses from Pakistan. Microbiology Resource Announcement. 8: e01397-18.

Brown, C.C., Olander, H.J., Meyer, R.F. (1991). A preliminary study of the pathogenesis of foot-and-mouth disease virus using *in situ* hybridization. Veterinary Pathology. 28: 216-222.

De Vleeschauwer, A.R., Lefebvre, D.J., Willems, T., Paul, G., Billiet, A., Murao, L.E., Neyts, J., Goris, N. and De Clercq, K. (2016). A refined guinea pig model of foot and mouth disease virus infection for assessing the efficacy of antiviral compounds. Transboundary and Emerging Diseases. 63: e205-e212.

Gibson-Corley, K.N., Olivier, A.K., Meyerholz, D.K. (2013). Principles for valid histopathologic scoring in research. Veterinary Pathology. 50: 1007-1015.

Gray, A.R., Wood, B.A., Henry, E., Azhar, M., King, D.P., Mioulet, V. (2020). Evaluation of cell lines for the isolation of foot-and-mouth disease virus and other viruses causing vesicular disease. Frontiers in Veterinary Science. 7: 426. https://doi.org/10.3389/fvets.2020.00426.

Habiela, M., Seago, J., Perez-Martin, E., Waters, R., Windsor, M., Salguero, F.J., Juleff, N. (2014). Laboratory animal models to study foot-and-mouth disease: A review with emphasis on natural and vaccine-induced immunity. The Journal of General Virology. 95: 2329-2345.

Kanwal, S., Saeed, A., Muneer, M., Arshad, M. (2014). Phylogenetics of foot and mouth disease virus in Punjab. British Journal of Virology. 1: 21-28.

Knudsen, R.C., Groocock, C.M. andersen, A.A. (1979). Immunity to foot-and-mouth disease virus in guinea pigs: Clinical and immune responses. Infection and Immunity. 24: 787-792.

Mahmud, M.S., Islam, E., Giasuddin, M., Samad, M.A., Karim, M.R., Ali, M.Z. (2018). Biological assay of foot and mouth disease virus (FMDV) serotypes for titrating BLRI developed trivalent FMD vaccines seed. Immunology and Infectious Diseases. 6: 23-26.

Núnez, J.I., Molina, N., Baranowski, E., Domingo, E., Clark, S., Burman, A., Berryman, S., Jackson, T. and Sobrino, F. (2007). Guinea pig-adapted foot-and-mouth disease virus with altered receptor recognition can productively infect a natural host. Journal of Virology. 81: 8497-8506.

OIE. (2012). FMD. In: Manual of Standard for Diagnostic Test and Vaccine. Ch. 2.1.5. Office International des Epizooties, Paris. 77-92.

Reed, L.J. and Muench, H. (1938). A simple method for estimating fifty percent (50%) ends points. American Journal of Hygiene. 27: 493-497.

Reid, S.M., Mioulet,V., Knowles, N.J., Nazeem, S., Graham, J.B. Donald, P.K. (2014). Development of tailored real time PCR assays for the diagnosis and differentiation of serotype O, A and Asia -1 foot and mouth disease virus lineage circulating in the Middle East. Journal of Virological Methods. 20: 146-153.

Rout, M., Subramaniam, S., Das, B., Mohapatra, J.K., Dash, B.B., Sanyal A., Pattnaik, B. (2017). Foot and mouth disease in wild population of India. Indian Journal of Animal Research. 51: 344-346.

Shahiduzzaman, A.N., Haque, M.E., Rahman, M.H., Khan, M.F. and Rahman, M.B. (2016). Serotyping and adaptation of foot and mouth disease virus in BHK-21 cell line towards the development of vaccine candidate. International Journal of Vaccines and Vaccinology. 3: 60. DOI: 10.15406/ijvv.2016.03.00060.

Suvarna, S.K., Christopher, L., Bancroft, J.D. (2019). In: Bancroft's Theory and Practice of Histological Techniques (8th Edn.), Elsevier, Churchill Livingstone, London, UK. 40-95.