RESEARCH ARTICLE Indian Journal of Animal Research, Volume 57 Issue 10: 1289-1292 (October 2023)

Ultrastructure of Trypanozoon-like Epimastigote in the Midgut of *Cephalopina titillator* (Diptera: Oestridae) 2nd Stage Larvae

Duaa Musleh Eid[1], Nancy T. Mohamed[2], Felwa A. Thagfan[3], Rewaida Abdel-Gaber[4], Mohamed A. Dkhil[2,5], Afaf Abd El Meguid[1]

10.18805/IJAR.BF-1621

ABSTRACT

Background: *Cephalopina titillator* is a common parasite affecting camelids and causing nasopharyngeal myiasis. The fine structure of the epimastigote stage obtained from the midgut of *Cephalopina titillator* 2nd stage larvae was investigated.

Methods: The larvae were obtained from the nasal passage of *Trypanosoma evansi* (*T. evansi*) infected camels.

Result: The main significant organelles of *T. evansi* were reported in the epimastigote. However, the kinetoplast was rarely observed. Also, the activity of the mitochondria was high while the volume of the glycosomes varies oppositely. Thick-walled triangular vacuole was reported near the nucleus of the epimastigote. This vacuole could represent degenerated flagellar pocket of the dying epimastigote. It was concluded that the trypomastigote stage of *T. evansi* reached the midgut of *C. titillator* through the attachment of the larvae to the nasal mucous membrane where it changed into the epimastigote stage which degenerate gradually.

Key words: *Camelus dromedarie, Cephalopina titillator*, *Trypanosoma evansi*.

INTRODUCTION

Following its domesticated host, the Palaearctic species *Cephalopina titillator* has expanded its range into camel-rearing regions of the world (Mehlhorn, 2014; Yao *et al*., 2022). The larvae of *C. titillator*, an obligatory parasite that only affects camelids and is a member of the Oestridae family, causes nasopharyngeal myiasis in camels (Hussein *et al*., 1982; Higgins, 1885). Additionally, they harm animal health, inhibit physiological and immune responses in the host, harm host tissues and result in significant financial losses for the camel breeding industry by lowering fertility and milk and meat production (Otranto, 2001).

The larvae of botfly *C. titillator* are common parasites of the nasal cavity of camels in Egypt and other countries where camels are raised (Fatani and Hilali, 1994). Previous investigation in Egypt showed that the fluid contents of the 3rd larval stages of *C. titillator*; obtained from camels (*Camelus dromedaries*) infected with *Trypanosoma evansi* (*T. evansi*); contained epimastigote stage (Hilali and Fahmy, 1993). The serological and molecular study revealed that this epimastigote reported from 2nd and 3rd stage larvae is strongly related to *T. evansi* infecting camels (Hilali *et al*., 2010).

This investigation aims to describe the fine structure of the epimastigote stage of *T. evansi* infecting *C. titillator* 2nd stage larvae and to compare its morphology with the trypomastigote stage of *T. evansi*.

MATERIALS AND METHODS

Cephalopina titillator larvae 2nd instars were recovered from naturally infected camel heads from the abattoir of Shebeen El Kanater, Qalubia governorate, Egypt. These camels were also infected with *T. evansi* as proved by the microhematocrit centrifugation technique (Murray *et al*., 1977). The heads were cut into sagittal sections and the 2nd stage larvae were retrieved from the turbinates and nasal passages. The larvae were identified according to Zumpt (1965).

For specimen preparation, the alimentary canal was separated from the insect during dissection and divided into anterior, middle and posterior midguts. For Electron microscope preparation the different regions of the midgut were pre-fixed in 2.5% cold buffered glutaraldehyde, (pH 7.2) for 4 hours. Then post fixed in 1% buffered osmium tetroxide for 30 minutes, washed in phosphate buffer (pH 7.2) followed by dehydration in a graded series of alcohol (50%-90%) for 15 min each and 100% for 10 min and pure acetone for 5 min. Infiltration was done in 2:1 acetone Epon

[1]Department of Entomology, Faculty of Science, Cairo University, Egypt.
[2]Department of Zoology and Entomology, Faculty of Science, Helwan University, Cairo, Egypt.
[3]Department of Biology, College of Science, Princess Nourah bint Abdulrahman University, Riyadh, Saudi Arabia.
[4]Department of Zoology, College of Science, King Saud University, P.O. 2455, Riyadh 11451, Saudi Arabia.
[5]Applied Science Research Center, Applied Science Private University, P.O. Box 11931, Amman, Jordan.

Corresponding Author: Rewaida Abdel-Gaber, Department of Zoology, College of Science, King Saud University, P.O. 2455, Riyadh 11451, Saudi Arabia. Email: rabdelgaber.c@ksu.edu.sa

How to cite this article: Eid, D.M., Mohamed, N.T., Thagfan, F.A., Abdel-Gaber, R., Dkhil, M.A. and Meguid, A.A.E. (2023). Ultrastructure of Trypanozoon-like Epimastigote in the Midgut of *Cephalopina titillator* (Diptera: Oestridae) 2nd Stage Larvae. Indian Journal of Animal Research. 57(10): 1289-1292. doi: 10.18805/IJAR.BF-1621.

Submitted: 27-12-2022 **Accepted:** 17-02-2023 **Online:** 28-03-2023

for 2 hr. 1:1 acetone: Epon overnight and embedded in Epon followed by polymerization for 20 hr. at 70°C. Ultrathin sections were stained with uranyl acetate and counter-stained in lead citrate (Reynolds, 1963). The images were captured using a Joel JEM - 1200 ExII Transmission Electron Microscope at the Military Horse Hospital in Cairo, Egypt.

RESULTS AND DISCUSSION

Cameline trypanosomosis (Surra) caused by *Trypanosoma evansi* is considered the most serious disease affecting camels causing morbidity of up to 30% and mortality of around 3% (Enwezor and Sackey, 2005; Diall *et al*., 2022). Hilali *et al*. (2010) showed that the epimastigote stage reported in *titillator* is related serologically and molecularly to *T. evansi*. This study is the first ultrastructural description of the epimastigote stage reported from the larval fluid of 2nd stage larvae obtained from camels infected with *T. evansi*.

The epimastigote stage was found in the middle and posterior midgut of *C. titillator* 2nd stage larvae. They were located close to the microvilli and in the lumen of the midgut (Fig 1). The epimastigote was always observed in a dividing state with the peritrophic membrane of the midgut surrounding these stages (Fig 2). The dimensions of the epimastigote stage varied from 4.5 to 20 µm×1.11 to 2.5 µm (average 8.9×1.9 µm). The dimensions of the epimastigote reported here were shorter than those previously recorded in *C. titillator* larval fluid (Hilali and Fahmy, 1993). This could be due to the use of glutaraldehyde as a fixative in this study and/or the ultrathin sections usually do not give the full length of the organism. The ultrastructure of the epimastigote stage showed that it was elongated fusiform in shape (Fig 3), enclosed in a unit plasma membrane (pellicle) formed of an outer thin and inner thick layer. Beneath this membrane lies a palisade of longitudinally arranged microtubules (Fig 5). The nucleus was enclosed by a double-layer nuclear envelope (Fig 6). It contained an osmiophilic mass at its center, representing the nucleolus and a few peripheral dense masses. The flagellar pocket was in front of the nucleus (Fig 3 and 7).

Some of the flagellar pockets contained coated vesicles (Fig 7). These vesicles were also observed in the cytoplasm of some epimastigotes. A kinetoplast was rarely observed near the flagellar pocket (Fig 8). Dyskinetoplastic forms were found in wild strains of trypanosome because of mutation or after treatment with trypanocides (Hajduk, 1978). Long-term *in vitro* cultivation of *T. evansi* resulted in dyskinetoplastic forms (Zweygarth *et al*., 1990). The flagellum originates from inside the flagellar pocket and extends anteriorly (Fig 7). A paraxial rod was observed within the flagellum (Fig 7). Thin-walled vacuoles and glycosomes were noticed in the cytoplasm while ribosomes were distributed throughout the matrix (Fig 4). Many dark spherical or oval osmophilic bodies were distributed in the cytoplasm (Fig 4). Thick-walled globular or oval-shaped vesicles were distributed in the cytoplasm, particularly at the posterior end (Fig 8). Poorly developed rough and smooth endoplasmic reticulum was observed in the cytoplasm. The Long-ramified mitochondria were present on the lateral sides of the epimastigote (Fig 4). In this study, the volume and activity of the mitochondria were high while the volume of the glycosomes varies the opposite. This agreed with Lopes *et al*., (2010) who reported this finding in the midgut stages of *T. brucei*. The thick-walled triangular vacuole reported here in the cytoplasm near the nucleus

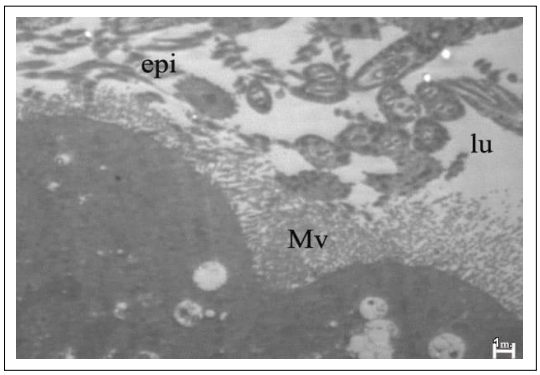

Fig 1: Epimastigote stages (epi) are located close to the microvilli (Mv) and in the lumen (lu) of the midgut. Scale bar in µm.

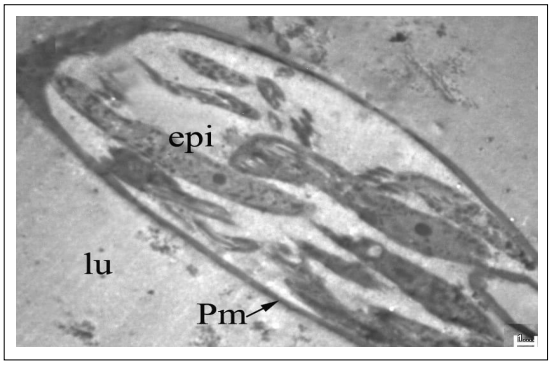

Fig 2: Epimastigote stages in a dividing state and is surrounded by the peritrophic membrane (Pm) of the midgut. Scale bar in µm.

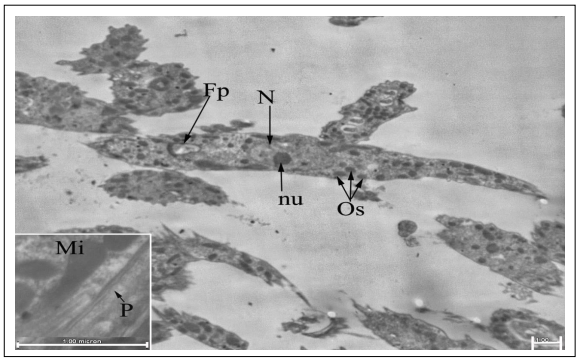

Fig 3: Longitudinal section of the epimastigote, notice pellicle (P), mitochondria (Mi), nucleus (n), nucleolus (nu), osmophilic bodies (Os) and flagellar pocket (Fp). Scale bar in µm.

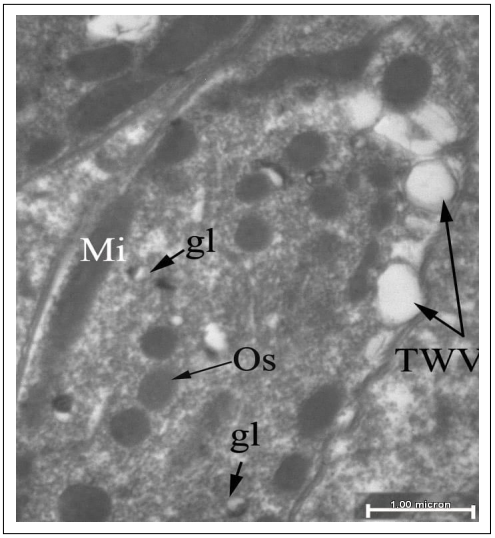

Fig 4: Posterior end of the epimastigote, notice osmophilic bodies (Os) glycosomes (gl), mitochondria (Mi) and thin-walled vesicles (TWV) scale bar in µm.

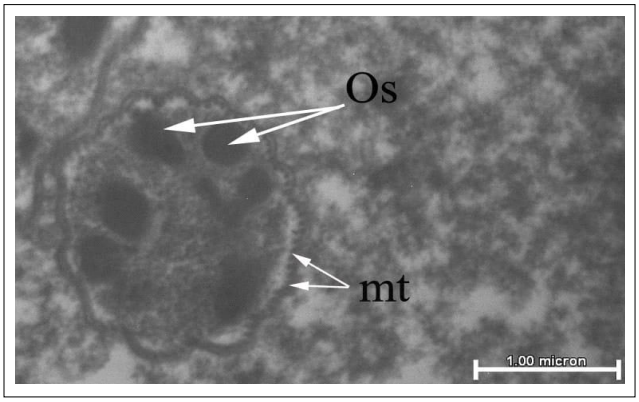

Fig 5: Cross section of epimastigote, notice microtubules (mt) and osmiophilic bodies (Os) scale bar in µm.

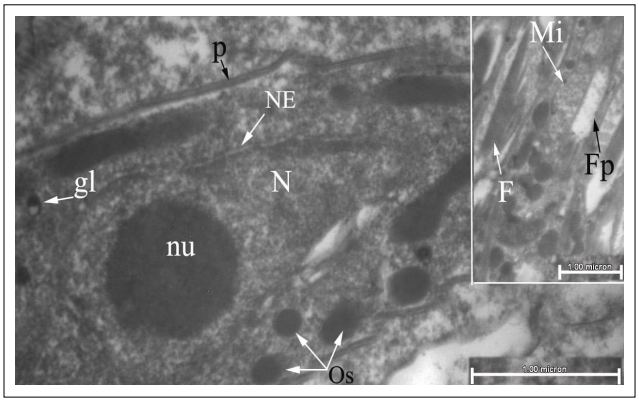

Fig 6: Nucleus (N) of epimastigote enclosed by double longer nuclear envelope (NE) notice nucleolus (nu) scale bar in µm.



Fig 7: Longitudinal section of epimastigote showing flagella pocket (Fp), flagellum (F) paraxial ro (PR) and coated vesicle (CV) thick-walled triangular vacuole (Twtv) scale bar in µm.



Fig 8: The cytoplasm of epimastigote containing kinetoplast (K), thick-walled vesicle (TV) and Osmophlic bodies (Os) scale bar in µm.

probably represents degenerated flagellar pocket of a dying epimastigote (Fig 7).

CONCLUSION

It can be concluded from this study that the trypomastigote stage of *T. evansi* reached the midgut of *C. titillator* through bleeding of the nasal mucous membrane at the site of its attachment. The trypomastigote changed to the epimastigote stage in the larval midgut and multiply there. However, it could not survive so long as indicated by the disappearance of the kinetoplast and degeneration of the flagellar pocket. This conclusion is supported by the absence of the epimastigote stage from the gut of adult *C. titillator* previously reared from 3rd stage larvae infected with the epimastigote stage.

ACKNOWLEDGEMENT

This study was supported by the Researchers Supporting Project (RSP2023R25), King Saud University, Riyadh, Saudi Arabia and also was supported by Princess Nourah bint Abdulrahman University Researchers Supporting Project number (PNURSP2023R96), Princess Nourah bint Abdulrahman University, Riyadh, Saudi Arabia.

Compliance with ethical standards

Data availability statement

All the datasets generated or analyzed during this study are included in this published article.

Conflict of interest

The author(s) declare that they have no conflict of interest regarding the content of this article.

REFERENCES

Diall, O., Desquesnes, M., Faye, B., Dia, M.L., Jacquiet, P., Sazmand, A., Otranto, D., Touratier, L. (2022). Development of a control strategy towards elimination of *Trypanosoma evansi* infection (surra) in camels in Africa. Acta Tropica. 234: 106583.

Enwezar, F.N.C. and Sackey, A.K.B. (2005). Camel trypanosomiasis-(A review). Veterinarski Archic. 75: 439-452.

Fatani, A. and Hilali, M. (1994). Prevalence and monthly variation of the second and third instars of *Cephalopina titillator* (Diptera: Oestrida) infesting camels in Eastern province of Saudi Arabia. Veterinary Parasitology. 53: 145-151.

Hajduk, S.L. (1978). Influence of DNA Complexing Compounds on the Kinetoplast of Trypanosomatids. In: Progress in Molecular and Subcellular Biology. [Hahn, F.G. (Ed.)] Springer, Heidelberg B. 158-200.

Higgins, A.J. (1985). Common ectoparasites of the camel and their control. British Veterinary Journal. 141(2): 197-216.

Hilali, M. and Fahmy, M.M. (1993). Trypanozoon - like epimastigote in the larvae of *Cephalopina titillator* (Diptera: Oestridae) infesting (*Camelus dromedarius*) infected with *Trypanosoma evansi*. Veterinary Parasitology. 45: 327-329.

Hilali, M., Abdel-Wahab, A., Abdel Maogood, S.Z., El Behairy, A.M. (2010). Comparative study between the epimastigote stage infecting *Cephalopina titillator* (Diptera: Oestridae) and *Trypanosoma evansi* infecting camels (*Camelus dromedarius*). Egyptian veterinary Medical Society of Parasitology Journal. 6: 1-10.

Hussein, M.F., Elamin, F.M., El-Taib, N.T. (1982). Basmaeil SMJVP: The pathology of nasopharyngeal myiasis in Saudi Arabian camels (*Camelus dromedarius*). Veterinary Parasitology. 9(3-4): 179-83.

Lopes, A.H., Souto-Padron, T., Dias, F.A., Gomes, M.T., Rodrigues, G.C., Zimmermann, L.T., Alvese Silva, T.L., Vermelho, A.B. (2010). Trypansomatids: Odd organisms, Divastating disease. The Open Parasitology Journal. 4: 30-59.

Mehlhorn, H. (2014). Encyclopedic Reference of Parasitology 6th ed. (Vol. 1, Ed.). Springer Press, Berlin.

Murray, M., Murray, P.K., Mc Intyre, W.I.M. (1977). An improved parasitological technique for the diagnosis of African trypanosomiasis. Transactions of the Royal Society of Tropical Medicine and Hygiene. 71(4): 325-328.

Otranto, D. (2001). The immunology of myiasis: Parasite survival and host defense strategies. Trends in Parasitology. 17(4): 176-182.

Reynolds, E.S. (1963). The use of lead citrate at high PH as an electron-opaque stain in electron microscopy. Journal of Cell Biology. 17: 208-212.

Zweygarth, E., Kaminsky, R., Webster, P. (1990). *Trypanosoma brucei evansi*: Dyskinetoplasia and loss of infectivity after long-term *in vitro* cultivation. Acta Tropica. 48: 95-99.

Zumpt, F. (1965). Myiasis in man and animals in the old world. Butterworth, London. 159-164.

Yao, H., Liu, M., Ma, W., Yue, H., Su, Z., Song, R., Ma, Q., Li, L., Wu, Z., Ma, Y., Chen, G., Chen, B., Yang, J. (2022). Prevalence and pathology of *Cephalopina titillator* infestation in *Camelus bactrianus* from Xinjiang, China. BMC Veterinary Research. 18(1): 360. doi: 10.1186/s12917-022-03464-5.