RESEARCH ARTICLE Indian Journal of Animal Research, Volume 57 Issue 12: 1662-1669 (December 2023)

A Comparison in Terms of Prevalence, Morphological and Histopathological Changes between *Eimeria* spp. that Infect Local Rabbits (*Oryctolagus cuniculus*) in Some Regions of Saudi Arabia

Mutee Murshed[1], Mohammed Mares[1], Hossam M.A. Aljawdah[1], Saleh Al-Quraishy[1]

10.18805/IJAR.BF-1682

ABSTRACT

Background: The epidemiology of parasitic infections is common in rabbit flocks and poses a significant threat to public health. And the most famous and influential of these causes are coccidia parasites, Coccidiosis in rabbits is an infection caused by intracellular protozoan parasites belonging to *Eimeria*, which is considered a major cause of significant morbidity and mortality.

Methods: A total of 210 fresh feces samples of adult domestic rabbits (*Oryctolagus cuniculus*) were collected from Riyadh City, Al Kharj and ADilam in Saudi Arabia to examine the incidence of the *Eimeria* infection of microscopically. Feces concentrated by the floatation technique. After that, freshly collected non-sporulated oocysts were suspended in 2.5% (W/V) potassium dichromate, placed in Petri dishes in the air, and allowed to sporulate at room temperature (25±3°C). The morphometric and specific characteristics of sporulated oocysts were studied by an Olympus microscope (BX51ggTF, OLYMPUS, Tokyo, Japan) using the oil immersion lens. Specimens were taken from all parts intestine and liver, and the tissues were kept in 10% formalin immediately and make tissue sections and that to study the histopathological change under light microscopic.

Result: An investigation was conducted in three cities in the Riyadh area (Riyadh, Al Kharj and Adilam) to determine the incidence of Eimeria species that parasitize local rabbits (*Oryctolagus cuniculus*). The overall frequency of these coccidial illnesses in rabbits in Riyadh City was 45.7%, in Adilam City it was 44.2% and in Al Kharj City it was 37.1%, respectively. There were five different species of *Eimeria*: *E. magna, E. flavescens, E. exigua, E. striedae* and *E. coecicola*, respectively. More than one species of Eimeria oocyst was obtained in the same examined sample. Single-infection 13/90 (14.4%), dual-infection 39/90 (43.3%) and triple-infection 38/90 (42.2%). *E. magna; E. flavescens; E. exigua; E. stiedae* and *E. coecicola*, respectively. Significant differences ($p \leq 0.05$) in prevalence were observed between the rabbits. Eimeria infection that affects the liver was confirmed by histopathological changes that were noted through the development of parasitic stages in the jejunum, ileum, cecum, end cecum and liver. It is possible to conclude that the current research offers pertinent information that aids in determining potential infection and future preventative measures against rabbit coccidiosis to lessen financial losses in the rabbit industry.

Key words: Coccidiosis, Hemorrhage, Inflammation, Oocyst residuum, Oocysts, Rabbit.

INTRODUCTION

Coccidiosis one parasitic infection epidemiology in rabbits, is an important topic in the meat industry and public health, to has contained less cholesterol and higher amounts of protein with essential amino acids than the meat of other animal species. Some strains are bred for fur production as well as for medical and biological purposes. Some breeds are reared for fur production as well as for medical and biological purposes (Al-Mathal, 2008; Demello, 2014). It improves health and reduces disease risk; rabbit meat can be considered a functional food. Rabbit meats increase the intake of nutritious and biologically active compounds such as polyunsaturated fatty acids (P.U.F.A.), docosahexaenoic acid (D.H.A.) and selenium, which are elevated in rabbit meat eaters. This helps reduce cardiovascular disease and other chronic diseases (Awuchi *et al*., 2022; Dalle Zotte and zendrő, 2011). The global production of rabbit meat has expanded by a factor of 2.5 during the course of the previous 50 years, reaching 1.6 million tons in 2009. Globally, the countries of China, Italy, Spain and France are the primary producers of rabbit meat (Ayres, 2021). Therefore, rabbit production is an important animal resource in the Kingdom of Saudi Arabia (Al-Mathal, 2008). Coccidiosis remains one of the most important infectious causes of digestive disorders in fattening rabbits (Hamid *et al*., 2019). Rabbit coccidian is an obligatory intracellular parasite causing coccidiosis in commercial and domestic rabbits (Peeters *et al*., 1981). Thus far, 15 species of *Eimeria* in rabbits have been identified.

[1]Department of Zoology, College of Sciences, King Saud University, Riyadh, Saudi Arabia.

Corresponding Author: Mutee Murshed, Department of Zoology, College of Sciences, King Saud University, Riyadh, Saudi Arabia. Email: mmares@ksu.edu.sa

How to cite this article: Murshed, M., Mares, M., Aljawdah, H.M.A. and Al-Quraishy, S. (2023). A Comparison in Terms of Prevalence, Morphological and Histopathological Changes between *Eimeria* spp. that Infect Local Rabbits (*Oryctolagus cuniculus*) in Some Regions of Saudi Arabia. Indian Journal of Animal Research. 57(12): 1662-1669. doi: 10.18805/IJAR.BF-1682.

Submitted: 09-08-2023 **Accepted:** 06-10-2023 **Online:** 16-11-2023

E. perforans, E. piriformis, E. exigua, E. media, E. magna, E. coecicola, E. vejdovskyi, E. flavescens, E. roobroucki, E. intestinalis, E. agnosta, E. nagpurensis, E. irresidua, E. matsubayashi and *E. oryctolagi*, parasitize the small intestine. These can be differentiated by the morphology of oocysts, site of infection, clinical signs and histopathological changes (Tylor *et al*., 2007; Ceré *et al*., 1996). The parasite has a life cycle that lasts from 4 to 14 days (Pakandl, 2013). The distribution and spread of animal coccidiosis are affected by many factors, including the high density of animals in a small area, the ambient air temperature, high humidity, different ages of animals in the same place, the quality of feed and the general health status of animals. The severity of the disease depends on the age of the animal and also on its ability to survive. They elicit an immune response to infection (Awais *et al*., 2012). The severity of coccidiosis depends on the presence of oocytes ingested. Clinical signs are anorexia, depression, abdominal pain and pale, watery mucous membranes, which may be absent in older rabbits. Examination of the stool usually shows blood and streaks of mucus. Young rabbits are stunted due to side effects on the kidneys, especially the liver (Pakandl, 2005). The condition in domestic rabbits occurs either in the intestines (intestinal coccidiosis) or the liver (hepatic coccidiosis) and mainly in young rabbits (Okumu *et al*., 2014; Pakandl *et al*., 2008). And rabbits housed in poor environmental sanitation and poor hygienic practices may cause weight loss or the inability to gain weight; diarrhea, which may be watery and bloody; dehydration; and death (González-Redondo *et al*., 2008). Histology revealed lymphocytic infiltration and the presence of coccidian oocysts and coccidian schizonts in the lamina propria of the intestinal epithelium and in a case of Liver coccidiosis showing coccidian oocysts, gametocytes and proliferation of bile duct epithelium Which leads to the death of rabbits (Okumu *et al*., 2014). This study determined how common *Eimeria* infections are in domestic rabbits by looking at oocysts in feces and pathological changes in the intestine. Furthermore, the article describes the shape of sporulated oocysts collected from different parts of Saudi Arabia.

MATERIALS AND METHODS

Approval of ethical

This study was conducted by the ethical rules for the use of animals established by the Kingdom of Saudi Arabia (permission number: KSU-SE-21-86, Ethics Committee of King Saud University).

Study collection fecal samples of rabbit

A total of 210 fresh feces samples of adult domestic rabbits *(Oryctolagus cuniculus)* were collected from Riyadh City, Al Kharj and Ad-Dilam in Saudi Arabia to examine the incidence of the *Eimeria* infection microscopically. Feces concentrated by the floatation technique; 2-3 g of each sample was put into 50 mL of saturated saline (0.9% NaCl). After passing the suspension through cheesecloth, it was then centrifuged (Yamato RE300, Tokyo, Japan) at a speed of 1500 rpm for 10 minutes (Long *et al*., 1976). To determine the sporulation presence and morphology of oocysts, freshly collected non-sporulated oocysts were suspended in 2.5% (W/V) potassium dichromate, placed in Petri dishes in the air and allowed to sporulate at room temperature (25±3°C). Periodic samples were examined under the microscope using an oil immersion objective lens and the progress of sporulation was recorded. The sporulation time was determined when the sporozoites within the sporocysts were fully formed. The sporulated oocytes were stored at 4°C to prepare them for molecular analysis.

Purification of *Eimeria* species oocyst

Oocysts were purified and washed in K2Cr2O7 by performing a serial dilution with distilled water until sporulated oocysts were obtained in a 10 µl solution. Each coccidium free rabbit was infected with one sporulated oocyst *via* oral inoculation. The purified *Eimeria* species oocysts were stored at 4°C until used (Upton *et al*., 1991).

Identification of *Eimeria* species

The morphometric and specific characteristics of sporulated oocysts were studied by an Olympus microscope (BX51ggTF, OLYMPUS, Tokyo, Japan) using the oil immersion lens. *Eimeria* species with at least 55-75 sporulated oocysts were identified using a combination of oocyst size, sporocyst size, the presence or absence of sporocyst residual bodies and the presence or absence of Stieda bodies. All measurements were made with an eyepiece micrometer and an oil immersion lens. The measurements were given in micrometers as means±SD followed by the range in parentheses. Only oocysts with sharply defined outlines and intact sporocysts were measured and recorded.

Examination of microscopic

Oocysts from each of the samples were photographed and morphometric characteristics were analyzed using an Olympus microscope (Olympus CX41, Tokyo, Japan) that was fitted with a digital camera. The results were presented as the mean along with the range.

Histopathological examination

Specimens were taken from all parts intestine and the tissues were kept in 10% formalin immediately after removal and 48 hours of fixation, tissue slide processing was made routinely using a set of increasing alcohol concentrations, tissue sections were embedded in paraffin blocks and sectioned by microtome at 5 µm. All tissues were stained with hematoxylin and eosin stain and the histopathological changes were examined under light microscopic.

Statistical analysis

The analysis of the ANOVA was carried out in a single direction and after that, statistical comparisons between the groups were carried out using the Duncan method. The

values have been reported using the mean plus or minus (±) the standard deviation when the significance threshold was set at P≤0.05. In its version 11 iteration, the Sigma Plot application was utilized for statistical analysis.

RESULTS AND DISCUSSION

In this research, 210 samples of local rabbits in three different cities (Riyadh, Al Kharj and Ad-Dilam) were examined for coccidiosis infection, and 90 rabbits were found to be infected with other different species of the *Eimeria* genus (Table 1), constituting 42.86% of the total (Fig 1). The infections were typical, and the breeders did not provide the rabbits with any *Eimeria* related vaccines or treatments. After an investigation, the overall frequency of these coccidial illnesses in rabbits in Riyadh City was 45.7%, in Ad-Dilam City it was 44.2% and in Al Kharj City it was 38.6%, respectively (Table 1, Fig 2), significant differences ($p<0.05$) in prevalence were observed between infected and uninfected rabbits. However, no significant difference was seen between Riyadh, Al Kharj and Dilam rabbits ($p>0.01$). In the domestic Saudi Arabian rabbits where the study was conducted (Abdel-Baki and Al-Quraishy, 2013), they found that the incidence of *Eimeria* spp. was (75%). In previous studies, the prevalence of coccidial infection in domestic Saudi Arabian rabbits has ranged from 73% to 90%. In the present study, the fecal analysis revealed that the prevalence of *Eimeria* spp. in domestic rabbits was 42.85% lower than in previous studies conducted in the Kingdom of Saudi Arabia, where it was 45.7%, 37.14 studies has ranged from 73% to 90%. In the present study, the fecal analysis revealed that the prevalence of *Eimeria* spp. in domestic rabbits was 42.85% lower than in previous studies conducted in the Kingdom of Saudi Arabia, where it was 45.7%. In addition, (Ras, 2020; Delahaut *et al*., 2020; Elshahawy and Elgoniemy, 2018), recorded that 34.93%, 68.12%, 70% and 86.50% of Egypt rabbits were infected with coccidiosis, respectively. While our findings were higher than those obtained in India (9.3%) and Brazil (19.5%) by (Heker *et al*., 2017), Moreover, reported (Li *et al*., 2010), that rabbit coccidiosis in Taiwanese pet shops and farms was 46.2% and 41.7%, respectively. A difference between prevalence rates might be attributed to management fac-tors such as housing and the use of chemoprophylaxis (Chowdhury and Fraser, 2008), various sampling methods, rabbit breeds and feed and poor hygienic conditions (AbouLaila, 2020; Heker *et al*., 2017; Jing *et al*., 2012). The prevalence rates of mixed and single infections with two to three types of *Eimeria* from 90 rabbit feces samples showed 14.44% and 85.56%, respectively (Fig 3). Through running rabbit stool tests, we found *Eimeria,* single-infection 13/90 (14.4%), dual-infection 39/90 (43.3%) and triple-infection 38/90 (42.2%) and we did not have a quadruple infection (Fig 4). The samples collected from Riyadh city were 32 infected samples out of a total of 70 rabbit faeces samples. Mixed species of *Eimeria* were obtained, *E. coecicola* + *E. magna* + *E. exigua* which constituted 10/70 (14.2%), followed by *E. flavescens* + *E. magna* + *E. Exigua* 7/70 (10%), *E. magna* + *E. exigua* 5/70 (7.1%), *E. coecicola* + *E. exigua* 3/70 (4.2%). While, single-infection was in small proportions *E. magna* 3/70 (4.2%), *E. coecicola* 2/70 (2.8%) and *E. stiedai* 2/70 (2.8%), respectively (Fig 5). The samples collected from Al Kharj city were 26 infected samples out of a total of 70 rabbit faeces

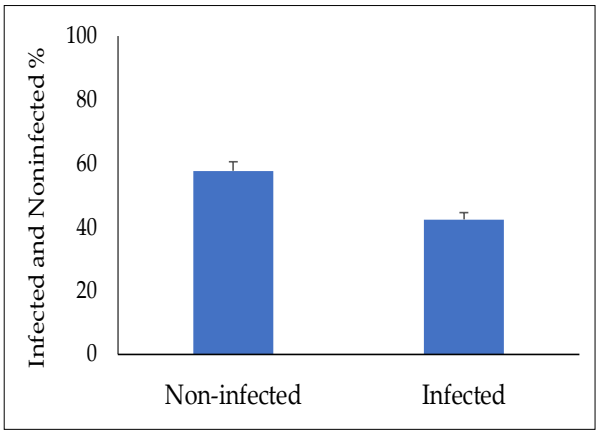

Fig 1: Generally, the infection rate of *Eimeria* parasites in domestic rabbits.

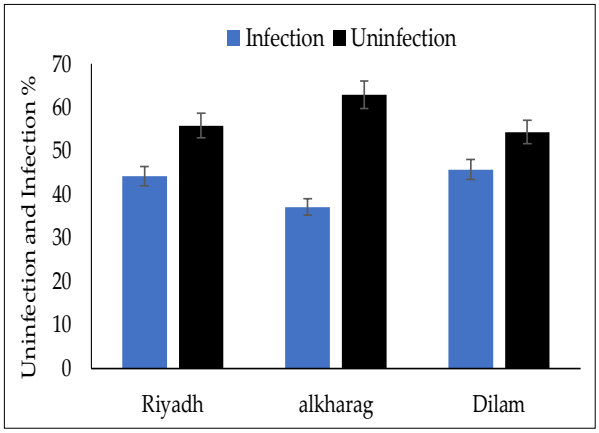

Fig 2: The infection and noninfectious rates in three different cities (Riyadh, Al Kharj and Adilam) in domestic rabbits.

Table 1: Prevalence of *Eimeria* species in fecal samples obtained from 210 samples in 3 areas in Saudi Arabia.

Sampling areas	no. sample examined	Infected	Non-infected	Prevalence (%)
Riyadh	70	32	38	45.7%
Al Kharag	70	27	43	38.6%
Ad-Dilam	70	31	39	44.2%
Total	210	90	120	42.85%

samples. The single-infection species of *Eimeria magna* was obtained 3/70 (4.2%). While mixed species of *Eimeria* were obtained in triple-infection and they were more present, *E. coecicola* + *E. flavescens* + *E. magna* 12/70 (17.1%), followed by dual-infection, *E. coecicola* + *E. exigua* 7/70 (10%), then *E. magna* + *E. exigua* 2/70 (2.8%), respectively (Fig 6). The samples collected from Dilam city were 31 infected samples out of a total of 70 rabbit faeces samples. The single-infection specie of *E. magna* and *E. stiedae* were obtained 2/70 (2.8%) and 2/70 (2.8%). While mixed types of *Eimeria* were obtained through dual infection, they were more present, *E. magna* + *E. exigua* 11/70 (15.7%), followed by triple-infection, *E. coecicola* + *E. flavescens* + *E. exigua* 9/70 (12.8%), *then E. coecicola* + *E. exigua* 5/70 (7.1%) and *E. coecicola* + *E. flavescens* 2/70 (2.8%), respectively (Fig 7). The morphometric measurements of the oocysts of these *Eimeria* species obtained from the infected rabbits are shown in (Table 2). Five different species of *Eimeria* were recognized as having been found in the rabbits' feces investigated below (Fig 8). Concurrent infections observed included species collected from naturally infected domestic rabbits.

Eimeria exigua

The sporulated oocysts of *E. exigua* appeared Spheroidal in shape and measured 15.7 (12-16) µm in length and 15.7 (12-16) µm in width and do not have a micropyle. There is no oocyst residuum (Fig 8A). This research aligns with the survey results (Elshahawy and Elgoniemy, 2018; Yakimoff, 1934).

Eimeria magna

The sporulated oocysts of *E. magna* appeared ovoid in shape and measured 24 (22-27) µm in length and 14.4 (14-17) µm in width and had a micropyle. There existed an oocyst residuum (Fig 8B). It was discovered that the oocysts of this parasite are similar to but slightly different from the oocysts of *E. magna* described by (Razavi *et al*., 2010).

Eimeria stiedae

The sporulated oocysts of *Eimeria stiedae* appeared cylindrical to elongate ellipsoid in shape and measured 29.3 (25-30) µm in length and 18 (16-18) µm in width

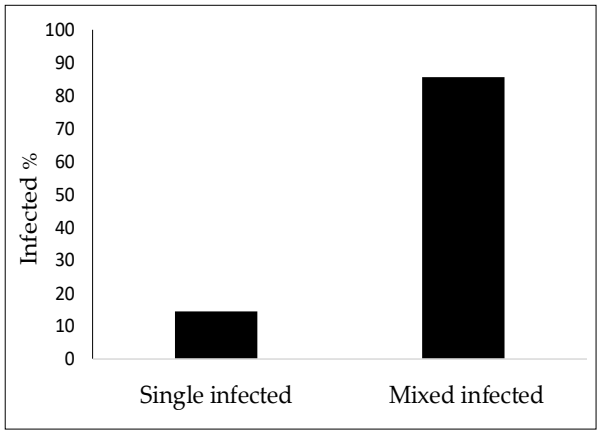

Fig 3: The prevalence rate of mixed infection with *Eimeria* species from 90 rabbit faecal samples.

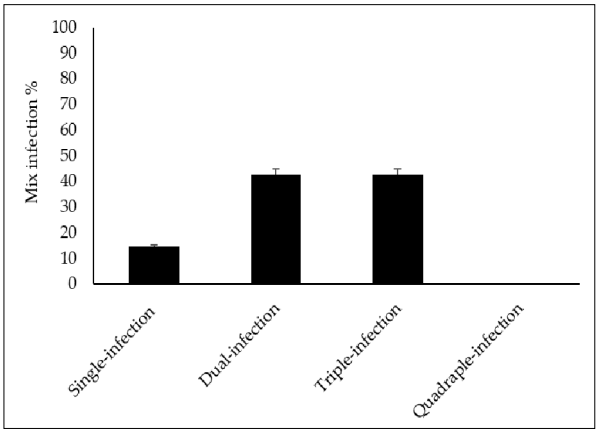

Fig 4: The mixed infection is the presence of a single infection or a double infection in domestic Rabbits samples.

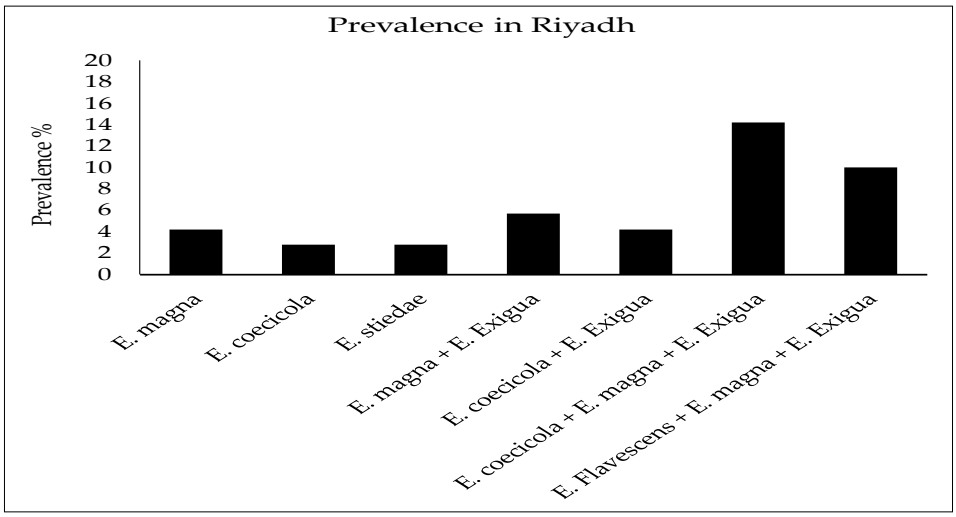

Fig 5: The prevalence rate of *Eimeria* species from 70 positive fecal samples of rabbits in Riyadh.

Table 2: Morphological comparison between coccidian oocysts detected from rabbits in the present study and other related species from the same host.

	Measurements	Shape	M	MC	OR	References
E. magna	33.24 × 17.92	Ovoid	+	-	+	Li *et al*., 2016
	27.48 × 19.23	Ovoid	+	-	+	Li *et al*., 2016
	35.1 × 23.9	Ovoid	+	-	+	Ras, 2020
	24 (23-26) × 14 (13-16)	Ovoid	+	-	+	Elhendy *et al.,* 2018
	24 (23-26) × 14.3 (13-16)	Ovoid	+	-	+	Elshahawy and Elgoniemy, 2018
	24 (22-27) × 14.4 (14-17)	Ovoid	+	-	+	This study
E. exigua	14.64 × 13.57	Spheroidal	-	-	-	Li *et al*., 2016
	13.66 × 12.82	Spherical	-	-	-	Li *et al*., 2016
	15 (14-17) × 15 (14-17)	Spherical	-	-	-	Yakimoff, 1934
	15 (14-17) × 15 (14-17)	Spherical	-	-	-	Elshahawy and Elgoniemy, 2018
	30.14 × 18.32	Ellipsoid	+	-	+	Li *et al*., 2016
	15.7 (12-16) × 15.7 (12-16)	Ellipsoid	-	-	-	This study
E. stiedai	26.5 (24-29) × 13.1 (11-15)	Ellipsoid	+	-	+	Elshahawy and Elgoniemy, 2018
	30.14 × 18.32	Ellipsoid	+	-	+	Li *et al*., 2016
	29.3 (25-30) × 18 (16-18)	Ellipsoid	+	-	+	This study
E. coecicola	28.10 × 15.64	Elongated, ellipsoidal	+	-	+	Li *et al*., 2016
	34.1 × 18.7	Ellipsoidal, ovoid	+	-	+	Ras, 2020
	24 (23-29) × 14 (14-17)	Cylindrical	+	-	+	AbouLaila, 2020
	24.6 (22-29) × 14.2 (12-17)	Cylindrical	+	-	+	Elshahawy and Elgoniemy, 2018
	24.8 (23-29) × 13.6 (12-16)	Cylindrical	+	-	+	This study
E. flavescens	23 (22-30) × 16.2 (14-18)	Ovoid	-	-	-	Elshahawy and Elgoniemy, 2018
	23 (22-30) × 16 (14-18)	Ovoid	+	-	-	Ogolla *et al*., 2018
	24.82 × 16.05	Piriform	+	-	-	Li *et al*., 2016
	24.8 (22-29) × 17.6 (15-18)	Ovoid	+	-	+	This study

M = Micropyle; MC = Micropylar cap; OR = Oocyst residuum. + = Present; - = Absent

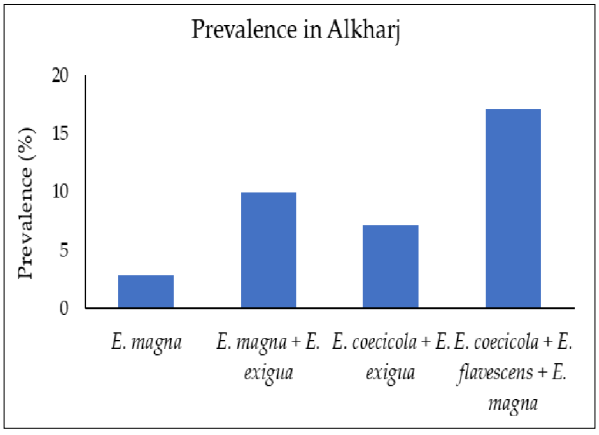

Fig 6: The prevalence rate of Eimeria species from 70 positive fecal samples of rabbits in Al Kharj.

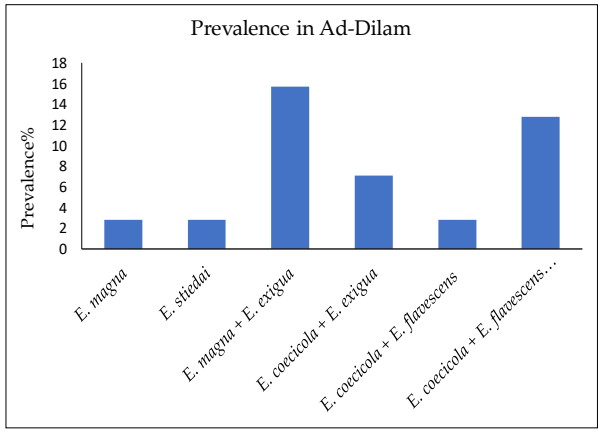

Fig 7: The prevalence rate of *Eimeria* species from 70 positive fecal samples of rabbits in Adilam.

and had a micropyle. There existed an oocyst residuum (Fig 8C) and they were found to be similar to those of the *Eimeria* medium. However, these are only minor distinctions (Li *et al*., 2016).

Eimeria coecicola

The sporulated oocysts of *E. coecicola* appeared cylindrical in shape and measured 24.8 (23-29) µm in length and 13.6 (12-16) µm in width and had a micropyle. There existed an oocyst residuum (Fig 8D). These findings are in line with those of a survey con-ducted by (Ras, 2020; Li *et al*., 2016), with some minor variations.

Eimeria flavescens

The sporulated oocysts of *E. flavescens* appeared ovoid in shape and measured 24.8 (22-29) µm in length and 17.6 (15-18) µm in width and had a micropyle. There existed an oocyst residuum (Fig 8F). This study is in line with the survey

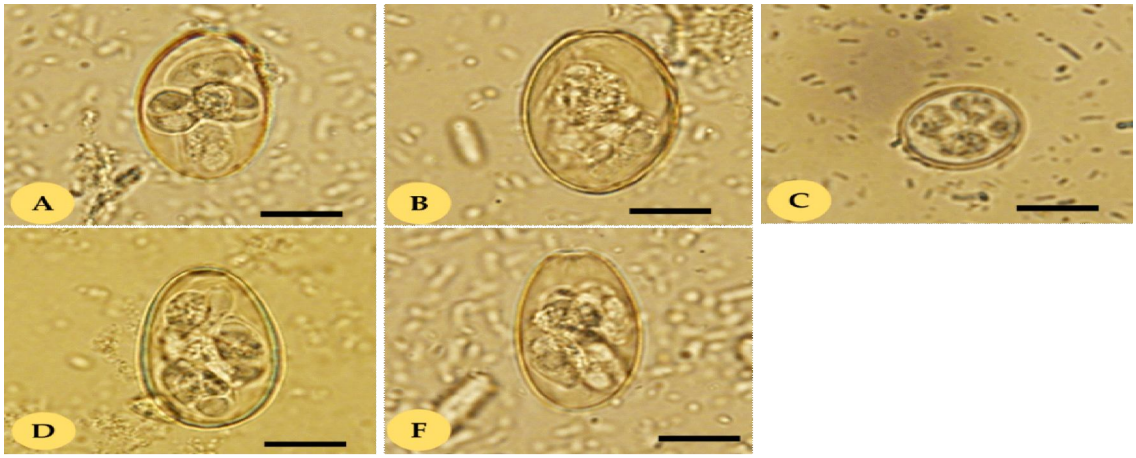

A: *E. magna;* B: *E. flavescens;* C: *E. exigua;* D: *E. stiedai;* F: *E. coecicola*. Scale bars = 10 µm.

Fig 8: Sporulation oocysts of the five species of *Eimeria* collected from naturally infecting domestic rabbits *Oryctolagus cuniculus.*

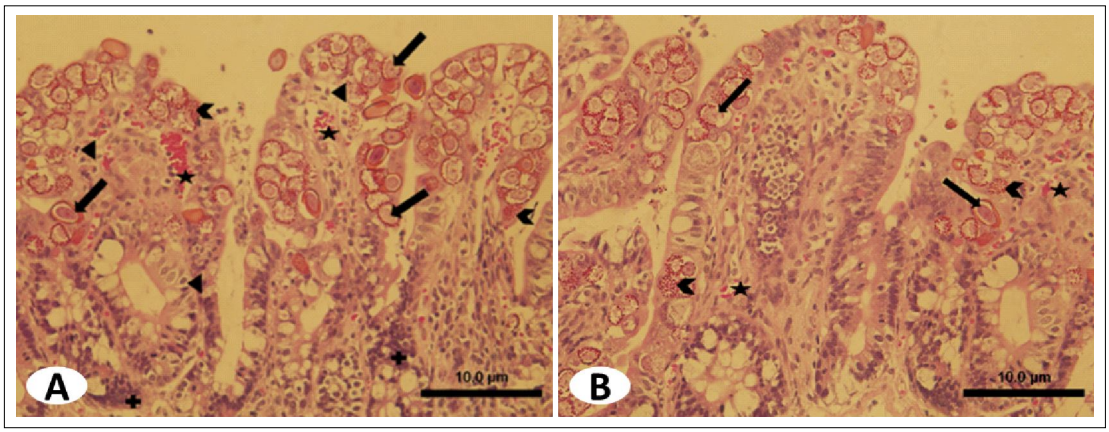

Fig 9: Histopathological changes in the jejunum (A) and ileum (B), different developmental parasitic stages, including gametocytes and oocysts (arrows) in addition to multiple schizonts (arrowheads) occupying the sites of intestinal absorptive epithelium, multi-spot of hemorrhage (asterisk) and inflammation with diffuse infiltration of lymphocytes (plus sign).

performed by (Elshahawy and Elgoniemy, 2018; Li *et al*., 2016), with some minor changes.

Rabbits infected with *E. magna, E. exigua, E. flavescens, E. coecicola* and *E. stiedae* were subjected to a histopathological analysis of their jejunum (A), ileum (B), cecum (C), end cecum (D) and liver (E) and (F). Histopathological change, the *E. magna, E. exigua* is found in the superficial epithelium of the jejunum and ileum. Various parasitic developmental stages, such as gametocytes and oocysts, and multiple schizonts occupying the sites of intestinal absorptive epithelium, as well as multispots of bleeding and inflammation with diffuse infiltration of lymphocytes (Fig 9), are seen in the jejunum and ileum during a histopathological examination. This is consistent with several studies (Ogolla *et al*., 2018; Elhendy *et al*., 2018). *E. flavescens* is found in the superficial epithelium of the caecum and *E. coecicola* in the epithelium of the end cecum (Norton *et al*., 1979). Histopathological changes in the cecum and end cecum, different developmental parasitic stages, including gametocytes and oocysts in addition to multiple schizonts occupying the sites of intestinal absorptive epithelium, multi-spot of hemorrhage, Focal steatosis and inflammation with diffuse infiltration of lymphocytes (Fig 10). This is consistent with several studies (Elhendy *et al*., 2018). Lesions in liver tissue sections from infected rabbits were largely confined to the liver and bile ducts and consisted primarily of extensive bile duct hyperplasia. The bile ducts are markedly enlarged and lined with hyperplastic columnar epithelial cells arranged in multiple branched papillary lobes extending into the bile duct lumen, resembling adenomatous hyperplasia with the presence of parasite developmental stages. Many stages of protozoa such as microgametocytes, macrogametocytes and oocysts have also been observed. Inflammation with severe hemorrhage and diffuse lymphocytic infiltration in many areas was also observed (Fig 11). This is consistent with several studies (Al-Saeed *et al*., 2017; Al-Naimi *et al*., 2012).

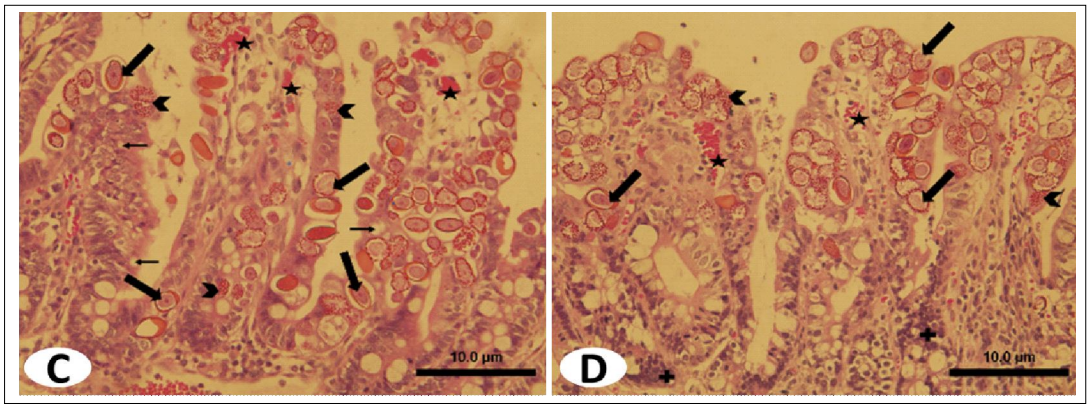

Fig 10: Histopathological changes in the cecum (C) and end cecum (D), different developmental parasitic stages, including gametocytes and oocysts (arrows) in addition to multiple schizonts (arrow heads) occupying the sites of intestinal absorptive epithelium, multi-spot of hemorrhage (asterisk), Focal steatosis (small arrows) and inflammation with diffuse infiltration of lymphocytes (plus sign).

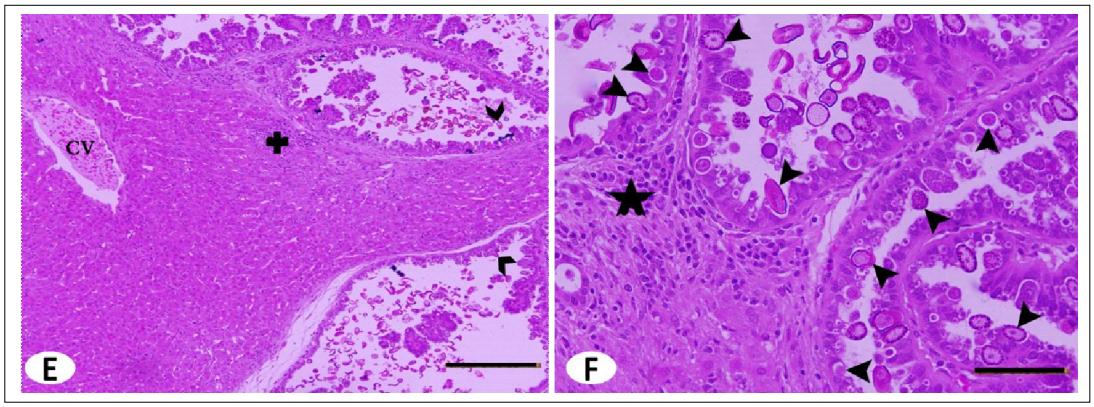

Fig 11: Histopathological changes in the liver (E) and (F), different developmental parasitic stages, including gametocytes and oocysts (arrows heads) and inflammation with diffuse infiltration of lymphocytes (plus sign).

CONCLUSION

In summary, the present survey shows the prevalence of coccidiosis in rabbits in many cities in Saudi Arabia. Knowledge of the current prevalence of coccidiosis and *Eimeria* species will help to assess the potential for infection and provide relevant data to evaluate the effectiveness of future control strategies for coccidiosis in rabbits, thereby minimizing economic losses in the rabbit industry.

ACKNOWLEDGEMENT

This work was supported by the Researcher supporting project (RSP-2023/3), King Saud University.

Conflict of interest declaration

The authors declare that they have no conflict of interest.

REFERENCES

Abdel-Baki, A.A.S., Al-Quraishy, S. (2013). Prevalence of Coccidia (*Eimeria* spp.) infection in domestic rabbits, *Oryctolagus cuniculus,* in Riyadh, Saudi Arabia. Pakistan Journal of Zoology. 45(5): 1329.

AbouLaila, M.R. (2020). *Eimeria* stiedae: Infection rate and molecular characterization by nested PCR in rabbits from Minoufiya Governorate, Egypt. Egyptian Veterinary Medical Society of Parasitology Journal. 16(1): 34-49.

Al-Mathal, E.M. (2008). Hepatic coccidiosis of the domestic rabbit (*Oryctolagus cuniculus* domesticus L.) in Saudi Arabia. World Journal of Zoology. 3(1): 30-35.

Al-Saeed, M.H., Al Saeed, A.H., Jori, M.M. (2017). Study of physiological and histological changes in rabbits induced with hepatic coccidiosis. Journal University of Kerbala. 15(1): 1-13.

AL-Naimi, R.A.S., Khalaf, O.H., Tano, S.Y., H Al-Taee, E. (2012). Pathological study of hepatic coccidiosis in naturally infected rabbits. Al-Qadisiyah Journal of Veterinary Medicine Sciences. 11(1): 63-69.

Awais, M.M., Akhtar, M., Iqbal, Z., Muhammad, F., Anwar, M.I. (2012). Seasonal prevalence of coccidiosis in industrial broiler chickens in Faisalabad, Punjab, Pakistan. Tropical Animal Health and Production. 44: 323-328.

Awuchi, C.G., Chukwu, C.N., Iyiola, A.O., Noreen, S., Morya, S., Adeleye, A. O., Okpala, C. O. R. (2022). Bioactive compounds and therapeutics from fish: Revisiting their suitability in functional foods to enhance human wellbeing. BioMed Research International. https://doi.org/10.1155/2022/3661866.

Ayres, R.U. (2021). The History and Future of Technology: Can Technology Save Humanity from Extinction? Springer Nature.

Ceré, N., Humbert, J.F., Licois, D., Corvione, M., Afanassieff, M., Chanteloup, N. (1996). A New Approach for the Identification and the Diagnosis of *Eimeria* mediaParasite of the Rabbit. Experimental Parasitology. 82(2): 132-138.

Chowdhury, A.A., Fraser, G.C. (2008). Coccidia (*Eimeria* spp.) of domestic rabbits in New South Wales. Australian Veterinary Journal. 86(9): 365-366.

Dalle Zotte, A., Szendrő, Z. (2011). The role of rabbit meat as functional food. Meat Science. 88(3): 319-331.

Delahaut, V., Rašković, B., Salvado, M.S., Bervoets, L., Blust, R., De Boeck, G. (2020). Toxicity and bioaccumulation of Cadmium, Copper and Zinc in a direct comparison at equitoxic concentrations in common carp (*Cyprinus carpio*) juveniles. PLoS One. 15(4): e0220485.

Demello, M. (2014). Rabbits in captivity. The Ethics of Captivity. 77-89. doi: 10.1093/acprof:oso/9780199977994.003.0006.

Elhendy, A., Kuraa, H., Nageib, B. (2018). Pathological and parasitological studies on some *Eimeria* species in rabbits using light and electron microscope. Assiut Veterinary Medical Journal. 64(157): 81-93.

Elshahawy, I., Elgoniemy, A.S.H.R.A.F. (2018). An epidemiological study on endoparasites of domestic rabbits *(Oryctolagus cuniculus)* in Egypt with special reference to their health impact. Sains Malays. 47(1): 9-18.

González-Redondo, P., Finzi, A., Negretti, P., Micci, M. (2008). Incidence of coccidiosis in different rabbit keeping systems. Arquivo Brasileiro de Medicina Veterinária e Zootecnia. 60: 1267-1270.

Hamid, P.H., Prastowo, S., Kristianingrum, Y.P. (2019). Intestinal and hepatic coccidiosis among rabbits in Yogyakarta, Indonesia. Veterinary World. 12(8): 1256-1260.

Heker, M.M., Nakamura, A.A., Santana, B.N., Meireles, M.V. (2017). Etiological aspects of *Eimeria* spp. infection in Brazilian rabbit (*Oryctolagus cuniculus)* farms. Veterinary Parasitology: Regional Studies and Reports. 8: 78-81.

Jing, F., Yin, G., Liu, X., Suo, X., Qin, Y. (2012). Large-scale survey of the prevalence of *Eimeria* infections in domestic rabbits in China. Parasitology Research. 110: 1495-1500.

Li, H., Shen, M., Hou, Z., Yin, X. (2016). Morphology and molecular identification of the *Eimeria* spp. in domestic rabbits. Pakistan Journal of Zoology. 48(1): 289-291.

Li, M.H., Huang, H.I., Ooi, H.K. (2010). Prevalence, infectivity and oocyst sporulation time of rabbit-coccidia in Taiwan. Tropical Biomedicine. 27(3): 424-429.

Li, S., Tan, H.Y., Wang, N., Hong, M., Li, L., Cheung, F., Feng, Y. (2016). Substitutes for bear bile for the treatment of liver diseases: research progress and future perspective. Evidence -Based Complementary and Alternative Medicine.

Long, P.L., Millard, B.J., Joyner, L.P., Norton, C.C. (1976). A guide to laboratory techniques used in the study and diagnosis of avian coccidiosis. Folia Veterinaria Latina. 6(3): 201-217.

Norton, C.C., Catchpole, J., Joyner, L.P. (1979). Redescriptions of *Eimeria* irresidua Kessel and Jankiewicz, 1931 and *E. flavescens* Marotel and Guilhon, 1941 from the domestic rabbit. Parasitology. 79(2): 231-248.

Ogolla, K.O., Okumu, P.O., Gathumbi, P.K., Waruiru, R.M. (2018). Effects of anticoccidial drugs on gross and histopathological lesions caused by experimental rabbit coccidiosis. Symbiosis. 4: 2381-2907.

Okumu, P.O., Gathumbi, P.K., Karanja, D.N., Mande, J.D., Wanyoike, M.M., Gachuiri, C.K., Borter, D.K. (2014). Prevalence, pathology and risk factors for coccidiosis in domestic rabbits (*Oryctolagus cuniculus*) in selected regions in Kenya. Veterinary Quarterly. 34(4): 205-210.

Pakandl, M. (2005). Selection of a precocious line of the rabbit coccidium *Eimeria* flavescens Marotel and Guilhon (1941) and characterisation of its endogenous cycle. Parasitology Research. 97: 150-155.

Pakandl, M. (2013). Coccidia of rabbit: A review. Folia Parasitologica. 56(3): 153-166.

Pakandl, M., Hlásková, L., Poplštein, M., Chromá, V., Vodièka, T., Salát, J., Mucksová, J. (2008). Dependence of the immune response to coccidiosis on the age of rabbit suckling. Parasitology Research. 103: 1265-1271.

Peeters, J.E., Geeroms, R., Froyman, R., Halen, P. (1981). Coccidiosis in rabbits: A field study. Research in Veterinary Science. 30(3): 328-334.

Ras, R.A. (2020). Prevalence and morphological identification of *Eimeria* spp. in domestic rabbit *(Oryctolagus cuniculus)* in Sharkia province, Egypt. Egyptian Veterinary Medical Society of Parasitology Journal (EVMSPJ). 16(1): 114-130.

Razavi, S.M., Oryan, A., Rakhshandehroo, E., Moshiri, A., Mootabi Alavi, A. (2010). *Eimeria* species in wild rabbits (*Oryctolagus cuniculus*) in Fars province, Iran. Tropical Biomedicine. 27(3): 470-475.

Tylor, M.A., Coop, R.L., Wall, R.L. (2007). Veterinary Parasitology 3rd Ed. Blackwell Publishing, Oxford, 717.

Upton, S.J., McAllister, C.T., Trauth, S.E. (1991). Description of the oöcysts of *Eimeria septemvittata* n. sp. (Apicomplexa: Eimeriidae) from queen snakes, Regina septemvittata (Serpentes: Colubridae), in Arkansas. Systematic Parasitology. 20: 199-201.

Yakimoff, W. L. (1934). Two new species of Coccidia: *Eimeria* triffitt n. sp. of the eland *(Orias canna)* and *Eimeria peruviana* n. sp. of the llama *(Lama glama)*. Parasitology. 26(4): 510-511.