RESEARCH ARTICLE Indian Journal of Animal Research, Volume 57 Issue 12: 1599-1605 (December 2023)

The Effect of Vitamin E on Intestinal Epithelial Cells in Broiler Subjected to Heat Stress

D. Korkmaz[1]

10.18805/IJAR.BF-1690

ABSTRACT

Background: Heat stress leads to great economic losses in poultry industry because of increasing climate change globally. There are several nutrients which are generally used as to combat against heat stress. Vitamin E is one of the feed additives used to prevent losses due to heat stress. This study investigated the protective effect of vitamin E against cellular damage that may occur in intestinal epithelial cells against the heat stress. There is no information on the response of vitamin E to cellular damage in intestinal epithelial cells in broilers under heat stress.

Methods: In the current study, damage and the response to damage were tried to be revealed by considering both apoptotic factors, necrosis and inflammation markers. For this purpose, a total of 30 broiler chicks were divided into three replicates and analyzed. The control group was kept at 24°C, while the heat stress group was subjected to heat stress at 35°C (5 hours/day). Finally, 300 mg/kg vitamin E (a-tocopherol acetate) was supplemented daily to the heat stress+vitamin E group while heat stress was applied at 35°C (5 h/day).

Result: In the study, immuno-stainings were performed with caspase-9 to detect the intrinsic pathway of apoptosis, caspase-8 and TNF-α to detect the extrinsic pathway of apoptosis and IL-6 primary antibodies to detect the pro-inflammatory immune response. Consequently, it was determined in the study that caspase-9 activity, which was positive only in epithelial cells in all groups, increased significantly in heat stress, but vitamin E decreased this activity by 75%. However, caspase-8 activity increased with heat stress in both epithelial and connective tissue and vitamin E had a protective effect. It was observed that TNF-α activity increased with heat stress in all three parts of the small intestine, especially in the duodenum. However, this activity in the group with vitamin E was closer to the control group. IL-6 activity, an indicator of pro-inflammatory response, caused no difference between the groups. As a result, the study indicates that apoptosis may occur even if there is no acute systemic inflammation in the intestinal epithelial cells of living organisms exposed to heat stress. Additionally, this study reveals that vitamin E may reduce the effect of apoptosis in the intestines against heat stress.

Key words: Broiler, Caspase-8, Caspase-9, Heat stress, IL-6, Intestine, TNF-α, Vitamin E.

INTRODUCTION

Heat stress is one of the most challenging environmental stressors that affects poultry production worldwide and leads to substantial economic losses annually (Lara and Rostagno 2013; Li *et al*., 2020). Especially in broiler, the gastrointestinal system, which serves as the body's largest immune organ, is highly susceptible to heat stress (Varasteh *et al*., 2015).

Apoptosis is a programmed form of cell death regulated by the Bcl-2 family and the caspase protein family (Brentnall *et al*., 2013). Caspases, an extended family of aspartate-specific cysteine proteases, are evolutionarily conserved proteins for the initiation and execution of apoptosis (Aral *et al*., 2019). Both the intrinsic and extrinsic pathways mediate apoptosis. The extrinsic pathway is induced by cell death receptors (DRs) that interact with specific ligands such as tumour necrosis factor-α (TNF-α) and its associated caspase-8 (Nunez *et al*., 1998) and also Fas ligand, TNF-related apoptosis-inducing ligand (TRAIL) (Molnar *et al*., 2021). The caspase-9 activation and subsequent activation of effector caspases induce the intrinsic pathway. Mitochondrial outer membrane permeabilization (MOMP) mediates this type of apoptosis and is defined as mitochondria-centered cell death (Brentnall *et al*., 2013).

[1]Department of Histology-Embryology, University of Harran, Faculty of Veterinary Medicine, Sanliurfa/Turkiye.

Corresponding Author: D. Korkmaz, Department of Histology-Embryology, University of Harran, Faculty of Veterinary Medicine, Sanliurfa/Turkiye. Email: denizkorkmaz@harran.edu.tr

How to cite this article: Korkmaz, D. (2023). The Effect of Vitamin E on Intestinal Epithelial Cells in Broiler Subjected to Heat Stress. Indian Journal of Animal Research. 57(12): 1599-1605. doi: 10.18805/IJAR.BF-1690.

Submitted: 23-08-2023 **Accepted:** 18-09-2023 **Online:** 03-10-2023

Both TNF-α and IL-6 are the pro-inflammatory cytokines of the immune response (Li *et al*., 2020). Elevations in serum concentrations that are observed when exposed to heat stress indicate a systemic inflammatory response (Li *et al*., 2020).

Vitamins are defined as a group of complex organic compounds that are required for normal physiological functions and are found in very small amounts in natural foods. Vitamin E (VE) is a fat-soluble vitamin of plant origin and is essential for the integrity of the reproductive, muscular, circulatory, nervous and immune systems (Leshchinsky and Klasing, 2001).

This study aimed to investigate the effects of heat stress and vitamin E, which we believe to have a protective role against heat stress, on TNF-α and IL-6, both of which are pro-inflammatory cytokines and Caspase-9 and Caspase-8, both of which are markers of apoptosis, in the intestinal mucosa of poultry.

MATERIALS AND METHODS

A total of 30 broiler chicks, one day old, procured from a private enterprise were utilized as material. This study was conducted at the University of Harran Faculty of Veterinary Medicine Laboratory in the Histology-Embryology. The experiment was conducted between 2021 and 2023.

The chicks were divided into three groups.

1. The control group (10 animals) was kept at 24°C.
2. The experimental group (10 animals) was exposed to heat stress at 35°C (5 hours/day).
3. The experimental group (10 animals) was exposed to heat stress at 35°C (5 hours/day) and supplemented with 300 mg/kg of vitamin E (α-tocopheryl acetate) (Khan *et al*., 2012).

The experiment was conducted in May and June. In the first two weeks, the ambient temperature gradually decreased from 34°C to 24°C. Groups were supplied with feed and water *ad libitum*. The chickens were fed *ad libitum* a starter diet and growth/finishing diet. In the first two weeks, the ambient temperature gradually decreased from 34°C to 24°C on day 15. Application of heat stress (35°C) (5h/day) began on the sixteenth day. The environment was constantly illuminated. When the animals reached the 6th week of age, seven chicks from each group (control, heat stress and heat stress + vitamin E groups) were sacrificed through decapitation. Tissue samples were extracted from the duodenum, jejunum and ileum. The samples were kept in a 10% Neutral Buffer Formalin (NBF) fixative solution for 24 hours. After the routine tissue follow-up, they were blocked in paraffin. Three 6-micron serial sections were cut at 50 µm intervals from each block. The sections were subject to the following staining:

1. Caspase-9 to detect intrinsic pathway apoptosis.
2. Caspase-8 and TNF-α to detect extrinsic pathway apoptosis.
3. Immuno-staining with IL-6 primary antibodies to reveal pro-inflammatory immune response.

Immuno-histochemistry

Six-micron thick tissue samples placed on Poly-L-lysine-coated slides were stained with streptavidin-biotin-peroxidase complex technique (ABC). The tissues were treated with caspase-8 (1:50, ab4052; Abcam, Cambridge, USA), caspase-9 (1:100, ab52298; Abcam, Cambridge, USA), TNF-α (1: 50, ab6671; Abcam, Cambridge, USA) and IL-6 (10 µg/mL, RPA079Ga01-Recombinant Interleukin 6; Cloud-Clone Corp, USA) primary antibodies were applied (1 hour at room temperature) (Jackson and Blyhe 1995).

The stained slides were examined using a light microscope (Leica DMLB-İzmir-Turkey) and an image analysis system (Leica DC200 CD camera and Q-win standard image analysis program-İzmir-Turkey).

Semi-quantitative score

The effects of heat stress and vitamin E supplement with heat stress on apoptotic markers and pro-inflammatory cytokines in the duodenum, jejunum and ileum were semi-quantitatively scored by subjective scoring method as (negative: 0 [<1% positive]; weak: 1 [1-25% positive]; moderate: 2) [>25-75% positive]; and strong: 3 [>75% positives]) (Bianchi *et al*., 1992).

RESULTS AND DISCUSSION

Caspase-9 immunostaining findings

Caspase-9 activity was observed to be positive only in epithelial cells in all groups in the present study.

In the control group, no immuno-reaction was observed in crypts in duodenal sections, but there was moderate immuno-reaction in villi epithelial cells (Fig 1A). At the same time, a weak immuno-reaction was noted in the crypt and villi in the jejunum (Fig 1B) and ileum (Fig 1C) (Table 1). In the heat stress group, strong immunoreaction was observed in the crypt and villi in the duodenum (Fig 2A). In the jejunum, a strong reaction was observed in the villi, while there was a weak immuno-reaction in the crypts (Fig 2B). In the ileum, a moderate positive reaction was noted in the villi, crypts (Fig 2C) and lymph follicles (Fig 2D) (Table 1). For heat stress + vitamin E group, in the duodenum, moderate positivity was found in the villi (Fig 3A), but not observed in the crypts (Fig 3B). In the jejunum, the positive reaction was found to be moderate in the villi and weak in the crypts (Fig 3C). In the ileum, there was a weak reaction at the crypts and lymph follicles, while villi epithelium was found to be moderately (Fig 3D) (Table 1).

Caspase-8 immunostaining findings

Regarding caspase 8 in all groups, a positive reaction was found in both epithelium and connective tissue in this study. Weak cytoplasmic staining was observed in the duodenum

Table 1: Semi-quantitative caspase-9 immuno-reactivity in duodenum, jejunum and ileum.

Groups	D		J		I		
	V	C	V	C	V	LF	C
Cnt	++	-	+	+	+	+	+
Heat	+++	+++	+++	+	++	++	++
Heat+VE	++	-	++	+-	++	+	+

Negative: - [<1% positive]; Weak: + [1-25% positive]; Moderate: ++ [>25-75% positive] and strong: +++ [>75% positive]. D: Duodenum, J: Jejunum, I: Ileum, Cnt: Control, V: Villus, C: Crypt, LF: Lymph follicle.

in the control group. There was a weak immuno-reaction in the crypts, villi and connective tissue (Fig 4A). In the jejunum, weak or negative immuno-reaction was observed in the crypts, while there was a weak reaction in the villi (Fig 4B). In the ileum, weak or negative immuno-reactions were observed in the crypts, while moderate immuno-reaction was observed in the connective tissue, villi and lymph follicles (Fig 4C). Moderate positivity was observed in the villi and weak reaction in the crypt of the duodenum (Fig 5A). Weak immuno-reaction was observed in the villi and crypts in the

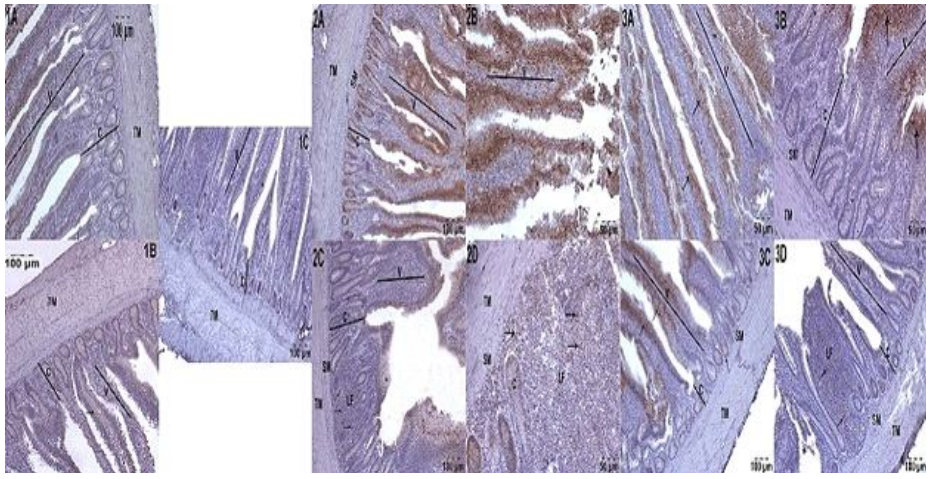

1A: Control duodenum, 1B: Control jejunum, 1C: Control İleum, C: Crypt, V: Villus, TM: Tunica muscularis, arrow: Lymph follicle.

2A: Heat stress duodenum, 2B: Heat stress jejunum, 2C: Heat stress ileum, 2D: Heat Stress Lymph follicle in ileum, C: Crypt, V: Villus, TM: Tunica muscularis, SM: Submucosa, LF: Lymph follicle, arrow: Immuno-positive cells in lymph follicle.

3A: Heat stress+E Vit duodenum,3B: Heat stress+E Vit duodenum,3C: Heat stress+E Vit jejunum, 3D: Heat stress+ E Vit ileum, C: Crypt, V: Villus, TM: Tunica muscularis, SM: Submucosa, LF: Lymph follicle, arrow: Immuno-positive cells.

Fig 1-3: Distribution of Caspase-9 immuno-reactivity in duodenum, jejunum and ileum.

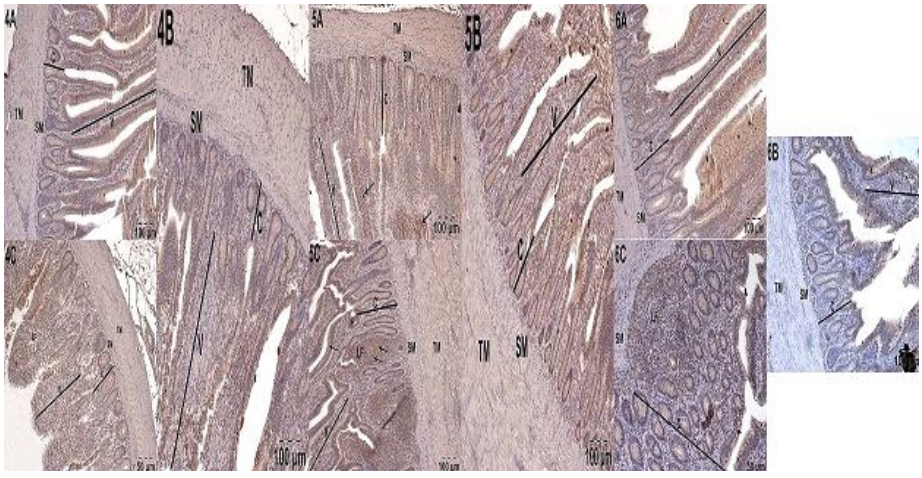

4A: Control duodenum, 4B: Control jejunum, 4C: Control İleum, C: Crypt, V: Villus, TM: Tunica muscularis, SM: Submucosa, LF: Lymph follicle.

5A: Heat stress duodenum, 5B: Heat stress jejunum,5C: Heat Stress ileum, C: Crypt, V: Villus, TM: Tunica Muscularis, SM: Submucosa, LF: Lymph follicle, arrow: Immuno-positive cells.

6A: Heat stress+E Vit duodenum, 6B: Heat stress+E Vit jejunum,6C: Heat stress+ E Vit ileum, C: Crypt: Villus: Tunica Muscularis, SM: Submucosa, LF: Lymph follicle.

Fig 4-6: Distribution of Caspase-8 immunoreactivity in duodenum, jejunum and ileum.

jejunum in the heat stress group (Fig 5B). Strong immuno-reaction was observed in the villi and lymph follicles, while negative immuno-reaction was observed in the crypts. (Fig 5C). Negative or weak immuno-reaction was observed in the crypts of the duodenum (Fig 6A), jejunum (Fig 6B) and ileum (Fig 6C) in the Heat stress + vitamin E group. There was a moderate immuno-reaction in the lymph follicles (Fig 6C) (Table 2).

TNF-α immunostaining findings

As for TNF-α, a weak immuno-reaction was observed in the villi, crypt epithelium and lymph follicles in the duodenum (Fig 7A), jejunum (Fig 7B) and ileum (Fig 7C) in the control group. A moderate immuno-reaction was found in all parts of the duodenum (Fig 8A) while weak immuno-reaction was observed in the villi, crypt and lymph follicles in the jejunum (Fig 8B) and ileum (Fig 8C) in the heat stress group. The reaction was less than heat stress in all regions of the duodenum in the Heat stress + vitamin E group (Fig 9A). The immuno-reaction in the jejunum was found to be not much different compared to heat stress (Fig 9B). A weak immuno-reaction was observed in both villi and crypt of the ileum in de Heat stress + vitamin E group (Fig 9C) (Table 3).

IL-6 immunostaining findings

Regarding IL-6, weak positivity was observed in the cytoplasm in all areas in the duodenum (Fig 10A) and jejunum (Fig 10B) in the control group. In the ileum, weak immuno-reaction was observed in the lymph follicles, but there was a moderate immuno-reaction in the villi (Fig 10C). A weak reaction was observed in all areas in all three regions in the Heat stress group (Fig 11A, 11B, 11C). All regions in the Heat stress + vitamin E group exhibited immuno-reaction similar to the control (Fig 12A, 12B, 12C) (Table 4).

Caspases are a conserved family of cysteine-aspartic proteases that mediate programmed cell death and inflammation (Avrutsky and Troy, 2021). Caspase-9, as the most extensively studied initiator caspase, is an important factor in the intrinsic or mitochondrial pathway involved in various stimuli, including chemotherapies, stress agents and radiation (Li *et al*., 2017). Miao *et al*. (2020) found no significant variation in the protein levels of caspase 3 and

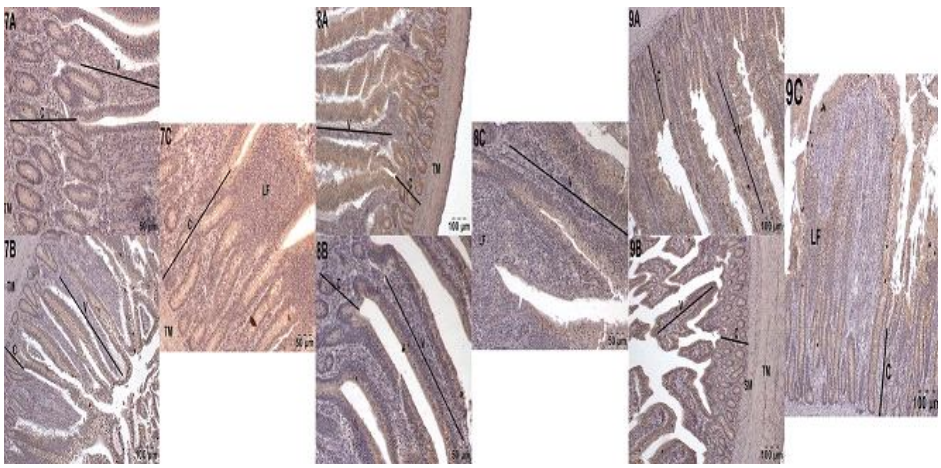

7A: Control duodenum, 7B: Control jejunum, 7C: Control İleum, C: Crypt, V: Villus, TM: Tunica muscularis 7 LF: Lymph follicle

Heat stress duodenum, 8B: Heat stress jejunum, 8C: Heat Stress ileum, C: Crypt, V: Villus, TM: Tunica muscularis, LF: Lymph follicle.

9A: Heat stress+E Vit duodenum, 9B: Heat stress+E Vit jejunum, 9C: Heat Stress+E Vit ileum, C: Crypt, V: Villus, TM: Tunica muscularis, SM: Submucosa, LF: Lymph follicle.

Fig 7-9: Distribution of TNF-α immunoreactivity in duodenum, jejunum and ileum.

Table 2: Semi-quantitative caspase-8 immuno-reactivity in duodenum, jejunum and ileum.

Groups	D		J		I		
	V	C	V	C	V	LF	C
Cnt	+	+-	+	+-	++	++	+-
Heat	++	+	+	+	+++	+++	-
Heat+VE	+-	-	+-	-	+	++	-

Negative: - [<1% positive]; Weak: + [1-25% positive]; moderate: ++ [>25-75% positive] and strong: +++ [>75% positive]. D: Duodenum, J: Jejunum, I: Ileum, Cnt: Control, V: Villus, C: Crypt, LF: Lymph follicle.

caspase 9 in the livers of broilers that were exposed to a maximum temperature of 35°C for 6 hours. Aengwanich and Wandee (2022) examined the blood cells of broilers at different temperature ranges. They found that caspase-9 and caspase-3 activities decreased at 42-43°C, but caspase 9 and caspase 3 activities increased at 44-45°C and higher temperatures. This was attributed to the increase in heat shock proteins (HSP70) against heat stress at temperatures between 42 and 43°C and the suppression of apoptosis by that increase. Caspase-9 activity was observed to be positive only in epithelial cells in all groups in the present study. The heat stress group in this study was exposed to heat stress at 35°C (5 hours/day). Caspase-9 activity was found to increase significantly in all small intestinal sections of the animals in the heat stress group. Unlike, Miao *et al*. (2020), it was considered that the increase in caspase-9 activity in the intestines at 35°C may be caused by two reasons. The first one is due to the small intestinal epithelium being the most rapidly affected part of the intestinal epithelium by environmental factors and the second one may be the

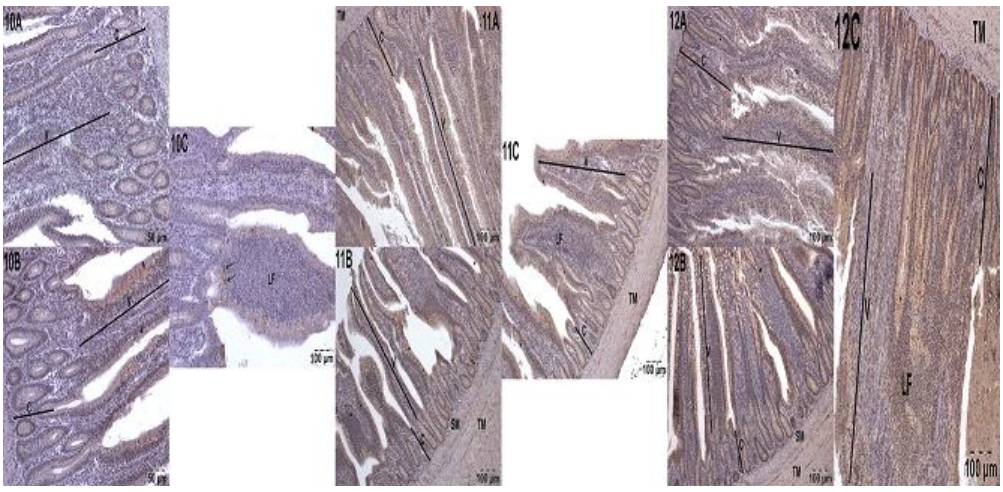

10A: Control duodenum,10B: Control jejunum,10C: Control ileum, C: Crypt, V: Villus, TM: Tunica Muscularis, SM: Submucosa, LF: Lymph follicle, arrow: Immuno-positive cells.
11A: Heat stress duodenum,11B: Heat stress jejunum,11C: Heat stress ileum, C: Crypt, V: Villus, TM: Tunica Muscularis, SM: Submucosa, LF: Lymph follicle.
12A: Heat stress+ E Vit duodenum, 12B: Heat stress+ E Vit jejunum, 12C: Heat stress+ E Vit ileum, C: Crypt, V: Villus, TM: Tunica Muscularis, SM: Submucosa, LF: Lymph follicle.

Fig 10-12: Distribution of IL-6 immunoreactivity in duodenum, jejunum and ileum.

Table 3: Semi-quantitative TNF-α immuno-reactivity in duodenum, jejunum and ileum.

Groups	D		J		I	
	V	C	V	C	V	C
Cntr	+	+	+	+-	+	-
Heat	++	++	+	+-	+	+-
Heat+VE	+-	+-	+-	+-	+	+-

Negative: - [<1% positive]; weak: + [1-25% positive]; moderate: ++ [>25-75% positive]; and strong: +++ [>75% positive]. D: Duodenum, J: Jejunum, I: Ileum, Cnt: Control, V: Villus, C: Crypt.

Table 4: Semiquantitative IL-6 immunoreactivity in duodenum, jejunum and ileum.

Groups	D		J		I	
	V	C	V	C	V	C
Cnt	+-	+	+	+-	++	+-
Heat	+-	+	+	+-	+	+-
Heat+VE	+-	+-	+	+-	++	+

Negative: - [<1% positive]; Weak: + [1-25% positive]; Moderate: ++ [>25-75% positive] and strong: +++ [>75% positive]. D: Duodenum, J: Jejunum, I: Ileum, Cnt: Control, V: Villus, C: Crypt.

exposure of the experimental group to heat stress for a long period of time as three weeks. However, caspase-9 activity in the vitamin E-supplemented group reacted closely to the control group.

Caspase-8 is the first cysteine protease identified as an apical caspase that triggers exogenous apoptosis (Muzio *et al*., 1996). Caspase-8 activates other caspases such as caspase-3-7-9 to initiate apoptosis and thus induce apoptosis (Aral *et al*., 2019). Imao *et al*. (2006) discovered that recurrent heat stress increased caspase-8 activity while studying apoptosis that heat stress induced in mouse liver. The present study revealed that caspase-8 activity increased in both epithelial and connective tissue in chicken intestines that were exposed to heat stress at 35°C (5 hours/day). However, vitamin E was observed to increase the caspase activity closer to the control group. This indicates that vitamin E showed antioxidant activity by decreasing the rate of increase of caspase-8 in the broiler intestinal epithelium because the control group was not exposed to heat stress.

Under stress conditions such as heat stress, different immune cells secrete pro-inflammatory cytokines (Siddiqui *et al*., 2020). TNF-α is reported to increase in egg-laying hens under heat stress, resulting in a decrease in the number of follicles and egg production in the ovary (Li *et al*., 2020). However, Lendez *et al*. (2021) found that the expression of TNF-α and its receptors decreased in dairy cattle under heat stress conditions. They argued in their study that the immune system of animals was affected by heat stress and that animals that are physiologically unable to resist high temperatures may have a less effective immune response and therefore may be more susceptible to opportunistic infections. It is reported that exposure of broilers to both acute and chronic heat stress can elevate serum corticosteroid levels and induce intestinal inflammation (Quinteiro-Filho *et al*., 2012). Tang *et al*. (2021) reported that the levels of TNF-α and caspase-1 protein in the duodenum and ileum of poultry were significantly increased by heat stress. Duodenum in particular was reported to be more susceptible to heat stress-induced inflammation than other parts of the small intestine. It was observed in the present study that heat stress increased TNF-α activity in all three parts of the small intestine in broilers, especially in the duodenum. However, TNF-α activity in the group with vitamin E was found to be closer to the control group like caspase 8.

IL-6 is reported to be produced by immune-mediated cells, mesenchymal cells, vascular endothelial (VE) cells, fibroblasts and many other cells under physiological and pathological conditions (Tanaka *et al*., 2014). In 42-day-old chickens, heat stress was observed to raise the serum concentration of IL-6. This was reported to be a systemic inflammatory response (Li *et al*., 2020). The increase in IL-6 induced by stress was observed to decrease in the jejunum but not the ileum when Galacto-oligosaccharide was introduced to the diets of chickens kept under heat stress conditions. It was stated that a difference in the micro-biota composition between the ileum and jejunum may be the cause of the more severe heat-induced damage observed in the ileum (Varasteh *et al*., 2015). In the present study, it was observed that heat stress at 35°C (5 h/day), which started in the 4th week and ended in the 6th week after incubation, caused no difference between the groups in the level of IL-6 in all sections of the small intestine. However, IL-6 activity was higher in the ileum in all groups but not in all regions. This supports that the difference in micro-biota composition causes IL-6 activity to be higher in the ileum, as stated by Varasteh *et al*. (2015).

The intestinal mucosa has a unique position in mucosal immunity and exhibits complex defense mechanisms (Wu *et al*., 2016). This study put forth the effects of heat stress and vitamin E given for protection on TNF- α, IL-6, caspase-9 and caspase-8 in the duodenum, jejunum and ileum mucosa of broilers. It is of primary significance to expel damaged cells from the healthy medium to inhibit proliferative diseases in the life cycle (Li *et al*., 2017).

CONCLUSION

It would be of great benefit for animal nutritionists to better understand the intestinal mucosa of broilers, which plays a major role in nutrition since it is cost effective. This study revealed that exposure to heat stress at 35°C (5 h/day) for three weeks induced apoptosis in intestinal epithelial cells and connective tissue, but no acute systemic inflammatory response. This result suggested that prolonged heat stress at low temperatures was not sufficient to induce an acute response.

Over the last few years, the effects of antioxidants such as vitamin E on gene expressions have been introduced. Such dietary supplements can significantly stimulate antioxidant-related gene activations. Exposure to long-term heat stress at low temperatures may cause cellular damage, such as increased apoptosis, even though it does not cause systemic inflammation in the organism.

In conclusion, the study revealed that adding vitamin E to the rations regularly can be effective in preventing possible cellular damage.

ACKNOWLEDGEMENT

This research received no specific grant from any funding agencies in the public, commercial, or not-for-profit sectors.

Conflict of interest

The authors declare that there is no conflict of interest.

REFERENCES

Aengwanich, W. and Wandee, J. (2022). The effect of increased ambient temperature on Hsp70, superoxide dismutase, nitric oxide, malondialdehyde and caspase activity in relation to the intrinsic and extrinsic apoptosis pathway of broiler blood cells. Journal of Thermal Biology. 105. doi.org/10.1016/j.jtherbio.2022.103211.

Aral, K., Aral, C.A., Kapila, Y. (2019). The role of caspase-8, caspase-9 and apoptosis inducing factor in periodontal disease. Journal of Periodontology. 90(3): 288-294. doi: 10.1002/JPER.17-0716.

Avrutsky, M. and Troy, C. (2021). Caspase-9: A Multimodal therapeutic target with diverse cellular expression in human disease. Frontiers in Pharmacology. 9(12): 701301. doi: 10.3389/fphar.2021.701301.

Bianchi, A.T.J., Zwart, R.J., Jeurissen, S.H.M., Moonen-Leusen, H.W.M. (1992). Development of the B and T cells compartments in porcine lymphoid organs from birth to adult life: An immunohistological approach. Veterinary Immunology and Immunopathology. 33(3): 201-221. doi: 10.1016/0165-2427(92)90182-p.

Brentnall, M., Rodriguez-Menocal, L., De Guevara, R.L., Cepero, E., Boise, L.H. (2013). Caspase-9, caspase-3 and caspase-7 have distinct roles during intrinsic apoptosis. BMC Cell Biology. 14: 32. http://www.biomedcentral.com/1471-2121/14/32.

Imao, M., Nagaki, M., Moriwaki, H. (2006). Dual effects of heat stress on tumor necrosis factor-α-induced hepatocyte apoptosis in mice. Lab Invest. 86: 959-967. https://doi.org/10.1038/labinvest.3700451.

Jackson, P. and Blyhe, D. (1995). Immunolabelling Techniques for Light Microscopy. In: [Beesley, J.E. (Ed.)] Immunocytochemistry, Oxford University Press. p: 15-41.

Khan, R.U., Rahman, Z.U., Nikousefat, Z., Javdani, M., Tufarelli, V., Dario, C., Selvagg, M., Laudadio, V. (2012). Immunomodulating effects of vitamin E in broilers. World's Poultry Science Journal. 68(1): 31-40. doi.org/10.1017/S0043933912000049.

Lara, L.J. and Rostagno. M.H. (2013). Impact of heat stress on poultry production. Animals. 3: 356-369. doi: 10.3390/ani3020356.

Lendez, P.A., Cuesta, L.M., Farias, M.V.N., Vater, A.A., Ghezzi, M.D., Mota-Rojas, D., Dolcini, G.L., Ceriani, M.C. (2021). Alterations in TNF-α and its receptors expression in cows undergoing heat stress. Veterinary Immunology and Immunopathology. 235: 110232. doi.org/10.1016/j.vetimm.2021.110232.

Leshchinsky, T.V. and Klasing, K.C. (2001). Relationship between the level of dietary vitamin E and the immune response of broiler chickens. Poultry Science. 80: 1590-1599. doi:10.1093/ps/80.11.1590.

Li, G.M., Liu, L.P., Yin, B., Liu, Y.Y., Dong, W.W., Gong, S., Zhang, J., Tan, J.H. (2020). Heat stress decreases egg production of laying hens by inducing apoptosis of follicular cells *via* activating the FasL/Fas and TNF-α systems. Poultry Science. 99: 6084-6093. doi.org/10.1016/j.psj.2020.07.024.

Li, P., Zhou, L., Zhao, T., Liu, X., Zhang, P., Liu, Y., Zheng, X., Li, Q. (2017). Caspase-9: Structure, mechanisms and clinical application. Oncotarget. 8(14): 23996-24008. doi: 10.18632/oncotarget.15098.

Li, Q., Wan, G., Peng, C., Xu, L., Yu, Y., Li, L., Li, G. (2020). Effect of probiotic supplementation on growth performance, intestinal morphology, barrier integrity and inflammatory response in broilers subjected to cyclic heat stress. Animal Science Journal. 91: e13433. doi:10.1111/asj.13433.

Miao, O., Si, X., Xie, Y., Chen, L., Liu, Z., Liu, L., Tang, X., Zhang, H. (2020). Effects of acute heat stress at different ambient temperatures on hepatic redox status in broilers. Poultry Science. 99: 4113-4122. doi.org/10.1016/j.psj.2020.05.019.

Molnar, T., Pallagi, P., Balint, T., Kir, R., Csoma, E., Jenei, V., Varga, Z., Gogol, P., Hueber, A.O., Zoltan, M., Erdelyi, F., Szab, G., Szandtner, A.P., Bacsi, A., Vir, L., Mal, J., Koncz, G. (2021). Caspase-9 acts as a regulator of necroptotic cell death. The FEBS Journal. 288: 6476-6491. doi: 10.1111/febs.15898.

Muzio, M., Chinnaiyan, A.M., Kischkel, F.C., O'Rourke, K., Shevchenko, A., Ni, J., Scaffidi, C., Bretz, J.D., Zhang, M., Gentz, R., Mann, M., Krammer, P.H., Peter, M.E., Dixit, V.M. (1996). FLICE, a novel FADD-homologous ICE/CED-3-like protease, is recruited to the CD95 (Fas/APO-1) death-inducing signaling complex. Cell. 85: 817-827. doi: 10.1016/s 0092-8674(00)81266-0.

Nunez, G., Benedict, M., Hu, Y., Inohara, N. (1998). Caspases: The proteases of the apoptotic pathway. Oncogene. 17: 3237-3245. https://doi.org/10.1038/sj.onc.1202581.

Quinteiro-Filho, W.M., Gomes, A.V.S., Pinheiro, M.L., Ribeiro, A., Ferraz-de-Paula, V., Astolfi-Ferreira, A.J., Palermo-Neto, J. (2012). Acute heat stress impairs performance parameters and induces mild intestinal enteritis in broiler chickens: Role of acute HPA axis activation. Journal of Animal Science. 90(6): 1986-1994. doi.org/10.2527/jas.2011-3949.

Siddiqui, S.H., Kang, D., Park, J., Khan, M., Shim, K. (2020). Chronic heat stress regulates the relation between heat shock protein and immunity in broiler small intestine. Scientific Reports. 10: 18872. doi.org/10.1038/s41598-020-75885-x.

Tang, L.P., Li, W.H., Liu, Y.L., Lun, J.C., He, Y.M. (2021). Heat stress aggravates intestinal inflammation through TLR4-NF-kB signaling pathway in Ma chickens infected with *Escherichia coli* O157: H7. Poultry Science. 100(5): 101030. doi.org/10.1016/j.psj.2021.10103.

Tanaka, T., Narazaki, M., Kishimoto, T. (2014). IL-6 in inflammation, immunity and disease. Cold Spring Harbor Perspectives Biology. 4: 6(10): a016295. doi: 10.1101/Cshperspect.a016295.

Wu, B., Guo, H., Cui, H., Peng, X., Fang, J., Zuo, Z., Deng, J., Wang, X., Huang, J. (2016). Pathway underlying small intestine apoptosis by dietary nickel chloride in broiler chickens. Chemico-Biological Interactions. 5(243): 91-106. doi: 10.1016/j.cbi.2015.11.010.

Varasteh, S., Braber, S., Akbari, P., Garssen, J., FinkGremmels, J. (2015). Differences in susceptibility to heat stress along the chicken intestine and the protective effects of galactoo ligosaccharides. PLOS ONE. 10(9): e0138975. doi: 10.1371/journal.pone.0138975.