RESEARCH ARTICLE Indian Journal of Animal Research, Volume 57 Issue 11: 1438-1447 (November 2023)

Myrrh Attenuates Gonadal Toxicity and DNA Fragmentation Induced by Ethanol in Male Rats

Abeer Alahmari[1,2]

10.18805/IJAR.BF-1691

ABSTRACT

Background: Long-term ethanol consumption causes pathological alterations to the male reproductive system, possibly resulting in infertility. Myrrh is a resin with antioxidant properties that is produced from the bark of *Commiphora* tree species. This research aimed to observe the protective impact of myrrh extract supplementation on male reproductive injury and toxicity induced by ethanol treatment.

Methods: Adult male Sprague Dawley rats were orally treated with 40% ethanol (3 g/kg) in combination with myrrh extract (500 mg/kg) for four weeks to investigate the curative efficiency of myrrh extract against ethanol toxicity from physiological, histopathological and genetic aspects.

Result: The findings revealed that the sperm count, testosterone level and DNA concentration diminished significantly in the ethanol-treated rats compared to control rats, while the contents of malondialdehyde (MDA), heat shock protein 70 (HSP70) and proinflammatory mediators, including tumor necrosis factor-α (TNF-α) and nitric oxide (NO), were elevated significantly; severe degenerative changes in the testicular structure and strong testicular DNA fragmentation were also observed. Co-treatment with myrrh attenuated lipid peroxidation and improved testicular histomorphology, testosterone levels and DNA concentrations and pattern, while at the same time, the levels of both HSP70 and TNF-α levels were increased. Our results provide insight into the curative impacts of myrrh on ethanol toxicity resulting from the rich content of curzerene in myrrh, which has antioxidant activities.

Key words: Ethanol, Inflammation, Myrrh, Testis, Testosterone.

INTRODUCTION

Infertility is usually described as a reproductive disorder characterized by the inability to achieve pregnancy after one year of frequent unprotected intercourse (Vander and Wyns, 2018). Approximately 15% of all couples of reproductive ages worldwide suffer from infertility. About 20-30% of infertility is thought to be associated with male factors such as declining semen quality (Kumar and Singh, 2015). Reproductive health is influenced by several factors, including environmental, hereditary, physiological and social variables. Chemicals, radiation and heavy metal exposure are among the environmental factors. In addition, lifestyle choices such as nutrition, smoking and alcohol consumption significantly impact reproductive health due to their crucial influences on spermatogenesis and hormonal regulation (Sharma *et al*., 2013).

Chronic ethanol exposure in the male reproductive system is known to produce toxic impacts, leading to sexual impairment that may result in infertility (Agbodjento *et al*., 2021). Chronic ethanol exposure has been shown to promote germ cell death, leading to sterility through various pathways, including oxidative stress, mitochondrial malfunction and the overexpression of inducible nitric oxide synthase (iNOS) (Eid *et al*., 2018). Other studies in adult male rats reported that acute exposure to ethanol leads to an increase in the rate of autophagy in Sertoli cells, which is accompanied by elevated apoptosis of germ cells, inhibition of androgen receptors in somatic cells of testes and improved iNOS production in Sertoli cells (Horibe *et al*., 2017). The process associated with ethanol intake and decreased sperm integrity is linked to the depression of nicotinamide adenine dinucleotide along with the synthesis of reactive oxygen species (ROS), subsequently affecting testosterone metabolism and spermatogenesis (Muthusami and Chinnaswany, 2005).

There has been significant interest in many medicinal plants in the field of bioremediation because they contain active compounds and antioxidants that reduce the oxidative damage caused by free radicals (Akbari *et al*., 2017). In Saudi society, myrrh is a commonly used herb in traditional medicine. It is a yellowish aromatic oleo gum resin produced from the tree bark of *Commiphora* species, endemic to dry areas such as the Middle East, India and Africa (Haffor, 2010). Since ancient times, myrrh resin has been utilized

[1]Department of Biology, Faculty of Science, King Khalid University, P.O. Box 9004, Abha 61413, Saudi Arabia.
[2]Research Center for Advanced Materials Science (RCAMS), King Khalid University, P.O. Box 9004, Abha 61413, Saudi Arabia.

Corresponding Author: Abeer Alahmari, Department of Biology, Faculty of Science, King Khalid University, P.O. Box 9004, Abha 61413, Saudi Arabia. Email: alahmry@kku.edu.sa

How to cite this article: Alahmari, A. (2023). Myrrh Attenuates Gonadal Toxicity and DNA Fragmentation Induced by Ethanol in Male Rats. Indian Journal of Animal Research. 57(11): 1438-1447. doi: 10.18805/IJAR.BF-1691.

Submitted: 25-08-2023 **Accepted:** 16-09-2023 **Online:** 10-10-2023

as a traditional drug to treat various conditions, such as wounds, stomach pains, fever, obesity and gynecological diseases (Lebda *et al*., 2021). In addition, a literature review revealed that myrrh has anti-inflammatory, anticancer, antimicrobial and antioxidant properties (Khalil *et al*., 2020). These activities may be associated with many of the active compounds found within them. According to previous studies, myrrh is composed of approximately 30%-60% gum, 25%-40% resin and 3%-8% odorous oil (Cao *et al*., 2019).

The discovery of novel curative agents against gonadal toxicity remains a challenge. Despite the interest, no scientific studies have been conducted on the impacts of myrrh on male reproductive disorders caused by alcohol consumption. Therefore, the current study was the first attempt to study myrrh extract's ability to mitigate the adverse effects of ethanol on male gonads in adult rats of physiological, histopathological and genetic aspects.

MATERIALS AND METHODS

The experiment was conducted during the period (2022, April to 2023, January) at Central Lab, Science College, King Khalid University (KKU), Saudi Arabia, Abha. All procedures were performed by the associated EU and ARRIVE guidelines and approved by the Research Ethical Committee of KKU, Abha (approval No. 2022-2125).

Myrrh extract preparation and analysis

The method by which the myrrh extract was prepared was described by El-Sherbiny *et al*. (2013). Myrrh was purchased in resin from a local market in Khamis Mushait, Saudi Arabia. The parts of the myrrh were washed well with distilled water and then ground into fine pieces. Ten grams of ground myrrh were weighed and transferred to a flask filled with 200 ml of deionized water, which was thoroughly mixed and placed in an 80°C water bath for 7 hours. The formed solution was centrifuged for 15 min at 4,000 rpm, filtered with filter paper and stored at 4°C until use. The chemical contents of myrrh were previously analyzed using gas chromatography-mass spectrometry (GC-MS) (Alahmari *et al*., 2022).

Animals and experimental design

Twenty-eight adult male Sprague Dawley rats, 2-3 months old (250-270 g), were acquired from the animal house of the Science College at KKU. The rats were transferred to cages in the animal house under humidity and temperature control (22±2°C) with 12 h light-dark cycles. Then, they were provided ad libitum access to food and water throughout the experiment. The rats were randomly divided into four groups (7 rats each) and orally treated by gastric tube for four weeks. Group I (control): Rats received physiological saline (0.9% NaCl). Group II (Ethanol): Animals received 40% ethanol (3 g/kg). Group III (Myrrh): Animals received 500 mg/kg of myrrh extract. Group IV (Ethanol+Myrrh): Animals received myrrh extract (500 mg/kg) two hours after the administration of 40% ethanol (3 g/kg). The doses of ethanol and myrrh were determined based on previous studies (Hosseini *et al*., 2017; Shalaby and Hammouda, 2014), respectively.

Twenty-four hours after the end of treatment, the rats in all groups were sacrificed under ether anesthesia. Blood samples were collected by heart puncture and then serum was separated and stored at -80°C until use. The testes and epididymis were removed and prepared for the following analysis.

Epididymal sperm count

For sperm count, the caudal epididymis was ground in 5 mL of saline, placed in a rocker for 10 minutes and incubated for 2 minutes at room temperature. The resulting supernatant was diluted 1:100 with a solution containing 100 mL of distilled water, 1 mL of 35% formalin, 5 g of $NaHCO_3$ and 25 mg of eosin. Approximately 10 µL of the diluted sperm suspension was placed on a Neubauer hemocytometer and left for 5 minutes. Then, the sperm were counted under a light microscope at high magnification and the results were expressed as $\times 10^6$ sperm/mL (Yokoi *et al*., 2003).

Testicular tissue homogenization

The right testis of each rat was rapidly excised and washed with saline to remove any blood. Then, each testis was homogenized in 100 mM phosphate buffer containing 1 mM EDTA (pH 7.4) and centrifuged at 12000× g for 30 min at 4°C (Shahin *et al*., 2018). The supernatant was stored at -80°C until use in the following biochemical examination.

Biochemical analysis

Testosterone assay

The serum testosterone concentration (ng/mL) in rats was measured using a Testosterone ELISA kit (cat. no. ab108666; Abcam, Cambridge, England) following the manufacturer's protocol. The amount of testosterone in serum was determined by measuring the intensity of the signal at 450 nm.

Estimation of lipid peroxidation

The malondialdehyde (MDA) level in the testicular tissue supernatant was measured as markers of lipid peroxidation (LPO) using commercial kits (cat. nos. ab238537; Abcam, Cambridge, England) according to the manufacturer's instructions. Using a microplate reader, the quantities of MDA were determined by measuring the absorbance at 450 nm and expressed as pmol/mg.

Measurement of heat shock protein 70 (hsp70) levels

Quantitative measurements of HSP70 levels (ng/mg) in testicular tissue obtained from all rats were determined using an HSP70 ELISA Kit (cat. no. ab133060; Abcam, Cambridge, England) to evaluate the cellular response to stress factors following the manufacturer's protocol. The optical density (OD) (absorbance) was measured at 450 nm using a microplate reader.

Measurement of proinflammatory mediator production

The production of tumor necrosis factor-α (TNF-α) and nitric oxide (NO) were assayed as indicators of inflammation using commercially available ELISA kits (cat. nos. ab236712 and ab65328, respectively; Abcam, Cambridge, England) according to the manufacturer's protocols. The quantities of TNF-α and NO in the testicular samples were determined by measuring the absorbance at 450 nm using a microplate reader. TNF-α and NO values are expressed as pg/mg and nmol/mg, respectively.

Histological examinations

Portions of the left testis of each animal were rapidly removed after euthanasia. The tissues were immediately fixed in 10% formalin for at least 48 hours, dehydrated in a graded series of alcohol, embedded in paraffin wax and cut using a microtome into 5 ìm thick sections. For photo-microscopic assessment, paraffin-embedded sections were stained with hematoxylin and eosin (H&E). The observed histopathological changes and damage in testicular tissue and spermatogenesis were analyzed according to Johnsen's mean testicular biopsy score (MTBS) criteria. For these assessments, the MTBS was estimated from 100 seminiferous tubules in each group (5 rats each) by a digital microscope (Omax-M837ZL, China). Each tubule was given a score from 1 (no cells in the seminiferous tubules) to 10 (complete spermatogenesis) (Johnsen, 1970).

Testicular DNA content and fragmentation

To determine whether co-treatment with myrrh would protect DNA from degradation, DNA was extracted from tissue sections obtained from testicular biopsies of all rats. Multiple 5-µm thick sections from each block were placed into DNAse-free RNAse-free 1.5 mL microcentrifuge tubes. The Gsync™ DNA Extraction Kit (Geneaid Biotechnology, New Taipei City) was used according to the manufacturer's recommendations to extract genomic DNA from each of the pelleted cell suspensions. The concentration and purity of each DNA sample were assessed by analyzing 1 µL of elute with a NanoDrop 1000 UV VIS spectrophotometer (Thermo Fisher Scientific, Massachusetts). To evaluate the integrity of the extracted DNA, we loaded 5 µL of each sample onto a 1.5% gel using the M12 Complete Electrophoresis Package (Edvotek Inc., Washington) for 40 min at 90°C. The bands were visualized under UV light using the ChemiDoc-It2 Imaging System (Analytik Jena, Thuringia).

Statistical analysis

All data are expressed as the mean ± standard error (SE) using one-way analysis of variance (ANOVA) in SPSS 16 statistical software (Chicago, Illinois, USA). Statistical differences were considered significant at the $P \leq 0.05$ level by using Tukey's multiple range test procedure.

RESULTS AND DISCUSSION

Epididymal sperm count

As shown in Table 1, ethanol intake significantly decreased the sperm count ($P \leq 0.0001$) in rats compared with the control. However, myrrh treatment alone had no significant effect on sperm count and this parameter was too close to the control. Additionally, administering myrrh with ethanol revealed a slight improvement in sperm count.

Testosterone level

The results presented in Table 1 show a statistically significant reduction in serum testosterone levels ($P \leq 0.0001$) in ethanol-treated rats compared to those in control animals. In contrast, treatment with myrrh alone resulted in no significant change in the level of testosterone in comparison to the control. Overall, coadministration of myrrh and ethanol significantly improved testosterone levels ($P \leq 0.01$) compared to those in the ethanol group.

Estimation of lipid peroxidation

The levels of lipid peroxidation marker (MDA) in the testicular tissues of all experimental animals are summarized in Table 1. MDA level was significantly increased ($P \leq 0.0001$) in the ethanol-treated group compared to those in the control group. Compared to ethanol intake alone, this level was depleted considerably after combined ethanol and myrrh treatment ($P \leq 0.05$). No significant difference in MDA level was observed between the myrrh-treated and control groups.

Table 1: Effects of treatment with ethanol and/or myrrh on sperm count, testosterone, MDA, HSP70, TNF-α, NO and DNA values.

Parameters	Experimental groups			
	Control	Ethanol	Myrrh	Ethanol+myrrh
Sperm count (×10^6 sperm/mL)	97.08±3.99	68.10±5.09****	93.45±3.50	78.10±1.84
Testosterone (ng/mL)	2.67±0.12	1.60±0.06****	2.79±0.17	2.38±0.15##
MDA (pmol/mg)	16.73±1.43	41.78±5.90****	18.84±3.06	32.22±6. 46#
HSP70 (ng/mg)	60.66±3.75	94.36±5.38**	61.72±4.94	111.85±7.14
TNF-α (pg/mg)	143.5±5.2	195.6±9.32****	225.99±7.88	309.91± 9.97####
NO (nmol/mg)	100.9±7.02	136.88±6.17**	98.58±7.97	123.14±6.86
DNA concentration (ng/µL)	151.04±39.88	65.69±36.45*	157.82±13.48	143.75±20.05#

Means±SE of 7 animals in each group. Significant differences are statistically indicated by (*) *vs*. control group; (#) *vs*. ethanol-treated group.

Measurement of HSP70 production

In the ethanol-treated group, the concentration of HSP70 was found to be significantly ($P \leq 0.0001$) elevated compared with that in the control group. Co-treatment with myrrh did not attenuate the effect of ethanol on HSP70 production, as its level was significantly increased ($P \leq 0.0001$) compared with that in the control group. There was no significant difference between the concentration of HSP70 after treatment with myrrh only when compared with the control group (Table 1).

Measurement of TNF-α and NO production

The data indicated a significant increase in the production of TNF-α in the testes obtained from all experimental groups compared to control ($P \leq 0.0001$). Regarding the NO level, the ethanol administration induced a significant increase in NO production ($P \leq 0.01$) compared to the control. No significant change was recorded in this parameter after treatment with myrrh alone compared to the control. On the other hand, the combined treatment of ethanol with myrrh slightly attenuated the production of NO when compared with the ethanol intake only (Table 1).

Histological analysis

The mean MTBS values for the testes obtained from the control and experimental groups are illustrated in Fig 1. The MTBS of the ethanol-treated testes was significantly lower than that of the control and ethanol-myrrh-treated groups. However, co-treatment of ethanol with myrrh resulted in a significant increase in MTBS. On the other hand, the MTBS value for the rat testes after treatment with myrrh alone was near that in the control group.

The testes from the control rats appeared to have a normal histological morphology with a regular seminiferous tubule structure. The seminiferous tubules were rounded and surrounded by interstitial connective tissue containing interstitial Leydig cells and blood vessels (Fig 2a). Additionally, the germinal epithelium lining each seminiferous tubule was thick and intact and cells in different phases of spermatogenesis (spermatogonia, primary and secondary spermatocytes, spermatids and sperm) were buried closer to the lumen with the outermost layer of supporting Sertoli cells (Fig 2b). Similarly, no significant histological changes were observed in the testes of the rats treated with 500 mg/kg myrrh only compared to those in the control tissue sections (Fig 2c and d).

In contrast, treatment with ethanol caused severe degenerative changes in the testicular structure represented by erosion in some regions of the tunica albuginea, the absence of septa between the seminiferous tubules, which led to interference in the tubules, intertubular edema, necrosis of the seminiferous tubules with increased empty areas and a lack of several types of spermatogenic cells (incomplete spermatogenesis) with cleavage of cohorts of germ cells from the seminiferous epithelium released into the lumen as clusters (Fig 3 a-d). Additionally, the interstitial tissue was expanded and vacuolized. However, co-treatment with myrrh led to a significant reduction in the histopathological changes caused by ethanol and significantly improved the pattern of the seminiferous tubules and phases of spermatogenesis, with mild necrosis remaining in some areas (Fig 4 a and b).

Effects of different treatments on testicular DNA content and fragmentation

The data presented in Table 1 illustrate that treatment with ethanol harmed the DNA in testicular tissue; ethanol induced a significant decrease in testicular DNA content ($P \leq 0.05$) compared to the control. Moreover, the concentration of testicular DNA from rats treated with myrrh alone was near that of the untreated control group ($P > 0.05$). On the other hand, co-treatment with myrrh extract plus ethanol led to a

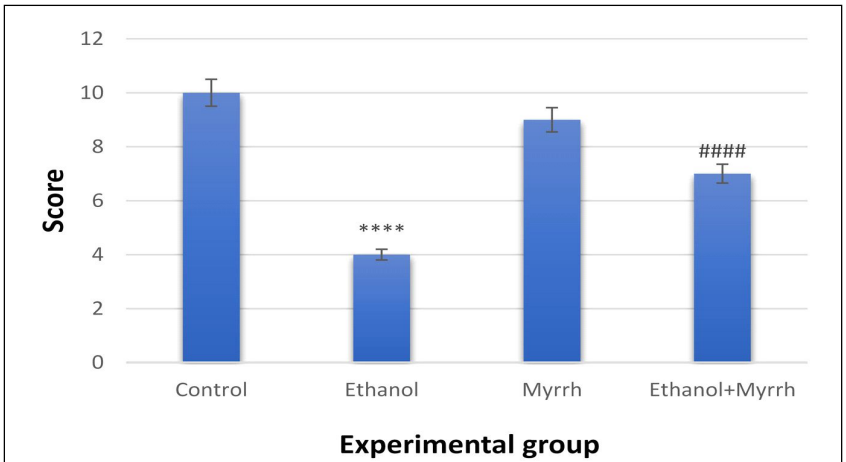

All values are expressed as the mean±SE of n=5. ****$p \leq 0.0001$ *vs.* control; #### $p \leq 0.0001$ *vs.* ethanol-treated rats.

Fig 1: The mean Johnsen's testicular biopsy score (MTBS) in the control and experimental groups.

significant restoration in the concentration of DNA compared to ethanol intake only ($P \leq 0.05$).

Moreover, DNA fragmentation in testicular tissue was examined using gel electrophoresis (Fig 5) as a DNA ladder showing a range of fragments (b and 1). When comparing the bands among the experimental groups, the band of the control group (b and 2) was clear and showed more integrity. Ethanol intake (b and 3) resulted in a noticeable pattern of DNA damage, which showed remarkable smearing. In contrast, ingestion of myrrh alone (b and 4) had no adverse effects on the pattern of DNA and did not cause its fragmentation. Co-treatment with myrrh extract plus ethanol improved the pattern of DNA (b and 5) towards more similarity to the control.

The current study's primary purpose was to evaluate myrrh extract's protective effect on male reproductive toxicity induced by ethanol intake. In this research, 40% ethanol administration at a dosage of 3 ml/kg for four weeks led to a significant decrease in the concentration of testosterone in conjunction with a reduction in the count of epididymal sperm compared to the control group. Several scientific researchers have reported similar findings in animals and humans (Borges *et al*., 2018; Sadeghzadeh *et al*., 2019). The release of testosterone is known to be regulated by the hypothalamic-pituitary-gonadal axis (HPG) (Stamatiades and Kaiser, 2018), in which the hypothalamus releases a gonadotropin-releasing factor (GnRF) to bind with its pituitary gland receptors. Consequently, follicle-stimulating hormone (FSH) and luteinizing hormone (LH) are produced. FSH acts on Sertoli cells to enhance sperm production, while LH binds to Leydig cells to promote testosterone synthesis (MacLean *et al*., 2022). Previous research has indicated that alcohol consumption may negatively affect the efficiency of the endocrine system, including the HPG axis, thus inhibiting the production of LH and testosterone (Enebeli *et al*., 2022).

Moreover, other mechanisms may explain how testosterone is reduced after ethanol intake. The harmful impact of ethanol may occur *via* modification of the NO pathway, which eventually indirectly leads to the prevention of GnRH secretion (Finelli *et al*., 2021). In addition, ethanol is involved in increasing the rate of testosterone removal as well as suppressing testosterone synthesis-related enzymes (Talbi *et al*., 2022). Additionally, ethanol intake can stimulate the production of prolactin, causing hypogonadism and the subsequent reduction in gonadal hormones and impaired spermatogenesis (Rachdaoui and Sarkar, 2017).

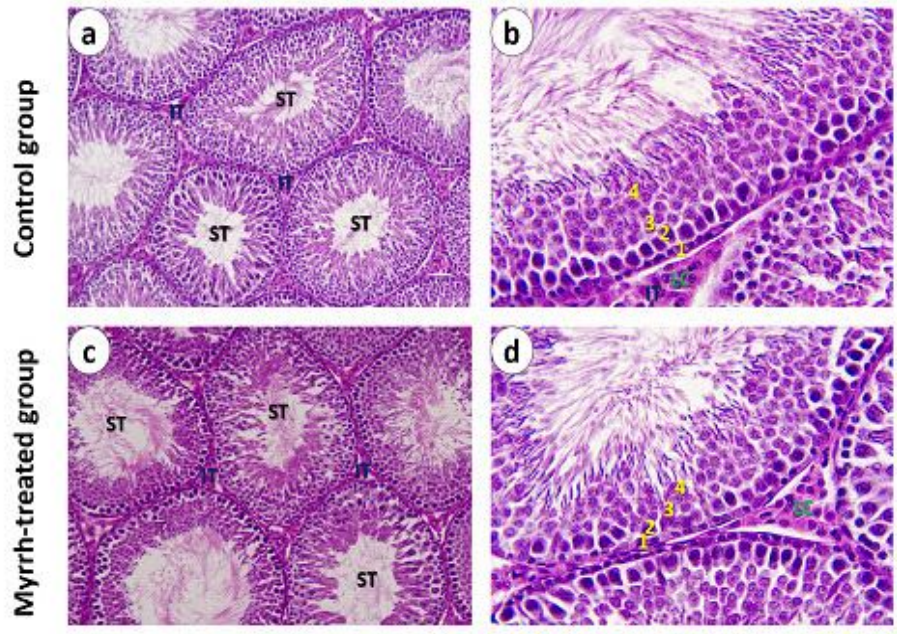

(a) Tissue from the control rats show normal testicular structure, regular seminiferous tubules (ST) and interstitial tissue (IT) (100×). (b) High-magnification image of the control section of seminiferous tubules in which the spermatogenic layers and spermatozoa appeared normal. Spermatogonia (1), 1st spermatocytes (2), 2nd spermatocytes (3) and spermatids (4). The interstitial tissue (IT) contains Leydig cells (LC) (400×). (c) Tissue from the myrrh-treated rats shows an intact seminiferous tubule (ST) structure, as shown in the control (100×). (d) High-magnification image of the seminiferous tubule sections from rats treated with myrrh showing intact germinal epithelium containing cells in various stages of spermatogenesis, as shown in the control (400×). Scale bar= 400 µm.

Fig 2: Photomicrographs of transverse testicular sections stained with HandE from control and myrrh-treated rats.

On the other hand, the above findings were confirmed by the observed severe degenerative changes in the testicular structure along with elevated levels of MDA in testicular tissue after four weeks of ethanol intake as an indicator of oxidative stress. Our findings agree with a previous study performed on rats (Nishi *et al*., 2018), which demonstrated that ethanol induces oxidative stress, resulting in severe consequences on the male reproductive system. Oxidative stress can be stimulated by ethanol through various mechanisms. It promotes reactive oxygen species (ROS) production, essential mediators in different biological events, such as resistance to toxic agents and cell signaling (Yang and Lian, 2020). Several cellular macromolecules, including proteins and lipids, react with ROS, making them very unstable and harming the histological structure of the testes, hence deteriorating the cellular integrity and preventing tissue recovery. Furthermore, the overproduction of ROS alters the redox balance in the cell to create oxidative stress, which is the main factor involved in several pathophysiological disorders (Hussain *et al*., 2021). Additionally, metabolites of ethanol, such as acetaldehyde, apparently induce cellular redox disequilibrium by raising the levels of peroxidation indicators and by lowering cellular antioxidant activities, thereby stimulating germinal cell apoptosis and causing incomplete spermatogenesis and testicular atrophy (Cui *et al*., 2019).

Under oxidative conditions, HSP70 is usually expressed in response to cellular alterations from exposure to toxic agents. Additionally, HSP70 plays an active role in the repair mechanisms of macromolecules and the disposal of unrepairable peptides (Sable *et al*., 2018). Moreover, HSP70 protects cells from apoptosis by binding to the active sites of caspases (Purandhar *et al*., 2014). Thus, HSP70 works together with the active compounds in myrrh to inhibit the ROS that causes cellular insult, which explains the significant increase in the levels of HSP70 in the testicular tissues in both the ethanol-treated and ethanol+myrrh-treated groups in this study. The current findings revealed that ethanol treatment not only promotes oxidative injury but also leads to increased production of NO and TNF-α. According to several studies, we think the oxidative stress produced after ethanol administration can stimulate an inflammatory response that is apparent in the elevation of NO and TNF-α levels in testicular tissues (Horibe *et al*., 2017; Zhang *et al*., 2022).

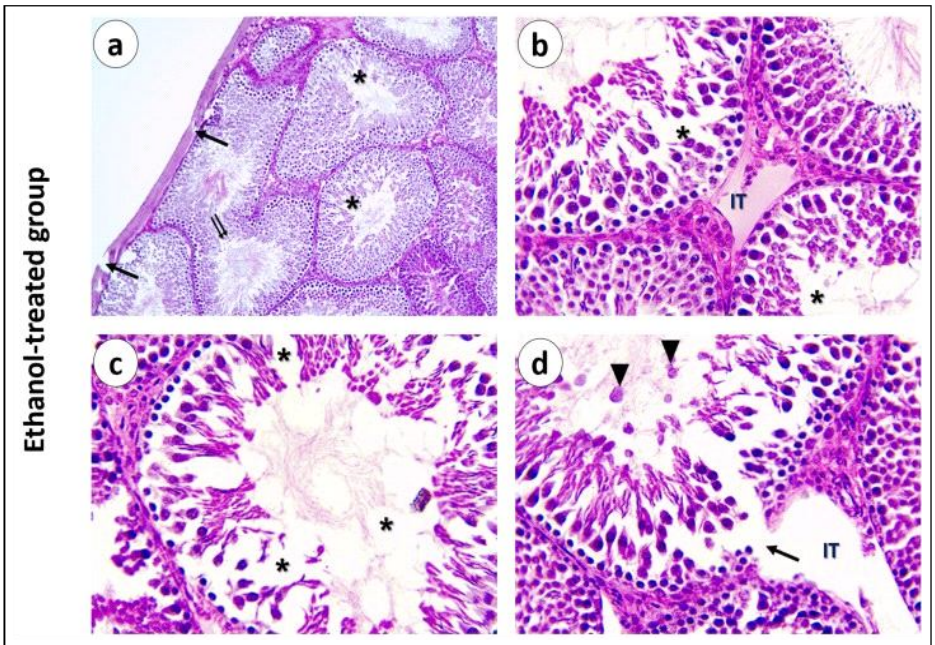

(a) The testicular tissue shows erosion (arrow) in the tunica albuginea layer and necrosis (*) of seminiferous tubules with interference in some seminiferous tubules due to the absence of the septum (double arrow) (100×). (b) High-magnification image of the seminiferous tubules displaying necrosis (*) with increased empty areas and a lack of several spermatogenic cells, as well as intertubular oedema in the interstitial tissue (IT) (400×). (c) High-magnification image of the seminiferous tubules showing severe vacuolated degeneration and a loss of several spermatogenic cells (*) (400×). (d) High-magnification image of the seminiferous tubules illustrating erosion in the septa (arrow), empty space in interstitial connective tissue (IT) and the separation of germ cells and their sloughing off into the lumen (headed arrow) (400×). Scale bar = 400 µm.

Fig 3: Photomicrographs of transverse testicular sections stained with H and E from ethanol-treated rats.

Additional research confirmed that TNF-α is a crucial activator of inflammatory responses and has a broad range of biological impacts, including the induction of NO synthesis (Lampiao and du Plessis, 2008). Elevated TNF-α secretion may ultimately be responsible for increased NO release noticed after ethanol consumption.

Regarding genotoxicity, ethanol treatment caused a significant decrease in testicular DNA concentration along with DNA fragmentation, consistent with the results of Peccerella *et al*. (2018). This finding could be due to the accumulation of ethanol metabolites such as acetaldehyde, which can enhance DNA damage and modify the mRNA expression of specific genes responsible for hormonal control of spermatogenesis, thereby affecting the mitochondrial RNA of spermatozoa and reproductive capacity (Rompala and Homanics, 2019). Moreover, acetaldehyde interacts with DNA and proteins, forming adducts that can promote testicular tissue injury (Zhang *et al*., 2022).

Despite various studies on myrrh's use in treating several diseases, its protective role against testicular toxicity induced by ethanol is not yet clear. Our results showed that the administration of myrrh extract alone did not cause any significant changes in the biochemical parameters, testicular structure, or DNA content compared with those in the control group. This suggests that the intake of myrrh at specific, regulated doses is safe for male gonads. According to Weber *et al*. (2020), myrrh has various therapeutic benefits on the body if used at specific dosages for particular durations. On the other hand, co-treatment of ethanol with myrrh extract maintained the functional cytoarchitecture of the testis, as evidenced by increases in sperm count and testosterone levels. In addition to its influential role in mitigating oxidative and genotoxicity, myrrh improved the histological pattern of the seminiferous tubules. The current results are consistent with previous research (Hassanzadeh-Taheri *et al*., 2019), suggesting that the administration of myrrh can be advantageous against reproductive disorders induced by various toxic agents, including elevated sperm concentration and sex hormones as well as decreased testicular peroxidation and germinal cell apoptosis. In this study, myrrh extract caused a slight decrease in NO levels in testicular tissues, reflecting the initiation of its anti-inflammatory activity against ethanol toxicity. In addition, myrrh mitigated the MDA level and restored the DNA content and testicular tissue appearance, which are indicators of its crucial role in attenuating ethanol-induced oxidative stress.

The cytoprotective activities of myrrh illustrated in the current research could be due to the presence of several pharmacologically active components, including terpenoids, flavonoids, lignans and various steroids (Shekhawat and Sisodia, 2021). According to the phytochemical analysis of myrrh using GC/MS in our previous study, curzerene is the predominant component in the extract (Alahmari *et al*., 2022). Curzerene is a sesquiterpenoid isolated from some medicinal plants (Wang *et al*., 2017). In this study, we suggested that the high content of curzerene in the myrrh may have an influential role in the possibility of the myrrh extract in reducing ethanol toxicity and improving testicular tissue. This suggestion is compatible with previous *in-vivo* and *in-vitro* studies (Wang *et al*., 2017; Kumar *et al*., 2017). Also, other studies have demonstrated that some essential oils containing curzerene as a major component showed significant antioxidant activity against free radicals from exposure to toxins (Li *et al*., 2010). In addition, other minor elements in myrrh extract could be participating in an ameliorative effect of myrrh against ethanol toxicity. According to a previous study, myrrh and its components have suggested their efficiency in attenuating pathological conditions by suppressing ROS production and decreasing the concentration of LPO markers in damaged tissues, thus interrupting the feedback cycle of oxidation and mitigating

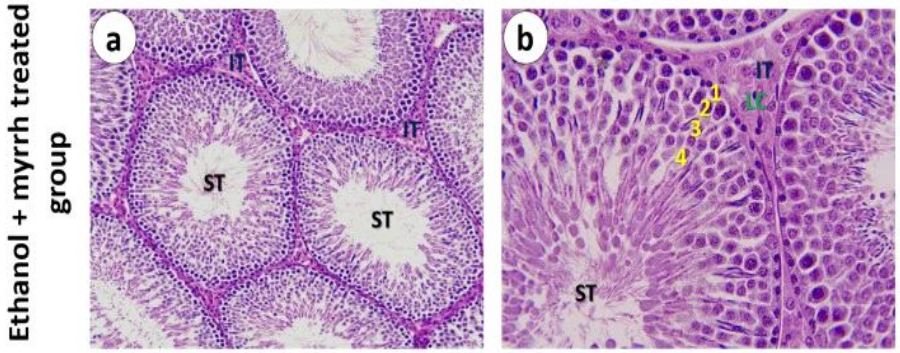

(a) The testicular tissue shows a marked reduction in histopathological alterations (100×). (b) High-magnification image of the seminiferous tubules displaying improvements in the seminiferous tubule structure and stages of spermatogenesis. Spermatogonia (1), 1st spermatocytes (2), 2nd spermatocytes (3) and spermatids (4) (400×). ST, seminiferous tubule; IT, interstitial tissue. Scale bar= 400 µm.

Fig 4: Photomicrographs of transverse testicular sections stained with H&E from ethanol+myrrh-treated rats.

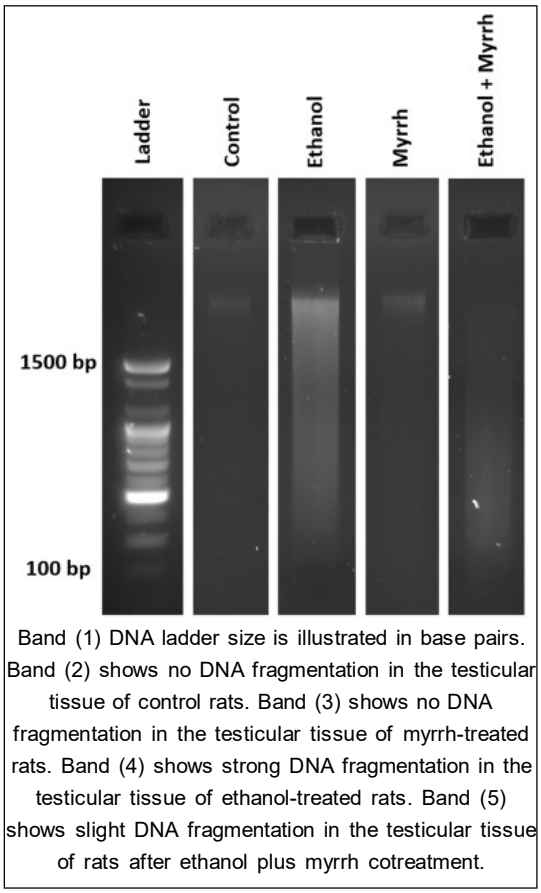

Band (1) DNA ladder size is illustrated in base pairs. Band (2) shows no DNA fragmentation in the testicular tissue of control rats. Band (3) shows no DNA fragmentation in the testicular tissue of myrrh-treated rats. Band (4) shows strong DNA fragmentation in the testicular tissue of ethanol-treated rats. Band (5) shows slight DNA fragmentation in the testicular tissue of rats after ethanol plus myrrh cotreatment.

Fig 5: Effect of myrrh consumption on ethanol-induced testicular DNA fragmentation using agarose gel electrophoresis.

tissue injury (Fatani *et al*., 2016). In addition, myrrh and its constituents play a significant role in removing ROS by promoting the upregulation of the nuclear factor erythroid 2-related factor 2 (Nrf2) pathway (Lebda *et al*., 2021). Nrf2 acts as a regulator of cellular defense against oxidants by controlling the transcription of antioxidant enzymes and suppressing proinflammatory mediators, thus remodeling and repairing damaged tissues (Chen, 2021). Scientific study has also shown the ability of these materials to enhance the expression of antioxidant genes to control physiological resistance during toxic exposure (Mirzaei *et al*., 2021). All of the above pathways could explain the ability of myrrh to protect against ethanol toxicity, which was represented by the improvements in histopathological and biochemical alterations caused by ethanol.

On the other hand, the level of HSP70 in testicular tissue remained high after co-treatment with myrrh, along with the high level of testicular TNF-α. According to previous studies, the HSP70 level is elevated in response to stress or the overproduction of ROS, as noted by Ibrahim *et al.* (2016). The production of HSP70 is an efficient mechanism by which cells protect themselves from cytotoxic agents. Several studies illustrated that HSP70 has essential roles in adaptation, inflammation and the expansion of the physio-pathological events of tumor creation and oxidative stress. In the current study, myrrh protected testicular tissues from ethanol by upregulating HSP70, which regulates the internal immune response and inhibits cellular apoptosis. Additionally, the high level of TNF-α in this study may suggest an adaptive immune process to keep sufficient ROS levels for cell signaling (Kurashova *et al*., 2020). All of these activities against ethanol toxicity may be related to the bioactive content in myrrh extract, which possesses antioxidant and antiapoptotic properties.

CONCLUSION

In conclusion, the findings of the current study reveal the harmful impacts of ethanol intake on testicular tissue, which was represented by spermatogenesis inhibition, diminished testosterone production, oxidative stress, inflammation and DNA fragmentation accompanied by histopathological alterations that occurred through possible cellular dysfunction mechanisms, such as the overproduction of ROS, which alters the redox balance in the cell. Co-treatment with myrrh protected the cells of the testes. These findings provide insight into the curative impacts of myrrh on ethanol-induced testicular toxicity and its benefits to counteract oxidative stress in rat testis and restore spermatogenesis. These pharmaceutical effects may be related to the high content of curzerene in the myrrh extract, which has antioxidant and anti-inflammatory properties to remove ROS and promote the upregulation of the Nrf2 pathway. Therefore, myrrh could be a promising therapeutic in future clinical research to attenuate the gonadal toxicity caused by alcohol consumption.

ACKNOWLEDGEMENT

The author extends their appreciation to the Deanship of Scientific Research at KKU for partially funding this work and the author acknowledges the Research Centre for Advance Materials (RCAMS) at King Khalid University, Saudi Arabia, for their valuable technical support.

Conflict of interest: None.

REFERENCES

Agbodjento, E., Klotoé, J.R., Dougnon, T.V., Sacramento, T.I., Dougnon, T.J., Atègbo, J.M. (2021). Effect of Rourea coccinea on ethanol-induced male infertility in Wistar albino rats. Andrologia. 53: e14047.

Akbari, A., Nasiri, K., Heydari, M., Mosavat, S.H., Iraji, A. (2017). The protective effect of hydroalcoholic extract of *Zingiber officinale* roscoe (ginger) on ethanol-induced reproductive toxicity in male rats. Journal of Evidence-Based Complementary and Alternative Medicine. 22: 609-617.

Alahmari, A.S., El-Mekkawy, H.I., Al-Doaiss, A.A., Alduwish, M.A. (2022). Effect of natural *Commiphora myrrha* extract against hepatotoxicity induced by alcohol intake in rat model. Toxics. 10: 729. doi: 10.3390/toxics10120729.

Borges Jr, E., Braga, D.P.D.A.F., Provenza, R.R., Figueira, R.D.C.S., Iaconelli Jr, A., Setti, A.S. (2018). Paternal lifestyle factors in relation to semen quality and *in vitro* reproductive outcomes. Andrologia. 50: e13090.

Cao, B., Wei, X.C., Xu, X.R., Zhang, H.Z., Luo, C.H., Feng, B., Xu, R.C., Zhao, S.Y., Du, X.J., Han, L., Zhang, D.K. (2019). Seeing the unseen of the combination of two natural resins, frankincense and myrrh: Changes in chemical constituents and pharmacological activities. Molecules. 24: 3076. doi: 10.3390/molecules24173076.

Chen, Q.M. (2021). Nrf2 for cardiac protection: Pharmacological options against oxidative stress. Trends in Pharmacological Sciences. 42: 729-744.

Cui, J., Liu, Y., Chang, X., Gou, W., Zhou, X., Liu, Z., Li, Z., Wu,/ Y., Zuo, D. (2019). Acetaldehyde induces neurotoxicity *in vitro via* oxidative stress- and Ca^{+2} imbalance-mediated endoplasmic reticulum stress. Oxidative Medicine and Cellular Longevity. 2593742. doi: 10.1155/2019/2593742.

Eid, N., Ito, Y., Horibe, A., Hamaoka, H., Kondo, Y. (2018). A Method for *in vivo* Induction and Ultrastructural Detection of Mitophagy in Sertoli Cells. In. Methods in Molecular Biology (Clifton, N.J.). NY: Humana Press, New York. Pp: 103-112.

El-Sherbiny, I.M., Salih, E., Reicha, F.M. (2013). Green synthesis of densely dispersed and stable silver nanoparticles using myrrh extract and evaluation of their antibacterial activity. Journal of Nanostructure in Chemistry. 3: 1-7.

Enebeli, B., Nwangwa, E.K., Nwogueze, B.C., Nzenegu, A., Agbonifo -Chijiokwu, E., Omeru, O., Ebuwa, E.I. (2022). *In vivo* attenuation of alcohol- and cadmium chloride-induced testicular toxicity modulated by silymarin in male Wistar rat. Biological Trace Element Research. 200: 3666-3676.

Fatani, A.J., Alrojayee, F.S., Parmar, M.Y., Abuohashish, H.M., Ahmed, M.M., Al-Rejaie, S.S. (2016). Myrrh attenuates oxidative and inflammatory processes in acetic acid-induced ulcerative colitis. Experimental and Therapeutic Medicine. 12: 730-738.

Finelli, R., Mottola, F., Agarwal, A. (2021). Impact of alcohol consumption on male fertility potential: A narrative review. International Journal of Environmental Research and Public Health. 19: 328. doi: 10.3390/ijerph19010328.

Haffor, A.S. (2010). Effect of myrrh (*Commiphora molmol*) on leukocyte levels before and during healing from gastric ulcer or skin injury [*Commiphora molmol*]. Journal of Immunotoxicology. 7: 68-75.

Hassanzadeh Taheri, M., Hosseini, M., Dorranipour, D., Afshar, M., Moodi, H., Salimi, M. (2019). The oleo-gum-resin of commiphora myrrha ameliorates male reproductive dysfunctions in streptozotocin-induced hyperglycemic rats. Pharmaceutical Sciences. 25: 294-302.

Horibe, A., Eid, N., Ito, Y., Hamaoka, H., Tanaka, Y., Kondo, Y. (2017). Upregulated autophagy in Sertoli cells of ethanol-treated rats is associated with induction of inducible nitric oxide synthase (iNOS) androgen receptor suppression and germ cell apoptosis. International Journal of Molecular Sciences. 18: 1061. doi: 10.3390/ijms18051061.

Hosseini, S.M., Taghiabadi, E., Abnous, K., Hariri, A.T., Pourbakhsh, H., Hosseinzadeh, H. (2017). Protective effect of thymoquinone, the active constituent of Nigella sativa fixed oil, against ethanol toxicity in rats. Iranian Journal of Basic Medical Sciences. 20: 927-939.

Hussain, T., Murtaza, G., Metwally, E., Kalhoro, D.H., Kalhoro, M.S., Rahu, B.A., Sahito, R.G. A., Yin, Y., Yang, H., Chughtai, M.I., Tan, B. (2021). The role of oxidative stress and antioxidant balance in pregnancy. Mediators of Inflammation. 2021: 9962860.

Ibrahim, I.A., Abdulla, M.A., Hajrezaie, M., Bader, A., Shahzad, N., Al-Ghamdi, S.S., Gushash, A.S., Hasanpourghadi, M. (2016). The gastroprotective effects of hydroalcoholic extract of Monolluma quadrangula against ethanol-induced gastric mucosal injuries in Sprague Dawley rats. Drug Design, Development and Therapy. 10: 93-105.

Johnsen, S.G. (1970). Testicular biopsy score count-A method for registration of spermatogenesis in human testes: Normal values and results in 335 hypogonadal males. Hormones. 1: 2-25.

Khalil, N., Fikry, S., Salama, O. (2020). Bactericidal activity of Myrrh extracts and two dosage forms against standard bacterial strains and multidrug-resistant clinical isolates with GC/ MS profiling. AMB Express. 10: 21. doi: 10.1186/s13568-020-0958-3.

Kumar, A.S., Jeyaprakash, K., Chellappan, D.R., Murugan, R. (2017). Vasorelaxant and cardiovascular properties of the essential oil of Pogostemon elsholtzioides. Journal of Ethnopharmacology. 199: 86-90.

Kumar, N. and Singh, A.K. (2015). Trends of male factor infertility, an important cause of infertility: A review of literature. Journal of Human Reproductive Sciences. 8: 191-196.

Kurashova, N.A., Madaeva, I.M., Kolesnikova, L.I. (2020). Expression of HSP70 heat-shock proteins under oxidative stress. Advances in Gerontology. 10: 20-25.

Lampiao, F. and du Plessis, S.S. (2008). TNF-alpha and IL-6 affect human sperm function by elevating nitric oxide production. Reproductive Biomedicine Online. 17: 628-631.

Lebda, M.A., Mostafa, R.E., Taha, N.M., Abd El-Maksoud, E.M., Tohamy, H.G., Al Jaouni, S.K., El-Far, A.H., Elfeky, M.S. (2021). Commiphora myrrh supplementation protects and cures ethanol-induced oxidative alterations of gastric ulceration in rats. Antioxidants. 10: 1836. doi: 10.3390/ antiox10111836.

Li, Z.H., Wang, Q., Ruan, X., Pan, C.D., Jiang, D.A. (2010). Phenolics and plant allelopathy. Molecules. 15: 8933-8952.

MacLean, C.M., Godsafe, Z., Soto-Forte, P., Larsen, F. (2022). Pharmacokinetic, safety and pharmacodynamic properties of teverelix trifluoroacetate, a novel gonadotropin-releasing hormone antagonist, in healthy adult subjects. Clinical Pharmacology in Drug Development. 11: 257-269.

Mirzaei, S., Zarrabi, A., Hashemi, F., Zabolian, A., Saleki, H., Azami, N., Hamzehlou, S., Farahani, M.V., Hushmandi, K., Ashrafizadeh, M., Khan, H., Kumar, A.P. (2021). Nrf2 signaling pathway in chemoprotection and doxorubicin resistance: Potential application in drug discovery. Antioxidants. 10: 349. doi: 10.3390/antiox10030349.

Muthusami, K.R. and Chinnaswamy, P. (2005). Effect of chronic alcoholism on male fertility hormones and semen quality. Fertility and Sterility. 84: 919-924.

Nishi, K., Ramakrishnan, S., Gunasekaran, V.P., Parkash, K., Ramakrishnan, A., Vijayakumar, N., Ganeshan, M. (2018). Protective effects of pcoumaric acid on ethanol induced male reproductive toxicity. Life Sciences. 209: 1-8.

Peccerella, T., Arslic-Schmitt, T., Mueller, S., Linhart, K.B., Seth, D., Bartsch, H., Seitz, H.K. (2018). Chronic Ethanol Consumption and Generation of Etheno-DNA Adducts in Cancer-Prone Tissues. In Alcohol and Cancer: Proceedings of the Third International Conference. Springer International Publishing. Pp: 81-92.

Purandhar, K., Jena, P.K., Prajapati, B., Rajput, P., Seshadri, S. (2014). Understanding the role of heat shock protein isoforms in male fertility, aging and apoptosis. World Journal of Men's Health. 32: 123-132.

Rachdaoui, N. and Sarkar, D.K. (2017). Pathophysiology of the effects of alcohol abuse on the endocrine system. Alcohol Research: Current Reviews. 38: 255-276.

Rompala, G.R. and Homanics, G.E. (2019). Intergenerational effects of alcohol: A review of paternal preconception ethanol exposure studies and epigenetic mechanisms in the male germline. Alcoholism, Clinical and Experimental Research. 43: 1032-1045.

Sable, A., Rai, K.M., Choudhary, A., Yadav, V.K., Agarwal, S.K., Sawant, S.V. (2018). Inhibition of heat shock proteins HSP90 and HSP70 induce oxidative stress, suppressing cotton fiber development. Scientific Reports. 8: 3620. doi: 10.1038/s41598-018-21866-0.

Sadeghzadeh, M., Shirpoor, A., Naderi, R., Kheradmand, F., Gharalari, F.H., Samadi, M., Khalaji, M., Gharaaghaji, R. (2019). Long-term ethanol consumption promotes changes in beta-defensin isoform gene expression and induces structural changes and oxidative DNA damage to the epididymis of rats. Molecular Reproduction and Development. 86: 624-631.

Shahin, S., Singh, S.P., Chaturvedi, C.M. (2018). 2.45-GHz microwave radiation induced oxidative and nitrosative stress mediated testicular apoptosis: Involvement of a p53 dependent bax-caspase-3 mediated pathway. Environmental Toxicology. 33: 931-945.

Shalaby, M.A. and Hammouda, A.A. (2014). Analgesic, anti-inflammatory and anti-*hyperlipidemic* activities of *Commiphora molmol* extract (Myrrh). Journal of Intercultural Ethnopharmacology. 3: 56-62.

Sharma, R., Biedenharn, K.R., Fedor, J.M., Agarwal, A. (2013). Lifestyle factors and reproductive health: Taking control of your fertility. Reproductive Biology and Endocrinology. 11: 1-15.

Shekhawat, M. and Sisodia, S.S. (2021). A review on pharmacology of oleo-gum resin of *Commiphora wightii*. World Journal of Pharmaceutical Research. 10: 735-723.

Stamatiades, G.A. and Kaiser, U.B. (2018). Gonadotropin regulation by pulsatile GnRH: Signaling and gene expression. Molecular and Cellular Endocrinology. 463: 131-141.

Talbi, A., Khelili, K., Remita, F., Abdennour, C. (2022). The benefit of Silybum marianum in ethanol-induced reprotoxicity of male Wistar rat. Brazilian Journal of Pharmaceutical Sciences. 58: e19264.

Vander Borght, M. and Wyns, C. (2018). Fertility and infertility: Definition and epidemiology. Clinical Biochemistry. 62: 2-10.

Wang, Y., Li, J., Guo, J., Wang, Q., Zhu, S., Gao, S., Zhang, W., Wang, J., Zang, L. (2017). Cytotoxic and antitumor effects of curzerene from curcuma longa. Planta Medica. 83: 23-29.

Weber, L., Kuck, K., Jürgenliemk, G., Heilmann, J., Lipowicz, B., Vissiennon, C. (2020). Anti-inflammatory and barrier-stabilising effects of myrrh, coffee charcoal and chamomile flower extract in a co-culture cell model of the intestinal mucosa. Biomolecules. 10: 1033. doi: 10.3390/biom 10071033.

Yang, S. and Lian, G. (2020). ROS and diseases: Role in metabolism and energy supply. Molecular and Cellular Biochemistry. 467: 1-12.

Yokoi, K., Uthus, E.O., Nielsen, F.H. (2003). Nickel deficiency diminishes sperm quantity and movement in rats. Biological Trace Element Research. 93: 141-154.

Zhang, Y., Ding, H., Xu, L., Zhao, S., Hu, S., Ma, A., Ma, Y. (2022). Lutein can alleviate oxidative stress, inflammation and apoptosis induced by excessive alcohol to ameliorate reproductive damage in male rats. Nutrients. 14: 2385. doi: 10.3390/nu14122385.