RESEARCH ARTICLE Indian Journal of Animal Research, Volume 58 Issue 2: 200-209 (February 2024)

Immunomodulatory effect of *Eugenia caryophyllata* against Vitamin D-induced Toxicity in Liver of Male Westar Rats

Manal F. El-Khadragy[1], Noura M. AlDurgham[2], Sherifa S. Hamed[3], Fatma Elzahraa H. Salem[4], Maha A. Aljumaa[1], Hany M. Yehia[5,6], Mariam A. Alkhateeb[1]

10.18805/IJAR.BF-1711

ABSTRACT

Background: Vitamin D is essential for overall health, wellbeing and immune system. hypervitaminosis D led to many deleterious effects and increased mortality. This study aimed evaluate the immunomodulatory potential of eugenol (volatile phenolic constituent of clove essential oil obtained from *Eugenia caryophyllata*) against inflammation induced by vitamin D toxicity.

Methods: Vitamin D (100 mg/kg) was orally administered into male albino rats followed by an oral administration of eugenol (100 mg/kg) for two months.

Result: Histological results showed Vitamin D intoxication cause distinct alterations such as loss of lobular architecture, fibrosis and necrosis, treatment of eugenol with injected of Vitamin D showed improvement in the histological features of liver tissues. The study showed that a significant upregulation in the TNF-α, IL-2 and iNOS genes expression levels caused by Vitamin D compared to the control group. Eugenol treatment caused a significant decreased TNF-α, IL-2 and iNOS activity and down-regulated gene expression levels. In Conclusion, hepatoprotective effects of eugenol through inhibiting pro-inflammation by vitamin D toxicity and increase the activity of the antioxidant defense system.

Key words: Antioxidants, Clove, Gene expression, Inflammation, Liver, Vitamin D.

INTRODUCTION

The regulation of metabolism, calcium and phosphorus absorption and bone health all depend on vitamin D. However, vitamin D has impacts beyond maintaining bone health and mineral equilibrium. The fact that vitamin D receptors (VDR) are found in numerous tissues and organs suggests that the functions of vitamin D go far beyond maintaining bone homeostasis (Wang *et al.,* 2023). In addition, the enzyme that transforms 25[OH] D into Vitamin D (1,25[OH]2 D), which is biologically active, has been discovered in tissues other than the kidneys (Carlberg, 2023) and extra renal synthesis of 1,23[OH]2D may be just as significant in controlling cell growth and differentiation via paracrine or autocrine regulatory mechanisms (Holick, 2008). The mechanism of action of vitamin D3 *via* its hormonal form, dihydroxy vitamin D3, involves a nucleus VDR that controls the transcription of a number of target genes in a range of vitamin D target cells, with the majority of these genes being involved in the calcium homeostasis of cell differentiation (Jones *et al*., 1998). When pharmacological amounts of vitamin D have been consumed through extended periods of time or from only one megadose, it results in a significant rise in circulation 25[OH]D concentrations, which causes hypervitaminosis D (Vieth, 1999).

Hypervitaminosis D, commonly known as vitamin D toxicity (VDT), is a rare but potentially dangerous illness that develops when a person has high levels of 25(OH)D in their circulation (Agraharkar *et al.,* 2012). When the level of 25-OH (D), the primary storage form of vitamin D, surpasses 150 ng/Ml, hypervitaminosis D develops (Araki *et al.*, 2011). According to Atabek *et al.* (2006) and Orbak *et al.* (2006), hypercalcemia symptoms such as poor appetite, weight loss, abdominal pain, vomiting, constipation, polyuria and polydipsia, as well as in severe cases, life-threatening dehydration, coexist with symptoms of vitamin D intoxication.

[1]Department of Biology, College of Science, Princess Nourah Bint Abdulrahman University, P.O. Box 84428, Riyadh 11671, Saudi Arabia.
[2]Department of Zoology, College of Science, King Saud University, P.O.2455, Riyadh, 11451, Saudi Arabia.
[3]Department of Zoology, Faculty of Science, Alexandria University, Alexandria, Egypt.
[4]Department of Zoology and Entomology, Faculty of Science, Helwan University, Cairo, Egypt, P.O. Box 11611, Egypt.
[5]Department of Food Science and Nutrition, College of Food and Agriculture Science, King Saud University, Riyadh 1145, Saudi Arabia.
[6]Department of Food Science and Nutrition, Faculty of Home Economics, Helwan University, Helwan 11111, Egypt.

Corresponding Author: Mariam A. Alkhateeb, Department of Biology, College of Science, Princess Nourah bint Abdulrahman University, P.O. Box 84428, Riyadh 11671, Saudi Arabia.
Email: MAAlKhateeb@pnu.edu.sa.

How to cite this article: El-Khadragy, M.F., AlDurgham, N.M., Hamed, S.S., Salem, F.E.H., Aljumaa, M.A., Yehia, H.M. and Alkhateeb, M.A. (2024). Immunomodulatory effect of *Eugenia caryophyllata* against Vitamin D-induced Toxicity in Liver of Male Westar Rats. Indian Journal of Animal Research. 58(2): 200-209. doi: 10.18805/IJAR.BF-1711.

Submitted: 03-10-2023 **Accepted:** 26-11-2023 **Online:** 15-12-2023

Eugenia caryophyllata (Clove) is one of the most significant herbal medicines, which has been utilised in a variety of food spices, preservatives and medical applications. It includes volatile oil, which is used to stimulate the nervous system and improve cognition (Halder *et al*., 2011). The primary chemical component of cloves, polyphenylpropene eugenol, is what gives them their distinctive flavour. According to several research, eugenol has antiproliferative, anti-inflammatory, cytotoxic and antioxidant properties (*in vitro* and *in vivo*) (Said and Rabo, 2017).

The present work was aimed to evaluate the protective role of *Eugenia caryophyllata* extract against vitamin D - induced toxicity in rat's liver by using light microscopes, bioassay studies and molecular biology in adult male Wistar rat and these will be *via* examine the histological changes which probably induced in liver and evaluate the protective effect of *Eugenia caryophyllata* extract against vitamin D toxicity at the level of some genes in liver of rat.

MATERIALS AND METHODS

Chemicals

Vitamin D purchased from Novartis Company. Eugenol purchased from Sigma-Aldrich Company.

Experimental animals

Forty young healthy male Westar rats weighing about 200 gm were obtained from Animal House from the company for biological products and vaccines (VACSERA), Cairo, Egypt. Animals were housed in plastic cages under controlled temperature (23±28°C) and maintained in groups of five per cage in a light-dark cycle. They were given free access to a commercial pellet diet and tap water and allowed to acclimatize for three days before initiation of the experiment. They were divided into four groups (10 animals each) and will be treated as follows:

Group I: Control group (-ve) each animal orally given saline (100 mg/kg b/w) for 2 months.

Group II: Control group (+ve) each animal orally given vitamin D (100 mg/kg /w) for 2 months (Holcombe *et al.,* 2015).

Group III: Each animal orally given eugenol (100 mg/kg b/w) for 2 months (Paula-Freire *et al.,* 2016).

Group IV: Each animal orally given vitamin D (100 mg /kg b/w) then orally given eugenol (100 mg/kg b/w) for 2 months. By the National Institutes of Health (NIH) Guidelines for the Care and Use of Laboratory Animals, 8th edition, all protocols and animal handling at the Department of Zoology, Faculty of Science, Helwan University were approved by the Committee on Research Ethics for Laboratory Animal Care (approval number: HU/Z/010-19).

Total phenolic content

Total phenolic compound content of *G. eugenol* extract was assayed by the Folin-Ciocalteu method as described previously (Chaieb *et al.,* 2007). Briefly, 0.1 mL of the sample's extract was mixed with 2.5 mL of distilled water in a test tube and then 0.1 mL of undiluted Folin-Ciocalteu reagent (Sigma-Aldrich, St. Louis, MO, USA) was added. The solution was mixed well and then allowed to stand for 6 min before adding 0.5 mL of 20% sodium carbonate solution. The color developed for 30 min at room (20°C) temperature and the absorbance was measured at 760 nm using a spectrophotometer (PD 303 UV spectrophotometer, Apel Co., Limited, Saitama, Japan). A blank sample was prepared using 0.1 mL of methanol instead of the extract. The measurement was compared to a calibration curve of gallic acid solution and expressed as milligram (mg) equivalent (eq.) of gallic acid per gram (g) of dry weight extract.

Total flavonoids

The aluminium chloride colorimetric method was used to determine the total flavonoid content of eugenol extract as described previously (Baba and Malik, 2015). Briefly, in a test tube, 50 µL of the extract was mixed with 4 mL of distilled water, 0.3 mL of 5% $NaNO_2$ solution and 0.3 mL of 10% AlCl3. $6H_2O$. The mixture was allowed to stand for 6 min and then 2 mL of 1 mol/L NaOH solution was added; distilled water was subsequently added to bring the final volume to 10 mL. The mixture was allowed to stand for another 15 min and the absorbance was measured at 510 nm. The total flavonoid content was calculated from a calibration curve and the result is expressed as mg eq. rutin/g dry weight.

DPPH (2,2-diphenyl-1-picrylhydrazyl) scavenging activity radical

The power of the eugenol extract to scavenge DPPH radicals was assayed as described previously (Akillioglu *et al.,* 2010). A fresh solution of 0.08 mM DPPH radical in methanol was prepared. Next, 950 µL of DPPH solution was mixed with 50 µL extract and incubated for 5 min. Exactly 5 min later, the absorbance of the mixture was measured at 515 nm (PD 303 UV spectrophotometer, Apel Co., Limited). Antioxidant activity (AA) is expressed as percentage inhibition of DPPH radical using the equation below:

$$AA = 100 - \left[\frac{A\ sample}{A\ control} \times 100\right]$$

Where,

A sample = Absorbance of the sample at time.

t= 5 min.

A control = Absorbance of the control.

ABTS [2,4,6-tri(2-pyridyl)-s-triazine] radical scavenging activity

The ABTS assay was used to determine the DPPH radical scavenging activity according to the method of Gouveia and Castilho (2011). The ABTS+ radical solution was prepared by reacting 50 mL of 2 mM ABTS solution with 200 µL of 70 mM potassium persulfate solution. This mixture was stored in the dark for 16 h at room temperature

was diluted with pH 7.4 phosphate buffered saline (PBS) solution to an initial absorbance of 0.700±0.021 at 734 nm.

This solution was freshly prepared for each set of analysis. To determine the antiradical scavenging activity, an aliquot of 100 µL methanolic solution was mixed with 1.8 mL of ABTS+ solution and the decrease in absorbance at 734 nm (PD 303 UV spectrophotometer, Apel Co., Limited, Saitama, Japan) was recorded during 6 min. The results are expressed as µmol Trolox equivalent per g of dried extract (µmol eq. Trolox/g), based on the Trolox calibration curve.

Ferric reducing antioxidant power (FRAP)

Ferric reducing antioxidant power (FRAP) was performed as described previously (Benzie and Strain, 1996).

Real time PCR

The total RNA was isolated from the liver tissue using an RN easy plus Minikit (Qiagen, Valencia, CA). One microgram of the total RNA and random primers were used for cDNA synthesis using the Revert Aid H minus Reverse Transcriptase (Fermentas, Thermo Fisher Scientific Inc., Canada). For real time PCR analysis, the cDNA samples were run in triplicate and GAPDH was used as a reference gene. Each PCR amplification included non-template controls and all reagents except for the cDNA. Real time PCR reactions were performed using Power SYBR Green (Life Technologies, CA) and were conducted on the Applied Biosystems 7500 Instrument. The typical thermal profile is 95°C for 3 min, followed by 40 cycles of 95°C for 15 s and 56°C for 30s. After PCR amplification, the 1Ct was calculated by subtracting the GAPDH Ct from each sample Ct. The method of Pfaffl was used for the data analysis (Pfaffl, 2001). The PCR primers for iNOS, IL-2 and TNF-α genes were synthesized by Jena Bioscience GmbH (Jena, Germany). Primers were designed using the Primer-Blast program from NCBI. For a reference gene, GAPDH was used.

The primer sets used were as the following:

GAPDH: Sense: 5′-GCATCTTCTTGTGCAGTGCC-3′,
Antisense: 5′-GATGGTGATGGGTTTCCCGT-3′;
iNOS: Sense:5′-GTTCCTCAGGCTTGGGTCTT-3′,
Antisense:5′- TGGGGGAACACAGTAATGGC-3′;
IL-2: Sense: 5′-CTGCAGCGTGTGTTGGATTT-3′,
Antisense: 5′-GGCTCATCATCGAATTGGCAC-3′;
TNF-α: Sense: 5′-AGAACTCAGCGAGGACACCAA-3′,
Antisense: 5′-GCTTGGTGGTTTGCTACGAC-3′

Histopathological studies

Liver tissue samples were fixed in 10% neutral formalin for 24 h and paraffin blocks were routinely processed for light microscopy. Slices of 4-5 µm were obtained from the prepared blocks and stained with hematoxylin and eosin as well as Masson's trichrome for hepatic fibrosis. The preparations obtained were visualized using a Nikon microscope.

Statistical analysis

Results were expressed as Mean±SE (standard error). Data for multiple variable comparisons were analysed by one-way analysis of variance (ANOVA). For the comparison of significance between groups, Duncan's test was used as a post hoc test according to the statistical package program (SPSS version 22).

RESULTS AND DISCUSSION

The total amounts of the phenolic and flavonoids contents present in the investigated eugenol were 12545.203±163.740 mg eq. gallic acid/g and 454.906±8.878 mg eq. Rutin/g, respectively (Table 1). Furthermore, the results indicated that the eugenol has potent free radical scavenging power. For the DPPH, ABTS and FRAP assays, values of 76.206±0.268, 2466.667±11.547 and 2321.566±92.459 µmol eq. Trolox/g, respectively, were obtained.

Histopathological patterns showed in the liver (Fig 1, 2, 3 and 4). The results of examination showed that normal structure in the control group, examination of eugenol and vitamin D-treated rat liver revealed that treatment with eugenol was able to ameliorate the vitamin D-induced liver toxicity. While Vitamin D-administration produced many alterations in the hepatic tissue, showing congestion and dilatation of central vein, blood sinusoids and the hepatic portal vein. Few collagen fibers were detected around the central veins (GIV) (Fig 4), in the portal areas surrounding the blood sinusoids, similar to the control group (GI) and eugenol treated group (GIII).

During inflammation, nuclear had a seminal role in immunity, because its active pro-inflammatory genes encoding iNOS, TNF-α and IL-2. The current study showed that a significant upregulation in gene expression of iNOS mRNA, TNF-α mRNA, IL-2 mRNA which induced by Vitamin D overdose compare to control group (Fig 5). Effect of eugenol on hepatic IL-2 mRNA, which shows significantly increase in infected non-treated group level (10.7% at $ap<0.05$), while showed that significantly decrease on eugenol group and treated group (5.7% at $abp<0.05$; 4.3% at $bp<0.05$) respectively compared to control groups (0.9% at $p<0.05$). However, the effect of eugenol on hepatic iNOS

Table 1: Experimental determination of total phenolic and flavonoids contents and antioxidant capacity assays (ABTS, DPPH and FRAP) for the eugenol.

Parameters	Mean±SE
Total phenols (mg eq. Gallic acid/g sample)	12545.203±163.740
Total flavonoids (mg eq. Rutin/g sample)	454.906±8.878
DPPH (%)	76.206±0.268
ABTS (µmol eq. Trolox/g sample)	2466.667±11.547
FRAP (µmol eq. Trolox/g sample)	2321.566±92.459

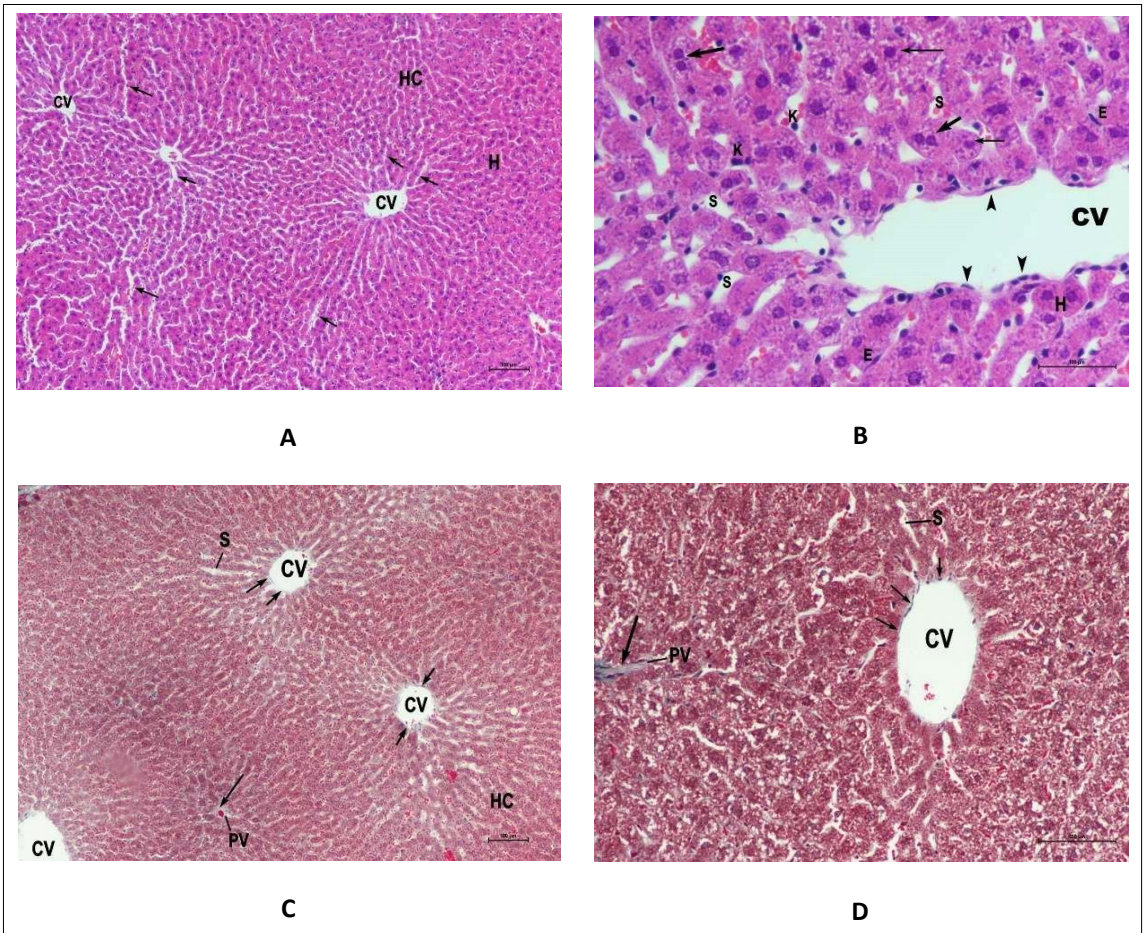

(A) A well-preserved normal liver architecture hepatic cords (HC) with hepatocytes (H), central veins (cv) and blood sinusoids (arrows). **(B)** Normal morphological liver architecture with central vein (CV) lined with endothelial cells (arrow head), hepatic cords with surrounding hepatocytes (H), either mononucleated (thin arrow) or binucleated (thick arrow). Note the presence of Kupffer cells (K) and narrow blood sinusoids (S). **(C)** Few blue collagen fibres (arrows) around central vein (CV); hepatic cords (HC) portal vein (PV); blood sinusoids (S). **(D)** A faint thin layer of collagen fibres (thin arrows) surrounding the central vein and little amount of normally distributed collagen fibres (thick arrow) is seen in the portal area (PV). No collagen deposition is noted in blood sinusoids (S).

Fig 1: Photo micrograph of rat liver of control group (G I).

mRNA, which shows significantly increase in infected non-treated group level (6.3% at ap<0.05), while showed that significantly decrease on eugenol group and treated group (3.1% at abp<0.05; 1.7% at bp<0.05), respectively compared to control groups (1% at p<0.05). while, the effect of eugenol on hepatic TNF-α mRNA, which shows significantly increase in infected non-treated group level (7.7% at ap<0.05), while showed that significantly decrease on eugenol group and treated group 3.5% at abp<0.05; 3.1% at bp<0.05), respectively compared to control groups (1.1% at p<0.05). In the present study, treatment with Vitamin D at a dose of 100 mg/kg b/w per daily for two months led to the development of hepatic injury and inflammatory in rats. The results obtained in this work are similar to the findings of Karim *et al.* (2013), who have reported the inflammatory effects of Vitamin D. The close association between several cytokines is influenced by Vitamin D status.

Histopathological changes produced by Vitamin D drug such as fibrosis and inflammatory of hepatocytes around the central veins were dose-dependently recovered by the pretreatment eugenol (Prasad *et al.,* 2010; Yogalakshmi *et al.,* 2010). The current study showed that rats treated with eugenol oxidative stress produced by free radicals is the main and primary step in Vitamin D toxicity contributing to both onset and progression of fibrosis. The antioxidant effect of flavonoids found in eugenol enhanced the process of regeneration. This result may be due to the destruction of

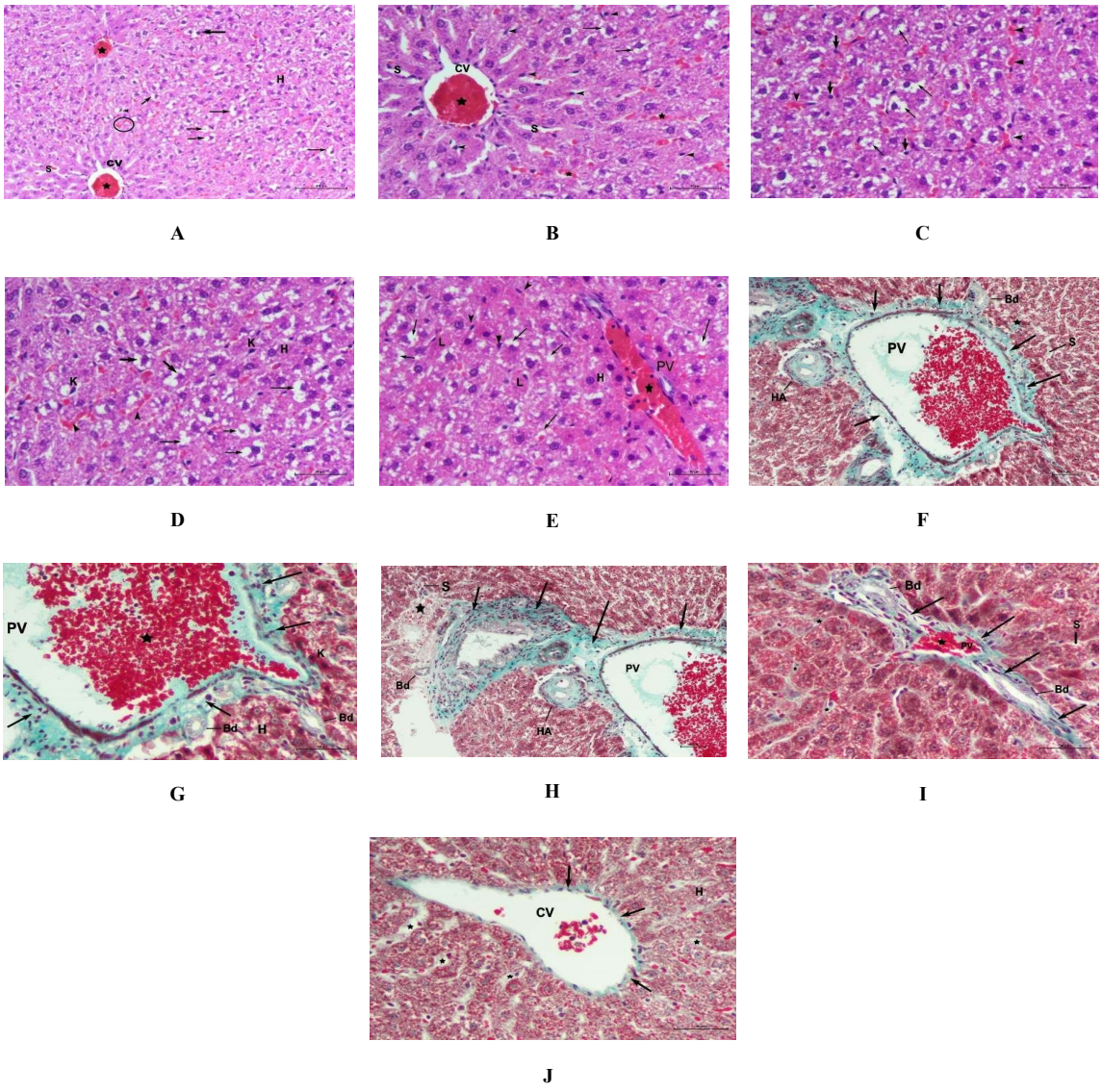

(A) Loss of radial arrangement of hepatic cords, congestion of central vein (CV) and sinusoid (S), haemorrhage (circle), cytoplasmic vacuolization of hepatocytes (H) with eccentric nuclei and pyknotic nuclei (arrow head). **(B)** Congestion of central vein, cytoplasmic vacuolization of hepatocytes (thin arrow), sinusoid (S) and Kupffer cells (arrow head) especially around the central vein. **(C)** Hepatocytes with pleomorphic and heterochromatic nuclei with indistinct nuclear envelope and disappearance of nucleoli, congestion and collapsed blood sinusoids congestion (arrow head), cytoplasmic vacuolization of hepatocytes (thin arrow). Note the increased Kupffer cells (thick arrow). **(D)** Deformed liver architecture with ballooning vacuolization of hepatocytes (H) (thin arrow) with necrotic eccentric nuclei (thick arrow), increased Kupffer cells (k) and congestion of blood sinusoid (arrow head). **(E)** Congestion (star) of portal vein (PV), cytoplasmic vacuolization (arrows) of hepatocytes (H) with liquid infiltration (L) and an increase of Kupffer cells (arrow head). **(F)** Dark blue colour (collagen fibres) around the portal area (arrows) including portal vein (PV), hepatic artery (HA) and bile duct (Bd) indicated extensive fibrosis. Also, a faint blue colour in the sinusoid (S). **(G)** Collagen fibres (arrows) around the congested portal vein (PV). Notice, lymphocytes in the PV (star), proliferated bile duct (Bd), hepatocytes (H) Kupffer cells(K). **(H)** Complete and extensive fibrosis around the portal area (arrows), necrotic area (star) near blood sinusoid (S), Hepatic artery (HA), congested hepatic portal vein (PV). **(I)** Extended deposition of collagen fibres around congested portal area (arrows) and around the blood sinusoids (star). PV; portal vein, Bd; bile duct, S; blood sinusoid. **(J)** A deposition of collagen fibres (arrows) around the central vein (CV) and the blood sinusoids (star).

Fig 2: Photo micrograph of liver of rats treated with vitamin D (G II).

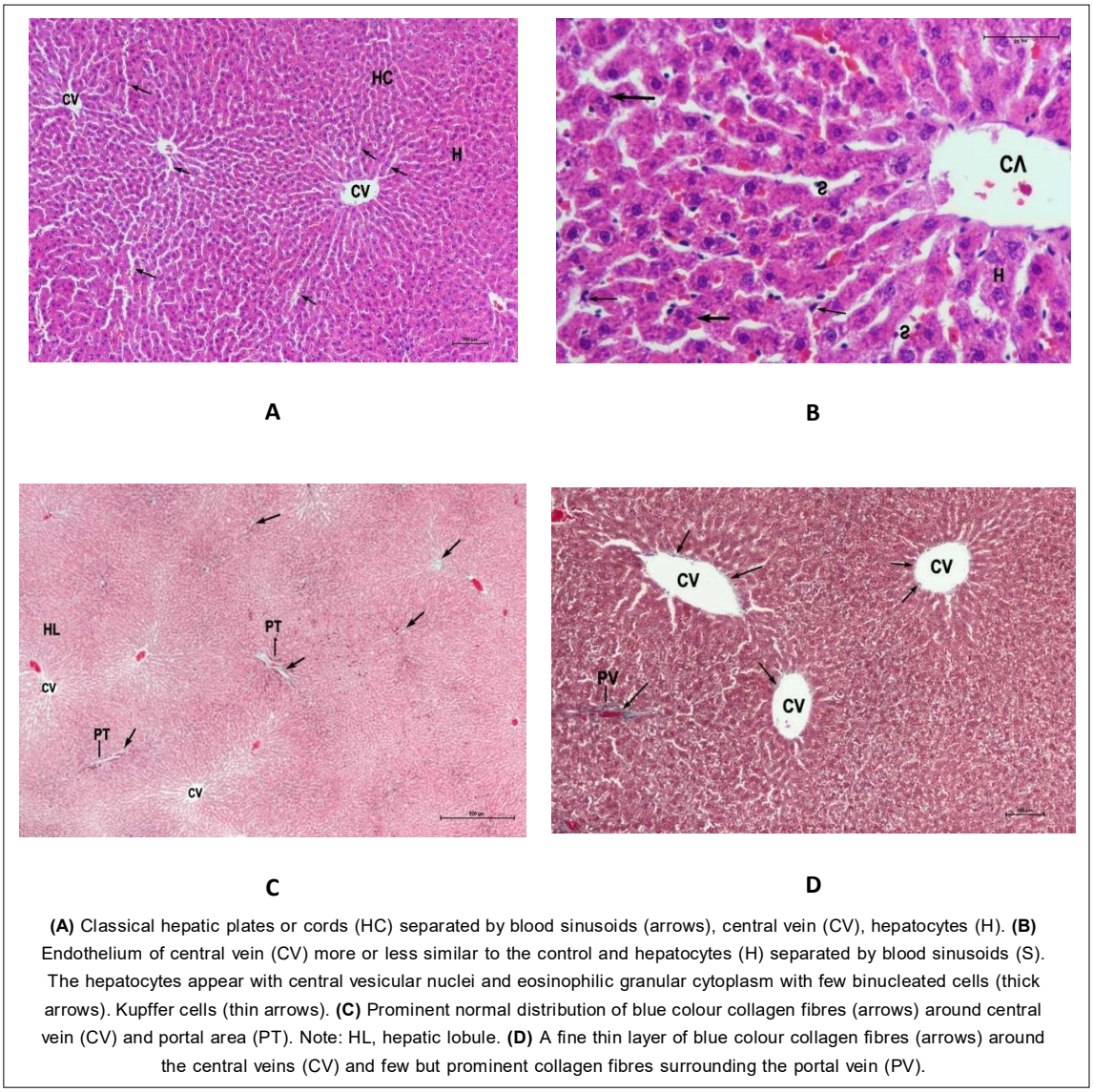

(A) Classical hepatic plates or cords (HC) separated by blood sinusoids (arrows), central vein (CV), hepatocytes (H). **(B)** Endothelium of central vein (CV) more or less similar to the control and hepatocytes (H) separated by blood sinusoids (S). The hepatocytes appear with central vesicular nuclei and eosinophilic granular cytoplasm with few binucleated cells (thick arrows). Kupffer cells (thin arrows). **(C)** Prominent normal distribution of blue colour collagen fibres (arrows) around central vein (CV) and portal area (PT). Note: HL, hepatic lobule. **(D)** A fine thin layer of blue colour collagen fibres (arrows) around the central veins (CV) and few but prominent collagen fibres surrounding the portal vein (PV).

Fig 3: Photo micrograph of liver of rats treated with eugenol (G III).

free radicals, supplying a competitive substrate for unsaturated lipids in the membrane and/or accelerating the repair mechanism of the damaged cell membrane (Hamed *et al.,* 2016).

Histological investigations revealed that Vitamin D exposure caused progressive alterations in the liver regions, these results in agreement with several previous studies (Abdel-Rahman and El-Megeid, 2006; Yogalakshmi *et al.,* 2010). We found that, after the eugenol, liver tissue showed a normal lobular pattern with a mild degree of necrosis and a lymphocytic infiltration almost comparable to the normal control.

Vitamin D induced fibrosis in which collagen fibres extended between the two adjacent central veins, while, the Vitamin D and eugenol-treated group resulted in a recovery of the hepatic tissue, with a faint thin blue layer of collagen fibres.

Inflammation is characterized by release of pro-inflammatory cytokines such as tumor necrosis factor-alpha (TNF-α) and interleukin-2 (IL-2), well as inflammatory mediators, inducible nitric oxide syntheses (iNOS). These inflammatory mediators and cytokines are involved in many human diseases including rheumatoid arthritis, asthma, atherosclerosis and endotoxin-induced multiple organ injuries (Guslandi, 2005; Ritchlin *et al.,* 2003).

Anti-inflammatory agent reduce the inflammatory response by suppressing the production of inflammatory cytokines and mediator (Leech *et al.,* 1998; Makarov, 2000) nuclear factor-Kb (NF-κB) has seminal role in immunity, because it activate pro-inflammatory genes encoding

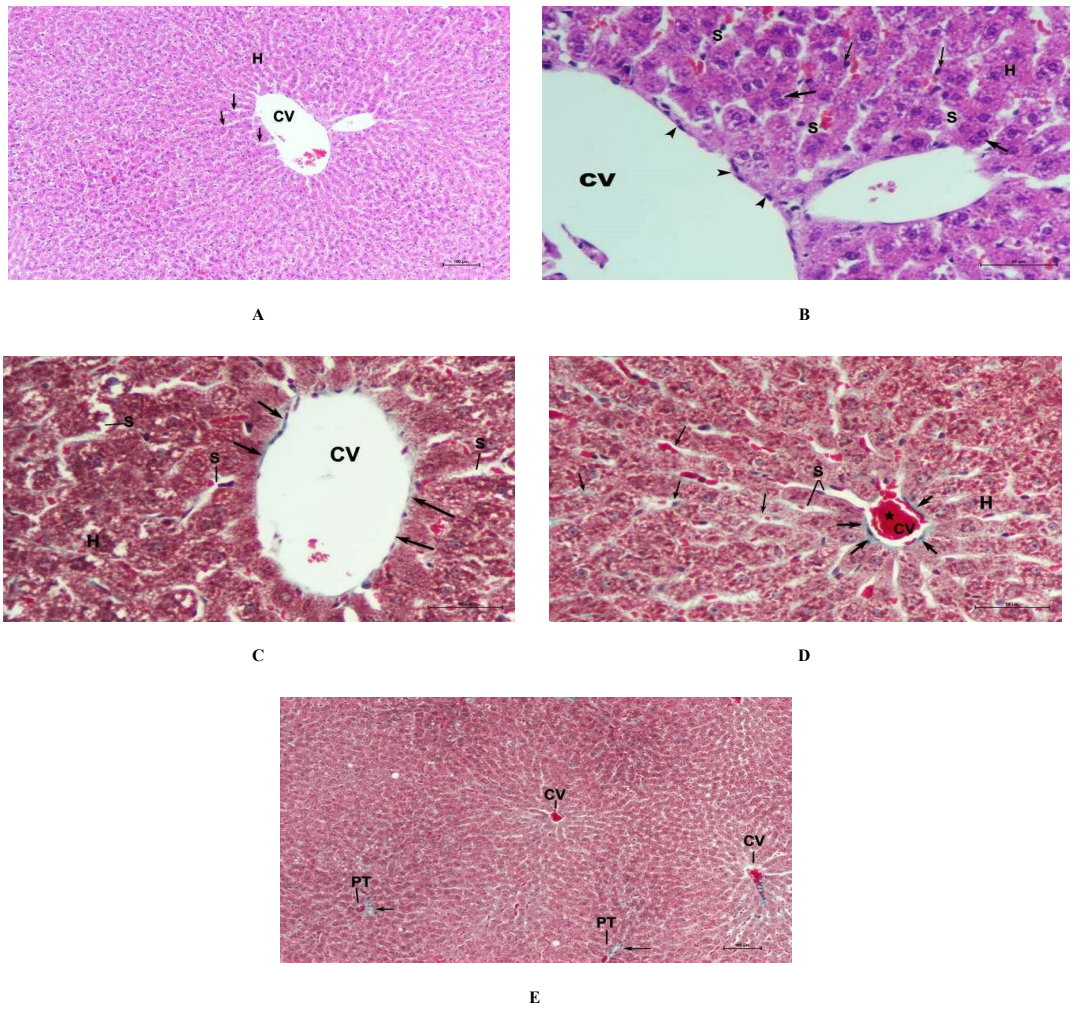

(A) A great recovery of the hepatocytes (H). The hepatic cells nearly retain their radial arrangement around the central vein (CV). Numerous blood sinusoids (arrow) appeared between the hepatic cells. **(B)** The hepatocytes (H) surrounding central vein (CV) which is lined with endothelial cells (arrow head). Notice, blood sinusoids (S) Kupffer cells are observed in the lining of the sinusoids (arrows). **(C)** Few collagen fibres (arrows) around the central vein (CV). **(D)** Few collagen fibres (thick arrows) around the central vein (CV). A very fine thin layer of collagen fibres (thin arrows) is observed surrounding blood sinusoids (S). **(E)** Faint thin blue layer of collagen fibres (arrows) in the portal area (PT) and around the central veins (CV).

Fig 4: Photo micrograph of rat liver administrated with vitamin D and treated with eugenol (GIV).

(iNOS), (TNF-α) and (IL-2) (Makarov, 2000). It is activated by phosphorylation, ubiquitination and subsequent proteolytic degradation of the (NF-κB) protein by activated iNF-κB kinase (IKK), the liberated NF-κB translocate to the nucleus and bind as transcription factor to kb motifs in the promotes of target genes, leading to their transcription. Aberrant NF-κB activity associated with various inflammatory diseases and most anti-inflammatory drugs suppress inflammatory cytokine expression by inhibiting the NF-κB pathway (Tak and Firestein, 200; Keifer *et al.,* 2001). Thus, an NF-κB inhibitor has clinical potential in inflammatory diseases.

The goal of study was to evaluate the effect of eugenol as anti-inflammatory caused significant immunostimulant activity on both specific and non-specific immune mechanisms, where used eugenol in medicine for some inflammatory and pain ailments (Daniel *et al.,* 2009; Farhath *et al*., 2013).

The current study showed that a significant up regulated in iNOS, IL-2 and TNF-α genes expression levels caused by Vitamin D intoxication compared to the control group. In contrast treatment of eugenol caused a significant decreased iNOS, IL-2 and TNF-α genes and down-regulation genes expression levels, this is in agreement with a previous report by Karim *et al.* (2013) and Huang *et al.* (2015).

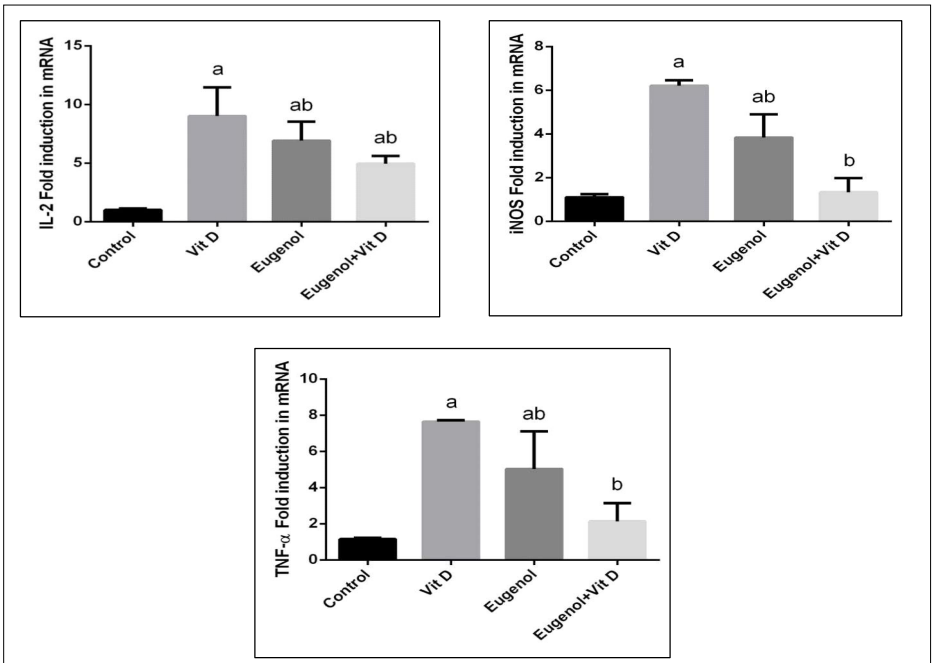

Values are means+SE (n=10). Note a. Significant change at p<0.05 with respect to the negative control group. ab significant change at p<0.05 with respect to the positive group.

Fig 5: Effect of eugenol on hepatic gene expression of IL-2 mRNA, iNOS mRNA and TNF-α mRNA induced by Vitamin D toxicity (100 mg/kg/w).

Phenolic compounds possess diverse biological activities and thought to be beneficial for treating oxidative stress induced cell damage. These activities might be related to their antioxidant activity because of their ability to scavenge free radicals by virtue of the presence of hydroxyl groups (Djeridane *et al.,* 2006). It can be stated that free radical scavenging effect is not limited to phenolic compounds.

The antioxidants play an important role in the regulation and maintenance of metabolism in the body against oxidative stress. It was reported that the induction of antioxidant enzymes reflected an enhancement in cellular protection, ensuring that potential oxidants are metabolized and therefore eliminated more rapidly (Chang *et al.,* 2008; Abdel Moneim, 2014). However, polyphenols are known to modulate transcription and expression of proteins related to the endogenous antioxidant defence. They do so by interacting with antioxidant response elements in promoter regions of genes that encode proteins related to the oxidative injury management (Moskaug *et al.,* 2005).

CONCLUSION

In conclusion, hepatoprotective effects of eugenol are presented through multiple ways. Eugenol inhibiting pro-inflammation by vitamin toxicity and increase the activity of the antioxidant defence system. The action of eugenol may alone increase inflammatory markers *in vivo*. Therefore, we recommend not using it alone except to reduce inflammation resulted from drugs caused inflammation.

ACKNOWLEDGEMENT

The authors extend their appreciation to the Deputyship for Research and Innovation, Ministry of Education in Saudi Arabia for funding this research work through the project number RI-44-0562.

Conflict of interest

All authors declared that there is no conflict of interest.

REFERENCES

Abdel Moneim, A. (2014). Citrus peel extract attenuates acute cyanide poisoning-induced seizures and oxidative stress in rats. CNS and Neurological Disorders-Drug Targets. 13(4): 638-646.

Abdel-Rahman, M.K. and El-Megeid, A.A.A. (2006). Hepatoprotective effect of soapworts (*Saponaria officinalis*), pomegranate peel (*Punica granatum* L) and cloves (*Syzygium aromaticum*) on mice with CCl hepatic intoxication. World Journal of Chemistry. 1(1): 41-46.

Agraharkar, M., Dellinger, O.D., Gangakhedkar, A.K. (2012). Hypercalcemia. Medscape References, New York, USA.

Akillioglu, H.G. and Karakaya, S. (2010). Changes in total phenols, total flavonoids and antioxidant activities of common beans and pinto beans after soaking, cooking and *in vitro* digestion process. Food Sci. Biotechnology. 19: 633-639.

Araki, T., Holick, M.F., Alfonso, B.D., Charlap, E., Romero, C.M., Rizk, D. and Newman, L.G. (2011). Vitamin D intoxication with severe hypercalcemia due to manufacturing and labeling errors of two dietary supplements made in the United States. The Journal of Clinical Endocrinology and Metabolism. 96(12): 3603-3608.

Atabek, M.E., Pirgon, O. and Sert, A. (2006). Oral alendronate therapy for severe vitamin D intoxication of the infant with nephrocalcinosis. Journal of Pediatric Endocrinology and Metabolism. 19(2): 169-172.

Baba, S.A. and Malik, S.A. (2015). Determination of total phenolic and flavonoid content, antimicrobial and antioxidant activity of a root extract of *Arisaema jacquemontii* Blume. Journal of Taibah University for Science. 9: 449-454.

Benzie, I.F.F. and Strain, J.J. (1996). The ferric reducing ability of plasma (FRAP) as a measure of "antioxidant power": The FRAP assay. Analytical Biochemistry. 239: 70-76.

Carlberg, C. (2023). Genomic signaling of vitamin D. Steroids. 198: 109271.

Chaieb, K., Hajlaoui, H., Zmantar, T., Kahla Nakbi, A., Rouabhia, M., Mahdouani, K. and Bakhrouf, A. (2007). The chemical composition and biological activity of clove essential oil, *Eugenia caryophyllata* [*Syzigium aromaticum* (L.) Myrtaceae]: A short review. Phytotherapy Research. 21(6): 501-506.

Chang, J.C., Lin, C.C., Wu, S.J., Lin, D.L., Wang, S.S., Miaw, C.L. and Ng, L.T. (2008). Antioxidative and hepatoprotective effects of *Physalis peruviana* extract against acetaminophen-induced liver injury in rats. Pharmaceutical Biology. 46(10-11): 724-731.

Daniel, A.N., Sartoretto, S.M., Schmidt, G., Caparroz-Assef, S.M., Bersani-Amado, C.A. and Cuman, R.K.N. (2009). Anti-inflammatory and antinociceptive activities A of eugenol essential oil in experimental animal models. Revista Brasileira de Farmacognosia. 19(1B): 212-217.

Djeridane, A., Yousfi, M., Nadjemi, B., Boutassouna, D., Stocker, P. and Vidal, N. (2006). Antioxidant activity of some Algerian medicinal plants extracts containing phenolic compounds. Food Chemistry. 97(4): 654-660.

Farhath, S., Vijaya, P.P. and Vimal, M. (2013). Immunomodulatory activity of geranial, geranial acetate, gingerol and eugenol essential oils: Evidence for humoral and cell-mediated responses. Avicenna Journal of Phytomedicine. 3(3): 224-230.

Gouveia, S. and Castilho, P.C. (2011). Antioxidant potential of artemisia argentea l'hér alcoholic extract and its relation with the phenolic composition. Food Research International Journal. 44: 1620-1631.

Guslandi, M. (2005). Antibiotics for inflammatory bowel disease: Do they work? European Journal of Gastroenterology and Hepatology. 17(2): 145-147.

Halder, S., Mehta, A.K., Kar, R., Mustafa, M., Mediratta, P.K. and Sharma, K. (2011). Clove oil reverses learning and memory deficits in scopolamine-treated mice. Planta Medica. 77(8): 830-834.

Hamed, S.S., Al-Yhya, N.A., El-Khadragy, M.F., Al-Olayan, E.M., Alajmi, R.A., Hassan, Z.K. and Moneim, A.E.A. (2016). The protective properties of the strawberry (*Fragaria ananassa*) against carbon tetrachloride-induced hepatotoxicity in rats mediated by anti-apoptotic and upregulation of antioxidant genes expression effects. Frontiers in Physiology. 7.

Holcombe, H., Parry, N.M., Rick, M., Brown, D.E., Albers, T.M., Refsal, K.R., Morris, J., Kelly, R. and Marko, S.T. (2015). Hypervitaminosis D and Metastatic Calcification in a Colony of Inbred Strain 13 Guinea Pigs, *Cavia porcellus*. Veterinary Pathology. 52(4): 741-751.

Holick, M.F. (2008). Sunlight, vitamin D and health: A D-lightful story. National Academy Science Letters. 2008: 147-166.

Huang, X., Liu, Y., Lu, Y. and Ma, C. (2015). Anti-inflammatory effects of eugenol on lipopolysaccharide-induced inflammatory reaction in acute lung injury *via* regulating inflammation and redox status. International Immunopharmacology. 26(1): 265-271.

Jones, G., Strugnell, S. and DeLuca, H.F. (1998). Current understanding of the molecular action of vitamin D. Physiological Review. 78: 1193-1231.

Karim, Y., Turner, C., Dalton, N., Roplekar, R., Sankaralingam, A., Ewang, M., Fogelman.I and Hampson, G. (2013). The relationship between pro-resorptive inflammatory cytokines and the effect of high dose vitamin D supplementation on their circulating concentrations. International Immunopharmacology. 17(3): 693-697.

Keifer, J.A., Guttridge, D.C., Ashburner, B.P. and Baldwin, A.S. (2001). Inhibition of NF-κB activity by thalidomide through suppression of IκB kinase activity. Journal of Biological Chemistry. 276 (25): 22382-22387.

Leech, M., Metz, C., Santos, L., Peng, T., Holdsworth, S. R., Bucala, R. and Morand, E. F. (1998). Involvement of macrophage migration inhibitory factor in the evolution of rat adjuvant arthritis. Arthritis and Rheumatology. 41(5): 910-917.

Makarov, S.S. (2000). NF-κB as a therapeutic target in chronic inflammation: Recent advances. Molecular Medicine Today. 6(11): 441-448.

Moskaug, J.Ø., Carlsen, H., Myhrstad, M.C. and Blomhoff, R. (2005). Polyphenols and glutathione synthesis regulation. The American Journal of Clinical Nutrition. 81(1): 277S-283S.

Orbak, Z., Doneray, H., Keskin, F., Turgut, A., Alp, H. and Karakelleoglu, C. (2006). Vitamin D intoxication and therapy with alendronate (case report and review of literature). European Journal of Pediatrics. 165(8): 583-584.

Paula-Freire, L.I.G., Molska, G.R. andersen, M. L. and Carlini, E.L.A. (2016). *Ocimum gratissimum* essential oil and its isolated compounds (Eugenol and Myrcene) reduce neuropathic pain in mice. Planta Medica. 82(3): 211-216.

Pfaffl, M.W. (2001). A new mathematical model for relative quantification in real-time RT-PCR. Nucleic Acids Research. 1;29(9): e45.

Prasad, R., Ali, S. and Khan, L. A. (2010). Hepatoprotective effect of *Syzygium aromaticum* extract on acute liver injury induced by thioacetamide. International Journal of Pharmacy and Clinical Research. 2: 68-71.

Ritchlin, C.T., Haas-Smith, S.A., Li, P., Hicks, D.G. and Schwarz, E.M. (2003). Mechanisms of TNF-α-and RANKL-mediated osteoclasto genesis and bone resorption in psoriatic arthritis. Journal of Clinical Investigation. 111(6): 821-831.

Said, M.M. and Rabo, M.M.A. (2017). Neuroprotective effects of eugenol against aluminium-induced toxicity in the rat brain. Archives of Industrial Hygiene and Toxicology. 68(1): 27-37.

Tak, P.P. and Firestein, G.S. (2001). NF-κB: A key role in inflammatory diseases. Journal of Clinical Investigation. 107(1): 7-11.

Vieth, R. (1999). Vitamin D supplementation, 25 hydroxy-vitamin D concentrations and safety. American Journal of Clinical Nutrition. 69: 842-856.

Wang, W., Li, Y., Meng, X. (2023). Vitamin D and neurodegenerative diseases. Heliyon Journal. 9(1): e12877.

Yogalakshmi, B., Viswanathan, P. and Anuradha, C.V. (2010). Investigation of antioxidant, anti-inflammatory and DNA-protective properties of eugenol in thioacetamide-induced liver injury in rats. Toxicology. 268(3): 204-212.