RESEARCH ARTICLE Indian Journal of Animal Research, Volume 58 Issue 7: 1221-1225 (July 2024)

The Possible Side Effects of *Ziziphus spina-christi* Extract on the Liver, Kidneys of Female Rats

Aiman A. Ammari[1], Ahmad R. Alhimaidi[1], Ramzi A. Amran[1], Ahmed M. Rady[1]

10.18805/IJAR.BF-1758

ABSTRACT

Background: It has become important to provide advice and education to herbal remedies users to increase evidence-based awareness of their potential side effects. This research explores the side effects of the *Ziziphus spina-christi* (ZSC) aqueous extract on biochemical indicators and histopathological changes of the liver, kidneys of female rats.

Methods: Fifteen female rats (five in each group) were orally administrated with the extract of ZSC at dosages of 10, 50 and 100 mg/kg bw/day for 14 days. Five other females were considered a control group, given only water. Clinical observations of toxicity were recorded during fifteen days. The biochemical biomarkers of liver (ALT and ALP enzymes) and kidneys (creatinine, uric acid and blood urea nitrogen) were evaluated in blood serum.

Result: In addition, the histopathological alterations in organs were evaluated. The results did not show any clear toxicity on the animal's weight or body organs. The alkaline phosphatase was elevated in female rats who received 50 mg and 100 mg of ZSC aqueous extract in comparison with the control group. The results did not show any significant changes in the serum glucose, BUN, creatinine, uric acid, alanine aminotransferase levels in female rats who received ZSC extract for 14 days. In conclusion, the results showed indications of side effects of the ZSC extract on liver enzymes after treating female rats with ZSC extract for 14 days.

Key words: Alanine transaminase, Alkaline phosphatase, Creatinine, *Ziziphus spina-christi*.

INTRODUCTION

Throughout the ages, the use of natural plants and herbal medicines has become widespread for ailments treatment and human health improvement. These extensive practices of herbal products are supported by the prevailing belief among people that they are safer than conventional drugs since they are natural products. It has become necessary to provide advice and education to users of medicinal herbs to increase evidence-based awareness about the possible side effects of these herbs (Alghadir *et al*., 2022). The unpredictable harmful effects of some herbal products used as complementary and alternative medicines on the liver, kidneys and other organs have been reported (Başaran *et al*., 2022; Jain and Olivero, 2019; Philips *et al*., 2020; Seeff *et al*., 2015).

The Ziziphus genus (Sidr in Arabic) encompasses approximately 135 species belonging to the Rhamnaceae family (Ara *et al*., 2008). They are found across warm-temperate, subtropical and tropical regions and are used as alternative folk remedies. The members of the Ziziphus genus have effective pharmaceuticals as an anti-inflammatory (Alsayari and Wahab, 2021), antipyretic (Jalung *et al*., 2023), analgesic (Henneh *et al*., 2021), antidiabetic (Abdel-Zaher *et al*., 2005), antimicrobial (Yahia *et al*., 2020), antifungal (El-Shahir *et al*., 2022), prevention of hypertension (Mohebbati *et al*., 2018) and treatment of malaria (Hafiz *et al*., 2019). More specifically, diverse methods of extract and various fractions of *Ziziphus spina-christi* (ZSC) have been employed for various remedial attributes such as immune enhancers and antioxidants (Abduljawad, 2020; Al-Ali and Jewad, 2019), decreasing obesity and metabolic inflammation (Yagoub *et al*., 2021), against bacterial infections (El-Kamali and Mahjoub, 2009) and as antidiarrheal agents (Adzu *et al*., 2003). The phytochemicals (like triterpenes, phenolics, flavonoids and saponin glycoside) of ZSC were discussed in various reports (Sakna *et al*., 2022).

Although, numerous investigations have proven the therapeutic importance and pharmacological activities of ZSC, however, fully investigating its side effects still requires further research. This project emphasizes on the side effects of the ZSC aqueous extract on biochemical indicators and histopathological examination of the liver, kidneys of female rats.

MATERIALS AND METHODS

Twenty grams of ZSC leaves were macerated in distilled water (200 ml) at 30°C with shaking at 150 rpm for 24 h. The suspensions were filtered with Whatman filter paper and the residue was re-extracted and then re-filtered as above.

[1]Department of Zoology, Faculty of Science, College of Science, King Saud University, P.O. Box 2455, Riyadh 11451, Kingdom of Saudi Arabia.

Corresponding Author: Aiman A. Ammari, Department of Zoology, Faculty of Science, College of Science, King Saud University, P.O. Box 2455, Riyadh 11451, Kingdom of Saudi Arabia.
Email: aammari@ksu.edu.sa

How to cite this article: Ammari, A.A., Alhimaidi, A.R., Amran, R.A. and Rady, A.M. (2024). The Possible Side Effects of *Ziziphus spina-christi* Extract on the Liver, Kidneys of Female Rats. Indian Journal of Animal Research. 58(7): 1221-1225. doi: 10.18805/IJAR.BF-1758.

Submitted: 16-01-2024 **Accepted:** 11-04-2024 **Online:** 06-05-2024

The two filtrates were pooled together and evaporated in a rotary evaporator at 40°C. The concentrated filtrate of each plant (water crude extract) was weighed and re-dissolved in normal saline at a final concentration of 100 mg, 50 mg, 10 mg /kg and stored at -20°C until use.

The twenty of healthy female rats (180-220 g) with ages between 12 and 14 weeks were sourced from the animal facility at the Zoology Department of the Science College, King Saud University (KSU). These rats were acclimated to a well-ventilated environment at a room temperature of 25±2°C, with a regular 12-hour light and dark cycle. They were provided with a standard diet and access to water. All experimental procedures adhered to the guidelines set by the ethics committee and the Institutional Animal Care at KSU (Approval no: KSU-SE-23-06). The four separate groups of female rats, each consisting of five animals, were exposure as the following: the first group, the control, received water, while the second, third and fourth groups were administered with the extract at dosages of 10, 50 and 100 mg/kg bw/day for 14 days.

Female rats were fasted for 12 hours to examine blood glucose levels using a Glucometer device. The blood was drawn directly from the heart of female rats into plain tubes, then centrifuged at 3500 rpm for 15 minutes to obtain the serum and frozen in the refrigerator until analysis. The clinical biochemical biomarkers of liver (ALT and ALP enzymes) and kidneys (creatinine, uric acid and blood urea nitrogen) were evaluated in blood serum.

The data collected from the experiment underwent analysis using the GraphPad Prism (version 10.1.1) software. To assess the normal distribution of our data, the Shapiro-Wilk test was employed. Various parameters such as liver enzymes, kidney parameters, organ weights, were subjected to one-way ANOVA, followed by Tukey's test. The results are reported as mean values accompanied by their standard deviations.

RESULTS AND DISCUSSION

No signs of poisoning or death were observed among female rats during the fourteen days of oral administration of ZSC aqueous extract. In addition, there was no significant difference between the daily body weights of female rats during the experimental period (Fig 1). The average weights

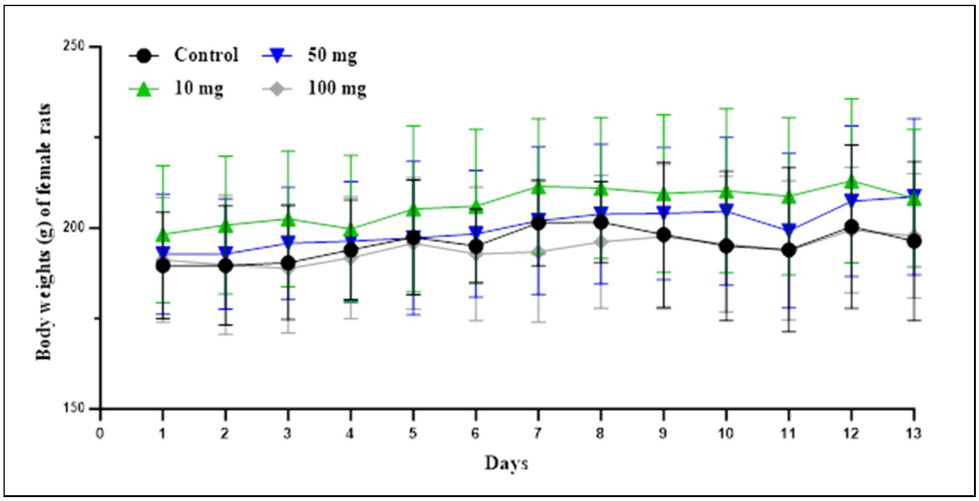

Fig 1: Results of female rat mean body weight of treated with Ziziphus spina-christi compared to control group.

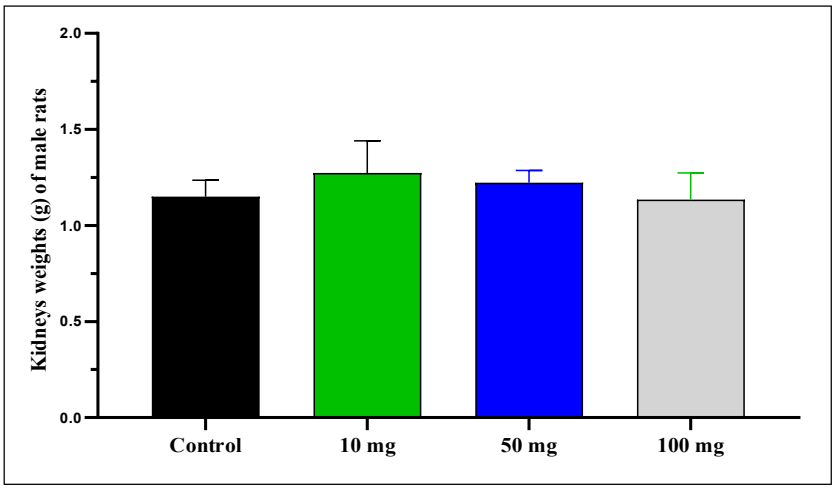

Fig 2: Results of female rat mean kidney weight of treated with *Ziziphus spina-christi* compared to control group.

of kidneys of animals treated with the ZSC aqueous extract did not show significant differences compared to the control group (Fig 2).

Fig 3 shows no significant differences in the serum glucose concentrations (mg/dl) among female rats after two weeks of exposure to the ZSC extract. BUN, creatinine and uric acid levels displayed no statistical difference (P>0.05) between female rats groups (Fig 3). The alkaline phosphatase was elevated in female rats who received 50 mg (p<0.05) and 100 mg (p<0.01) of ZSC aqueous extract

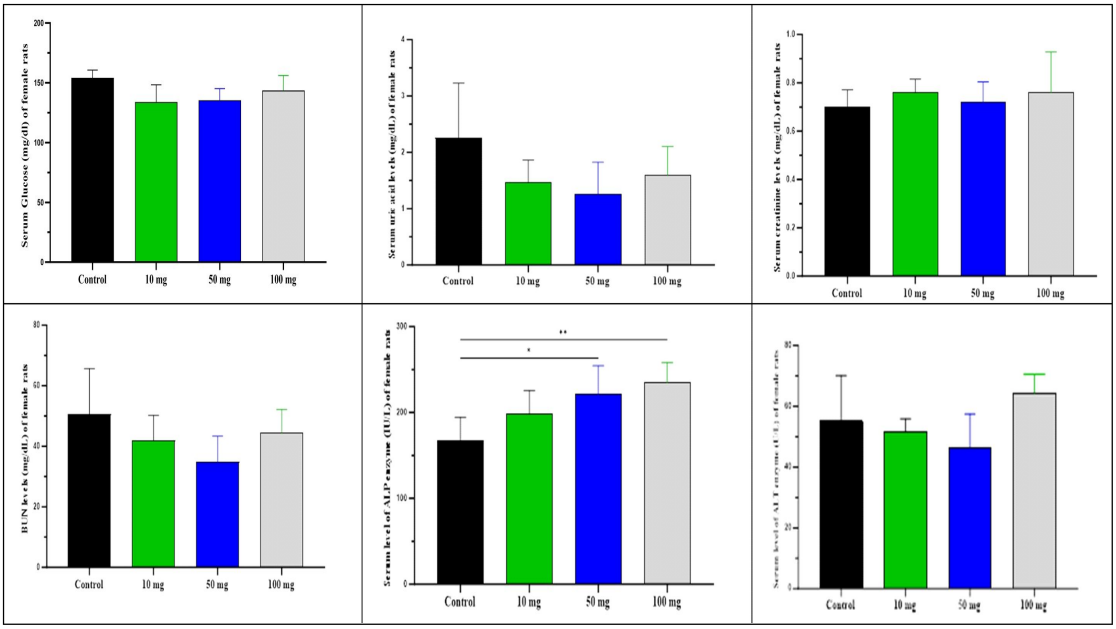

Fig 3: Means of blood glucose, uric acid, creatinine, BUN, ALP and ALT enzymes level of female rats group treated with *Ziziphus spina-christi* extract for two weeks.

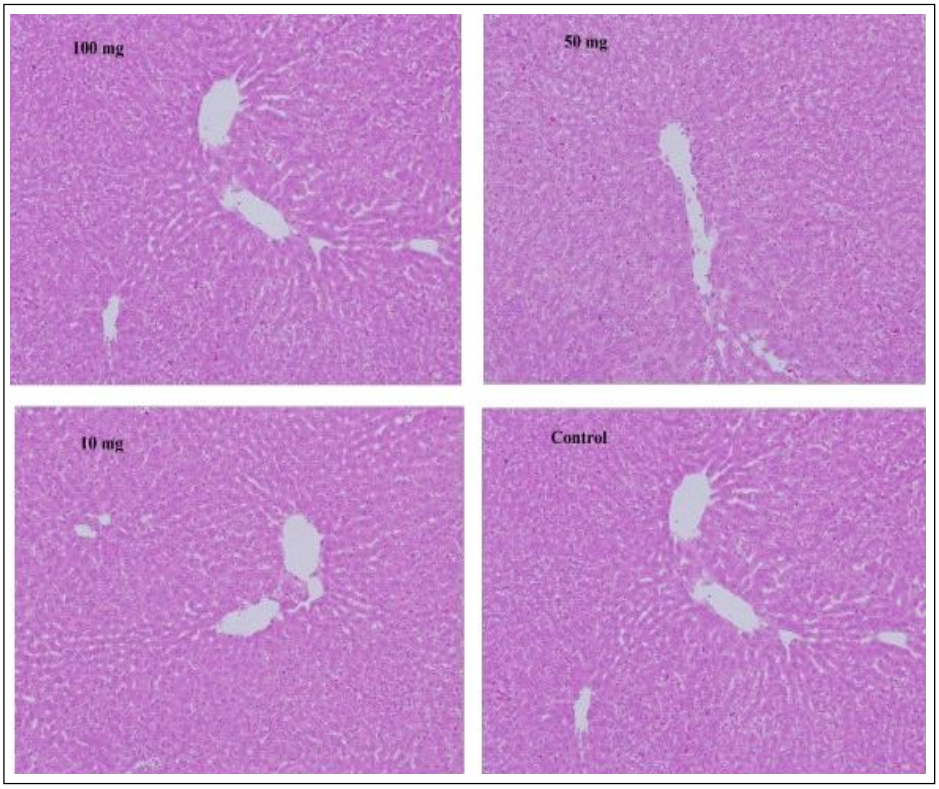

Fig 4: Histology of the livers of the female rat groups treated with *Ziziphus spina-christi* extract for two weeks compared to the normal.

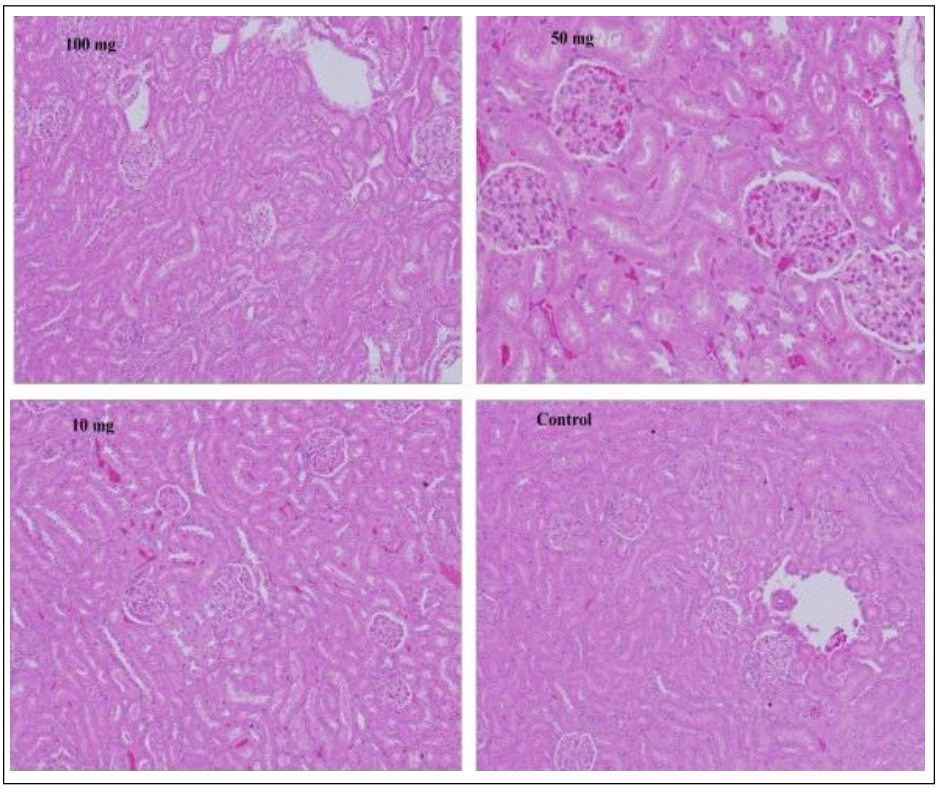

Fig 5: Histology of the kidney of the female rat groups treated with *Ziziphus spina-christi* extract for two weeks compared to the normal.

in comparison with the control group. In addition, alanine aminotransferase was slightly increased at a dosage of 100 mg group with no significant differences (P>0.05) compared to rats in the control group (Fig 3).

No pathological changes were revealed in the hepatocytes, portal sinuses and central veins of hepatic lobules (Fig 4). In renal histological sections, glomerular capsules, renal tubules and renal capillary structures were normal in all groups (Fig 5).

The lack of reports discussing the toxicity of ZSC extract justifies the need for more research to confirm its safety and to grow evidence-based awareness of its potential side effects. This research explores the side effects of the ZSC aqueous extract on biochemical indicators and histopathological changes of the liver, kidneys and ovary of female rats.

The liver is the main site metabolism of xenobiotics and toxic substances and therefore the liver is considered one of the organs most affected by these substances. The hepatocytes contain high levels of the ALT and ALP enzymes compared to other organs; therefore, they are considered biomarkers for detecting hepatobiliary damage (Henneh *et al*., 2022; Islam *et al*., 2021; Ozer *et al*., 2008).

CONCLUSION

Scientists are putting a lot of effort into finding natural substitutes that humans may use without risk. As a result, research on a variety of natural alternatives persisted and our investigation thereafter concentrated on assessing the use of *Ziziphus spina-christi* extract. Although our research showed some minor adverse effects on enzymes, this is not thought to be conclusive evidence for its intended application. Studies have demonstrated its efficacy in treating a variety of illnesses and infections. Similarly, weights were not considerably impacted by our findings. Additional many researches are necessary since there could be other variables, such the length of exposure, the extract's concentration, the dose, and several other issues.

ACKNOWLEDGEMENT

This study was funded by the Researchers Supporting Project (number RSP-2024/232), King Saud University, Riyadh, Saudi Arabia.

Conflict of interest

The authors of the manuscript declare that they have no competing or financial interests.

REFERENCES

Abdel-Zaher, A.O., Salim, S.Y., Assaf, M.H. and Abdel-Hady, R.H. (2005). Antidiabetic activity and toxicity of *Zizyphus spina-christi* leaves. Journal of Ethnopharmacology. 101(1-3): 129-138.

Abduljawad, S.H. (2020). Digestive fermentation, antioxidant status and haemato-biochemical indices of growing rabbits fed on diets supplemented with *Ziziphus spina-christi* leaf. Journal of Nutrition and Metabolism.

Adzu, B., Amos, S., Amizan, M.B. and Gamaniel, K. (2003). Evaluation of the antidiarrhoeal effects of *Zizyphus spina-christi* stem bark in rats. Acta Tropica. 87(2): 245-250.

Al-Ali, J.T. and Jewad, A.M. (2019). Effect of the alcoholic or the aqueous extracts of *Ziziphus spina-christi* leaves on the white blood cells and the oxidative stress status in local rabbits. Journal of International Pharmaceutical Research. 46(5): 548-554.

Alghadir, A.H., Iqbal, A. and Iqbal, Z.A. (2022). Attitude, beliefs and use of herbal remedies by patients in the Riyadh region of Saudi Arabia. In Healthcare. MDPI. 10(5): 907.

Alsayari, A. and Wahab, S. (2021). Genus *Ziziphus* for the treatment of chronic inflammatory diseases. Saudi Journal of Biological Sciences. 28(12): 6897-6914.

Ara, H., Hassan, M.A. and Khanam, M. (2008). Taxonomic study of the genus *Ziziphus* Mill.(Rhamnaceae) of Bangladesh. Bangladesh Journal of Plant Taxonomy. 15(1): 47.

Başaran, N., Paslı, D. and Başaran, A.A. (2022). Unpredictable adverse effects of herbal products. Food and Chemical Toxicology. 159: 112762.

El-Kamali, H.H. and Mahjoub, S.A.T. (2009). Antibacterial activity of Francoeuria crispa, *Pulicaria undulata*, *Ziziphus spina-christi* and *Cucurbita pepo* against seven standard pathogenic bacteria. Ethnobotanical Leaflets. (6): 6.

El-Shahir, A.A., El-Wakil, D.A., Abdel Latef, A.A.H. and Youssef, N.H. (2022). Bioactive compounds and antifungal activity of leaves and fruits methanolic extracts of *Ziziphus spina-christi* L. Plants. 11(6): 746.

Hafiz, T.A., Mubaraki, M.A., Diab, M.S., Dkhil, M.A. and Al-Quraishy, S. (2019). Ameliorative role of *Ziziphus spina-christi* leaf extracts against hepatic injury induced by Plasmodium chabaudi infected erythrocytes. Saudi Journal of Biological Sciences. 26(3): 490-494.

Henneh, I.T., Ahlidja, W., Alake, J., Kwabil, A., Ahmed, M.A., Kyei-Asante, B. and Armah, F.A. (2022). *Ziziphus abyssinica* root bark extract ameliorates paracetamol-induced liver toxicity in rats possibly via the attenuation of oxidative stress. Toxicology Reports. 9: 1929-1937.

Henneh, I.T., Armah, F.A., Ameyaw, E.O., Biney, R.P., Obese, E., Boakye-Gyasi, E. and Ekor, M. (2021). Analgesic effect of *Ziziphus abyssinica* involves inhibition of inflammatory mediators and modulation of KATP channels, opioidergic and nitrergic pathways. Frontiers in Pharmacology. 12: 714722.

Islam, M.T., Quispe, C., Islam, M.A., Ali, E.S., Saha, S., Asha, U.H. and Sharifi-Rad, J. (2021). Effects of nerol on paracetamol -induced liver damage in Wistar albino rats. Biomedicine and Pharmacotherapy. 140: 111732.

Jain, A. and Olivero, J.J. (2019). Herbal Nephropathy. Methodist Debakey Cardiovasc J. 15: 228-230. doi: 10.14797/mdcj-15-3-228.

Jalung, F., Rindayani, M.F. and Christiani, M. (2023). Uji Aktivitas Antipiretik Ekstrak Daun Bidara (*Ziziphus Spina Christi* L) Terhadap Mencit Jantan (*Mus musculus*). Journal of Pharmaceutical and Sciences. 1654-1657.

Mohebbati, R., Bavarsad, K., Rahimi, M., Rakhshandeh, H., Khajavi Rad, A. and Shafei, M.N. (2018). Protective effects of long-term administration of *Ziziphus jujuba* fruit extract on cardiovascular responses in L-NAME hypertensive rats. Avicenna J. Phytomed. 8: 143-151.

Ozer, J., Ratner, M., Shaw, M., Bailey, W. and Schomaker, S. (2008). The current state of serum biomarkers of hepatotoxicity. Toxicology. 245: 194-205. doi: 10.1016/j.tox.2007.11.021.

Philips, C.A., Ahamed, R., Rajesh, S., George, T., Mohanan, M. and Augustine, P. (2020). Comprehensive review of hepatotoxicity associated with traditional Indian Ayurvedic herbs. World Journal of Hepatology. 12(9): 574.

Sakna, S.T., Maghraby, Y.R., Abdelfattah, M.S. and Farag, M.A. (2022). Phytochemical diversity and pharmacological effects of triterpenes from genus Ziziphus: A comprehensive review. Phytochemistry Reviews. 1-26.

Seeff, L.B., Bonkovsky, H.L., Navarro, V.J. and Wang, G. (2015). Herbal products and the liver: A review of adverse effects and mechanisms. Gastroenterology. 148: 517-532.e513. doi: 10.1053/j.gastro.2014.12.004.

Yagoub, A.E.A., Alshammari, G.M., Subash-Babu, P., Mohammed, M.A.A., Yahya, M.A. and Alhosain, A.I. (2021). Synthesis of *Ziziphus spina-christi* (Jujube) root methanol extract loaded functionalized silver nanoparticle (ZS-Ag-NPs); physiochemical characterization and effect of ZS-Ag-NPs on adipocyte maturation, adipokine and vascular smooth muscle cell interaction. Nanomaterials. 11(10): 2563.

Yahia, Y., Benabderrahim, M.A., Tlili, N., Bagues, M. and Nagaz, K. (2020). Bioactive compounds, antioxidant and antimicrobial activities of extracts from different plant parts of two Ziziphus Mill. species. PloS one. 15(5): e0232599.