RESEARCH ARTICLE Indian Journal of Animal Research, Volume 58 Issue 6: 991-998 (June 2024)

Clinical and Radiological Evaluation of Racehorses with Sesamoiditis: Case Series

Emine Çatalkaya[1]

10.18805/IJAR.BF-1766

ABSTRACT

Background: Sesamoiditis causes intermittent lameness in horses and is characterized by the enlargement of vascular channels, local osteolysis, osteophyte and enthesophyte formation on radiography. This study aimed to report the relationship between the clinical and radiological findings of racehorses diagnosed with sesamoiditis, the treatment applied and long-term results.

Methods: The study included a total of 30 Arabian and Thoroughbred racehorses aged 2-7 years diagnosed with sesamoditis based on clinical and radiological examinations. These horses were treated and followed for nine months.

Result: Radiographic examination revealed different numbers of enlarged vascular channels in the proximal sesamoid bones in all the cases and osteophytosis (n=3), enthesophytosis (n=9), osteolysis (n=3) and fractures (n=6) in some cases. In addition, low heels were important in 27 cases. The body conformation and low-heeled hoof structure play a role in the development of sesamoiditis in horses and should be considered. As a result, body structure and low heel structure play a role in the development of sesamoiditis in horses and should be considered. This situation should be tried to be corrected by farriers during the foaling period. Sesamoiditis can have a positive prognosis with appropriate treatment and adequate rest, for this reason, treatment should be started in the early period.

Key words: Horse, Lameness, Metacarpophalangeal joint, Sesamoiditis.

INTRODUCTION

The two proximal sesamoid bones on the palmar/plantar surface of the metacarpophalangeal/metatarsophalangeal (MCP/MTP) joints in horses provide stability to the suspensory ligament and aid in the prevention of excessive/beyond physiological range hyperextension of these joints while the horse is performing (Hubert, 2001).

Sesamoiditis is a condition characterised by enlargement of the vascular channels of the proximal sesamoid bones (Lloyd *et al*., 2020; Sirin *et al*., 2020), local osteolysis and osteophyte and enthesophyte formation (Yücel, 2007; Reesink, 2017; Kumar *et al*., 2019). Sesamoiditis causes a decrease in exercise performance, especially in racehorses (Plevin *et al*., 2016; Sirin *et al*., 2020). Several sesamoids and more than one extremity may be affected simultaneously. Although the etiology of this disease is unclear, it has been reported that the vascular structure of the proximal sesamoid bones can be easily affected by traumas (Roux and Cartens, 2018), such as stress caused by high impacts and concussions to the base of the foot (Yücel, 2007), excessive hyperextension of MCP or MTP joint and partial rupture of the flexor tendons (superficial and deep flexor tendons, especially the superficial flexor tendon) and suspensory ligament around the MCP or MTP joint (Yücel, 2007; Plevin *et al*., 2016) or lesions of the inter-sesamoidal ligament (Roux and Cartens, 2018). It has been suggested that these factors cause a disruption in the nutrition of the bones, leading to bone demineralisation (Yücel, 2007; Plevin *et al*., 2016). In addition, the presence of sesamoiditis can weaken the bone and may result in fractures.

[1]Department of Surgery, Faculty of Veterinary Medicine, Dicle University, Diyarbakır-21200, Türkiye.

Corresponding Author: Emine Çatalkaya, Department of Surgery, Faculty of Veterinary Medicine, Dicle University, Diyarbakır-21200, Türkiye. Email: eminecatalkaya21@gmail.com

How to cite this article: Çatalkaya, E. (2024). Clinical and Radiological Evaluation of Racehorses with Sesamoiditis: Case Series. Indian Journal of Animal Research. 58(6): 991-998. doi: 10.18805/IJAR.BF-1766.

Submitted: 29-01-2024 **Accepted:** 16-03-2024 **Online:** 25-04-2024

The presence of radiographic vascular channels, especially in cases with no apparent lameness, was noted as an incidental finding in thoroughbred racehorses and it was reported that the racing performance of these horses was not affected (Santschi, 2013; Roux and Carstens, 2018; Lloyd *et al*., 2020).

Radiologic evaluation is as important as clinical examination in the diagnosis of sesamoiditis (Santschi, 2013; Roux and Carstens, 2018; Izci *et al*., 2018). Radiological imaging examination in the following four views is recommended: dorsoproximal-palmarodistal oblique (considered as the best view for detecting the lesions), lateromedial, dorsomedial-palmarolateral oblique and dorsolateral-palmaromedial oblique (Santschi, 2013; Roux and Carstens, 2018). Sesamoiditis is classified as articular and non-articular sesamoiditis. In its articular form, it is characterized by osteophytosis in the apical and basilar parts of the proximal sesamoid bone and usually develops secondary to inflammation of the relevant joint. The non-articular form is associated with primary diseases involving

the suspensory ligament and is characterized by dilated vascular channels and increased bone production in the abaxial or basal parts of the proximal sesamoid bone (Diakakis *et al*., 2005).

This study aimed to report the relationship between the clinical and radiological findings of racehorses diagnosed with sesamoiditis, the treatment applied and long-term results.

MATERIALS AND METHODS

Ethical statement

This study protocol was approved by the Dicle University Health Sciences Application and Research Center Local Ethics Committee (E-35582840-604.01.01-133495).

Animals

The study included 30 Arabian (n=17) and Thoroughbred (n=13) racehorses aged 2-7 years old, who experienced lameness, increased sensitivity in the MCP and/or MTP joint region and decreased exercise performance, at the Diyarbakır Hippodrome Directorate Equine Hospital.

Clinical examination

Full orthopeadic examination of horses were performed after obtaining medical history (so observation of a standing horse, examination in movement, flexion tests and diagnostic analgesia, after that x-rays). Further, the horses were assessed for lameness during walking and trotting. In addition, horses with intermittent lameness (post-gallop lameness) were examined after having them gallop. Then, the entire extremity was palpated and examined for heat and sensitivity. Each horse was made to trot after holding the MCP and/or MTP joint in flexion for 1 minute (flexion test). Intra-articular anaesthesia was administered and palmar digital as well as abaxial nerves blockades were performed in the cases in which the location of the lameness could not be determined during clinical examination. These procedures were performed from distal to proximal in the extremity by injecting 3 ml of local anaesthetic (Prilocaine Hydrochloride, Citanest 2%, Sanofi, Türkiye) for intra-articular anaesthesia according to the size of the joint and 3-5 ml of local anaesthetic (Prilocaine Hydrochloride, Citanest 2%, Sanofi, Türkiye) around the nerve for nerve blockade. Lameness was evaluated by making the horse trot for 10-20 minutes after administering the local anaesthetic. Additionally, lameness cases detected during the examination were scored between 1 and 5 according to the lameness scale standardized by the American Association of Equine Practitioners (AAEP) (0: Lameness not perceptible under any circumstances. 1: Lameness is difficult to observe and is not consistently apparent, regardless of circumstances (*e.g.* under saddle, circling, inclines, hard surface, *etc*.). 2: Lameness is difficult to observe at a walk or when trotting in a straight line but consistently apparent under certain circumstances (*e.g.* weight-carrying, circling, inclines, hard surface, *etc*.). 3: Lameness is consistently observable at a trot under all circumstances. 4: Lameness is obvious at a walk. 5: Lameness produces minimal weight bearing in motion and/or at rest or a complete inability to move) (Niemelä *et al*., 2016).

Radiological examination

Radiographic images of the MCP and MTP joint were taken in the lateromedial, dorsoproximal-palmarodistal oblique, dorsomedial-palmarolateral oblique and dorsolateral-palmaromedial oblique views and interpreted. Sesamoiditis was diagnosed based on findings such as erosions around the sesamoid bone, osteophytic areas, enlargement of vascular channels and osteolysis observed in the sesamoid bone in these radiographic positions.

Treatment

Cases with sesamoiditis who did not develop fractures were administered Phenylbutazone (Equi-Butazon, Provet, Türkiye, 4 mg/kg, slowly IV) for five days and received ten days of stable rest followed by walking exercises for three months. Cold hydrotherapy was recommended for cases with symptoms of inflammation and warm hydrotherapy and vitamin D (Devit-3 ampoule, Deva, Türkiye, IM) 3-4 weeks apart was recommended for cases with bone proliferation in the joint. To reduce inflammation and pain in the joint, intra-articular corticosteroid (Sinacort A, İbrahim Etem, 40 mg, Türkiye) and hyalorunic acid (Regenflex, Intrafarma, 2 ml, Turkiye) injections were administered and glycosaminoglycan (Glucosamine Condroitin Complex, Solgar, USA, 5 tablets daily via the oral route) was prescribed for a period of three months. In addition, 1 mg/kg tiludronate sodium (Tildren, Ceva, Türkiye) was diluted in 3000 ml isotonic sodium chloride (0.9% NaCl, Eczacıbaşı, Türkiye) solution and administered through the jugular vein as a slow infusion (single dose). Orthopaedic horseshoes with raised heels covered with a flexible material were recommended for cases with low heels to prevent concussions from the base. Bandages were applied for one week in cases of sesamoiditis that were not complicated with fractures and for three weeks in cases complicated with fractures. Follow-up radiography of all horses was performed every three months following the treatment. The same treatment was applied a second time to horses with sesamoiditis in which there was no clinical or radiological improvement. No second treatment was applied to horses with clinical and/or radiological improvement or functional improvement. Cryotherapy was administered for persistent cases that did not improve at the 6th month (2nd quarterly checkup) follow-up after treatment. Subsequently, a wound bandage was applied and the results were evaluated. The horses included in the study were followed up over a period of nine months.

RESULTS AND DISCUSSION

The horses included in the study consisted of Arabian (n=17) and Thoroughbred (n=13) horses aged 2-7 years. The breed,

sex and age distributions of these horses and their affected extremities are summarised in Table 1.

In cases with a lameness score of 1-2 (n=10) in the clinical examination performed after the medical histories of the horses were taken (Table 1), lameness could not be determined exactly in the examination. The medical histories of these horses reported a decrease in performance. In addition, local inflammation symptoms such as heat and pain were not evident on palpation of the affected area in six of them. Moreover, only one of these six horses had a positive flexion test. Of the 10 horses with a lameness score of 1-2, the other 4 had tenderness on palpation of the proximal sesamoid bone and the flexion test of these horses was positive. The number of dilated vascular channels on radiographs of horses with a lameness score of 1-2 (n=10) was 2-3. In addition to these findings, enthesophitis was also detected in one case. In this case, there were 2 dilated vascular channels, enthesophitis and clinical sensitivity on palpation of the area.

Although there was no abnormal finding (swelling, heat, *etc.*) in three of the cases with a lameness score of 3 (n=9), lameness during trot was observed, the lameness increased after the flexion test. There were 3-4 dilated vascular channels, enthesophitis and osteophitis findings on the radiographs of the cases with lameness score 3 (n=9). In addition to dilated vascular channels, both enthesophitis and osteophitis were present in 2 cases.

Pain and sensitivity on the palmar/plantar surface of the MCP or MTP joints were detected on clinical examination of the cases with a lameness score of 4-5 (n=11). In these cases, both the number of dilated vascular channels (4-5 or more) was higher than in other cases and the radiographic findings were more serious. There were osteophitis, enthesophitis, fracture and osteolysis findings on the radiographs of these cases.

The findings from the radiographs of the relevant joints of all the horses included in the study taken in the four views are summarised in Table 1. Enlarged vascular channels of ≥2 millimetres (mm) in the proximal sesamoid bone (n=30, Fig 1,3), erosions on the abaxial surface of the sesamoid bone (n=11, Fig 1,2), enthesophytosis (n=9, Fig 1,2), osteophytosis (n=3, Fig 1), fracture (n=6, Fig 1,2) and osteolysis (n=3, Fig 2) were observed on radiography. It was determined that the fracture was at the base of the sesamoid bone in three of the cases with fractures and at the midline of the bone in the other three cases.

Table 1: Distribution of cases according to age, race, gender, clinical findings and radiological findings.

			Horses	
			Thoroughbred horse	Arabian horse
Age			2 years old: 1 3 years old: 5 4 years old: 2 5 years old: 4 7 years old: 1	3 years old: 8 4 years old: 5 6 years old: 2 7 years old: 2
Gender			F: 2, M: 11	F: 5, M: 12
Forelimb			10	14
Hindlimb			3	3
Radiological findings	2 mm ≥ enlarged vascular canal	2	2	2
		3	4	5
		4	5	6
		5 and above	2	4
	Fracture		4	2
	Enthesophitis		5	4
	Osteophytis		1	2
	Osteolysis		2	1
Lameness score	0		-	-
	1		1	2
	2		3	4
	3		2	7
	4		4	3
	5		3	1

F: Female, M: Male Lameness score: 0: Lameness not perceptible under any circumstances. 1: Lameness is difficult to observe and is not consistently apparent, regardless of circumstances (*e.g.* under saddle, circling, inclines, hard surface, *etc.*). 2: Lameness is difficult to observe at a walk or when trotting in a straight line but consistently apparent under certain circumstances (*e.g.* weight-carrying, circling, inclines, hard surface, *etc.*). 3: Lameness is consistently observable at a trot under all circumstances. 4: Lameness is obvious at a walk. 5: Lameness produces minimal weight bearing in motion and/or at rest or a complete inability to move.

It was determined that most of the cases (n=27) included in the study were in the form of nonarticular sesamoiditis, while the other three cases were in both articular and nonarticular forms.

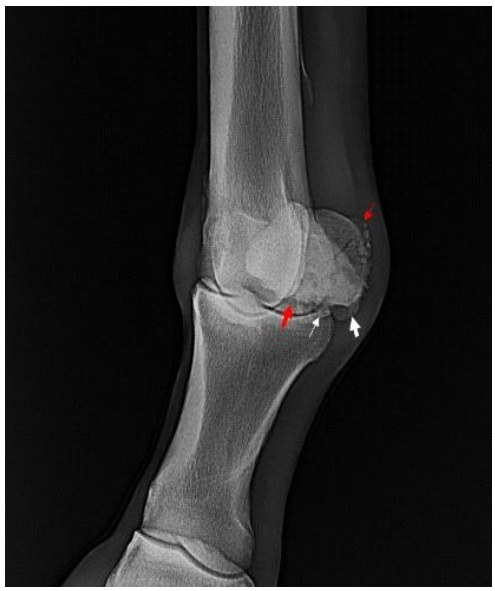

Bone outgrowths around the sesamoid bone are shown with a red arrow, osteophyte with a thick red arrow, enthesophitis with a thick white arrow and a broken white arrow at the base of the sesamoid bone.

Fig 1: Non-articular and articular sesamoiditis in a 3-year-old Arabian horse.



Irregularity in the wall of the proximal sesamoid bone is shown with a red arrow, fracture near midline of sesamoid bone with a white arrow, osteolysis with a thick white arrow and enthesophitis with a thick red arrow.

Fig 2: Non-articular sesamoiditis and fracture of the sesamoid bone in a 7-year-old Arabian horse.

In the present study, the forelimb was found to be affected in most of the cases (n=24). In contrast, the hindlimb was affected in six cases. In addition, the pastern was found to be long (fetlock close to the ground) (n=22), as an anatomical predisposition in almost all horses included in the study (n=27) and the heels were found to be low (heels close to the ground) (n=27). In one of the cases included in the study, bilateral sesamoiditis was observed in the forelimb. In addition to these findings, it was observed that among the proximal sesamoid bones, the medial (n=24) sesamoid bones were affected in the forelimb and the lateral (n=6) sesamoid bones in the hindlimb.

A complete recovery was observed in 13 of the treated horses (n=30). The other 13 horses did not show any radiologically observable change in their condition (their existing condition did not improve nor worsen); however, a functional improvement was observed during clinical examination and in their performance. The remaining four cases did not respond to treatment and these horses did not participate in any race again.

The enlargement vascular channel diameters of the horses (n=13) that recovered with the applied treatment in clinical and radiological examination were smaller than the other cases, rather than the number of enlargement vascular channels. 3 months (single cure) was applied to 10 of these cases. The remaining 3 cases were treated for 6 months (2 cures) and cryotherapy was also applied to these horses. In addition, the lameness score (1-3) of the fully recovered horses was lower than the functionally recovered and non-recovered horses. Although two cures of medical treatment (6 month) and cryotherapy were applied to the functionally recovered horses, there was no visible change in their radiological examinations, but their clinical examination showed no pain, no lameness and their performance improved. In 4 cases, no improvement was observed despite two cures of medical treatment and cryotherapy after the 6th month. It was determined that one of these horses had a fracture in the midline of the sesamoid bone along with other sesamoiditis findings and the remaining 3 horses had many enlargement vascular channels. Additionally, the lameness score of these horses was between 4-5.

Intense exercise programmes lead to stress and may cause musculoskeletal system injuries in racehorses. Factors such as excessive hyperextension in the fetlock joint (MCP/MTP joint) while bridling during racing exercises or races can injure both the MCP/MTP joint and hoof in thoroughbred racehorses (Menarim *et al.*, 2012). Proximal sesamoid bones are under a large amount of stress during exercise in racehorses and this is one of the common causes of lameness (Hubert *et al.*, 2001; Diakakis *et al.*, 2005; Yanmaz and Okumus, 2018).

Although the aetiology of sesamoiditis has not been fully elucidated, it has been associated with disruption of the vascular structure, lesions in the ligaments adhering to the sesamoid bones and inflammation developing in the surrounding tissues (Hubert *et al.*, 2001; Diakakis *et al.*, 2005;

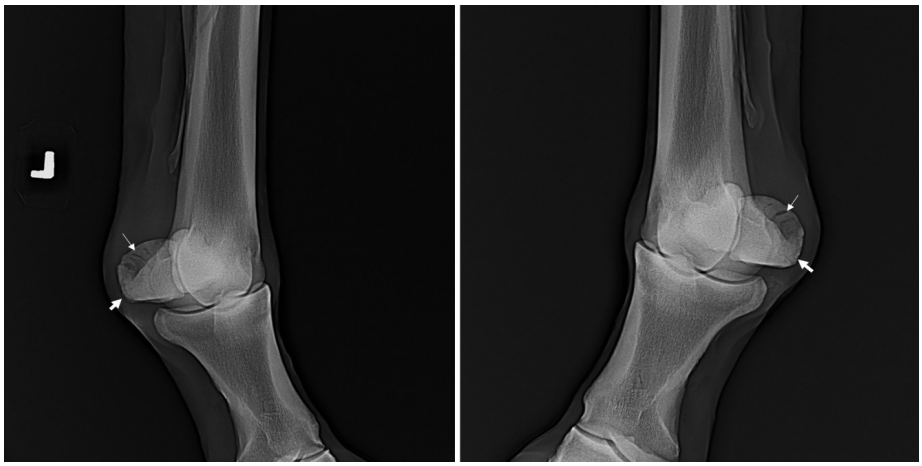

Enlarged vascular channels are indicated by a white arrow and irregularity in the sesamoid bone wall is indicated by a thick white arrow.

Fig 3: Non-articular sesamoiditis in a 4-year-old Thoroughbred horse.

Kumar *et al.*, 2019). Sesamoiditis is characterised by radiolucent areas and new bone formations in the sesamoid bones on radiography. Although it does not manifest with a very specific pathological finding, clinically significant symptoms may occur. There is usually pain on palpation of the affected sesamoid bones and/or when the joint is flexed. In some cases, lameness may occur only after high levels of exercise (Diakakis *et al.*, 2005). In this study, pain was detected on palpation and flexion of the MCP/MTP joints in 22 cases and on flexion in three cases. In the remaining five cases, the location of pain and lameness was determined by intra-articular and perineural analgesia.

Repetitive traumas cause inflammatory changes in the MCP/MTP joint and surrounding tissues as well as proximal sesamoid bones. The diagnosis of sesamoiditis is clinically confirmed if the lameness findings are present on examination, the source of the lameness is located at the MCP/MTP joints and there are apparent intra-osseous vascular channels and osteophytic and entesophytic changes on the radiographs (Hubert *et al.*, 2001; Yücel, 2007). Vascular channels in the sesamoid bones are considered normal if they are not apparent on radiographs or are smaller than 2 mm. In this study, the diagnosis was not made based only on enlarged vascular channels on radiological examination. Cases with enthesophytosis, osteophytosis and osteolysis in the sesamoid bones without enlargement of many vascular channels were also considered as sesamoiditis and treated. This is because these changes observed on radiographs cause inflammation and sensitivity of the sesamoid bones.

Sesamoiditis is clinically characterised by intermittent lameness in the forelimb and, less frequently, in the hindlimb (Cornelissen *et al.*, 2002). The load on the forelimb is higher than that on the hindlimb (Spike-Pierce, 2003; Izci *et al.*, 2015; Kumar *et al.*, 2019) and thus it is estimated that the sesamoid changes in the forelimbs may have a negative effect on performance parameters (Spike-Pierce, 2003). The MCP joint has been identified as the most common site of injury in racehorses (Menarim *et al.*, 2012). In thoroughbred racehorses, the medial sesamoid bones are more frequently affected by sesamoiditis than the lateral sesamoid bones, as joint hyperextension is concentrated in the middle part of the extremity (Menarim *et al.*, 2012). In this study, it was observed that sesamoiditis developed more often in the forelimb and medial sesamoid bone. In addition, it was observed that the vast majority of the horses (n=27) included in the study had a long pastern (n=22) and low heels (n=27) as an anatomical predisposition. Until recently, it was recommended that the normal hoof angle should be 48°-55° for the forelimb and 52°-60° for the hind legs. However, it was later reported that it was wrong not to take into account the individual structure of the horse's extremity. It is important to ensure that the dorsal surface of the hoof and pastern are parallel to each other (Bach *et al.*, 1995; O'Grady and Poupard, 2003). If the hoof structure does not conform to this, the hoof angle is corrected when the hoof is cut properly and the dorsal hoof wall and the dorsal surface of the pastern are aligned in a parallel plane. Changes in the hoof-pastern axis have been associated with a low heel or vertical hoof structure (Bach *et al.*, 1995; O'Grady and Poupard, 2003). This causes stress on and weakening of the soft tissues, usually in the palmar/plantar part of the foot, in hooves with low heels. The energy and stress occurring during hyperextension that develops in the region during racing or strenuous exercises bypass the soft tissue structures in the palmar/plantar part of the foot, causing the impact energy produced during landing to be transferred directly to the bone via the laminar interface (Bach *et al.*, 1995; O'Grady and Poupard, 2003; O'Grady, 2011). In this study, the angles were not fully determined, but the fact that 27 cases had low heels is an important finding. Therefore, a low value of this angle may cause excessive joint hyperextension and leads to stress on the suspensory ligament, tendons and sesamoid bones.

When the superficial and deep digital flexor muscles become sore during intense exercise, the musculotendinous units of these muscles provide less elastic support to the distal extremity. In such cases, the MCP/MTP joint extension may become maximal and the tensile forces applied to the proximal sesamoid bones may exceed the biomechanical tolerance of this structure, causing disruption and fractures of the sesamoid bone (Hubert *et al.*, 2001). In addition, chronic sesamoiditis has been shown to be a potential factor for the development of proximal sesamoid bone fractures due to lesions developing in the bones (Hubert *et al.*, 2001; Diakakis *et al.*, 2005). Fractures can occur in the apex, middle and base of proximal sesamoid bones. The bones may be divided into two fragments or the fracture may be a segmental fracture. Apical fractures occur in the proximal third of the sesamoid bone and are usually caused by hyperextension of the suspensory ligament, affecting the lateral sesamoid bone of the hindlimb. Sesamoid fractures in the midsection are transverse and are more common in young horses. Basilar fractures occur in the distal third of the sesamoid bone. In thoroughbred horses, midline fractures or basilar fractures occur usually in the medial proximal sesamoid bone of the forelimb (Hubert *et al.*, 2001). In this study, it was found that the sesamoid bone fractures occurred at the base of the sesamoid bone in three cases and in the midline of the bone in three cases. Two of the fractures were in the hindlimb. The fractures identified on the radiograph were observed in the medial sesamoid bone in the forelimb and in the lateral sesamoid bone in the hindlimb. This can be associated with the rate of stress that occurs in the lateral and medial sesamoid bones in the forelimb and hindlimbs during strenuous exercises. In addition, according to the observations obtained from this study, complete recovery was found in cases with midline fractures (except for one case), whereas functional improvement was found to be significant in cases with base fractures.

Sesamoiditis is categorised into articular and non-articular sesamoiditis (Diakakis *et al.*, 2005). The articular form is characterised by peripheral osteophytosis of the apical and basilar parts of the proximal sesamoid bone and usually develops secondary to inflammation of the MCP/MTP joint. The non-articular form is associated with primary diseases involving the suspensory ligament and is characterised by enlarged intra-osseous channels and/or growth of the bone and increased bone production in the abaxial or basal parts of the proximal sesamoid bone. Non-articular sesamoiditis is considered as actual sesamoiditis (Diakakis *et al.*, 2005). Osteophytosis is defined as osteophytic growths that develop at sites related to the joint and enthesophytosis is defined as osteophytic growths that develop at sites where the tendons or ligaments join the bone. Osteophytosis and enthesophytosis may occur as a result of inflammations that develop in the joints, tendons and surrounding soft and hard tissues (Rogers *et al.*, 1997; Hardcastle *et al.*, 2014). In this study, enthesophytosis (n=9), osteophytosis (n = 3) and osteolysis (n=3) were observed on the radiographs. In addition, erosions (n=11) were also detected on the abaxial surface of the proximal sesamoid bones on radiographic examination. In 27 (90%) of the 30 cases included in the evaluation, bone growths formed in the non-articular parts of the sesamoid bone, irregularities in the bone wall and the presence of an enlarged intraosseous canal in the bone showed that these cases were in the non-articular form. The remaining 3 cases (10%) were in both articular and nonarticular forms. In these cases, there was not only osteophyte formation in their radiographs. In addition, there were irregularities in the bone wall and the presence of an enlarged intraosseous vascular canal. This can be explained by the magnitude of the stress on the joints during intense exercises, joint inflammation, hyperextension in the regional tendons and ligaments and the stress on the proximal sesamoid bone from repetitive traumas.

The prognosis of sesamoiditis is better in young horses and a good prognosis can be achieved if the horse is allowed an adequate resting period (Diakakis *et al.*, 2005; Yanmaz, 2011). In addition, the amount of osteophytes and enthesophytes and the degree of damage to the suspensory ligament and intersesamoid ligaments also affect the prognosis (Diakakis *et al.*, 2005). In this study, four cases did not respond to treatment and these horses did not participate in any race afterwards. Of these four cases, one has sesamoiditis in the hindlimb and three had it in the forelimb. All of these cases had enlarged vascular channels on the radiograph. In addition to these findings, one case had a fracture near the middle part of the sesamoid bone. The worsening of the prognosis in these cases may be due to lack of rest and long-term treatment.

Early detection of musculoskeletal lesions is a key factor for the prevention of further injury and successful treatment in racehorses (Menarim *et al.*, 2012). Treatment of sesamoiditis should include measures to prevent osteophytosis and/or enthesophytosis development and/or fracture of the sesamoid bone as well as suspensory ligament injury. This treatment varies greatly depending on the lesions accompanying the inflammation of the sesamoid bone and the inflammation of the suspensory ligament and surrounding tissues. The suspensory ligament and distal intersesamoidean ligaments should be checked in all cases with suspected sesamoiditis. Co-administration of oral glycosaminoglycans for a period of at least two months is also recommended (Diakakis *et al.*, 2005). Bisphosphonates, such as tiludronate, are used to normalise bone metabolism through inhibition of bone resorption (Denoix *et al.*, 2003). Increased bone resorption and formation areas are observed in sesamoiditis. In our study, intra-articular corticosteroid and hyaluronic acid injections were administered and glycosaminoglycan was administered orally for 3 months to relieve the pain and discomfort in the treatment of sesamoiditis. Tiludronate sodium was used intravenously to normalise bone metabolism. According to the data obtained from this study, an initial long-term resting period

and the treatment protocol should not be interrupted for effective treatment. Moreover, it will be useful to support the treatment with administration of tiludronate sodium for bone metabolism and of glycosaminoglycan for improving tendon and ligament health as well as synovial fluid levels in the affected joint.

In addition to medical treatment, it is very important to restore the hoof balance and relieve stress and load on tissues, such as joints and tendons. For this purpose, orthopaedic horseshoes are recommended (Diakakis *et al.*, 2005). In this study, the treatment was supported by the use of orthopaedic horseshoes with high heels that could absorb impacts from the base in all horses with low heels.

CONCLUSION

With this study, it can be said that low-heeled hoof structure is important in the etiology of sesamoiditis in racehorses. For this reason, regular hoof care should be carried out by experienced farriers starting from the period when low-heeled horses are foals and the dorsal hoof wall and the dorsal surface of the trotter should be aligned in a parallel plane. However, if this is not possible, the problem should be tried to be corrected by using a high-heeled orthopedic horseshoe. It can also be emphasized that in cases where the dilated vascular channel diameter is not too large, very good results can be obtained with treatment and a good prognosis can be achieved with treatment and rest.

ACKNOWLEDGEMENT

I would like to thank Diyarbakır Hippodrome Directorate and its staff and Veterinarian Yunus Çelik for allowing this study to be carried out.

Additional informations

This research received no grant from any funding agency/ sector. The data that support the findings of this study are available on request from the corresponding author (Emine Çatalkaya). A part of this study was presented as an oral presentation at the 17th National 3rd International Veterinary Surgery Congress. 15-17 September 2022, Samsun/ TÜRKİYE.

Conflict of interest

There is no conflict of interest.

REFERENCES

Bach, O., Butler, D., White, K., Metcalf, S. (1995). Hoof balance and lameness: Improper toe length, hoof angle and mediolateral balance. Compendium Contin. Educ. Pract. Vet. 17: 1275-1282.

Cornelissen, B.P.M., Rijkenhuizen, A.B.M., Buma, P., Barneveld, A. (2002). A study on the pathogenesis of equine sesamoiditis: The effects of experimental occlusion of the sesamoidean artery. J. Vet. Med. 49: 244-250. DOI: 10.1046/j.1439-0442.2002.00447.x.

Denoix, J.M., Thibaud, D., Riccio, B. (2003). Tiludronate as a new therapeutic agent in the treatment of navicular disease: A double-blind placebo-controlled clinical tria. E.V.J. 35: 407-413. doi: 10.2746/042516403776014226.

Diakakisi, N., Maraki, M., Patsikas, M., Desiris, A. (2005). Equine sesamoiditis: Report on one case. J. Hellenic Vet. Med. Soc. 56: 350-357. doi: https://doi.org/10.12681/jhvms.15095.

Hardcastle, S.A., Dieppe, P., Gregson, C.L., Arden, N.K., Spector, T.D., Hart, D.J., Edwards, M.H., Dennison, E.M., Cooper, C., Williams, M., Smith, G.D., Tobias, J.H. (2014). Osteophytes, enthesophytes and high bone mass. Arthritis and Rheumatology. 66: 2429-2439. doi: 10.1002/art.38729.

Hubert, J.D., Latimer, F.G., Moore, R.M. (2001). Proximal sesamoid bone fractures in horses. Compendium. 23: 678-687.

Izci, C., Goksahin, E., Erol, M. (2015). Sole Cushion or Digital Cushion? Erciyes Univ. Vet. Fak. Derg. 12: 133-139.

Izci, C., Göksahin, E., Erol, M. (2018). Clinical and radiological evaluation of the bone lesions in lower extremity and foot region in draft horses. Erciyes Univ. Vet. Fak. Derg. 15: 30-36.

Kumar, V., Singh, Y.P., Parashar, M.C., Jaiswal, K. (2019). Diagnosis and Management of Sesamoiditis in a Mare. Intas Polivet. 20: 305-306.

Lloyd, K.A., Ayodele, B.A., Hitchens, P.L., Beck, C., Mackie, E.J., Whitton, R.C. (2020). Associations between the radiographic appearance of vascular channels in proximal sesamoid bones, their microstructural characteristics and past racing performance in Thoroughbreds. E.V.J. 52: 670-677. doi: 10.1111/evj.13239.

Menarim, B.C., Machado, V.M.V., Alvarez, L.E.C., Carneiro, R., Busch, L., Vulcano, L.C. (2012). Radiographic abnormalities in barrel racing horses with lameness referable to the metacarpophalangeal joint. J.E.V.S. 32: 216-221. doi: 10.1016/j.jevs.2011.09.064.

Niemelä, T.M., Tulamo, R.M., Hielm-Björkman, A.K. (2016). A randomised, double-blinded, placebo-controlled clinical study on intra-articular hyaluronan treatment in equine lameness originating from the metacarpophalangeal joint. B.M.C. Veterinary Research. 12: 60. doi: 10.1186/s12917-016-0687-7.

O'Grady, S.E. (2011). Foot Care and Farriery. In: Adams and Stashak's Lameness in Horses. [Baxter C.M. (Eds)]. Wiley-Blackwell, USA. pp. 2274-2337.

O'Grady, S.E., Poupard, D.E. (2003). Proper physiologic horseshoeing. Veterinary Clinics of North America: Equine Practice. 19: 333-344. doi: 10.1016/s0749-0739(03)00020-8.

Plevin, S., Mclellan, J., O'Keeffe, T. (2016). Association between sesamoiditis, subclinical ultrasonographic suspensory ligament branch change and subsequent clinical injury in yearling Thoroughbreds. E.V.J. 48: 543-547. doi: 10.1111/evj.12497.

Reesink, H.L. (2017). Foal Fractures: Osteochondral Fragmentation, Proximal Sesamoid Bone Fractures/Sesamoiditis and Distal Phalanx Fractures. Vet. Clinics North America Equine Practice. 33: 397-416. doi: 10.1016/j.cveq.2017.03.007.

Rogers, J., Shepstone, L., Dieppe, P. (1997). Bone formers: Osteophyte and enthesophyte formation are positively associated. A.R.D. 56: 85-90. doi: 10.1136/ard.56.2.85.

Roux, C., Carstens, A. (2018). Axial sesamoiditis in the horse: A review. J.S.A.V.A. 89: a1544. doi: 10.4102/jsava. v89i0. 1544.

Santschi, E.M. (2013). How to interpret radiographs of the fetlock and pastern joints of the young performance horse. Proceedings of the 59th Annual Convention of the American Association of Equine Practitioners, December 7-11, Nashville/Tennessee. 59: 364-371.

Sirin, O.Z., Sen, Y., Ozgermen, B., Bumin, A., Alkan, Z. (2020). Clinical and radiographic diagnosis of developmental orthopedic disease and bone lesions determined in thoroughbred Arabian foals. Dicle Univ. Vet. Fak. Derg. 13: 114-118. doi: 10.47027/duvetfd.794092.

Spike-Pierce, D.L., Bramlage, L.R. (2003). Correlation of racing performance with radiographic changes in the proximal sesamoid bones of 487 Thoroughbred yearlings. E.V.J. 35: 350-353. doi: 10.2746/042516403776014262.

Yanmaz, L.E. (2011). İnfrared termal kameranın ekstremite hastalıkları tanısında kullanılabilirliği: Yarış atlarında karşılaştırmalı araştırma. PhD Thesis. Atatürk University, Institute of Health Science, Türkiye.

Yanmaz, L.E., Okumus, Z. (2018). Thermographic assessment of extremity temperature alterations of cases with bucked shin complex, splints, carpal osteoarthritis and sesamoiditis in sport horses. Erciyes Univ. Vet. Fak. Derg. 15: 41-45.

Yücel, R. (2007). Spor Atlarında Ortopedik Hastalıklar. 1st ed. Aktif Yayıncılık. İstanbul/Türkiye.