RESEARCH ARTICLE Indian Journal of Animal Research, Volume 58 Issue 8: 1275-1279 (August 2024)

Assessment of Biochemical and Histological Effects of One of Ziziphus Genus Extract on Ovarian Function in Female Rats

Ahmad R. Alhimaidi[1], Aiman A. Ammari[1], Ramzi A. Amran[1], Ahmed M. Rady[1]

10.18805/IJAR.BF-1768

ABSTRACT

Background: There is a growing need to offer guidance and instruction to those who use herbal medicines in order to enhance their understanding of the scientifically supported risks associated with these therapies. This study investigates the adverse effects of the *Ziziphus spina-christi* (ZSC) aqueous extract on the biochemical markers and histological alterations in the ovaries of female rats.

Methods: A total of fifteen female rats, with five rats in each group, were given the extract of ZSC orally at doses of 10, 50 and 100 mg/kg bw/day for a duration of 14 days. Five more ladies were designated as a control group and provided just with water. During a span of fifteen days, clinical findings of toxicity were documented. The ovarian function was evaluated by assessing the biochemical indicators and measuring the quantities of serum estradiol and progesterone. Furthermore, an assessment was conducted to examine the histological changes in the organs.

Result: The results did not show any clear toxicity on the animal's weight or body organs. Estrogen and progesterone levels in female rats who received ZSC extract for 14 days. In addition, no pathological changes were revealed in the ovary histological sections. Significant differences were detected in the numbers of ovarian follicles in females treated with the ZSC extract compared to the control. In conclusion, the results showed indications of side effects of ovarian follicles after treating female rats with ZSC extract for 14 days.

Key words: Estrogen, Ovaries, Progesterone, *Ziziphus spina-christi*.

INTRODUCTION

Over time, the utilization of natural plants and herbal remedies has been prevalent for the treatment of illnesses and the enhancement of human health. The widespread use of herbal medications is justified by the common perception that they are safer than conventional pharmaceuticals due to their natural composition. There is a growing need to offer guidance and instruction to individuals who use medicinal herbs in order to enhance their understanding of the potential adverse effects associated with these plants, based on scientific research (Choudhury *et al*., 2023). Reports have shown the unforeseen detrimental impact of several herbal medications, commonly employed as complementary and alternative therapies, on vital organs such as the liver and kidneys (Rani *et al*., 2024; Henneh *et al*., 2022).

There are over 135 species in the Ziziphus genus, which is called Sidr in Arabic. They are all members of the Rhamnaceae family (Jha *et al*., 2023; Sakna *et al*., 2023; Shelef *et al*., 2017). They are distributed across warm-temperate, subtropical and tropical areas and are employed as alternative traditional medicines. Ziziphus genus members provide potent medicines with anti-inflammatory properties (Imran *et al*., 2023; Mohammed *et al*., 2023), A wide range of techniques have been used to get different components from Ziziphus spina-christi (ZSC) and these components have been utilized for numerous therapeutic purposes, including promoting the growth of new blood vessels and inhibiting cell proliferation (Alghamdi *et al*., 2023), decreasing Choline on Acute Liver Disease (El-Megeid *et al*., 2023), antioxidants (Bouzid *et al*., 2023; Neamah and Jabar, 2023). The phytochemicals present in ZSC, such as triterpenes, phenolics, flavonoids and saponin glycoside, have been the subject of discussion in several papers (Sakna *et al*., 2023).

While the therapeutic relevance and pharmacological actions of ZSC have been extensively studied, additional study is needed to properly investigate its potential negative effects. This project focuses on studying the adverse effects of the ZSC aqueous extract on the biochemical markers and histological evaluation of the ovaries in female rats.

MATERIALS AND METHODS

If not stated otherwise, all chemicals used in this project were obtained from Sigma.

[1]Department of Zoology, Faculty of Science, College of Science, King Saud University, P.O. Box 2455, Riyadh 11451, Kingdom of Saudi Arabia.

Corresponding Author: Ahmad R. Alhimaidi, Department of Zoology, Faculty of Science, College of Science, King Saud University, P.O. Box 2455, Riyadh 11451, Kingdom of Saudi Arabia. Email: ahimaidi@ksu.edu.sa

How to cite this article: Alhimaidi, A.R., Ammari, A.A., Amran, R.A. and Rady, A.M. (2024). Assessment of Biochemical and Histological Effects of One of Ziziphus Genus Extract on Ovarian Function in Female Rats Indian Journal of Animal Research. 58(8): 1275-1279. doi: 10.18805/IJAR.BF-1768.

Submitted: 29-01-2024 **Accepted:** 16-04-2024 **Online:** 10-05-2024

The process involved macerating twenty grams of ZSC leaves in 200 ml of distilled water at a temperature of 30°C. The mixture was shaken at a speed of 150 rpm for a duration of 24 hours. The suspensions underwent filtration using Whatman filter paper and the remaining solid material was subjected to a second extraction and subsequent filtration, using the same procedure as mentioned before. The two filtrates were combined and subjected to evaporation using a rotary evaporator at a temperature of 40°C. The concentrated filtrate of each plant, obtained from the crude extract, was measured and then dissolved again in normal saline solution to achieve a final concentration of 100 mg, 50 mg and 10 mg per kilogram. The resulting solution was kept at a temperature of -20°C until it was needed.

A cohort of twenty female rats, weighing between 180-220 g and aged 12-14 weeks, was obtained from the animal facility at the Zoology Department of the Science College, King Saud University (KSU). The rats were used to a well-ventilated environment maintained at a room temperature of 25±2°C, with a consistent 12-hour light and dark cycle. They were given a conventional food and had access to water. The experimental techniques followed the rules established by the ethics committee and the Institutional Animal Care at KSU, with approval number KSU-SE-23-06. The four distinct cohorts of female rats, each including five individuals, were subjected to the following exposure: The control group got water, while the second, third and fourth groups were given the extract at doses of 10, 50 and 100 mg/kg bw/day for a duration of 14 days.

The weights of the female rats were monitored every day throughout the dosing period until necropsy (14 days). Clinical observations of toxicity such as lethargy, unresponsiveness, abnormal breathing and aggression were recorded.

The blood was drawn from the hearts of female rats and collected in regular tubes. It was then subjected to centrifugation at a speed of 3500 revolutions per minute for a duration of 15 minutes to separate the serum. The resulting serum was thereafter stored in a refrigerator until it was ready for analysis. The serum estradiol and progesterone concentrations were assessed to determine the ovaries function. The instructions and procedures included with the kits were followed.

The animals were dissected directly after blood was collected and ovaries were placed directly in formalin fixative (10%). The fixated tissues were washed in distilled water, dehydrated, cleared, embedded the tissues into paraffin blocks, cut into thin sections, mounted onto slides, stained by hematoxylin and eosin and examined for histopathological alterations. The ovarian follicles were classified following the method outlined by Adelakun *et al*. (2022). Primordial follicles were identified based on the presence of a patchy row of squamous cells surrounding the oocyte. Primary follicles were distinguished by the presence of rows of cuboidal cells, spaces between cells and two layers of the theca. Graafian follicles were recognized by the presence of a large follicular antrum.

The data collected from the experiment underwent analysis using the GraphPad Prism (version 10.1.1) software. To assess the normal distribution of our data, the Shapiro-Wilk test was employed. Various parameters such as, hormone levels, organ weights and the percentage of ovarian follicles were subjected to one-way ANOVA, followed by Tukey's test. The results are reported as mean values accompanied by their standard deviations.

RESULTS AND DISCUSSION

There were no indications of toxicity or mortality in female rats throughout the course of fourteen days of orally administering the ZSC aqueous extract. The average weights of ovaries of animals treated with the ZSC aqueous extract did not show significant differences compared to the control group (Fig 1).

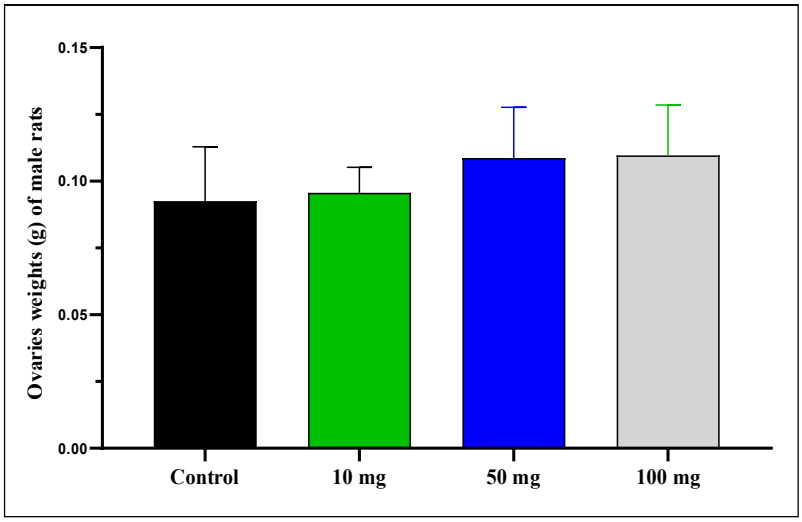

Fig 1: Results of female rat mean ovary weight of treated with *Ziziphus spina-christi* compared to control group.

The results in Fig 2 did not show any significant changes in the estrogen and progesterone levels in female rats received ZSC extract for 14 days although the two hormones concentration increased in females treated with high doses.

Fig 3 shows different stages of ovarian follicles in the four groups. The ovarian follicles showed an increase in the numbers of primary and secondary follicles in the control group compared to the other three groups, while the number of primordial and graafian follicles increased in the 100 mg group compared to the control.no pathological changes were revealed in the ovary (Fig 4)

Due to the absence of papers that discuss the toxicity of ZSC extract, there is a justification for the necessity of doing more study to verify its safety and to cultivate evidence-based awareness of all of its possible adverse effects. The purpose of this study is to investigate the adverse effects of the ZSC aqueous extract on the biochemical markers and histological alterations that occur in the ovaries of female rats.

The antioxidant activity of six distinct genotypes of Ziziphus nummularia (coded as ZNP01-06) fruit extract was assessed by Uddin *et al*. (2020) using *in vitro* techniques. The extract exhibited the most elevated antioxidant capacity due to the presence of polyphenols, which might potentially facilitate the identification of novel pharmaceutical compounds (Uddin *et al*., 2020). It has been verified that Ziziphus jujuba contains polysaccharides that exhibited the most potent antioxidant effect in an *in vitro*

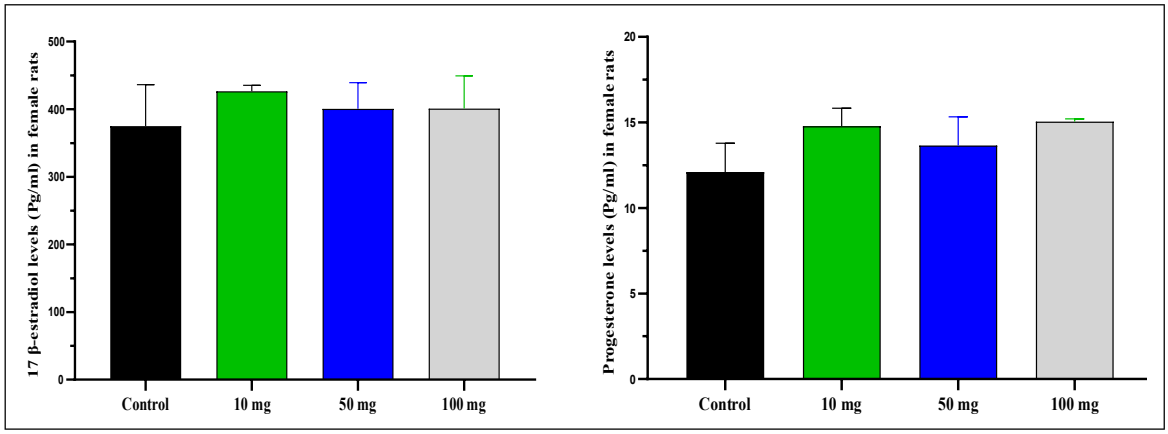

Fig 2: Means of serum estrogen, progesterone, level of female rats group treated with *Ziziphus spina-christi* extract for two weeks.

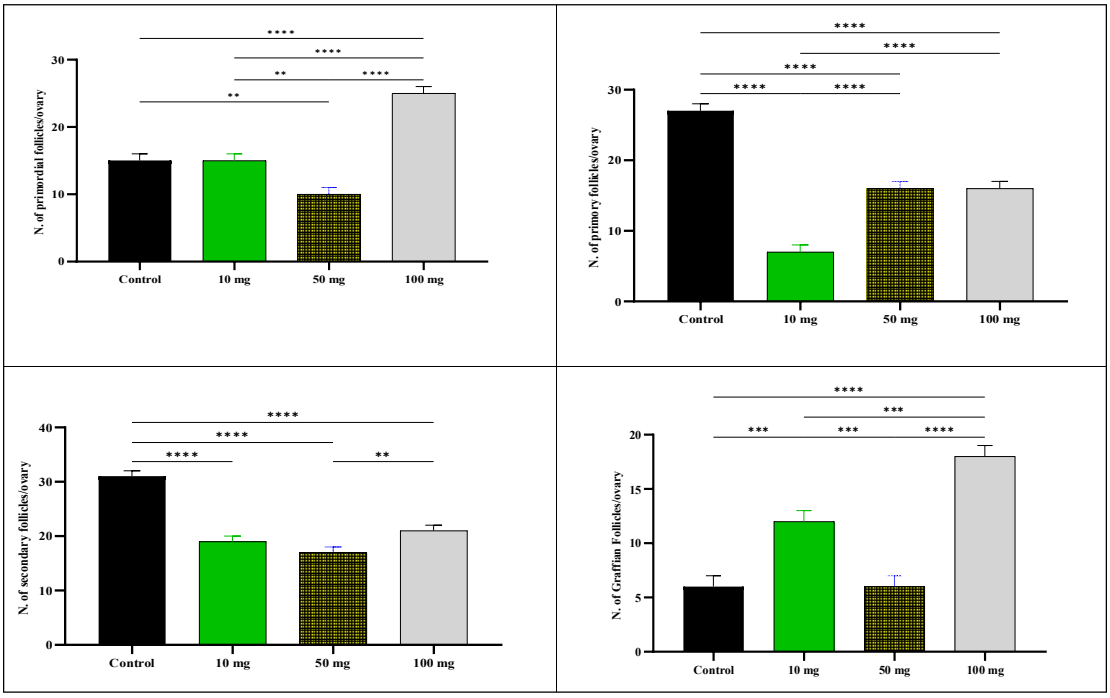

Fig 3: The results of follicles counted in ovary of *Ziziphus spina-christi* extract for two weeks.

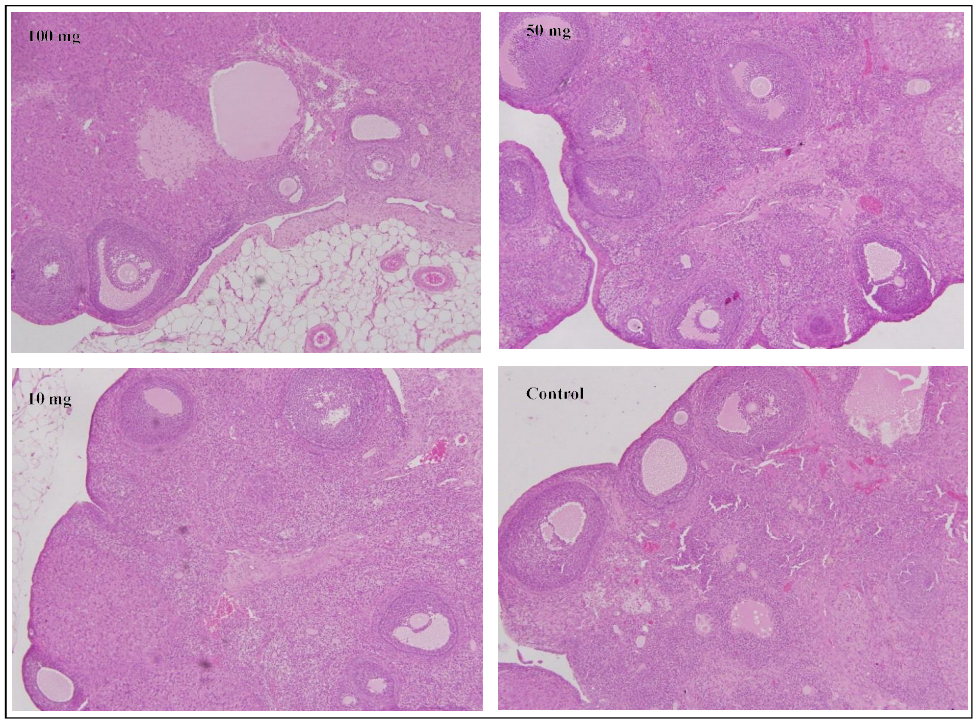

Fig 4: Histology of the ovary of the female rat groups treated with *Ziziphus spina-christi* extract for two weeks compared to the normal.

investigation. The findings indicate that Ziziphus jujuba has the potential to serve as an antioxidant in functional meals (Yang *et al*., 2021).

Shady *et al*. (2022) conducted a recent study to examine the antioxidant activity of Ziziphus mauritiana fruit extracts using an *in vitro* assay. The findings demonstrate the robust antioxidant capacity due to the existence of antioxidant molecules (Shady *et al*., 2022). Extensive research has focused on antioxidant chemicals derived from plants, including examining the extract of *Ziziphus oxyphylla* and *Cedrela serrata* and comparing the fractions obtained from their leaves, bark and roots. The findings indicated that the ethyl fractions derived from the leaves and barks of Ziziphus oxyphylla and Cedrela serrata exhibited the most potent antioxidant activity, with an IC_{50} value of less than 10 mg/mL. The leaves and bark shown more antioxidant activity compared to the roots in their ability to counteract free radicals, which serve as a defense against many harmful substances.

The ovary, the effect of the ZSC extract on the percentage of ovarian follicle numbers, whether increased or decreased, was shown at different stages of folliculogenesis with no significant changes in the progesterone and estrogen concentrations. Plants contain phytoestrogens that may cause disturbances in the normal folliculogenesis process (Homady *et al*., 2002).

CONCLUSION

The results that were reported demonstrated that Ziziphus is a genus of plants that is considered to be favorable. Furthermore, due to the fact that it is non-toxic and effective, it has the potential to be utilized and researched for additional medicinal uses. Ultimately, it is possible that future study on this plant might be beneficial for the discovery of novel drugs.

ACKNOWLEDGEMENT

This study was funded by the Researchers Supporting Project (number RSP-2024/232), King Saud University, Riyadh, Saudi Arabia.

Conflict of interest

The authors of the manuscript declare that they have no competing or financial interests.

REFERENCES

Adelakun, S.A., Akintunde, O.W., Akingbade, G.T. and Adedotun, O.A. (2022). Bioactive component of aqueous extract of Solanum melongena ameliorate estradiol valerate induced ovarian-pituitary dysfunctions in female Sprague-Dawley rats: Histomorphological and biochemical evidence. Phytomedicine Plus. 2(1): 100175.

Alghamdi, T., Salem, D.A. and El-Refaei, M.F. (2023). Anti-angiogenic and anti-proliferative activity of ziziphus leaf extract as a novel potential therapeutic agent for reducing hepatic injury in experimental hamster schistosomiasis. PLOS Neglected Tropical Diseases. 17(6): e0011426.

Bouzid, H.A., Bijla, L., Ibourki, M., Oubannin, S., Elgadi, S., Koubachi, J. and Gharby, S. (2023). *Ziziphus lotus* (L.) Lam. almonds nutritional potential: Evidence from proximate composition, mineral, antioxidant activity and lipid profiling reveals a great potential for valorization. Biomass Conversion and Biorefinery. pp. 1-15.

Choudhury, A., Singh, P.A., Bajwa, N., Dash, S. and Bisht, P. (2023). Pharmacovigilance of herbal medicines: Concerns and future prospects. Journal of Ethnopharmacology. 116383.

El-Megeid, A., Abd El-Aziz, A., Hassan, L.B. and Shafeek, O.H. (2023). Effect of some levels from *ziziphus spina-christi* leaves and choline on acute liver disease in rats. Journal of Advanced Zoology. 44.

Henneh, I. T., Ahlidja, W., Alake, J., Kwabil, A., Ahmed, M.A., Kyei-Asante, B. and Armah, F.A. (2022). *Ziziphus abyssinica* root bark extract ameliorates paracetamol-induced liver toxicity in rats possibly *via* the attenuation of oxidative stress. Toxicology Reports. 9: 1929-1937.

Homady, M.H., Khleifat, K.M., Tarawneh, K.A. and Al-Raheil, I.A. (2002). Reproductive toxicity and infertility effect of Ferula hormonis extracts in mice. Theriogenology. 57(9): 2247-2256.

Imran, S., Bibi, Y., Munawar, T., Yousaf, A.M. and Hasnain, M. (2023). A panoramic review on ethnomedicinal, therapeutic, phytochemical and advance attributes, of the genus *Ziziphus* Mill., native to Pakistan. Ethnobotany Research and Applications. 25: 1-32.

Jha, D., Hangargekar, P., Akbar, M., Parihar, A.S., Kashyap, S., Joshi, A. and Rahman, M.A. (2023). Ziziphus mauritiana: An in-depth review of its medicinal attributes and pharmacological activities. Intelligent Pharmacy. doi: 10.1016/j.ipha.2023.12.001

Mohammed, A., Abdulrasak, M.A., Musa, A.L., Liman, J.H., Israel, E., Harry, U. and Dickson, O. (2023). Anti-hyperglycaemic and selected organ protective effects of *Ziziphus spina-christi* hydroethanol leaf extract in alloxan induced diabetic rats. Gadau Journal of Pure and Allied Sciences. 2(2): 146-155.

Neamah, N.M. and Jabar, Z.H. (2023). Evaluating the Total Antioxidant Activity and Free Radicles Scavenger of Ziziphus Leaves, Bark Ethanoic Extracts and the Aqueous Extract of Ficus Leaves in Basrah.

Rani, J., Dhull, S.B., Rose, P.K. and Kidwai, M.K. (2024). Drug-induced liver injury and anti-hepatotoxic effect of herbal compounds: A metabolic mechanism perspective. Phytomedicine. 122: 155142.

Sakna, S.T., Yasmin, R. Maghraby, Mohamed, S.A. and Mohamed, A.F. (2023). Phytochemical diversity and pharmacological effects of triterpenes from genus Ziziphus: A comprehensive review. Phytochem Review. 22: 1611-1636.

Shady, N.H., Soltane, R., Maher, S.A., Saber, E.A., Elrehany, M.A., Mostafa, Y.A. and Abdelmohsen, U.R. (2022). Wound healing and antioxidant capabilities of Zizyphus mauritiana fruits: *In-vitro*, *in-vivo* and molecular modeling study. Plants. 11(11): 1392. doi: 10.3390/plants11111392.

Shelef, O., Weisberg, P.J. and Provenza, F.D. (2017). The value of native plants and local production in an era of global agriculture. Frontiers in Plant Science. 8: 2069. doi: 10.3389/fpls.2017.02069.

Uddin, N., Ali, N., Uddin, Z., Nazir, N., Zahoor, M., Rashid, U. and Nisar, M. (2020). Evaluation of cholinesterase inhibitory potential of different genotypes of *Ziziphus nummularia*, their HPLC-UV and molecular docking analysis. Molecules. 25(21): 5011. doi: 10.3390/molecules25215011.

Yang, Y., Qiu, Z., Li, L., Vidyarthi, S.K., Zheng, Z. and Zhang, R. (2021). Structural characterization and antioxidant activities of one neutral polysaccharide and three acid polysaccharides from Ziziphus jujuba cv. Hamidazao: A comparison. Carbohydrate Polymers. 261: 117879.