RESEARCH ARTICLE Indian Journal of Animal Research, Volume 58 Issue 10: 1758-1764 (October 2024)

Effects of *Vitis vinifera* Leaves on the Oxidative Status of New Zealand Rabbit Liver Infected with *Eimeria stiedae*

Mohammed M. Mares[1], Rewaida Abdel-Gaber[1], Saleh Al-Quraishy[1]

10.18805/IJAR.BF-1805

ABSTRACT

Background: Rabbits are the most important protein sources of animals for humans all over the world. Its production has increased significantly in recent years and it has become one of the most important animal sources in the Kingdom of Saudi Arabia. Coccidiosis is one of the most dangerous diseases affecting rabbits and other animals causing global economic losses. Plant extracts have been used as potential alternatives to chemotherapy because they do not have the negative consequences of tissue deposits and drug resistance.

Methods: The current study examined the antioxidant activity of *Vitis vinifera* leaf extract (VVLE) in New Zealand rabbits infected with *Eimeria stiedae*. The extract was subjected to phytochemical analysis by FT-IR. A total of 35 male New Zealand rabbits were divided into seven groups. Group 1 served as the uninfected, untreated (negative control) group. Group 2 uninfected and treated at 400 mg/kg of extract to test for toxicity. Group 3 represented the infected, non-treated (positive control) group. While, groups 4, 5 and 6 comprised infected treated with at 100 mg/kg, 200 mg/kg and 400 mg/kg of extracts, respectively. Finally, group 7 consisted of infected rabbits treated with Toltrazuril at a dosage of 5 mg/kg body weight.

Result: The analysis of phytochemicals by FT-IR for *Vitis vinifera* leaf extract revealed the existence of 15 biologically active compounds. VVLE was able to decrease the induced weight loss due to infection. Moreover, the oxidative status due to *E. stiedae* infection had been changed after treatment with VVLE where the level of glutathione, malondialdehyde and nitric oxide was improved indicating the antioxidant activity of the VVLE. Our findings suggested that VVLE could boost the induced oxidative stress in the liver of infected New Zealand rabbits, but studies are needed to determine the mechanism of VVLE.

Key words: *Eimeria stiedae*, Hepatic coccidiosis, New Zealand rabbits, Oocysts, *Vitis vinifera* leaves.

INTRODUCTION

Rabbit production has become one of the most important animal resources in the world (Cadric *et al.*, 2017). Consumers prefer rabbits for their low cholesterol and fat contents and high levels of the essential amino acid (Cadric *et al.*, 2017). In addition to this commercial value, it is also due to the high prolificacy, early maturity, fast growth rate, high genetic selection potential, efficiency in feed conversion and economic utilization of space by rabbits (Lukefahr and Cheeke, 1990). Coccidiosis constitutes a major parasitic disease in poultry and other domestic animals, including rabbits (Yousif and Abdul-Aziz, 1995). Several risk factors allegedly affect the increased number of coccidiosis cases in rabbits, including the enclosure management, hygiene level, season and age of rabbits (Wang and Tsai, 1991). *Eimeria* is a genus of Apicomplexan parasites that includes various species responsible for the development of coccidiosis (Barbour *et al.*, 2015).

Currently, 15 species of the genus *Eimeria* are believed to be responsible for rabbit coccidiosis, including *Eimeria stiedae*, *Eimeria magna*, *Eimeria matsubayashi*, *Eimeria neoleporis*, *Eimeria nagpurensis*, *Eimeria irresidua*, *Eimeria flavescens*, *Eimeria piriformis*, *Eimeria intestinalis*, *Eimeria exigua*, *Eimeria elongate*, *Eimeria perforans*, *Eimeria vejdovskyi*, *Eimeria coecicola* and *Eimeria media* (Liu, 2019; Xie *et al.*, 2021). *E. stiedae* is by far the most pathogenic *Eimeria* species and mainly parasitizes the liver and bile duct epithelial cells of rabbits, resulting in liver coccidiosis (Hassan *et al.*, 2016; Jing *et al.*, 2016). Most of these *Eimeria* species affect rabbit production and according to their level of pathogenicity can cause reduced growth rate, feed conversion and increased mortality (El-Shahawi *et al.*, 2012). Hepatic coccidiosis (*Eimeria stiedae*) is one of the most pathogenic coccidian protozoans in domestic rabbits causing severe coccidiosis and increased mortality (Sivajothi *et al.*, 2016).

Vitis vinifera is a perennial woody vine of the family Vitaceae and it has been evaluated for potential medical uses. From different parts of this plant essentially fruits, several preparations used in folk medicine have been derived (Bombardelli and Morazzonni, 1995). Fresh leaves

[1]Department of Zoology, College of Science, King Saud University, Riyadh 1145, Saudi Arabia.

Corresponding Author: Mohammed M. Mares, Department of Zoology, College of Science, King Saud University, Riyadh 1145, Saudi Arabia. Email: mmares@ksu.edu.sa

How to cite this article: Mares, M.M., Abdel-Gaber, R. and Al-Quraishy, S. (2024). Effects of *Vitis vinifera* Leaves on the Oxidative Status of New Zealand Rabbit Liver Infected with *Eimeria stiedae*. Indian Journal of Animal Research. 58(10): 1758-1764. doi: 10.18805/IJAR.BF-1805.

Submitted: 23-04-2024 **Accepted:** 28-06-2024 **Online:** 15-07-2024

have been used externally to heal wounds and to lance abscesses (Kallel *et al*., 2008). Grape leaf-based medicines are traditionally used for diarrhea, hepatitis and stomachaches (Kapoor, 1990; Bombardelli and Morazzonni, 1995; Felicio *et al*., 2001). The most important compounds recorded previously in this plant were resveratrol, quercetin, catechin, flavone, flavonols, anthocyanin, gallic acid and epicatechin (Aouey *et al*., 2016). Here, we determined the antioxidant activity of *Vitis vinifera* leaf extracts against coccidiosis induced by *Eimeria stiedae* in New Zealand rabbits.

MATERIALS AND METHODS

Preparation of the *Vitis vinifera* extract

Leaves of *Vitis vinifera* were collected from local markets in Riyadh, Saudi Arabia. The leaves underwent air-drying and were subsequently ground into powder using an electric blender. Subsequently, cold extraction was performed in 70% methanol, with continuous mixing by a shaker for 24 hours (Amer *et al*., 2015). The dissolved contents obtained were homogenized, filtered using filter paper and evaporated at 40°C in a rotary evaporator (IKA, Germany). The solvent was evaporated to obtain extractions (Chikoto and Eloff, 2005). The extract obtained was kept at -20°C until use.

Infrared spectroscopy analysis of *Vitis vinifera* leaves extract

Following the processing steps, a small portion of the material was homogenized by blending it with an abundant amount of potassium bromide powder (1: 99 wt%). Subsequently, the material underwent a coarse crushing process before being loaded into pellet-forming equipment. The NICOLET 6700 Fourier-transform infrared spectroscopy (FT-IR), an optical spectrometer from Thermo Scientific, was employed to analyze the infrared spectrum. At a temperature of 25°C, spectra were captured with a 4 cm resolution, spanning from 4000 cm^{-1} to 400 cm^{-1} (Hussein *et al*., 2016).

Experimental animals

A total of 35 male New Zealand white rabbits (*Oryctolagus cuniculus*) were purchased from a farm in Riyadh, Saudi Arabia. The rabbits were at the age of 12 weeks and non-infection *Eimeria stiedae*. On arrival, they were immediately placed in disinfected wire cages of the same size and housed individually under hygienic conditions in the Animal House of the Department of Zoology, King Saud University. All rabbits were provided with water and feed. The diet was free from anticoccidial drugs. Rabbits were acclimated for a week and their fecal samples were checked daily for coccidia using a concentrated flotation technique (Heelan and Ingersoll, 2002). The King Saud University Research Ethics Committee (REC) approved this study (KSU-SE-22-38).

In vivo infection and experimental design

A total of 35 male New Zealand rabbits (Oryctolagus cuniculus) aged 12 weeks were individually weighed and assigned to 7 groups of 5 rabbits per group as the following:

Group 1: Non-treated (negative control) (n=5).
Group 2: Non-infected and treated (n=5) with the plant extracts at 400 mg/kg of body weight.
Group 3: Infected-non-treated (positive control) (n=5).
Group 4: Infected and treated (n=5) with the plant extracts at 100 mg/kg of body weight.
Group 5: Infected and treated (n=5) with the plant extracts at 200 mg/kg of body weight.
Group 6: Infected and treated (n=5) with the plant extracts at 400 mg/kg of body weight.
Group 7: Infected and treated (n=5) with Toltrazuril at 5 mg/kg body weight.

All groups except groups 1 and 2 were inoculated with 5×10^4 sporulated *Eimeria stiedae* oocysts Mohammed *et al*. (2021). After one hour of infection, the three doses of *Vitis vinifera* leaf extracts and the reference drug will be injected orally into all rabbits according to Aouey *et al*. (2016) and El-Ghoneimy and El-Shahawy, (2017), respectively.

Body weight and feed consumption

Each rabbit's weight was measured individually and the body weight gain (BWG) was determined by subtracting the initial body weight (recorded on day 0 post-infection) from the final body weight (measured on day 18 post-infection). The feed consumption (FC) for each replicate was determined by subtracting the weight of the remaining feed from the initial offered feed weight at the beginning of the experiment.

The liver's oxidative status

Pieces of the rabbit's liver were weighed and homogenized in a 10% (w/v) phosphate buffer. Subsequently, it was centrifuged for 15 minutes at 5000 g and 4°C. The supernatant was utilized for various biochemical analyses using kits supplied by Biodiagnostic Co. (Giza, Egypt). The liver homogenate was prepared following the method outlined by Dkhil *et al*. (2012). Glutathione (GSH) and nitric oxide levels were assessed by Paglia *et al*. (1967) and Montogomery (1961), respectively. Malondialdehyde (MDA) levels were determined using the method described by Ohkawa *et al*. (1979).

Statistical analysis

Significance was evaluated by one-way analysis of variance and statistical comparisons between the groups were performed by Duncan's test, using a statistical package program (SPSS version 17.0). All values were expressed as the mean and the standard error of the mean. All p-values are two-tailed and $p\leq0.05$ is considered as significant for all statistical analyses in this study.

RESULTS AND DISCUSSION

The analysis of *Vitis vinifera* leaf extracts using Fourier transform infrared spectroscopy (FTIR) showed major bands at 3368.86 cm^{-1}, 2934.35 cm^{-1}, 1726.98 cm^{-1}, 1615.20 cm^{-1}, 1514.23 cm^{-1}, 1403.86 cm^{-1}, 1238.96 cm^{-1}, 1048.39 cm^{-1}, 931.17 cm^{-1}, 890.24 cm^{-1}, 818.14 cm^{-1}, 778.23 cm^{-1}, 711.28 cm^{-1},

Table 1: FTIR for *Vitis vinifera* leaf extract.

Compound class	Group	Appearance	Transmittance (%)	Absorption (cm^{-1})
Aliphtic primary amine	N-H stretching	Medium	0.284105	3368.86
Alkane	C-H stretching	Medium	1.497952	2934.35
α, β-unsaturated ester	C=O stetching	Strong	2.370419	1726.98
α, β-unsaturted ketone	C=C stetching	Strong	1.675232	1615.20
Nitro compound	N-O stetching	Strong	7.867413	1514.23
Alcohol	O-H bending	Medium	2.076292	1403.86
Alkyl ary ether	C-O stetching	Strong	2.249312	1238.96
Anhydride	CO-O-CO stretching	Strong	0.675071	1048.39
Alkene	C=C bending	Strong	14.6391	931.17
1,3-disubsttuted	C-H bending	Strong	16.0924	890.24
1,4-disubsttuted	C-H bending	Strong	13.58251	818.14
1,2-disubsttuted	C-H bending	Strong	11.85985	778.23
Alkene	C=C bending	Strong	10.0727	711.28
Halo compound	C-Br strtching	Strong	7.088568	592.24
Halo compound	C-I strtching	Strong	7.969068	520.21

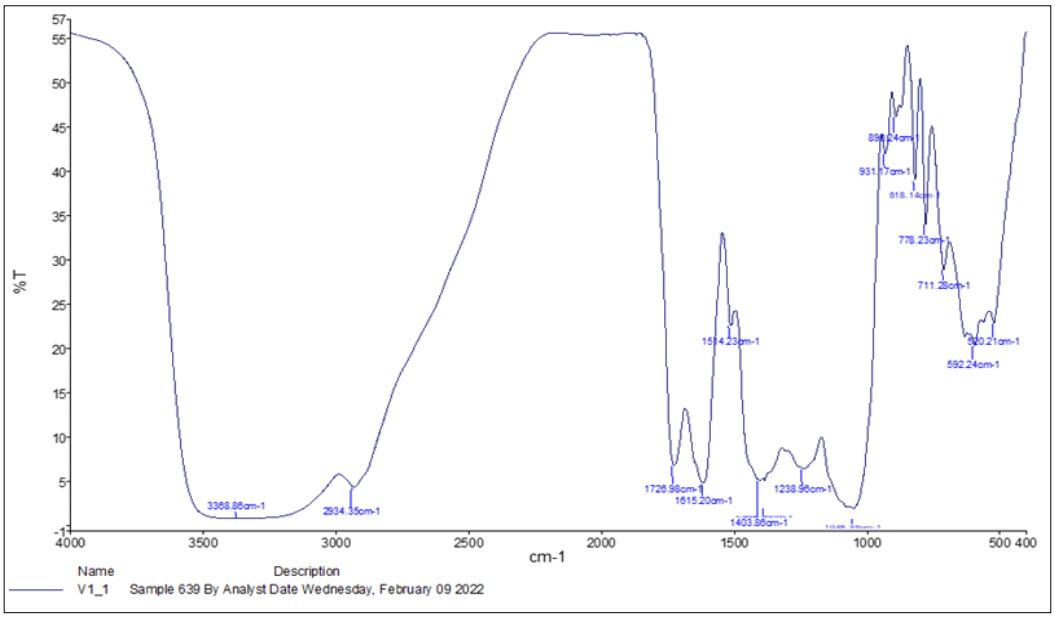

Fig 1: FTIR of *Vitis vinifera* leaf extract in an aqueous medium, revealing the functional characteristics of the material.

592.24 cm^{-1}, 520.21 cm^{-1} (Fig 1, Table 1). The 3368.86 cm^2 band corresponds to N-H stretching, confirming the presence of an aliphatic primary amine. Additionally, the 2934.35 cm^2 band indicates C-H stretching, suggesting the presence of an alkane. The 1726.98 cm^2 band corresponds to C=O stretching, confirming the presence of an α, β-unsaturated ester compound. Lastly, the 1615.20 cm^2 band confirms N-H stretching, indicating the presence of an α, β-unsaturated ketone. There was a nitro compound, an alcohol, an alkyl aryl ether, anhydride, an alkene and a 1,3-disubstituted at 1514.23, 1403.86, 1238.96, 1048.39, 931.17 and 890.24 cm^{-1}, in that order. Other compounds were also present.

The BWG of infected rabbits with *Eimeria stiedae* decreased significantly (P≤0.05) on day 18 post-infection compared with the non-infected rabbits (Fig 2). However, VVLE-challenged rabbits' groups without infection showed a significant increase (P≤0.05) in the BWG when compared to the infected rabbits' group, where the dose of 400 mg/kg VVLE showed a greater increase in the BWG than that occurred with the reference drug Toltrazuril (Fig 2). On day 18 post-infection the feed consumption (FC) of the infected group decreased compared to the non-infected group (Fig 3). This significant decrease (P≤0.05) was improved by the treatment of animals with VVLE in the treated group with 400 mg/kg VVLE (Fig 3). Rabbits treated with Toltrazuril also significantly appeared with increased FC (Fig 3). The beneficial effects observed may be attributed to the presence of phytochemicals, flavonoids and phenolic compounds in *Vitis vinifera* (grape) leaf extract. These compounds act as

potent antioxidants, aiding rabbits in maintaining a healthy commensal microflora. Additionally, they facilitate efficient nitrogen uptake, enhancing food digestion and nutrient absorption. Furthermore, this extract contributes to an improved innate and acquired immune response in rabbits, aligning with findings from previous studies by Brisbin *et al.* (2008) and Chand *et al.* (2021).

There has been a remarkable change in the infected with *Eimeria stiedae* and treated rabbits in glutathione (GSH), nitric oxide (NO) and malondialdehyde (MDA). *Eimeria stiedae* infection caused a significant decrease (P≤0.05) in the level of glutathione in the liver of rabbits (Fig 4). but after treatment of the infected rabbits with VVLE (400 mg/kg), the level of glutathione increases to nearly the

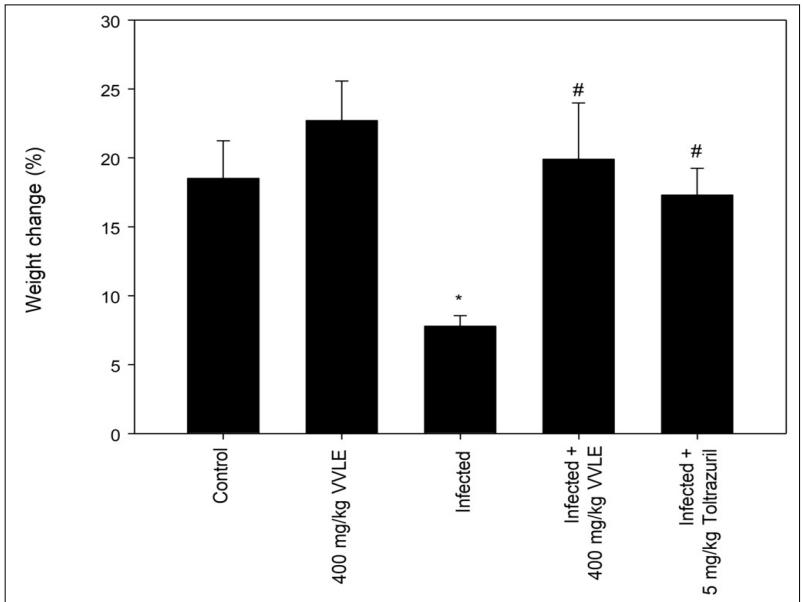

The values represent means ± SEM. *Indicates significance (P≤0.05) compared to the non-infected control group, while # denotes significance (P≤0.05) relative to the infected group.

Fig 2: VVLE significantly improved weight loss in rabbits infected with *Eimeria stiedae*.

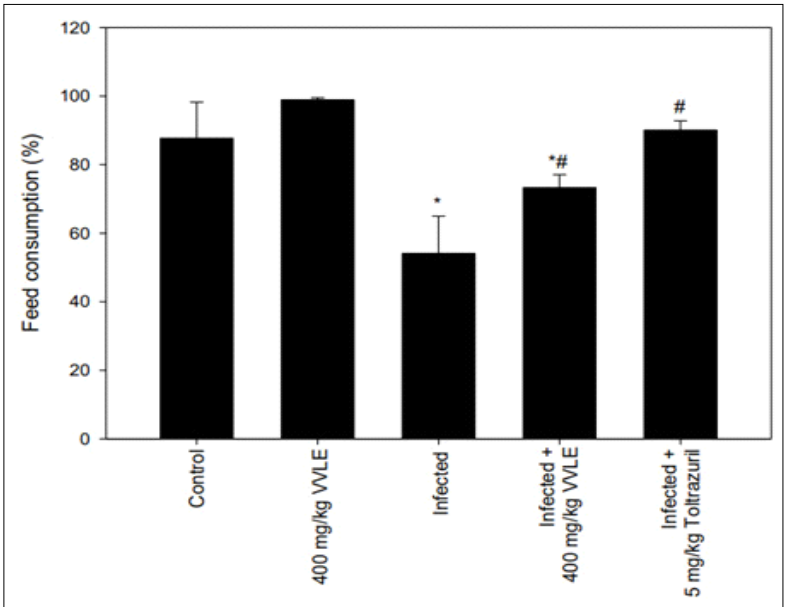

*Denotes significance (*P*≤0.05) compared to the non-infected control group, while # indicates significance (P≤0.05) relative to the infected group.

Fig 3: VVLE significantly enhanced feed consumption (%) in rabbits infected with *Eimeria stiedae*.

same as in the control groups. Compared to the reference drug, Toltrazuril. While the level of nitric oxide increased significantly (P≤0.05) after infection of rabbits with *Eimeria stiedae* (Fig 5). VVLE (400 mg/kg) was able to decrease nitric oxide to nearly the same as in the control groups. Compared to the reference drug, Toltrazuril. And *Eimeria stiedae* infection caused a significant increase (P≤0.05) in the level of malondialdehyde in the liver of rabbits (Fig 6). But after treatment of the infected rabbits with VVLE (400 mg/kg), the level of malondialdehyde decreased to nearly the same as in the control groups. Compared to the reference drug, Toltrazuril. Oxidative stress plays a crucial role in the pathophysiology of various pathological conditions. It is characterized by an increase in reactive oxygen species (ROS) and/or a reduction in antioxidant defense mechanisms (Heyman *et al.*, 2011). The findings align with the research by Çam *et al.* (2008) and Abdel-Maged *et al.* (2013). These studies indicate that elevated

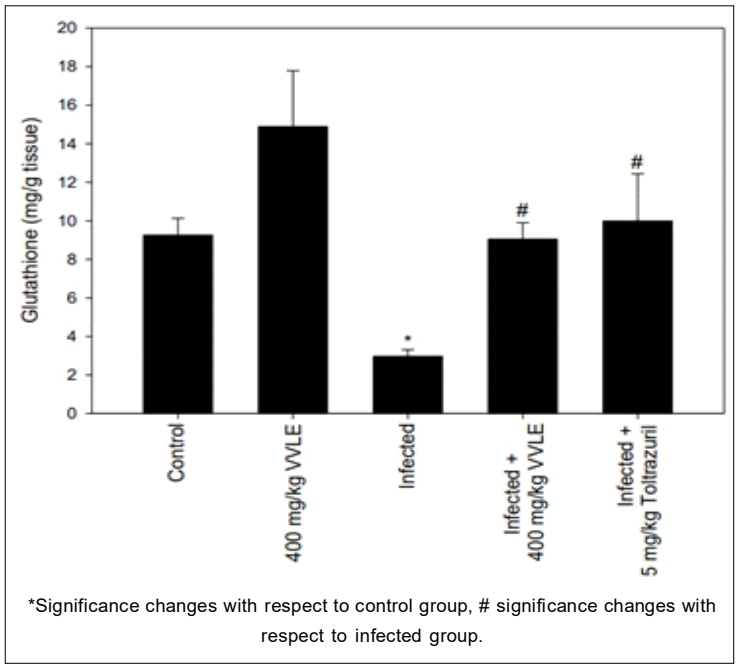

*Significance changes with respect to control group, # significance changes with respect to infected group.

Fig 4: Liver glutathione level after treatment of *Eimeria stiedae* infected rabbits with *Vitis vinifera*.

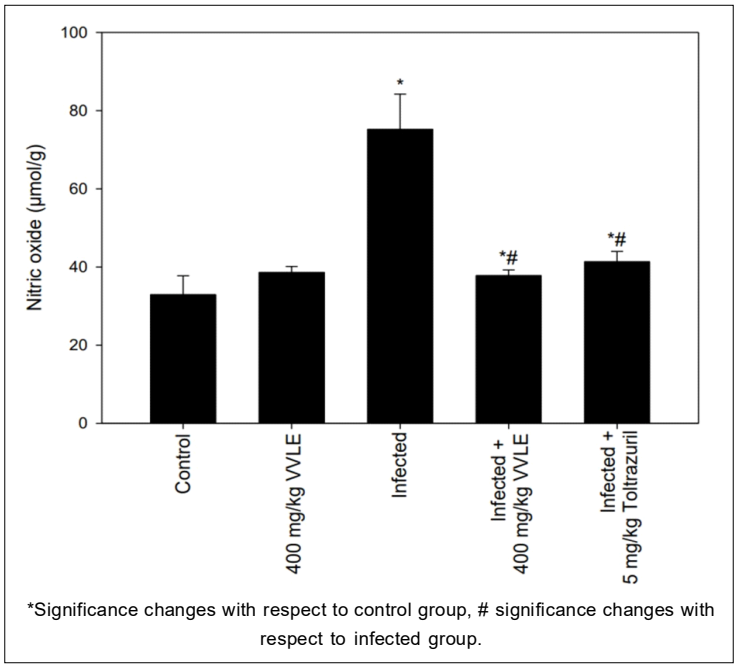

*Significance changes with respect to control group, # significance changes with respect to infected group.

Fig 5: Liver nitric oxide level after treatment of *Eimeria stiedae* -infected rabbits with *Vitis vinifera*.

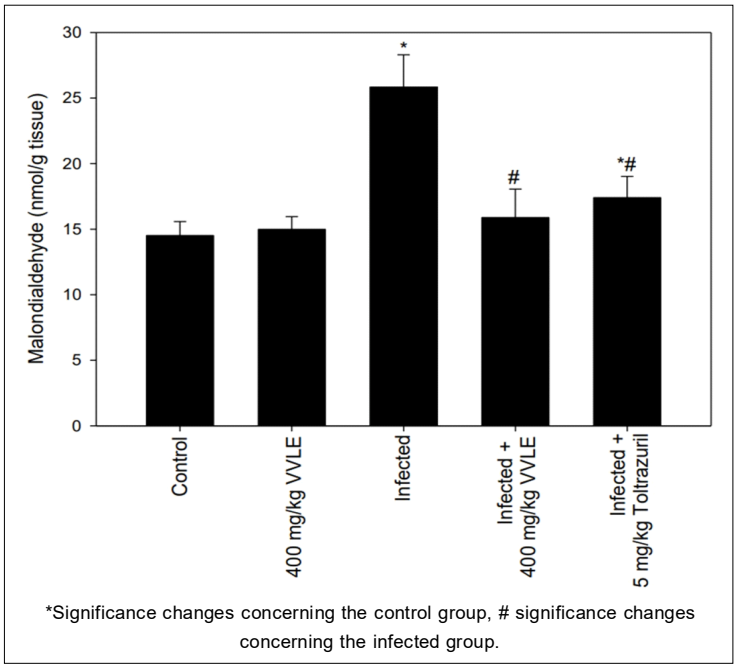

Fig 6: Liver malondialdehyde level after treatment of *Eimeria stiedae* -infected rabbits with *Vitis vinifera*.

levels of malondialdehyde (MDA) and nitric oxide in infected rabbits imply that *Eimeria stiedae* triggers lipid peroxidation. This process arises from damage to the bile duct and, consequently, the hepatic parenchyma. Lipid peroxidation can lead to impaired cell membrane permeability and subsequent cellular reactions, potentially resulting in cell death. Also, the decrease in glutathione production could result from liver damage caused by the infection. The liver plays a crucial role in glutathione synthesis. If the hepatic parenchyma is compromised due to the infection, it may lead to reduced glutathione production. Also, excessive free radicals: During the infection, these highly reactive molecules can cause damage to cellular components, including enzymes like glutathione. When free radicals overwhelm the antioxidant defense system, it can lead to a decrease in glutathione activity (Kaya *et al.*, 2007; Wang *et al.*, 2008). Regarding VVLE (400 mg/kg) and the toltrazuril supplemented group, the results of lipid peroxidation parameters were close to control values. VVLE (400 mg/kg) and toltrazuril led to a reduction in MDA and nitric oxide levels, while simultaneously increasing glutathione levels. These effects may further validate their antioxidant and anticoccidial properties.

CONCLUSION

Our findings indicate that *Vitis vinifera* is an effective agent, influencing both weight and feed intake. Additionally, *Vitis vinifera* appears to regulate the oxidative status in the liver of infected New Zealand rabbits. However, further studies are necessary to elucidate the precise mechanism of action of *Vitis vinifera* on both the host and the parasite.

ACKNOWLEDGEMENT

We thank the Researcher Support Program (RSP2024R/3), at King Saud University.

Conflict of interest

All authors declared that there is no conflict of interest.

REFERENCES

Abdel-Maged, A.D., Ahmed, N.E., Ramadan, M.Y., Elashrey, M.A. (2013). Biochemical effects of anti-protozoa on gastrointestinal tract enzymes and related hormones in rabbits. Benha Veterinary Medical Journal. 25(2): 113-124.

Amer, O.S., Dkhil, M.A., Hikal, W.M., Al-Quraishy, S. (2015). Antioxidant and anti-inflammatory activities of pomegranate (*Punica granatum*) on *Eimeria papillata*-induced infection in mice. BioMed Research International. 219670. doi: 10.1155/2015/219670.

Aouey, B., Samet, A.M., Fetoui, H., Simmonds, M.S.J., Bouaziz, M. (2016). Antioxidant, anti-inflammatory, analgesic and antipyretic activities of grapevine leaf extract (*Vitis vinifera*) in mice and identification of its active constituents by LC-MS/MS analyses. Biomedicine and Pharmacotherapy. 84: 1088-1098.

Barbour, E.K., Ayyash, D.B., Iyer, A., Harakeh, S., Kumosani, T. (2015). A review of approaches targeting the replacement of coccidiostat application in poultry production. Brazilian Journal of Poultry Science. 17(4): 405-418.

Bombardelli, E., Morazzonni, P. (1995). *Vitis vinifera* L. Fitoterapia. 66.

Brisbin, J.T., Gong, J., Sharif, S. (2008). Interactions between commensal bacteria and the gut-associated immune system of the chicken. Animal Health Research Reviews. 9(1): 101-110.

Çam, Y., Atasever, A., Eraslan, G., Kibar, M., Atalay, Ö., Beyaz, L., Liman, B.C. (2008). *Eimeria stiedae*: Experimental infection in rabbits and the effect of treatment with toltrazuril and ivermectin. Experimental Parasitology. 119(1): 164-172.

Cedric, Y., Khan Payne, V., Christelle Nadia, N.A., Kodjio, N., Kollins, E., Leonelle, M., Kuiate, J.-R., Mbida, M. (2017). *In vivo* anticoccidial and antioxidant activities of *Psidium guajava* methanol extract. European Journal of Medicinal Plants. 21(1): 1-12.

Chand, N., Ali, P., Alhidary, I.A., Abdelrahman, M.A., Albadani, H., Khan, M.A., Khan, R.U. (2021). Protective effect of grape (*Vitis vinifera*) seed powder and zinc-glycine complex on growth traits and gut health of broilers following *Eimeria tenella* challenge. Antibiotics. 10(2): 186.

Chikoto, H., Eloff, J.N. (2005). Antioxidant. Patent NR, 9681.

Dkhil, M.A., Moneim, A.A., Al-Quraishy, S. (2012). Antioxidant, hepatoprotective and ameliorative effects of *Azadirachta indica* on *Eimeria papillata*-induced infection in mice. Journal of Medicinal Plants Research. 6(20): 3640-3647.

El-Ghoneimy, A., El-Shahawy, I. (2017). Evaluation of amprolium and toltrazuril efficacy in controlling natural intestinal rabbit coccidiosis. Iranian Journal of Veterinary Research. 18(3): 164-169.

El-Shahawi, G.A., El-Fayomi, H.M., Abdel-Haleem, H.M. (2012). Coccidiosis of domestic rabbit (*Oryctolagus cuniculus*) in Egypt: Light microscopic study. Parasitology Research. 110: 251-258.

Felicio, J., Santos, R., Gonc, E. (2001) Chemical constituents from *Vitis veinifera* (Vitaceae). Sao Paulo. 68: 47-50.

Hassan, K.M., Arafa, W.M., Mousa, W.M., Shokier, K.A., Shany, S.A., Aboelhadid, S.M. (2016) Molecular diagnosis of *Eimeria stiedae* in hepatic tissue of experimentally infected rabbits. Experimental Parasitology. 169: 1-5.

Heelan, J.S., Ingersoll, F.W. Ingersoll, F.W. (2002). Essentials of Human Parasitology. Delmar Publishers.

Heyman, S.N., Rosen, S. Rosenberger, C. (2011). A role for oxidative stress. Contributions to Nephrology. 174: 138-48.

Hussein, A.O., Mohammed, G.J., Hadi, M.Y., Hameed, I.H. (2016). Phytochemical screening of methanolic dried galls extract of Quercus infectoria using gas chromatography-mass spectrometry (GC-MS) and Fourier transform- infrared (FT-IR). Journal of Pharmacognosy and Phytotherapy. 8(3): 49-59.

Jing, J., Liu, C., Zhu, S.X., Jiang, Y.M., Wu, L.C., Song, H.Y., (2016). Pathological and ultrastructural observations and liver function analysis of Eimeria stiedae infected rabbits. Veterinary Parasitology. 223: 165-172.

Kallel, K., Haouas, N., Pratlong, F., Kaouech, E., Belhadj, S., Anane, S., Dedet, J., Babba, H., Chaker, E. (2008). La leishmaniose cutanée due á Leishmania infantum MON-24 en Tunisie: extension du foyer vers le centre du pays. Bulletin de la Société de Pathologie Exotique 101: 30-31.

Kapoor, L. (1990). Handbook of Ayurvedic Medicinal Plants. CRC Press, Boca Raton, USA. pp. 45-56.

Kaya, S., Sütçü, R., Cetin, E.S., Arıdogan, B.C., Delibaş, N., Demirci, M. (2007). Lipid peroxidation level and antioxidant enzyme activities in the blood of patients with acute and chronic fascioliasis. International Journal of Infectious Diseases. 11(3): 251-255.

Liu, X. (2019). Coccidiosis in Rabbits (*Oryctolagus cuniculus*). In: Coccidiosis in Livestock, Poultry, Companion Animals and Humans. [Pakandl, M., Liu, X., (eds.)]. Florida: CRC Press. p. 159-168.

Lukefahr, S.D., Cheek, P.R. (1990). Rabbit project planning strategies for developing countries. Practical considerations. Livestock Research for Rural Development. 2(2): Article #22. Retrieved July 8, 2024, from http://www.lrrd.org/lrrd2/3/cheeke1.htm

Mohammed, L.S., Sallam, E.A., El Basuni, S.S., Eldiarby, A.S., Soliman, M.M., Aboelenin, S.M., Shehata, S.F. (2021). Ameliorative effect of neem leaf and pomegranate peel extracts in coccidial infections in New Zealand and V-Line rabbits: Performance, intestinal health, oocyst shedding, carcass traits and effect on economic measures. Animals. 11(8): 2441.

Montogomery, H., Dymock, J. (1961). The determination of nitrite in water: Colorimetric method of nitric oxide assay. Analyst. 86: 414.

Ohkawa, H., Ohishi, N., Yagi, K. (1979). Assay for lipid peroxides in animal tissues by thiobarbituric acid reaction. Analytical Biochemistry. 95(2): 351-358.

Paglia, D.E., Valentine, W.N. (1967). Studies on the quantitative and qualitative characterization of erythrocyte glutathione peroxidase. The Journal of Laboratory and Clinical Medicine. 70(1): 158-169.

Sivajothi, S., Reddy, B.S., Rayulu, V.C. (2016). Study on impression smears of hepatic coccidiosis in rabbits. Journal of Parasitic Diseases. 40: 906-909.

Wang, J.S., Tasi, S.F. (1991). Prevalence and pathological study on rabbit hepatic coccidiosis in Taiwan. Proceedings of the National Science Council, Republic of China. Part B15 (4): 240-243.

Wang, M.L., Suo, X., Gu, J.H., Zhang, W.W., Fang, Q., Wang, X. (2008). Influence of grape seed proanthocyanidin extract in broiler chickens: Effect on chicken coccidiosis and antioxidant status. Poultry Science. 87(11): 2273-2280.

Xie, Y., Xiao, J., Zhou, X., Gu, X., He, R., Xu, J., Jing, B., Peng, X., Yang, G. (2021). Global transcriptome landscape of the rabbit protozoan parasite *Eimeria stiedae*. Parasites and Vectors. 14: 308.

Yousif, O.M.A., Abdul-Aziz, J.A.M. (1995). Commercial Rabbit Production. Published by Al Dar Al-Arabia, Cairo, Egypt.