RESEARCH ARTICLE Indian Journal of Animal Research, Volume 59 Issue 4: 638-645 (April 2025)

Geraniol Abrogates Aluminum-elicited Testicular Toxicity and Endocrine-sperm Deficits by Curtailing Oxidative Inflammation and Caspase-dependent Apoptosis in Male Rats

Nourah Almulhim[1], Manal Alfwuaires[2], Hany Elsawy[3], Azza Sedky[4]

10.18805/IJAR.BF-1819

ABSTRACT

Background: Aluminum (Al) is a ubiquitous environmental toxicant associated with adverse effect on the testis. Thus, we investigated the protective effect of GER against Al-induced testicular injury and endocrine-sperm deficits in male rats.

Methods: Adult male rats were randomly divided into 4 groups: Control group, GER group (100 mg/kg body weight for 28 consecutive days, orally), Al group (200 mg/kg body weight every 3 days for 28 days, ip) and GER + Al group (100 mg/kg + 200 mg/kg). Levels of testosterone (T), luteinizing hormone (LH) and follicle-stimulating hormone (FSH) were measured in serum. Testicular parameters of oxidative stress, inflammation and apoptosis were analysed, as well as sperm parameters and testis histology.

Result: The Al exposure significantly ($p<0.05$) decreased levels of T, LH, FSH, IL-4 and IL-10, whereas Al increased oxidative stress, inflammation and apoptotic markers compared to the control. Al induced marked histopathological abrasions and caused adverse effects on sperm parameters compared to the control. On the contrary, the co-administration of GER with Al ameliorated the Al-induced endocrine-sperm deficits, testicular oxidative stress, cytokine inflammation and apoptosis. GER is a potential natural monoterpene for prevention of Al-induced testicular toxicity and endocrine-sperm dysfunction in rats.

Key words: Aluminium chloride, Geraniol, Inflammation, Oxidative stress, Testis, Toxicity.

INTRODUCTION

Exposure to chemicals via environment and in certain treatment conditions are a growing source of health challenge (Al-Nwaiser *et al*., 2022a; Al-Nwaiser *et al*., 2022b). Al accumulates in vital organs like kidney, liver, brain and testis, where it triggers cell deterioration and toxic damage (Othman *et al.,* 2020). Studies show that Al is a multi-organ toxicant due to its potential to cause hepatotoxicity, nephrotoxicity, neurotoxicity, cardiotoxicity, ovarian and testicular toxicities in various animal models (Deiab *et al*., 2023; Abu-Elfotuh *et al*., 2022). However, the testis is more susceptible to Al toxicity due to its high content of membrane polyunsaturated lipids. The disturbance of the testis may impair reproductive functions leading to depressed sperm quality and male infertility *via* oxidative inflammation and apoptosis (Rai *et al.,* 2023; Cheraghi *et al*., 2017). The mechanism of Al-induced testicular toxicity has been associated with reactive oxygen species (ROS)-mediated oxidative stress and inflammation that lead to apoptosis and a number of aberrant intracellular pathways (Rai *et al.,* 2023). Long-time exposure leads to high Al accumulation in the testis. The oxidative interaction of Al with testicular membranes, Sertoli cells, Leydig cells, spermatozoa and seminal plasma triggers ROS generation (Rai *et al*., 2023; Deiab *et al*., 2023; Cao *et al*., 2020). Thus, the ROS causes testicular oxidative deterioration, impairment of spermatogenesis and endocrine dysfunction (Deiab *et al.,* 2023; Yousef *et al.,* 2005; Deiab *et al.,* 2023; Cheraghi *et al*., 2017).

Studies show that natural phytocompounds exhibit antioxidant potentials that can combat ROS-mediated toxicity (Famurewa *et al.,* 2022; Famurewa *et al*., 2020; Ukwubile *et al.,* 2023). Geraniol is an acyclic isoprenoid monoterpene that can be isolated from the essential oils of various plants (Lei *et al.,* 2019). GER is a bioactive natural compound and a major component of lemon, rose palmrosa, lavender, orange essential oils and ginger (Algefare *et al*., 2024). Its pharmacological actions have been

[1]Department of Chemistry, College of Science, King Faisal University, Al-Ahsa, Saudi Arabia.
[2]Department of Biological Sciences, College of Science, King Faisal University, Al-Ahsa, 31982, Saudi Arabia.
[3]Department of Chemistry, Faculty of Science, Tanta University, Tanta, Egypt.
[4]Department of Zoology, Faculty of Science, Alexandria University, Alexandria, Egypt.

Corresponding Authors: Nourah Almulhim and Hany Elsawy, Department of Chemistry, College of Science, King Faisal University, Al-Ahsa, Saudi Arabia; Department of Chemistry, Faculty of Science, Tanta University, Tanta, Egypt.
Email: nmalmulhim@kfu.edu.sa, hany.mostafa@science.tanta.edu.eg
ORCID: https://orcid.org/0000-0001-8250-4023

How to cite this article: Almulhim, N., Alfwuaires, M., Elsawy, H. and Sedky, A. (2025). Geraniol Abrogates Aluminum-elicited Testicular Toxicity and Endocrine-sperm Deficits by Curtailing Oxidative Inflammation and Caspase-dependent Apoptosis in Male Rats. Indian Journal of Animal Research. 59(4): 638-645. doi: 10.18805/IJAR.BF-1819.

Submitted: 18-05-2024 **Accepted:** 10-07-2024 **Online:** 30-07-2024

reported in previous scientific literature (Lei *et al.*, 2019; Lin *et al.*, 2021; Younis *et al.*, 2021; Younis *et al.,* 2020; Ma *et al.,* 2023). In a recent study, however, GER attenuates carbon tetrachloride-induced hepatotoxicity *via* suppression of hepatic oxidative stress, pro-inflammation and apoptosis in rats (Algefare *et al.,* 2024). Therefore, the study was conceived to explore the possible protective mechanism of GER against Al-induced testicular damage by targeting oxidative stress, inflammation and apoptosis in rats.

MATERIALS AND METHODS

Chemicals

Geraniol was bought from Sigma Aldrich Chemicals (China). Commercial kits used in this study were procured from Jiancheng Co (Nanjing, China) and Biodiagnostics, Cairo, Egypt. The commercial kits used for the evaluation of reproductive hormones, including FSH (Cat. No. E-EI-M0511), testosterone (T: Cat. No. EIA1559), LH (Cat. No. AKRLH-010) and were purchased from BIOCODE-HYCEL, Belgium, DRG Instruments Gmbh, Germany; and Shibayagi Co., Ltd., Japan, respectively.

Animals

This work was carried out in 2023 between October to December. Male adult Sprague-Dawley rats were used in this study with a weight range of 200-250 g. They were housed in steel cages in laboratory conditions at the Animal house of the King Faisal University, Saudu Arabia: temperature room (23°C-27°C), 83% humidity, with a 12 h light/ dark cycle. Food and water were given *ad libitum* to rats during the period of acclimatization and experimental period. All experimental procedures including the use of animals were approved by the Ethical Committee of the King Faisal University, Kingdom of Saudi Arabia (KFU-REC-2024-MAR-ETHICS2095.

Experimental design

Immediately after one-week acclimatization, the SD male rats were divided randomly into 4 groups of 6 animals each as follows:

Group 1 (Control): Rats were given normal rat diet and tap water (5 ml/kg, orally) for 28 days.

Group 2 (GER): Rats were administered GER (100 mg/kg body weight, orally) for 28 days (Algefare *et al.,* 2024).

Group 3: (Al): Rats were administered Al (200 mg/kg body weight, ip) dissolved in normal saline with 3 days interval for 28 days (Irnidayanti *et al.,* 2023).

Group 4: (GER+ Al): Rats were administered GER and Al according to the doses in groups 2 and 3 above, GER (100 mg/kg, orally) + Al (200 mg/kg, ip) for 28 days, respectively.

The doses used in this study agree with the established doses in published papers (Irnidayanti *et al.,* 2023; Algefare *et al.,* 2024). Experimental rats were anesthetized (ketamine, 100 mg/kg and xylazine, 10 mg/kg) dissected and both trunk blood (plain sample bottles) and testis samples were collected for biochemical and histological studies. Samples of blood were centrifuged at 3000 g for 10 minutes and serum samples were obtained. They were stored in -20°C for hormonal analysis (FSH, T and LH). Each testicular tissue was aseptically divided into two parts; one part was stored for assays on testicular activities of GPx, CAT, SOD and levels of MDA, caspase-3, caspase-9, interleukin-6 (IL-6), tumor necrosis factor-α (TNF-α), interleukin-4 (IL-4) and interleukin-10 (IL-10). The testes (1:5 w/v) were homogenized with a potter-Elvehjem homogenizer attached to a Taflon plunger in ice cold phosphate buffer (50 mM, pH 7.5). The homogenate samples were centrifuged (11, 000 ×g for 20 minutes) to obtain supernatant samples which were kept at -80°C until the time of analyses. The other part of tissue was preserved in 10% neutral formalin for histopathological analysis.

Biochemical analyses

Determination of hormones

The FSH levels in the serum of rats was measured with the use of Belgian BIOCODE-HYCEL rat ELISA kit (Cat No. E-EI-M0511) according to the protocols of Teerds *et al.* (1989). The rat ELISA kit used to measure the serum testosterone (T) levels was purchased from DRG Instruments Gmbh, Germany (Cat No. EIA1559). The rat ELISA kit (Cat No. AKRLH-10) was purchased from Shibayagi Company Limited, Japan. The determination of LH in the rat serum was according to Shioya and Wakabayashi (1998) procedures.

Determination of sperm characteristics

Sperm quality was assessed using epididymal suspension in this study. The suspension was obtained from the minced epididymis in prewarmed saline (37°C): The sperm count/number, motility, abnormality was determined as explained in our previous study (Alturki *et al.,* 2022).

Determination of testicular oxidative stress markers

The testicular activities of superoxide dismutase (SOD, Cat. No. SD2520), catalase (CAT, Cat. No. CA2516), glutathione peroxidase (GPx, Cat. No. GP2524) and level of malondialdehyde (MDA, Cat. No. MD2528) were determined using the respective manufacturers' protocols of rat ELISA kits.

Determination of testicular pro-inflammatory and anti-inflammatory markers

The testicular levels of pro-inflammatory cytokines, interleukin-6 (IL-6, Cat No R016), tumor necrosis factor-α (TNF-α, Cat No R019) and anti-inflammatory cytokines, interleukin-10 (IL-10, Cat No R017) and interleukin-4 (IL-4, Cat No R013) were determined using rat standard ELISA kits.

Determination of testicular apoptotic caspase activity

The testicular caspase 3 (Cat No: A064) and caspase 9 (Cat No: A069) were determined with rat ELISA kits following the manufacturer's directions.

Histopathological analysis

The preserved testis tissue was used to examine possible pathological alterations. The routine steps of H and E staining technique was followed according to Bancroft and Gamble (2002). Thereafter, possible histopathological changes were observed and photographed under a light microscope (Nikon 80i, Japan). The histopathological lesions were scored semi-quantitatively and mean values were determined: normal histostructure (0), mild (1), moderate (2) and severe alterations (3) (Elsawy *et al.,* 2023).

Statistical analyses

The GraphPad prism statistical software package (version 8; GraphPad Software Inc., San Diego, CA, USA) was used for analyses. Data were compared using one-way ANOVA followed by Tukey post-hoc test. Significant differences were obtained at P<0:05. The data were represented as mean± SEM (n= 6).

RESULTS AND DISCUSSION

Effect of GER on serum hormones and sperm characteristics of Al-exposed rats

Table 1 and 2 present the effect of GER on serum levels of FSH, T and LH and sperm characteristics in Al-exposed rats. It was observed that Al considerably reduced ($p<0.05$) the serum levels of FSH, T, LH, sperm count and motility while abnormality increased compared to the levels in control group. In contrast, the co-administration of GER with Al considerably reversed ($p<0.05$) the alterations compared to Al group.

Effect of GER on testicular oxidative stress and apoptosis markers in Al-exposed rats

Fig 1 represent the effects of GER on testicular activities of CAT, SOD and GPx, levels of MDA, caspase-3 and caspase-9 in Al-exposed rats. Results demonstrated that Al induced prominent ($p<0.05$) suppression in the testicular activities of CAT, SOD and GPx, whereas MDA levels, caspase-3 and caspase-9 increased in comparison to the control. Conversely, GER in GER + Al group reversed the oxidative effect of Al through significant increases in the activities of CAT, SOD and GPx, whereas MDA level, caspase-3 and caspase-9 reduced considerably ($p<0.05$) compared to the Al group.

Effect of GER on inflammatory and anti-inflammatory cytokines in Al-exposed rats

Fig 2 presents the effects of GER on the levels of pro-inflammatory (TNF-α and IL-6) and anti-inflammatory (IL-4 and IL-10) cytokines in rats exposed to Al. It was observed that Al triggered significantly ($p<0.05$) increased testicular levels of IL-6 and TNF-α, while the anti-inflammatory IL-10 and IL-4 levels reduced markedly ($p<0.05$) in comparison to the control. The concomitant administration of GER conspicuously reversed and restored the levels of the cytokines compared to the Al group.

Effect of GER on testis histology of Al-exposed rats

Examination of the testes sections of control group (Fig 1a) stained with H and E and GER group (Fig 1b) revealed no changes or lesions. Both showed normal testis structure with normal seminiferous tubules having complete spermatogenesis series and separated by interstitial tissue. Examination of the testicular tissues of Al-exposed group showed abnormalities in the testis structure where the seminiferous tubules appeared abnormal with incomplete spermatogenic series and surrounded by widened interstitial space (Fig 1c). Administration of GER showed improvement in testicular structure, the seminiferous tubules become closer to each other and the appearance of more spermatozoa in the tubular lumen (Fig 1d).

Table 1: Effect of GER on reproductive hormones in Al-exposed rats.

Group	FSH (ng/ml)	T (pg/ml)	LH (ng/ml)
Control	0.97±0.06	6.52±1.26	2.50±0.87
GER	0.99±0.10	6.32±1.66	2.51±0.61
Al	0.36±0.08*	3.91±0.97*	0.99±0.27*
GER + Al	0.57±0.10#	4.28±1.21#	1.40±0.88#

Values are mean ± SEM (6 rats/group). Abbreviations: Al: Aluminum; GER: geraniol; FSH: Follicle stimulating hormone; LH: Leutenizing hormone; T: Testosterone. *p<.05: Significant when compared to control group in the same column; #p<0.05: Significant when compared to Al group in the same column.

Table 2: Effect of GER on sperm quality characteristics in Al-exposed rats.

Group	Sperm count 10^6 cells/ml	Sperm motility (%)	Sperm abnormality (%)
Control	95.4±6.30	80.4±5.99	7.1±2.38
GER	95.2±6.11	81.2±8.31	7.2±3.41
Al	70.4±8.34*	56.2±10.38*	26.2±5.14*
GER + Al	81.0 7.77#	69.6 ±4.98#	14.8 2.18#

Values are mean ± SEM (6 rats/group). Abbreviations: Al: Aluminum; GER: Geraniol; *p<.05: Significant when compared to control group in the same column; #p<0.05: Significant when compared to Al group in the same column.

In the current study, the Al triggered a endocrine suppression demonstrated by marked reductions in the levels of FSH, T and LH compared to the control group (Table 1). These observations indicate that Al may interfere with spermatogenesis and steroidogenesis and influence the endocrine system (Berihu *et al.*, 2015). Therefore, the consequent result of the hormonal deficits was the impaired spermatogenesis leading to the declines observed in sperm count, mobility and morphology in this study. Previous studies have shown that reduced levels of FSH, T and LH

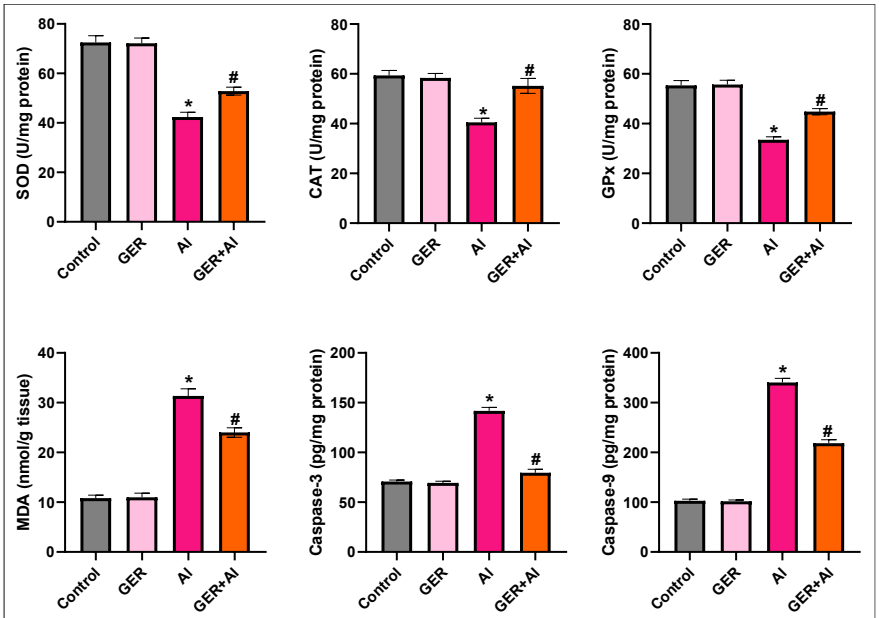

Al: Aluminum; GER: Geraniol. Values are expressed as mean ± SEM (n = 6). [N] Significant when compared to control ($p<0.05$); #significant compared to the Al group.

Fig 1: Effect of GER on testicular markers of oxidative stress and caspases in Al-exposed rats.

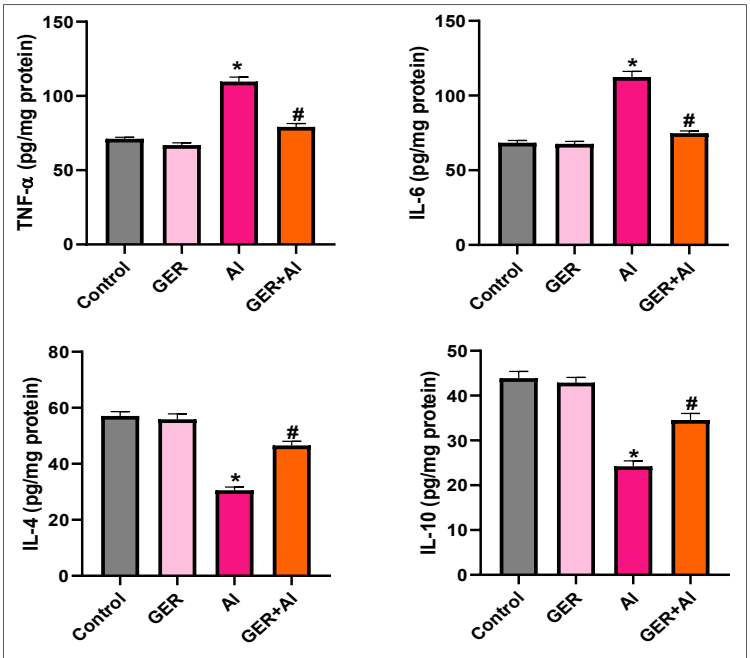

Al: Aluminum; GER: Geraniol. Values are expressed as mean ± SEM (n = 6). [N] Significant when compared to control ($p<0.05$); #significant compared to the Al group.

Fig 2: Effect of GER on testicular markers of inflammation (TNF-α and IL-6) and antiinflammation (IL-4 and IL-10) in Al-exposed rats.

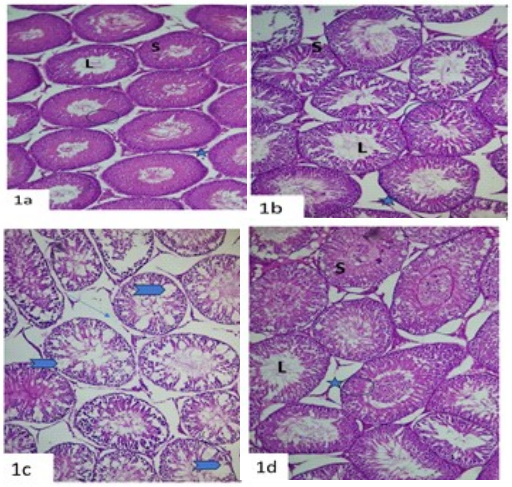

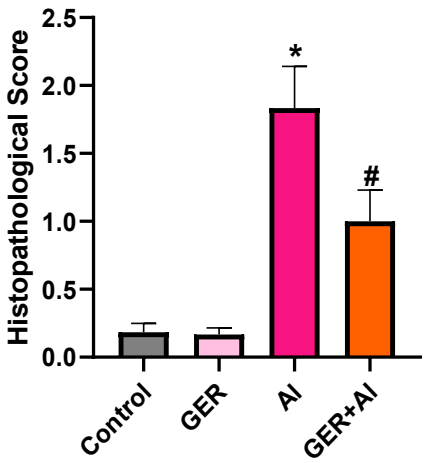

1a: control; 1b: GER group, (both show normal structure of seminiferous tubules with complete spermatogenic series and interstitial tissue); 1c: Al-exposed group shows testicular disruption, 1d: GER + Al group indicates an improvement in the seminiferous structure. S: seminiferous tubules, interstitial tissue (asterick), L: lumen, circle, germinal epithelium: arrow, widened interstitial space, arrow head: degenerated seminiferous tubules. (X100). Al: Aluminum; GER: Geraniol. Values are expressed as mean ± SEM (n = 3). [N] Significant when compared to the control ($p < 0.05$); [#]significant compared to the Al group. Hematoxylin and eosin staining of testicular tissue of different experimental groups.

Fig 3: Effect of GER on the histology of testis in Al-exposed rats.

are associated with abnormal sperm characteristics (Table 2) (Alturki *et al.,* 2022 Deiab *et al.,* 2023 Behairy *et al.,* 2022). Comparable results were reported by Cheraghi *et al.* (2017), who show that Al caused considerable reductions in the levels of T and LH followed by abnormal sperm quality in rats in consistent with our findings herein. The deleterious effect of Al on germinal epithelium detachment, seminiferous tubules and spermatogenic cell degeneration have also been demonstrated recently (Rai *et al.,* 2023). Oxidative alteration in mitochondrial membrane permeability may be a mechanism leading to altering sperm motility and morphology. On the contrary however, the oral administration of GER for 28 days inhibited the toxicity of Al on the hormones and sperm characteristics in this study (Table 1 and 2). The levels of the hormones and sperm quality in GER + Al group were prominently elevated in comparison to the levels obtained in Al group. The observed GER-mediated protection against Al may be due to antioxidant property of GER as shown and reported in previous studies (Younis *et al.,* 2021; Younis *et al.,* 2020; Algefare *et al.,* 2024; Oyedeji *et al.*, 2023).

Al induced testicular oxidative stress in this study. There were considerable reductions in the testicular activities of SOD, GPx and CAT, while the levels of MDA increased conspicuously in comparison to the control (Fig 1). Earlier studies indicate that Al-induced organ injury is associated with ROS generation and oxidative stress (Rai *et al.,* 2023; Othman *et al.,* 2020). Redox imbalance in cells or tissues overwhelms antioxidant mechanism leading to oxidative stress (Famurewa *et al.,* 2017; (Famurewa *et al.,* 2019; Wang *et al.,* 2020). However, the depressed activities of SOD, GPx and CAT occasioned by Al in this study exposed the testicular cell membrane to oxidative lipid peroxidation and degeneration which underlie the increased levels of MDA observed herein. Furthermore, the attack also disrupted the histological architecture with alterations in the seminiferous tubules demonstrated by incomplete spermatogenic series and surrounded by widened interstitial space (Fig 3-1a-1d) in consistent with earlier reports (Rai *et al.,* 2023; Deiab *et al.,* 2023). Interestingly, the administration of GER resisted and reversed the Al-induced oxidative histological deterioration and testicular oxidative stress. Significant elevations of these endogenous antioxidant enzymes were observed in the group co-treated with GER and Al in comparison to the Al group. The histopathological lesions were ameliorated. GER is known as an antioxidant bioactive monoterpene in several oxidative stress-related studies (Oyedeji *et al.,* 2023; Lin *et al.,* 2021; Younis *et al.,* 2020; Lei *et al.,* 2019). Our finding agrees with earlier findings (Younis *et al.,* 2020; Younis *et al.*, 2021; Algefare *et al.,* 2024; Oyedeji *et al.,* 2023).

Redox system imbalance is a well-recognised trigger of tissue inflammation(Al-Nwaiser *et al.*, 2022c; Famurewa *et al.*, 2020). And a robust body of findings shows the crosstalk of oxidative stress, inflammation and apoptosis (Famurewa *et al.,* 2019). We therefore assayed for some tissue markers of proinflammation. In the results of our analyses, we observed that Al significantly elevated the levels of testicular pro-inflammatory cytokines (TNF-α and IL-6), whereas the levels of anti-inflammatory cytokines (IL-4 and IL-10) considerably reduced compared to the control (Fig 2). In previous studies, Al has induced inflammatory (Falade *et al.*, 2022; Turk *et al.,* 2021; Othman *et al.,* 2020) in agreement with our findings (Wu *et al.*, 2020;

Younis *et al.,* 2020). Therefore, the testicular alterations in the levels of TNF-α, IL-6, IL-4 and IL-10 suggest that Al has a potential to induce inflammation. However, inhibition of the inflammatory response and oxidative stress prevents organs from damage. A number of phytochemicals have shown anti-inflammatory effects (Younis *et al.,* 2021; Famurewa *et al.,* 2020; Wang *et al.,* 2020). In corollary, GER in this study abrogated the Al-induced pro-inflammation. The anti-inflammatory effect of GER was demonstrated by pronounced decreases in the levels of TNF-α and IL-6, while the levels of anti-inflammatory cytokines, IL-4 and IL-10, increased in the testis of rats significantly compared to the Al group (Fig 2) as in the study of Malik *et al.* (2023; Ma *et al.,* 2023; Younis *et al.,* 2020; Khan *et al.,* 2013) and increasing the levels of IL-4 and IL-10 (Lei *et al.,* 2019).

We assayed for caspase-3 and caspase-9 in this study. Our findings agree with the earlier published report as demonstrated by the marked increased levels of caspase-3 and caspase-9 in the testis of Al-exposed rats compared to the control (Fig 1) (Abu-Elfotuh *et al.,* 2022; Othman *et al.,* 2020). In contrast, GER treatment ameliorated the observed changes in the levels of caspase-3 and caspase-9, indicating testicular cell protective activity against apoptosis. These findings are consistent with previous studies that indicate GER as a protective agent against caspase-dependent apoptosis in different agent-induced cardiotoxicity (Younis *et al.,* 2021), hepatotoxicity (Algefare *et al.,* 2024), cardiotoxicity (Younis *et al.,* 2020) and diabetic testicular injury (Oyedeji *et al.,* 2023).

CONCLUSION

In conclusion, the present study has demonstrated the Al-induced dysfunction in endocrine pituitary-gonadal axis and testicular toxicity in consistent with the existing literature. Importantly, the present work unravels, for the first time, that GER could exert testiculo-protective effect against Al-triggered testicular toxicity through abrogation of oxidative stress, inflammation and apoptosis. These beneficial effects could be adduced to the antioxidant, anti-inflammatory and antiapoptotic activities of GER in this study.

ACKNOWLEDGEMENT

The authors acknowledge the Deanship of Scientific Research, Vice Presidency for Graduate Studies and Scientific Research at King Faisal University, Saudi Arabia for financial support under the Annual Funding track (Grant No. KFU 241325).

Funding information

Deanship of Scientific Research, King Faisal University, Saudi Arabia, with Grant Number: GRANT No. KFU 241325.

Conflict of interest

All authors declare that they have no conflicts of interest.

REFERENCES

Al-Nwaiser, F.A., Bekht, G. and Sedky, A. (2022a). Betamethasone toxicity induced by topical maternal exposure prior to fertilization in heart of newborn rabbits. Indian Journal of Animal Research. 57(5): 632-637. doi: 10.18805/IJ AR.BF-1557.

Al-Nwaiser, F., Bekhet, G. and Sedky, A. (2022b). cerebellar toxicity induced by maternal exposure to topical betamethasone prior to fertilization in newborn rabbits. Indian Journal of Animal Research. 56(8): 1017-1023. doi: 10.18805/IJA R.BF-1458.

Al Nwaiser, F., Bekhet, G. and Sedky, A. (2022c). Hepatorenal toxicity induced by maternal exposure to topical betamethasone prior to fertilization in newborn rabbits. Indian Journal of Animal Research. 56(9): 1132-1137. doi: 10.18805/IJA R.BF-1456.

Abu-Elfotuh, K.., Hussein, F.H., Abbas, A.N., Al-Rekabi, M.D., Barghash, S.S., Zaghlool, S.S., El-Emam, S.Z. (2022). Melatonin and zinc supplements with physical and mental activities subside neurodegeneration and hepatorenal injury induced by aluminum chloride in rats: Inclusion of GSK-3β-Wnt/β-catenin signaling pathway. Neurotoxicology. 91: 69-83.

Algefare, A.I., Alfwuaires, M., Famurewa, A.C., Elsawy, H., Sedky, A. (2024). Geraniol prevents CCl_4-induced hepatotoxicity *via* suppression of hepatic oxidative stress, pro-inflammation and apoptosis in rats. Toxicology Report. 12: 128-134.

Alturki, H.A., Elsawy, H.A., Famurewa, A.C. (2022). Silymarin abrogates acrylamide-induced oxidative stress-mediated testicular toxicity via modulation of antioxidant mechanism, DNA damage, endocrine deficit and sperm quality in rats. Andrologia. 54(9): e14491.

Ansari, M.Y., Ahmad, N., Haqqi, T.M. (2020). Oxidative stress and infammation in osteoarthritis pathogenesis: Role of polyphenols. Biomedicine and Pharmacotherapy. 129: 110452.

Bancroft, J.D. and Gamble, M. (2002). Theory and Practice of Histological Techniques. 796.

Behairy, A., Hashem, M.M., Abo-El-Sooud, K., El-Metwally, A.E., Hassan, B.A., Abd-Elhakim, Y.M. (2022). Quercetin abates aluminum trioxide nanoparticles and lead acetate induced altered sperm quality, testicular oxidative damage and sexual hormones disruption in male rats. Antioxidants. 11: 2133.

Berihu, B.A. (2015). Histological and functional effect of aluminium on male reproductive system. Int. J. Pharmacentical Science and Research. 6(8): 1122-1132.

Cao, C., Zhang, H., Wang, K., Li, X. (2020). Selenium-rich yeast mitigates aluminum-mediated testicular toxicity by blocking oxidative stress, inhibiting NO production and disturbing ionic homeostasis. Biological Trace Element Research. 195: 170-177.

Cheraghi, E., Golkar, A., Roshanaei, K., Alani, B. (2017). Aluminium-induced oxidative stress, apoptosis and alterations in testicular tissue and sperm quality in wistar rats: Ameliorative effects of curcumin. Int. Journal of Fertility and Sterility. 11(3): 166-175.

Deiab, N.S., Kodous, A.S., Mahfouz, M.K., Said, A.M., Ghobashy, M.M., Abozaid, O.A. (2023). Smart hesperidin/chitosan nanogel mitigates apoptosis and endoplasmic reticulum stress in fluoride and aluminum induced testicular injury. Biological Trace Element Research. doi: 10.1007/s12011-023-03991-8.

Elsawy, H., Famurewa, A.C. and Sedky, A. (2023). Resveratrol mitigates diabetic testicular dysfunction, endocrine deficits and insulin resistance *via* suppression of sperm-endocrine aberrations and oxidative inflammation in rats. Andrologia. https://doi.org/10.1155/2023/6385767.

Falade, A., Adewole, K., Adekola, A., Ikokoh, H., Okaiyeto, K., Oguntibeju, O. (2022). Aqueous extract of bay leaf (*Laurus nobilis*) ameliorates testicular toxicity induced by aluminum chloride in rats. Veterinaty World. 15(11): 2525-2534.

Famurewa, A.C., Aja, P.M., Maduagwuna, E.K., Ekeleme-Egedigwe, C.A., Ufebe, O.G., Azubuike-Osu, S.O. (2017). Antioxidant and anti-inflammatory effects of virgin coconut oil supplementation abrogates acute chemotherapy oxidative nephrotoxicity induced by anticancer drug methotrexate in rats. Biomedicine and Pharmacotherapy. 96: 905-911.

Famurewa, A.C., Asogwa, N.T., Aja, PM, *et al*. (2019). *Moringa oleifera* seed oil modulates redox imbalance and iNOS/NF-8B/caspase-3 signaling pathway to exert antioxidant, anti-inflammatory and antiapoptotic mechanisms against anticancer drug 5-fluorouracil-induced nephrotoxicity in rats. South African Journal of Botany. 127: 96-103.

Famurewa, A.C., Renu, K., Eladl, M.A., Chakraborty, R., Myakala, H., El-Sherbiny, M., Elsherbini, D.M., Vellingiri, B., Madhyastha, H., Wanjari, U.R., Mukherjee, A.G., Gopalakrishnan, A.V. (2022). Hesperidin and hesperetin against heavy metal toxicity: Insight on the molecular mechanism of mitigation. Biomedicine and Pharmacotherapy. 149: 112914.

Famurewa, A.C., Ekeleme-Egedigwe, C.A., Onwe, C.S., Egedigwe, U.O., Okoro, C.O., Egedigwe, U.J. and Asogwa, N.T. (2020). Ginger juice prevents cisplatin-induced oxidative stress, endocrine imbalance and NO/iNOS/NF-κB signalling *via* modulating testicular redox-inflammatory mechanism in rats. Andrologia. 52: e13786.

Irnidayanti, Y., Fatona, D., Rizkawati, V. (2023). Histological changes in liver and kidney of male mice by age after exposure to aluminum chloride. Toxicology and Industrial Health. 39(8): 441-450.

Khan, A.Q., Khan, R., Qamar, W., Lateef, A., Rehman, M.U., Tahir, M., Ali, F., Hamiza, O.O., Hasan, S.K., Sultana, S. (2013). Geraniol attenuates 12-O-tetradecanoylphor-bol-13-acetate (TPA)-induced oxidative stress and inflammation in mouse skin: Possible role of p38 MAP Kinase and NF-kappaB. Experimental and Molecular Pathology. 94: 419-429.

Lei, Y., Fu, P., Jun, X., Cheng, P. (2019). Pharmacological properties of geraniol- A review. Planta Medica. 85: 48-55.

Lin, L., Long, N., Qiu, M., Liu, Y., Sun, F., Dai, M. (2021). The inhibitory efficiencies of geraniol as an anti-inflammatory, antioxidant and antibacterial, natural agent against methicillin-resistant *Staphylococcus aureus* infection *in vivo*. Infectection and Drug Resistance. 14: 2991-3000.

Ma, J., Xu, Y., Zhang, M., Li, Y. (2023). Geraniol ameliorates acute liver failure induced by lipopolysaccharide/ D-galactosamine *via* regulating macrophage polarization and NLRP3 inflammasome activation by PPAR-γ methylation geraniol alleviates acute liver failure. Biochemical Pharmacology. 210: 115467.

Malik, H., Tahir, M., Alsahli, T., Tusher, M., Alzarea, S., Alsuwayt, B., Jahan, *et al*. (2023). Geraniol suppresses oxidative stress, inflammation and interstitial collagenase to protect against inflammatory arthritis. ACS Omega. 8(40): 37128-37139.

Othman, M.S., Fareid, M.A., Abdel Hameed, R.S., Abdel Moneim, A.E. (2020). The protective effects of melatonin on aluminum-induced hepatotoxicity and nephrotoxicity in rats. Oxid. Med. Cell. Longev. pp. 7375136.

Oyedeji, T., Olasore, H., Oluwole-Banjo, A., Isong, J., David, B., Ekpere, C., Ilesanmi, O., Madu, D., Matthew, C. (2023). Geraniol ameliorates testicular damage in diabetic rats *via* inhibition of redox parameters and mitochondrial-mediated apoptosis. Pharmacological Research-Modern Chinese Medicine. 8: 100268.

Rai, R., Jat, D., Mishra, S.K. (2023). Naringenin ameliorates aluminum toxicity-induced testicular dysfunctions in mice by suppressing oxidative stress and histopathological alterations. Systems Biology and Reproductive Medicine. 69(5): 347-353.

Sakuma, Y. (2009). Gonadal steroid action and brain sex differentiation in the rat. Journal of Neuroendocrinology. 21(4): 410-414.

Shioya, N. and Wakabayashi, K. (1998). *In vivo* bioactivities and kinetic parameters of rat luteinizing hormone components: Discrepancy between *in vitro* and *in vivo* assays. Endocrine Journal. 45: 307-314.

Teerds, K.J., Closset, J., Rommerts, R.F.G., De Rooij, D.G., Stocco, D.M., Colenbrander, B., Gwensing, J. and Hennen, G. (1989). Effects of pure FSH and LH preparations on the number and function of Leydig cells in immature hypophy sectomized rats. Journal of Endocrinology. 120: 97-106.

Türk, E., Tekeli, I.O., Özkan, H., Uyar, A., Cellat, M., Kuzu, M., Yavas, I., Yegani, A.A., Yaman, T. and Güvenç, M. (2021). The protective effect of esculetin against aluminium chloride-induced reproductive toxicity in rats. Andrologia. 53(2): e13930.

Ukwubile, C.A., Ikpefan, E.O., Dibal, M.Y., Umeano, V.A., Menkiti, D.N., Kaosi, C.C., Paul, S., Famurewa, A.C., Nettey, H., Yerima, T.S. (2023). Pharmacognostic profiles, evaluation of analgesic, anti-inflammatory and anticonvulsant activities of *Newbouldia laevis* (P. Beauv.) Seem. ex Bureau leaf and root extracts in Wistar rats. Journal of Ethnopharmacology. 314: 116632.

Wang, L., He, Y., Li, Y., Pei, C., Olatunji, O.J., Tang, J., Famurewa, A.C., Wang, H. and Yan, B. (2020). Protective effects of nucleosides-rich extract from *Cordyceps cicadae* against cisplatin induced testicular damage. Chemistry and Biodiversity. 17(11): e2000671.

Waykar, B.B. and Alqadhi, Y.A. (2018). Administration of honey and royal jelly ameliorate cisplatin induced changes in liver and kidney function in rats. Biomedicine and Pharmacology Journal. 11(4): 2191-2199.

Wu, Y., Wang, Z., Fu, X., Lin, Z., Yu, K. (2020). Geraniol-mediated osteoarthritis improvement by down-regulating PI3K/Akt/NF-κB and MAPK signals: *In vivo* and *in vitro* studies. Int. Immunopharmacology. 86: 106713.

Younis, N., Elsewedy, H., Soliman, W., Shehata, T., Mohamed, M. (2021). Geraniol isolated from lemon grass to mitigate doxorubicin-induced cardiotoxicity through Nrf2 and NF-κB signaling. Chemico- Biological Interactions. 347: 109599.

Younis, N.S., Abduldaium, M.S. and Mohamed, M.E. (2020). Protective effect of geraniol on oxidative, inflammatory and apoptotic alterations in isoproterenol-induced cardiotoxicity: Role of the Keap1/Nrf2/HO-1 and PI3K/Akt/mTOR pathways. Antioxidants. 9: 977-992.

Yousef, M.I., El-Morsy, A.M., Hassan, M.S. (2005). Aluminium-induced deterioration in reproductive performance and seminal plasma biochemistry of male rabbits: protective role of ascorbic acid. Toxicology. 215: 97-107.