RESEARCH ARTICLE Indian Journal of Animal Research, Volume 59 Issue 4: 629-637 (April 2025)

Ameliorative Effects of *Teucrium polium* Leaves Ethanolic Extract on Liver Histopathology Induced by *Eimeria papillata*

Saleh Maodaa[1], Sarah Alawwad[2], Afaf Alatawi[1], Rewaida Abdel-Gaber[1], Dalal Alhomoud[1], Saleh Al-Quraishy[1], Esam Al-Shaebi[1]

10.18805/IJAR.BF-1827

ABSTRACT

Background: *Teucrium polium* is an herb utilized in traditional medicine for its biological activity. In the present study, *T. polium* leaves ethanolic extract (TPLEE) was investigated for its effects on coccidiosis resulting from *Eimeria papillata* infection in mice. **Methods:** *In vivo*, TPLEE (150 mg/kg) was administered for its antioxidant and hepatoprotective properties. The anticoccidial and anti-inflammatory effects of TPLEE were evaluated by measuring oocyst suppression and assessing liver histopathology, respectively. **Result:** Indicated that treatment with 150 mg/kg TPLEE led to oocyst suppression percentage of 91.2±4.1, similar to the efficacy of the reference drug amprolium (93.2±3.9) and was associated with a significant decrease in the number of developmental parasitic stages in jejunal sections. Infection with the parasite causes metabolic disturbance, inflammation and liver injury, as evidenced by histopathological changes such as Kupffer cell activation, vacuolated hepatocytes and increases in inflammatory cellular infiltration. In addition, infection led to a significant increase in malondialdehyde (MAD) and nitric oxide (NO) and a significant decrease in superoxide dismutase (SOD) and glutathione (GSH). The TPLEE showed significant hepatoprotective ability by improving the above parameters. TPLEE demonstrated both anticoccidial properties and the ability to alleviate preexisting liver damage caused by Eimeria infection.

Key words: Liver, Oocyst, Oxidative stress, *Teucrium polium*.

INTRODUCTION

Coccidiosis, caused by apicomplexan parasites of the genus *Eimeria,* is a well-recognized parasitic disease affecting the intestinal tract of wild and domestic animals (Sohaib and Jamil, 2017). The infection targets various intestinal sites and progresses rapidly (within 4-7 days), marked by parasite replication within host cells and significant damage to the intestinal mucosa. One such species, *E. papillata*, inhabits the jejunum of mice, leading to significant damage to the intestinal mucosa, inflammation and heightened oxidative conditions (Abdel-Tawab *et al*., 2020; Abdel-Tawab *et al*., 2024). While its primary impact is on the intestinal tract, it indirectly affects accessory organs like the liver. where is the liver exhibits an even more pronounced response, despite not being a direct target site of *E. papillata* (Dkhil *et al*., 2011a). Research indicates that *Eimeria* infection impact the liver and exhibits several signs of moderate inflammation, *i.e.*, inflammatory cellular infiltrations around the central vein, dilatated blood sinusoids, an increase in vacuolated hepatocytes, hypertrophic Kupffer cells. Dkhil and Al-Quraishy (2012) reported metabolic disturbance and hepatic tissue damage induced by *E. papillata* infection. So, hepatic health is severely compromised due to metabolic deterioration and elevated levels of key hepatic parameters alongside hepatic tissue damage.

To combat coccidiosis and enhance poultry health, conventional strategies like administering coccidiostats in feed and preventive vaccinations are commonly employed. However, there's a growing concern over the emergence of drug-resistant oocysts and the presence of drug residues in broiler meat and its toxicity. Currently, a wide range of broad-spectrum anti-coccidial medications, including decoquinate, toltrazuril, amprolium, diclazuril and sulfonamide, are used to treat and prevent *eimeriosis*. These drugs have been developed toxicity and resistance as a result of frequent use. Nonetheless, efforts to find novel compounds with anti-*Eimeria* action should be made in light of growing concerns regarding parasite resistance, consumer health and the environmental safety of commercial medications (Wunderlich *et al*., 2014). Additionally, the issue of drug resistance has prompted numerous researchers to look for alternative approaches to treating coccidiosis.

In summary, a number of mechanisms are known by which coccidia become resistant to anticoccidial drugs. Resistance may involve altered permeability of the cell

[1]Department of Zoology, College of Science, King Saud University, P.O. 2455, Riyadh 11451, Saudi Arabia.

[2]Department of Food Science and Nutrition, College of Food and Agricultural Science, King Saud University, P.O. Box 2460, Riyadh 11451, Saudi Arabia.

Corresponding Author: Saleh Maodaa, Department of Zoology, College of Science, King Saud University, P.O. 2455, Riyadh 11451, Saudi Arabia. Email: maodaa_28@yahoo.com

How to cite this article: Maodaa, S., Alawwad, S., Alatawi, A., Abdel-Gaber, R., Alhomoud, D. Al-Quraishy, S. and Al-Shaebi, E. (2025). Ameliorative Effects of *Teucrium polium* Leaves Ethanolic Extract on Liver Histopathology Induced by *Eimeria papillata.* Indian Journal of Animal Research. 59(4): 629-637. doi: 10.18805/IJAR.BF-1827.

Submitted: 05-06-2024 **Accepted:** 18-07-2024 **Online:** 26-08-2024

membrane so that the drug is no longer taken up or is rapidly pumped out of the cell (ionophores), use of an alternative biochemical pathway (clopidol, quinolones) and modification of the target sites in the coccidia parasites (amprolium).

Also, there are several processes that are understood to cause coccidial resistance to anticoccidial medications. Whereas, resistance can take several forms, such as changing the target locations in the coccidia parasites (amprolium), using an alternate biochemical pathway (clopidol, quinolones), or changing the permeability of the cell membrane so that the drug is either rapidly pumped out of the cell or no longer taken in (ionophores) (Abbas *et al*., 2011).

In response to these pressing global needs, there's a heightened interest in safe and effective alternatives for controlling coccidiosis, including the use of plant extracts, essential oils and traditional medicinal products. Where it is considered medicinal plants serve as the primary source of alternative or natural medical systems, esteemed for their therapeutic properties. These approaches are valued for their efficacy in yielding effective chemical ingredients (Sidiropoulou *et al*., 2020 and Mosaddeghi *et al*., 2021)., showcasing organ-protective characteristics in Eimeria-infected hosts while targeting the parasites directly (Wunderlich *et al*., 2014).

T. polium, a perennial wild flowering plant that is widely distributed, has been traditionally utilized in treating various ailments (Akin *et al*., 2010; Çakılcıoğlu *et al*., 2010; Couladis *et al*., 2003). Recent studies on this plant have unveiled its efficacy in treating a multitude of disorders, likely attributed to its flavonoids and sterols, known for their anti-inflammatory properties (Abdollahi *et al*., 2003). *T. polium*, fragrant in nature, contains a rich array of compounds, including tannin, terpenoid, saponin, flavonoid, glycoside-α, sterol, leucoanthocyanin, beta-caryophyllene, caryophyllene oxide, diterpenoid, asparagine and dietrin, some of which exhibit anti-inflammatory effects (Aburjai *et al*., 2006; Ansari *et al*., 2009; Oganesyan *et al*., 1991).

Multiple studies highlighted the hepatoprotective properties of *T. polium* extract. For instance, Kareem and Hamza (2022) demonstrated that the aqueous extract of *T. polium* mitigated liver tissue damage induced by the preservative sodium benzoate in male rabbits (*Oryctolagus cuniculus*). Similarly, Panovska *et al*. investigated the hepatoprotective effects of the ethyl acetate extract of *T. polium* L. against liver damage induced by carbon tetrachloride (CCl4). They found that intraperitoneal injection of *T. polium* extract over 7 days led to the restoration of liver damage to a normal state (Panovska *et al*., 2007). Furthermore, liver morphology and histopathological findings corroborate the protective efficacy of this extract against liver damage induced by acetaminophen (Forouzandeh *et al*., 2013).

In a phytochemical investigation by Bahramikia and Yazdanparast (2012), extracts and isolated components from various parts of *T. polium* exhibited distinct biological effects, including antioxidant, antiseptic, anti-inflammatory, cytotoxic, antibacterial, antifungal properties and in vitro anthelminthic and anticoccidial activity (Al-Shaebi *et al*., 2023; Bahramikia and Yazdanparast, 2012).

The present study aimed to assess the anticoccidial activity and ameliorative effects of *T. polium* TPLEE extract against oxidative stress and histopathological changes in the liver of mice infected with *E. papillata*.

Materials and Methods

Between August 2023 and February 2024, this experiment was finished in the zoology department of King Saud University's College of Sciences. In this study, thirty-five adult Swiss albino male mice, aged between 8 to 10 weeks and weighing 30 to 35 g, were obtained from the animal house at the College of Science, King Saud University. The mice were housed in well-ventilated cages under specific pathogen-free conditions, with a controlled temperature of 23±5°C and a 12-hour light/12-hour dark cycle. Throughout the study, the animals were provided with standard pellet diets and tap water ad libitum. Before commencing the experiment, the mice were allowed a period of seven days for acclimatization.

In May 2022, *T. polium* leaves were gathered from Al-Badyah Tabuk, Saudi Arabia, situated at 27°45′59.5″N 36°31′48.8″E, approximately 80 km south of Tabuk. The plant's identification was confirmed by a specialist at the herbarium of the Botany Department, College of Science, King Saud University, Riyadh, Saudi Arabia. Following the method outlined by Qabaha *et al*. (2021) with some modifications, *T. polium* leaf extract was prepared. The leaves were air-dried and subsequently ground into a powder. This powder was then subjected to a cold maceration extraction technique using an ethanol (50%) solvent system for a duration of 24 hours. The ethanolic extract was filtered, concentrated using a rotary evaporator under pressure and at a temperature of 50°C and then collected and stored in sealed bottles at -20°C.

This study used the coccidian parasite, *E. papillata*, as a model parasite. *Eimeria* parasite oocysts were passaged in laboratory mice (*Mus musculus*). Unsporulated oocysts were collected from faeces and allowed to sporulate in a solution containing 2.5% (w/v) potassium dichromate. They were then washed in a phosphate buffer solution to prepare them for the remainder of the experiment. A preliminary study was done to determine the most effective dose of TPLEE (50, 150 and 250 mg/kg). Seven groups of five mice each were used (Table 1), as follows:

Groups (3-7) were orally inoculated with 100 µl of saline containing about 10^3 sporulated *E. papillata* oocysts. After 60 minutes of infection, groups 4, 5, 6 and 7 were treated for five succeeding days with the mentioned doses of TPLEE and amprolium, respectively (Table 1).

On the 5th day post-infection (p.i.), faecal pellets from each mouse in the 4 to 7 groups were collected. The total

number of shed oocysts was determined following the method described by Schito *et al*. (1996). Additionally, the suppression (%) of oocyst shedding was calculated using the formula:

$$\frac{\text{100- oocyst output in the treated group}}{\text{Oocyst output in the infected group}} \times 100$$

Subsequently, all mice were euthanized and their liver was harvested and preserved for use in the subsequent stages of the experiment.

Small pieces of liver tissue were extracted and immediately preserved in 10% neutral buffered formalin before being embedded in paraffin. Tissue sections, 5 μm thick, were then stained with hematoxylin and eosin to detect histopathological alteration. To show total carbs by the histochemical analysis, slices were stained using periodic Acid-Schiff's procedure (Hotchkiss, 1948).

The liver homogenate was prepared following the protocol outlined in Dkhil *et al*. (2012). The glutathione (GSH) level in the liver homogenate was determined according to Ellman (1959). During this process, GSH is decreased to produce a yellow molecule using Ellman's reagent (5,52 dithiobis (2-nitrobenzoic acid). When chromogen absorbance is measured at 405 nm, it is directly correlated with GSH content. Similarly, the amount of lipid peroxidation in the liver homogenate was determined by heating the liver homogenate to a boiling point for thirty minutes in a water bath and adding one milliliter of each of trichloroacetic acid (10%) and thiobarbituric acid (TBA) (0.67%). By measuring the absorbance at 535 nm, thiobarbituric acid-reactive molecules were identified and malondialdehyde (MDA) equivalents were used as a gauge Ohkawa *et al*. (1979). The NO assay on the liver homogenate was conducted in accordance with the protocol outlined by Berkels *et al*. (2004). When N-(1-naphthyl) ethylenediamine was mixed with sulfanilamide, it was oxidized by the nitrous acid that was created in an acidic medium with nitrite. This resulted in the appearance of a vivid reddish-purple azo dye. The resultant color was measured at 540 nm. The homogenate's superoxide dismutase (SOD) activity was measured using the Nishikimi *et al*. (1972) method. The success of the experiment depends on the enzyme's capacity to stop the nitroblue tetrazolium dye from being reduced by phenazine methosulphate, which is visible at 560 nm.

SPSS (version 20) statistical program (SPSS Inc., Chicago, IL, USA) was used to analyze our data by one-way analysis of variance (ANOVA) to statistical comparisons among the groups. Results were expressed as mean±SE and values of $p \leq 0.05$ were considered statistically significant.

Results and Discussion

Based on a preliminary study, treatment of infected mice with various doses of TPLEE demonstrated a notable suppression of oocyst output. Particularly, treatment with 150 mg/kg TPLEE exhibited a suppression percentage of 91.2±4.1, closely resembling the efficacy of the reference drug amprolium (93.2±3.9). However, the other two doses showed a significant decrease in efficacy (Table 2). Consequently, for subsequent investigations, the dose of 150 mg/kg was selected.

Experimental infection of mice with *E. papillata* oocysts led to the development of different parasite stages in the epithelial cells of the jejunum (Table 3). The treatment with 150 mg/kg TPLEE resulted in a significant reduction in the number of parasitic stages.

Microscopic analysis of eosin/hematoxylin-stained liver sections did not show any evidence of parasites (Fig 1). However, the liver exhibited moderate pathological alterations, including inflammatory injury, vacuolated hepatocytes and hyperplasia of Kupffer cells, when compared to the livers of non-infected mice.

In addition, staining of the liver tissue of mice infected with the parasite with periodic acid-Schiff revealed a reduced amount of carbohydrates compared to the control group (Fig 2). Infections with *E. papilata* resulted in a statistically significant ($P<0.05$) increase in NO and MDA levels in the liver of mice. TPLEE (150 mg/kg) treatment lowered the *E. papillata*-induced increase in the levels of both NO and MDA significantly (Fig 3 and 4).

Notably, the levels of GSH and SOD showed a significant ($P<0.01$) and ($P<0.001$) decrease as a result of infection with the parasite, reaching (143 ±14) and (67±10), respectively, compared to the control group, while treatment with the plant extract (150 mg/kg) led to a significant increase ($P<0.05$), reaching (175±10) and (96±9), respectively, compared to the infected and untreated group (Fig 5 and 6).

Table 1: Experimental design of the study.

Groups	Infection and treatment schedule
Negative control (Group 1)	Non-infected-non-treated
TPPE 150 mg/kg (Group 2)	Non- infected daily received oral administration of TPPE150 mg/kg for 5 days.
Positive control (Group 3)	(Infected-non-treated)orally inoculated with 100-µl saline containing about 10^3 sporulated *E. papillata* oocysts.
TPPE 50,150 and 200 mg/kg (Group 4,5 and 6)	Non- infected daily received oral administration of TPPE 50,150 and 200 mg/kg for 5 days respectively.
Infected+Amprolium 120 mg/kg (Group 7)	Infected and treated group with Amprolium (120 mg/kg body weight).

The liver serves as the initial site of interaction with the intestine *via* the portal vein. *E. papillata* typically targets the intestine, particularly the jejunum and normally does not invade the liver, though other lymphoid organs like the spleen and lymph nodes can be affected by related parasites such as *E. coecicola* (Renaux *et al*., 2001). Our study demonstrates that TPLEE effectively targets *Eimeria* parasites in the host. TPLEE exhibits significant anti-coccidial efficacy by markedly suppressing the percentage of oocysts and reducing the total number of parasite stages in the jejunum.

TPLEE's anticoccidial activity has been documented in coccidiosis. where is this effectiveness is likely due to its saponin component, known for its anti-coccidian properties. Saponins interact with cholesterol on the parasite cell membrane, impeding protozoan growth and ultimately leading to parasitic death (Al-Shaebi *et al*., 2023 and Al Sulaibi *et al*., 2020).

In the current study, *E. papillata* infections induce a mild inflammatory response in the hepatic tissue of mice, characterized by an increase in Kupffer cells and the abundance of leukocytes, particularly lymphocytes, as a typical tissue response to injury. Moreover, it's known that microbial and food antigens from the intestine can reach the liver through the hepatic portal system, triggering inflammatory and immune responses (Nagura and Sumi, 1988). The inflammation triggered by *E. papillata* prompts the activation and proliferation of numerous Kupffer cells (KCs). KCs, specialized macrophages located in the liver and integral to the mononuclear phagocyte system, demonstrate remarkable adaptability. They can alter both their morphology and function in response to shifts in the liver's microenvironment (Tacke and Zimmermann, 2014; Wynn and Vannella, 2016).

Previous studies demonstrated that the liver does respond strongly to *E. papillata* infections. Structural signs of moderate inflammation in the liver coincide with oxidative tissue damage (Dkhil *et al*., 2011b). Another species of *Eimeria, E. coecicola*, which targets the appendix part of the intestine in rabbits, also induces liver injury. Many rabbits

Table 2: Suppression rate of *E. papillata* oocysts in the infected, infected treated mice with 3 different doses of TPLEE as well as infected amprolium treated mice on day 5 p.i.

Groups	Oocysts suppression rate (%)
Infected	0
Infected+TPLEE 50 mg/kg	80.7±5.7***
Infected+TPLEE 150 mg/kg	91.2±4.1***
Infected+TPLEE 250 mg/kg	50.3±5.5***
Infected+Amprolium 120 mg/kg	93.2±3.9***

***Significant difference as compared with infected untreated ($P \leq 0.001$). All values are expressed as means±SD.

Table 3: Total parasitic stages in the jejunum of infected and treated mice (day 5 p.i.).

Groups	Total parasitic stages
Infected	20±2
Infected+TPLEE 150 mg/kg	6±2***
Infected+Amprolium 120 mg/kg	3±1***

***Significant difference as compared with infected untreated ($P \leq 0.001$). All values are expressed as means±SD.

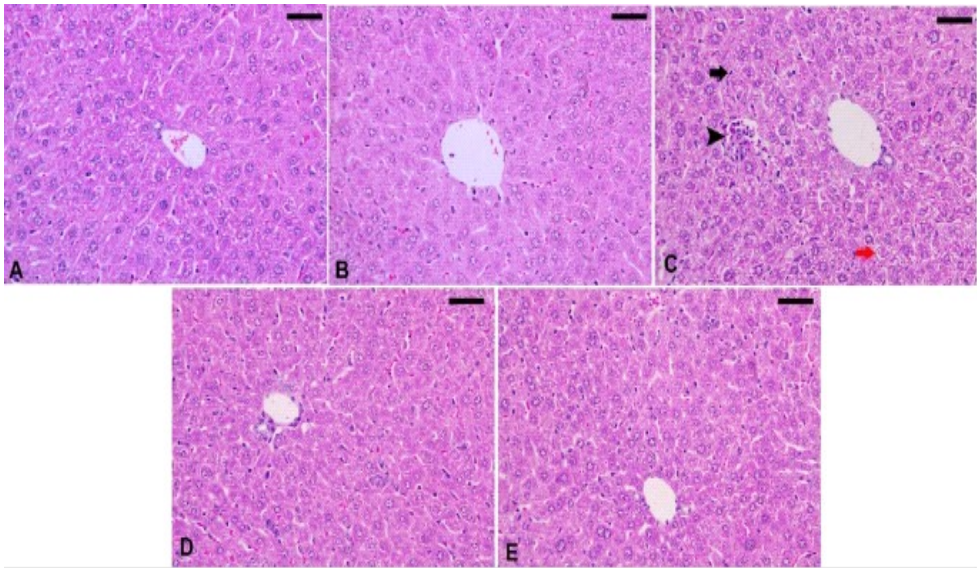

(A) non-infected group; (B) TPLEE (150 mg/kg) group; (C) infected group; the liver exhibited pathological alterations, such as inflammatory injury, vacuolated hepatocytes and hyperplasia of Kupffer cells; (D) infected+TPLEE (150 mg/kg); and (E) amprolium group. Scale bar = 50 µm.

Fig 1: Histological changes in liver tissue of mice during infection with *E. papillata* and after treatment with TPLEE.

exhibit several signs of moderate inflammation, including inflammatory cellular infiltrations around the central vein, dilated blood sinusoids, increased vacuolated hepatocytes and hypertrophic Kupffer cells (Al-Quraishy *et al*., 2012). TPLEE showed a hepatoprotective effect as it decreased signs of liver injury and restored the number of Kupffer cells. The ameliorative effects are attributed to its flavonoids and sterols, known for their anti-inflammatory properties (Çakılcıoğlu *et al*., 2010).

The breakdown of liver glycogen, the buildup of triglycerides in the liver and the mobilization of adipose tissue are among the metabolic consequences of inflammation

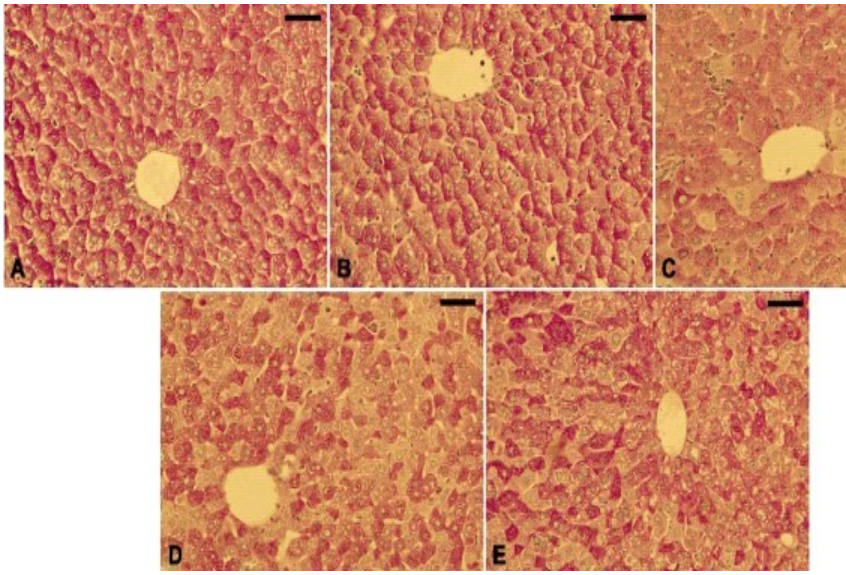

(A) non-infected group; (B) TPLEE (150 mg/kg) group; (C) infected group; (D) infected + TPLEE (150 mg/kg); and (E) amprolium group. Notes: (i) Reddish-purple hepatocytes containing carbohydrates. (ii) Periodic Schiff's method was used to dye the sections. Scale bars = 50 µm.

Fig 2: Total carbohydrates in liver sections.

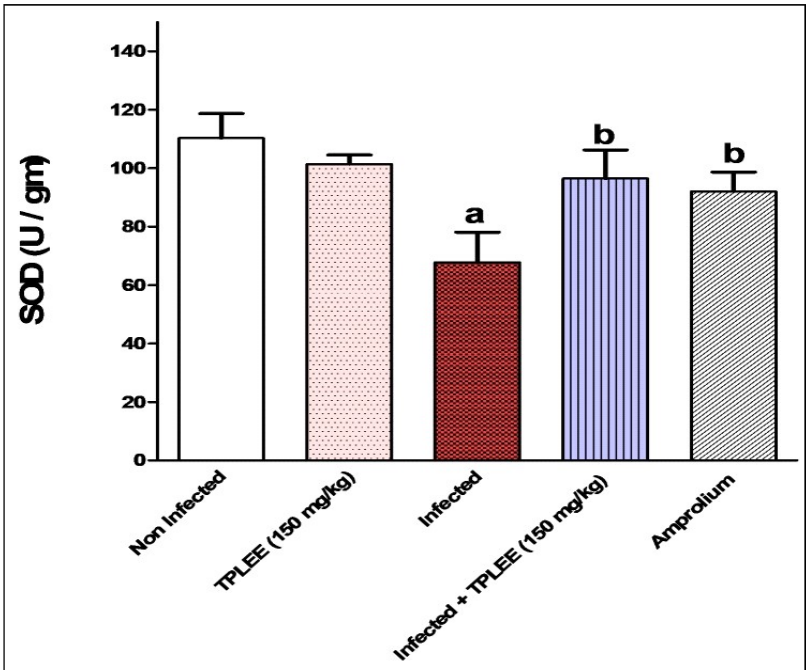

[a] indicates a significance against the control group with p< 0.001 and [b] indicates a significance against the infected group with p< 0.05. All values are expressed as means ± SD.

Fig 3: TPLEE elevated the amount of liver superoxide dismutase (SOD) in *E. papillata*-infected mice.

brought on by an *E. papillata* infection. More precisely, cytokines stimulate lipolysis directly, reduce feed intake and worsen insulin sensitivity to facilitate the breakdown of fat storage (Kushibiki *et al*., 2003). The low hepatocyte affinity for the periodic acid Schiff reaction (Fig 2) was indicative of this.

Our findings indicate that oxidative liver damage in mice infected with *E. papillata* infection is linked to a reduction in antioxidant enzymes like GSH and SOD and this is consistent with (Dkhil *et al*., 2012: Thagfan *et al*., 2023 and Al-Sayed *et al*., 2022), where is during an Eimeria infection, these enzymes are essential for shielding the

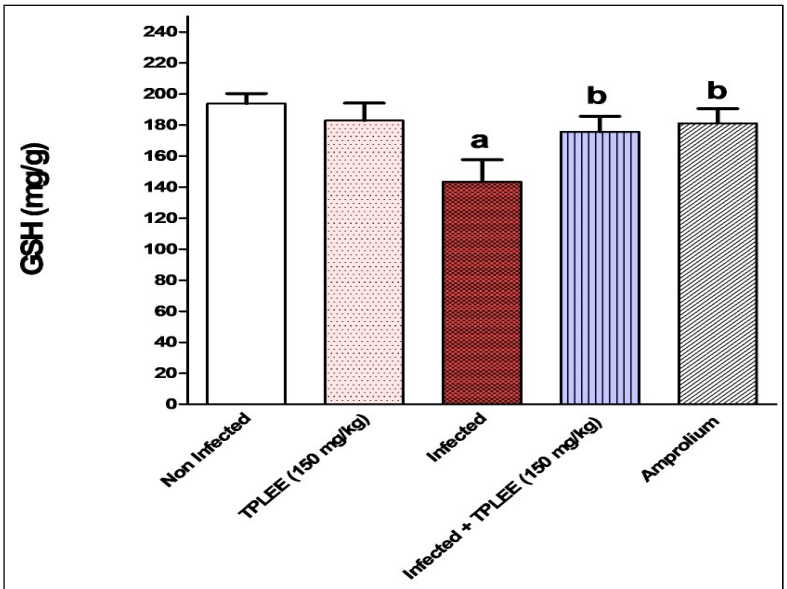

[a] indicates a significance against the control group with p<0.01 and [b] indicates a significance against the infected group with p<0.05. All values are expressed as means±SD.

Fig 4: Effect of *T. polium* leaves on the glutathione (GSH) level in mice infected with *E. papillata* infection.

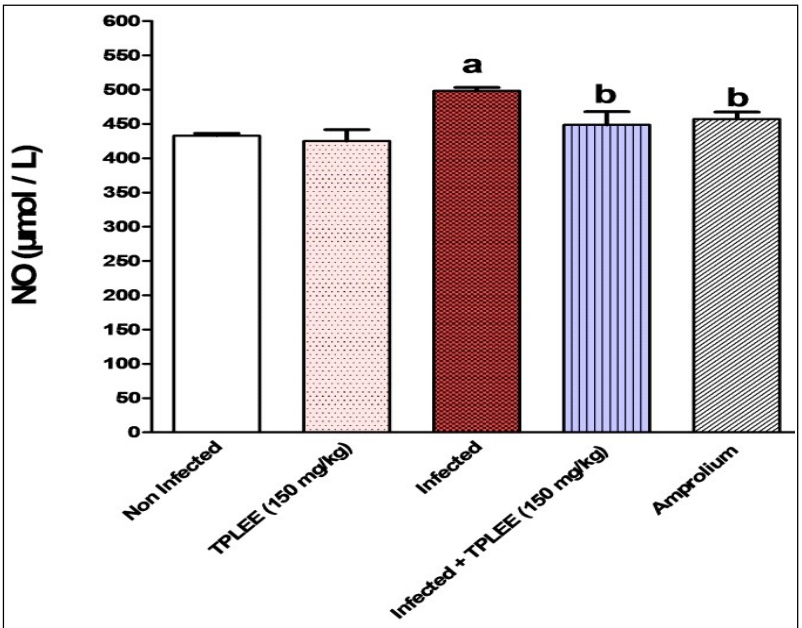

[a] indicates a significance against the control group with p<0.01 and [b] indicates a significance against the infected group with p<0.05. All values are expressed as means±SD.

Fig 5: *T. polium* leaves extract lowered liver nitric oxide (NO) levels in mice infected with *E. papillata*.

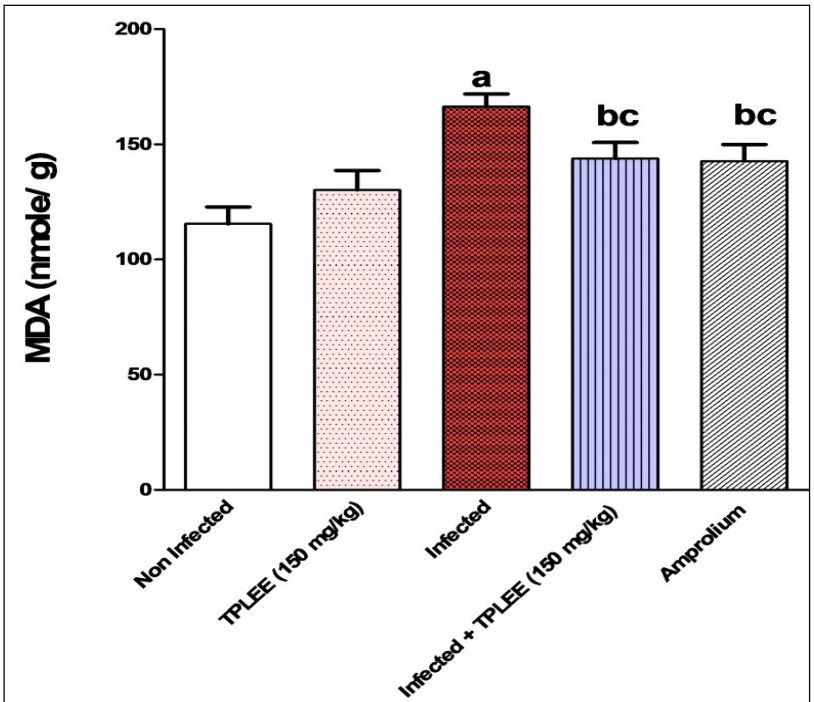

[a]indicates a significance against the control group with p<0.001 and [b, c] indicates a significance against the infected group with p< 0.05. All values are expressed as means±SD.

Fig 6: Malondialdehyde (MDA) levels in mice infected with *E. papillata* were enhanced by *T. polium* leaf extract.

animal body from free radical damage. When these enzyme levels drop, DNA and cellular membranes are harmed, lipid peroxidation is increased, protein oxidation is increased, intracellular stability is altered and cell death is induced. This irreversible damage is the result of an increase in reactive oxygen species.

In addition, the pathophysiology of intestinal coccidiosis was closely associated with nitric oxide (NO) and malondialdehyde (MDA), which were generated as a part of the host's cellular immune response to the *Eimeria* infection and this is consistent with Dkhil *et al*. (2012). Using TPLEE to treat *E. papillata*-infected mice resulted in a decrease in oxidative stress in the infected liver, which was corroborated by an increase in SOD and GSH levels and a reduction in MDA and NO. These results support the hypothesis presented by Ljubuncic *et al*. (2006) that *T. polium* is rich in flavonoids, which have anti-free radical properties and lead to protection against oxidative stress. Also, our current study's findings are consistent with a study by Alatawi *et al*. (2024) that found that TPE was effective as a natural antioxidant for reducing oxidative stress, enhancing antioxidant systems and stopping apoptosis in order to lessen nicotine's effects on hepatic biochemical and histological changes. Some studies have reported that medicinal plants treat liver damage in mice resulting from infection with *E. papillata*, such as garlic (Dkhil *et al*., 2011a); *Azadirachta indica* (Dkhil *et al*., 2012); and *Phoenix dactylifera* (Metwaly *et al*., 2012). According to Saleh *et al*. (2023) research, *Artemisia monosperma* leaves are a good natural source of strong antioxidants and medications that treat anthelminthiasis. which encourages the performance of multiple in vivo studies in quest of a successful cure. This makes these medicinal plants promising in curbing the damage caused by parasites.

Also, the study by Saleh *et al*. (2024) shown that TPLE has enhanced the behavioral performance of mice, which encourages the undertaking of several studies on the substances present in plants.

Our findings have proved that TPLE, at a dose of (150 mg/kg body weight), can protect mice against E. papillate infection. Moreover, the effect of TPLE comes from an increase in the intestinal levels of SOD and GSH, along with a decrease in NO and MDA. TPLE, once incorporated into an animal's regular diet, protects host tissue against impairments caused by a variety of pathogenic diseases. And although high doses of the plant had an effect, the most effective dose was 150 mg/kg.

CONCLUSION

The current study demonstrated that TPLEE exerted antioxidant properties and noteworthy anticoccidial activity against injuries induced by *E. papillata* in mice. The hepatoprotective effect was exerted mainly ability and enhancing the antioxidant defense system because of the high content of flavonoids and phenolics in the plant extract. improved histological structure of the liver

were further by TPLEE treatment from injuries induced by *E. papillata*.

ACKNOWLEDGEMENT

This work was supported by the Researchers Supporting Project (RSP2024R3) at King Saud University (Riyadh, Saudi Arabia).

Institutional review board statement

The animal study protocol was approved by the Institutional Review Board (or Ethics Committee) of Kingdom of Saudi Arabia (Ethics Committee, King Saud University, Ethics Agreement ID: KSU-SE-23-56).

Conflict of interest

The authors declare that there are no conflicts of interest.

REFERENCES

Abdel-Tawab, H., Abdel-Haleem, H.M., Abdel-Baki, A.A.S., Al-Quraishy, S., El-Mallah, A.M., (2020). Anticoccidial and antioxidant activities of *Moringa oleifera* leaf extract on murine intestinal eimeriosis. Acta Parasitologica. 65: 823-830.

Abdel-Tawab, H., Aboelhadid, S.M., El-Mallah, A.M., Abdel-Baki, A.-A.S., Al-Quraishy, S., Hassan, A.O., Yousef, E.A., (2024). Therapeutic efficacy of geranium-thymol combination against murine eimeriosis with reference to its apoptotic activity. Journal of King Saud University-Science. 36: 103043.

Abdollahi, M., Karimpour, H., Monsef-Esfehani, H.R., (2003). Antinociceptive effects of (*Teucrium polium* L.) total extract and essential oil in mouse writhing test. Pharmacological Research. 48: 31-35.

Aburjai, T., Hudaib, M., Cavrini, V., (2006). Composition of the essential oil from jordanian germander (*Teucrium polium* L.). Journal of Essential Oil Research. 18: 97-99.

Abbas, R.Z., Iqbal, Z., Blake,D.,Khan, M.N., Saleem, M.K. (2011). Anticoccidial drug resistance in fowl coccidia: The state of play revisited. World's. Poultry Science Journal. 67(2): 337-350.

Afaf Alatawi, Saud Alarifi, Esam M. Al-Shaebi, Saleh Al-Quraishy, Sarah A. Alawwad, Saleh N. Maoda, Jamaan S. Ajarem. (2024). Ameliorative effect of teucrium polium extract against nicotine induced liver toxicity in swiss albino mice. Indian Journal of Animal Research. 58(7): 1176-1186. doi: 10.18805/IJAR.BF-1743.

Akin, M., Oguz, D., Saracoglu, H., (2010). Antibacterial activity of essential oil from thymbra spicata var. spicata L. and *Teucrium polium* (Stapf Brig.). Interventions. 8: 53-58.

Al-Quraishy, S., Metwaly, M.S., Dkhil, M.A., Abdel-Baki, A.A.S., Wunderlich, F. (2012). Liver response of rabbits to *Eimeria coecicola* infections. Parasitology Research. 110: 901-911.

Al-Shaebi, E., Al-Quraishy, S., Abdel-Gaber, R., Maodaa, S., Alatawi, A., Alawwad, S., (2023). Efficacy of *Teucrium polium* leaves extract as anticoccidial and anthelmintic: *In vitro* study. Arquivo Brasileiro de Medicina Veterináriae Zootecnia. 75: 872-882.

Al Sulaibi, M.A., Thiemann, C., Thiemann, T. (2020). Chemical constituents and uses of calotropis procera and calotropis gigantea-a review (Part I-the plants as material and energy resources). Open Chemistry Journal. 7.

Al-Sayed, S.E., Abdel-Latif, M., Abdel-Haleem, H.M., El-Shahawy, G., Abdel-Tawab, H., (2022). Therapeutic effects of Hirudo medicinalis extract antigens on modulation of CD4+ CD25+ Foxp3 T cell activity in murine eimeriosis. Veterinary Parasitology. 309: 109772.

Ansari, M., Alizadeh, A., Paknejad, M., Khaniki, M., Naeimi, S., (2009). Effects of *Teucrium polium* honey on burn wound healing process. Journal of Babol University of Medical Sciences. 11: 7-12.

Bahramikia, S., Yazdanparast, R., (2012). Phytochemistry and medicinal properties of *Teucrium polium* L. (Lamiaceae). Phytotherapy Research. 26: 1581-1593.

Berkels, R., Purol-Schnabel, S., Roesen, R., (2004). Measurement of nitric oxide by reconversion of nitrate/nitrite to NO. Nitric Oxide Protocols. pp. 1-8.

Çakılcıoğlu, U., Şengün, M., Türkoğlu, İ. (2010). An ethnobotanical survey of medicinal plants of Yazıkonak and Yurtbaşı districts of Elazığ province, Turkey. Journal of Medicinal Plants Research. 4: 567-572.

Couladis, M., Tzakou, O., Verykokidou, E., Harvala, C., (2003). Screening of some Greek aromatic plants for antioxidant activity. Phytotherapy Research: An International Journal Devoted to Pharmacological and Toxicological Evaluation of Natural Product Derivatives. 17: 194-195.

Dkhil, M., Abdel-Baki, A., Wunderlich, F., Sies, H., Al-Quraishy, S., (2011a). Anticoccidial and antiinflammatory activity of garlic in murine *Eimeria papillata* infections. Veterinary Parasitology. 175: 66-72.

Dkhil, M., Abdel-Baki, A.A., Delić, D., Wunderlich, F., Sies, H., Al-Quraishy, S., (2011b). *Eimeria papillata*: Upregulation of specific miRNA-species in the mouse jejunum. Experimental parasitology. 127: 581-586.

Dkhil, M.A., Al-Quraishy, S. (2012). Metabolic disturbance and hepatic tissue damage induced by *Eimeria papillata* infection. African Zoology. 47: 255-260.

Dkhil, M.A., Moneim, A.A., Al-Quraishy, S., (2012). Antioxidant, hepatoprotective and ameliorative effects of *Azadirachta indica* on *Eimeria papillata*-induced infection in mice. Journal of Medicinal Plants Research. 6: 3640-3647.

Ellman, G.L., (1959). Tissue sulfhydryl groups. Archives of Biochemistry and Biophysics. 82: 70-77.

Forouzandeh, H., Azemi, M.E., Rashidi, I., Goudarzi, M., Kalantari, H. (2013). Study of the protective effect of *Teucrium polium* L. extract on acetaminophen-induced hepatotoxicity in mice. Iranian Journal of Pharmac Eutical Research: IJPR 12: 123-129.

Hotchkiss, R.D. (1948). A microchemical reaction resulting in the staining of polysaccharide structures in fixed tissue preparations. Archive of Biochemistry. 16: 131-141.

Panovska, T.K., Kulevanova, S., Gjorgoski, I., Bogdanova, M., Petrushevska, G., (2007). Hepatoprotective effect of the ethyl acetate extract of *Teucrium polium* L. against carbon tetrachloride-induced hepatic injury in rats. Acta Pharmaceutica. 57: 241-248.

Kareem, I.A., Hamza, N.M. (2022). Study of the biological efficacy of aqueous extract of T*eucrium Polium* on some histological parameters in male laboratory white rabbits of oryctolagus cuniculus. International Journal of Health Sciences. 6(S5): 7878-7889.

Kushibiki, S., Hodate, K., Shingu, H., Obara, Y., Touno, E., Shinoda, M. and Yokomizo, Y. (2003). Metabolic and lactational responses during recombinant bovine tumor necrosis factor-~ treatment in lactating cows. Journal of Dairy Science. 86: 819-827.

Mosaddeghi, P., Eslami, M., Farahmandnejad, M., Akhavein, M., Ranjbarfarrokhi, R., Khorraminejad-Shirazi, M., Shahabinezhad, F., Taghipour, M., Dorvash, M., Sakhteman, A., Zarshenas, M.M., Nezafat, N., Mobasheri,M.,Ghasemi,Y. (2021). A systems pharmacology approach to identify the autophagy-inducing effects of traditional persian medicinal plants. Scientific Reports. 11: 336.

Metwaly, M.S., Dkhil, M.A. and Al-Quraishy, S. (2012). Role of *Phoenix dactylifera* in ameliorating *Eimeria papillata*-induced hepatic injury in mice. Journal of Medicinal Plants Research. 6: 3041-3047.

Nagura, H., Sumi, Y. (1988). Immunological functions of the gut-role of the mucosal immune system. Toxicologic Pathology. 16: 154-164.

Nishikimi, M., Rao, N.A., Yagi, K., (1972). The occurrence of superoxide anion in the reaction of reduced phenazine methosulfate and molecular oxygen. Biochemical and Biophysical Research Communications. 46: 849-854.

Oganesyan, G., Galstyan, A., Mnatsakanyan, V., Shashkov, A., Agababyan, P. (1991). Phenylpropanoid glycosides of *Teucrium polium*. Chemistry of Natural Compounds. 27: 556-559.

Ohkawa, H., Ohishi, N., Yagi, K. (1979). Assay for lipid peroxides in animal tissues by thiobarbituric acid reaction. Analytical Biochemistry. 95: 351-358.

Qabaha, K., Hijawi, T., Mahamid, A., Mansour, H., Naeem, A., Abbadi, J., Al-Rimawi, F. (2021). Anti-inflammatory and antioxidant activities of *Teucrium polium* Leaf extract and its phenolic and flavonoids Content. Asian Journal of Chemistry. 33(4): 881-884.

Renaux, S., Drouet-Viard, F., Chanteloup, N.K., Le Vern, Y., Kerboeuf, D., Pakandl, M., Coudert, P., (2001). Tissues and cells involved in the invasion of the rabbit intestinal tract by sporozoites of eimeria coecicola. Parasitology Research. 87: 98-106.

Sidiropoulou, E., Skoufos, I., Marugan-Hernandez, V., Giannenas, I., Bonos, E., Aguiar-Martins, K., Lazari, D., Blake, D.P., Tzora, A., (2020). *In vitro* anticoccidial study of oregano and garlic essential oils and effects on growth performance, fecal oocyst output and intestinal microbiota *in vivo*. Frontiers in Veterinary Science. 7: 420.

Ljubuncic, P., Dakwar, S., Portnaya, I.; Cogan, U., Azaizeh, H., Bomzon, A., (2006). Aqueous extracts of *Teucrium polium* possess remarkable antioxidant activity *in vitro*. Evidence-based Complementary and Alternative Medicine. 3: 329-338.

Sohaib, M., Jamil, F. (2017). An insight of meat industry in pakistan with special reference to halal meat: A comprehensive review. Korean Journal for Food Science of Animal Resources. 37: 329-341.

Tacke, F., Zimmermann, H.W. (2014). Macrophage heterogeneity in liver injury and fibrosis. Journal of Hepatology. 60: 1090-1096.

Schito, M.L., Barta, J.R., Chobotar, B. (1996). Comparison of four murine Eimeria species in immunocompetent and immunodeficient mice. J. Parasitol. 82(2): 255-262.

Saleh, N.M., Rewaida, A.G., Afaf.A, Sarah, A.A., Saleh, Al-Q., Esam, M.A. (2023). Anthelmintic Activity of Artemisia monosperma Methanol Extracts against Eisenia fetida *in vitro* study. Indian Journal of Animal Research. 58(1): 115-121. doi: 10.18805/IJAR.BF-1705.

Saleh, M., Saleh, Al-Q., Rewaida, Ab., Afaf, A., Sarah, A., Dalal, A., Esam Al. (2024). Protective effects of teucrium polium leaves ethanolic extract against eimeria papillata-induced behavioral changes in mice. Indian Journal of Animal Research. 58(10): 1722-1732. doi: 10.18805/IJAR.BF-1802.

Thagfan, F.A., Dkhil, M.A., Al-Shaebi, E.M., Abdel-Gaber, R., Al-Quraishy, S., Elshanat, S. (2023). Biosynthesized nanosilver from ginger extract exhibits antioxidant and hepatic responses during *Eimeria papillata* Infection. ACS Omega. 8(26): 23806-23811.

Wunderlich, F., Al-Quraishy, S., Steinbrenner, H., Sies, H., Dkhil, M.A., (2014). Towards identifying novel anti-Eimeria agents: Trace elements, vitamins and plant-based natural products. Parasitology Research. 113: 3547-3556.

Wynn, T.A., Vannella, K.M., (2016). Macrophages in tissue repair, regeneration and fibrosis. Immunity. 44: 450-462.