RESEARCH ARTICLE Indian Journal of Animal Research, Volume 59 Issue 5: 755-760 (May 2025)

Protective Effects of *Ziziphus spina-christi* on Cadmium-induced Nephrotoxicity in Rats

Aiman A. Ammari[1], Ahmed R. Alhimaidi[1], Ramzi. A. Amran[1], Hossam M. Aljawdah[1], Mutee Murshed[1], Badr A. Aldahmash[1], Ahmed Rady[1]

10.18805/IJAR.BF-1854

ABSTRACT

Background: Cadmium is a common environmental toxin and its notable nephrotoxicity has been proven. In the kidneys. If picked up by such sources as unclean sewage or long-term pollution, this can become chronic exposure to cadmium. Through the use of contaminated food or water supplies and also industrial pollution with metals and aerosols that enter our rivers and lakes, it finds its way in there to an even greater extent still It accumulates mainly in the kidneys. As a medicinal plant rich in bioactive compounds, *Ziziphus spina-christi* was investigated for its possible protective effects against cadmium-induced kidney damage in rats.

Methods: The adult male and female Wistar albino rats were randomly divided in four groups: control group, *Ziziphus spina-christi* treatment (ZSC), ZSC treatment plus cadmium; the blood samples for serum analysis at end of treatment and kidney tissuesfor histological examination were from harvested at the end of the treatment period, blood samples were collected for serum analysis. Kidney tissue was obtained for histological examination. The range of biochemical parameters-creatine, blood urea nitrogen (BUN)and uric acid levels-were measured using diagnostic kits.

Result: Cadmium exposure actually decreased the rats' kidney weight and increased the levels of creatinine, uric acid and BUN in the male and female animals, indicating renal toxicity. This cadmium-fact pathology was apparently renal in nature and included glomerular and tubular necrosis as well vascular congestion. While treating rats with ZSC alone had no negative effect on their kidney function and did not cause any reduction in normalizes its weight or biochemical parameters, it did so when you administered cadmium rats them concurrently with. Those animals that had been treated with both cadmium and ZSC however showed a partial recovery in kidney weight, while the levels of serum creatinine, BUN and uric acid all fell significantly compared to those animals receiving only cadmium. Histologically speaking, the kidney damage exhibited by rats in the combination treatment category was less severe: their renal architecture more intact than in animals exposed solely to cadmium.

Key words: Cadmium, Inflammation, Nephrotoxicity, Oxidative stress, Renal protection, *Ziziphus spina-christi*.

INTRODUCTION

Cadmium, a pervasive environmental pollutant, is a recognized occupational hazard It can have some pretty nephrotoxic effects as well. Cadmium can be stored in the kidneys This accumulation of heavy metals means unfortunately when chronic exposure to cadmium is the result of contaminated food, water or industrial pursuits, renal dysfunction. It causes severe renal disease as it deposits in that vital organ. The kidneys are the epithelia of toxins and metabolism. With more than 99% to filter out once damage occurs there, kidney damage hastens that painful conclusion. Kidneys are most susceptible to its So it is that cadmium can attack the body's vital organs through different (Brzóska and Smereczański, 2023; Genchi *et al*., 2020).

Known as Sidr in Arabic, *Ziziphus spina-christi* is a medicinal plant with a history of traditional use in many cultures for various diseases. It is as well rich in bioactive compounds including flavonoids, saponins and tannins that also play accounts for some of its powerful antioxidant and anti-inflammatory capabilities. With these properties, *Ziziphus spina-christi* becomes a promising candidate for rescuing the harm cadmium does to kidney (Dhanalekshmi *et al*., 2022; Sabir and Alrasheid, 2024; Mostafa *et al*., 2023).

[1]Department of Zoology, College of Science, King Saud University, P.O. Box 2455, Riyadh 11451, Kingdom of Saudi Arabia.

Corresponding Author: Aiman A. Ammari, Department of Zoology, College of Science, King Saud University, P.O. Box 2455, Riyadh 11451, Kingdom of Saudi Arabia.
Email: aammari@ksu.edu.sa
ORCIDs: 0000-0002-1900-8446; 0000-0002-8608-334X; 0000-0002-8612-7576; 0000-0002-3675-1397; 0000-0003-3717-6424; 0000-0002-2989-5317; 0000-0001-5554-5858.

How to cite this article: Ammari, A.A., Alhimaidi, A.R., Amran, R. A., Aljawdah, H.M., Murshed, M., Aldahmash, B.A. and Rady, A. (2025). Protective Effects of *Ziziphus spina-christi* on Cadmium-induced Nephrotoxicity in Rats. Indian Journal of Animal Research. 59(5): 755-760. doi: 10.18805/IJAR.BF-1854.

Submitted: 06-08-2024 **Accepted:** 23-10-2024 **Online:** 12-12-2024

Ziziphus spina-christi used to be called Sidr. It is an old plant used in traditional medicine, *Ziziphus spina-christi*, is a rich resource for a wide variety of bioactive compounds, including flavonoids, saponins, tannins and alkaloids that have been shown through experimental studies to represent pharmacological activities such as antioxidation, anti-inflammation and cryoprotection (Hussein, 2019; Makhawi *et al*., 2020).

Cadmium produces oxygen, While Cells (Materials): Cadmium-generated hydrogen peroxide and other levels in the cell cause damage to proteins, lipids, nucleic acids and membrane structures basically. Then the cell gradually shows signs of senescence or cannot continue its function. (Apoptosis only applies if it hasn't reached an inevitable point yet.) This process is called necrosis. Toxic a Cells: With cadmium poisoning, the body releases sources of get oxidizing oxidation: more than 40 per cent for sheres proteins and more than 35 per cent for DNA. Unhealthy Environments: Cadmium-induced stress to cellular components produces free radicals. If these lyse cells, however, it gets called apoptosis rather than mere cell death on a massive scale. Inflammation It starts going when cadmium induced inflammation of the bladder inflammatory response sets off a number of cytokines that bring in other tissues drawn into area not originally. The inflammation like this brings more cells like white and red blood corpuscles-all with the same disease. This will further damage kidneys themselves. Oxidative Stress: Cadmium generates reactive oxygen species (ROS) that cause oxidative damage to cellular components, including lipids, proteinsand DNA. As a result, cells become dysfunctional or die off entirely. Inflammation happens in the same way it does during infections by bacteria. The molecule is massively stimulated to produce pro-inflammatory cytokines and mediators if it encounters cadmium (the amount of tissue destruction caused by one tiny particle alone can be amazing) This leads to chronic inflammation with more damage in kidneys nearby too. Anyway, it is clear that cadmium-induced inflammation brings about this state in which kidney and other functions are already damaged. Apoptosis and Necrosis: Cadmium induces programmed cell death (apoptosis) and uncontrolled cell death (necrosis), leading to the loss of functional renal cells and deterioration of kidney function.

Materials and Methods

Adult male and female Wistar albino rats, weighing between 200 and 250 grams, were sourced from the animal facility at the Zoology Department of the Science College, King Saud University (KSU). These rats were randomly assigned to polypropylene cages, with three rats per cageand were maintained under standard laboratory conditions. Before the start of the experiment, the rats underwent a one-week acclimatization period in a well-ventilated environment with a room temperature of 25±2°C and a regular 12-hour light/dark cycle. They were provided with a standard diet and had free access to water. All experimental procedures were conducted in accordance with the guidelines of the ethics committee and the Institutional Animal Care at KSU (Approval no: KSU-SE-23-6).

Twenty grams of *Ziziphus spina-christi* leaves were macerated in 200 ml of distilled water at 30°C while shaking at 150 rpm for 24 hours. The suspensions were filtered using Whatman filter paper and the residue was re-extracted and filtered again in the same manner. The two filtrates were combined and evaporated using a rotary evaporator at 40°C. The concentrated filtrate (water crude extract) was then weighed, re-dissolved in normal saline to a final concentration of 100 mg/kgand stored at -20°C until use (Ammari *et al*., 2023).

Twelve Wistar male and Twelve Wistar female rats, aged 8-10 weeks and weighing between 200 and 250 grams, were divided into four groups (n = 3 per group) as follows: Control Group (G1): Healthy, untreated rats. G2: Rats treated with 100 mg/kg body weight of *Ziziphus spina-christi* (ZSC). G3 (Cadmium Group): Rats administered 1 mg/kg body weight of cadmium. G4 (ZSC + Cadmium Group): Rats received 100 mg/kg of ZSC and 1 mg/kg of cadmium. Likewise for females the same groups. All treatments were given daily for a duration of 21 days.

At the end of the 21-day treatment period, all animals were fasted overnight before being euthanized by exsanguination. The rats were first anesthetized *via* an intraperitoneal injection of pentobarbital at a dose of 45 mg/kg body weight. Blood samples were then collected, incubated for 1 hour at 4°C and centrifuged at 3000 × g for 10 minutes to obtain serum. The kidneys from each rat were quickly removed, perfused with cold isotonic saline solutionand portions were fixed in a 10% formalin solution for histological examination.

The kidney enzymes from rat blood samples were analyzed to investigate the effects of cadmium and *Ziziphus spina-christi* extract. At the end of the experiment, blood samples from both female and male rats were collected in non-heparinized glass tubes for serum collection. The serum was then separated by centrifugation at 3000 rpm for 15 minutes. The enzymatic activities of Creatinine, Uric acidand BUN enzyme were measured using diagnostic kits with the BioSystem instrument BTS-350. Kidney samples from all treated and control rats were collected for histological analysis. Each rat was euthanized in a CO_2 chamber and the kidneys were extracted and preserved in 10% neutral formalin for 48 hours as small cube-sized samples (approximately 0.5 cm) for fixation. Subsequently, the kidney samples were dehydrated using an alcohol solution in a series of concentrations (30%, 50%, 70% and 100%).

Results and Discussion

Female Kidney - Cadmium exposure the renal architecture is disrupted. There is significant damage to the glomeruli and tubules, with evident signs of cellular necrosis and vacuolation. The image shows congestion in blood vessels with red blood cell aggregation. Group cadmium + *Ziziphus spina-christi* the renal architecture shows partial improvement compared to the cadmium exposure alone. The glomeruli and tubules are less damaged, with reduced signs of necrosis and vacuolation. Vascular congestion is also less pronounced the control group normal renal architecture is observed. Glomeruli and tubules are well-

defined with no signs of damage. Blood vessels are clear, with no signs of congestion or hemorrhage. And in group *Ziziphus spina-christi* the renal architecture is similar to the control group, indicating no adverse effects from the treatment. Glomeruli and tubules appear healthy and the blood vessels show no signs of congestion (Fig 1).

This detailed comparison and identification of pathological changes provide a clear understanding of the effects of cadmium and the protective role of *Ziziphus spina-christi* on female rat kidneys.

Male kidney-Cadmium group the renal architecture is disrupted. There is significant damage to the glomeruli and tubules, with evident signs of cellular necrosis and vacuolation. The image shows congestion in blood vessels with red blood cell aggregation.in group Cadmium + *Ziziphus spina-christi* the renal architecture shows partial improvement compared to the cadmium exposure alone.

The glomeruli and tubules are less damaged, with reduced signs of necrosis and vacuolation. Vascular congestion is also less pronounced compared with control group Control normal renal architecture is observed. Glomeruli and tubules are well-defined with no signs of damage. Blood vessels are clear, with no signs of congestion or hemorrhage and in group *Ziziphus spina-christi* the renal architecture is similar to the control group, indicating no adverse effects from the treatment. Glomeruli and tubules appear healthy and the blood vessels show no signs of congestion (Fig 2).

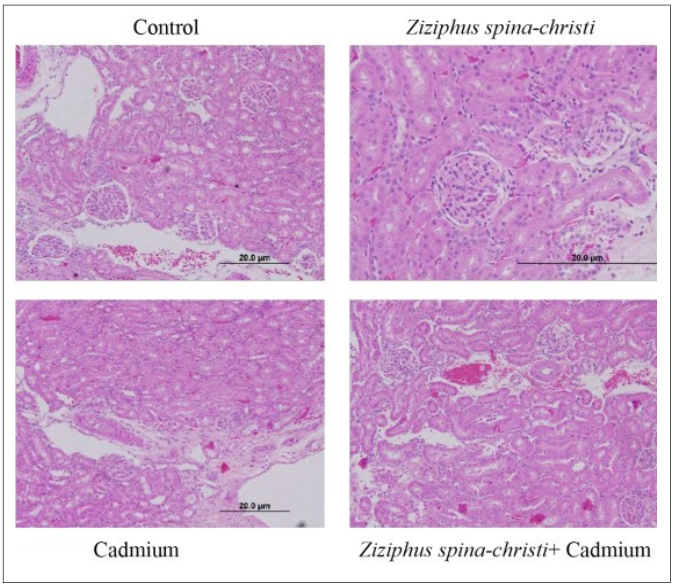

Fig 1: Histological analysis of kidney tissues in female rats: Effects of cadmium and *Ziziphus spina-christi.*

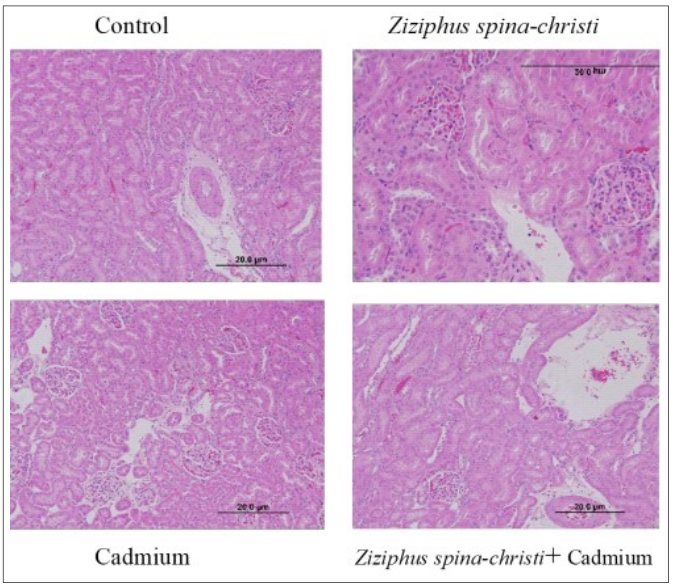

Fig 2: Histological analysis of kidney tissues in male rats: Effects of cadmium and *Ziziphus spina-christi.*

Ziziphus spina-christi shows a protective effect against cadmium-induced renal damage in male rats. This is evidenced by the reduced cellular and vascular changes in the kidney tissue when compared to cadmium exposure alone. The plant extract appears to mitigate oxidative stress and inflammation, preserving renal structure and function. Further studies are needed to fully understand the mechanisms behind these protective effects.

The histological analysis indicates that cadmium exposure induces more severe renal damage in female rats compared to males. However, treatment with *Ziziphus spina-christi* offers a protective effect against this damage in both sexes. Notably, females show a stronger protective response, suggesting potential sex-based differences in the efficacy of *Ziziphus spina-christi*. Further studies are needed to explore these differences and optimize treatment strategies.

The graph presents the kidney weights of male and female rats under four different experimental conditions: control, cadmium exposure, *Ziziphus spina-christi* extract treatment and combined cadmium and *Ziziphus spina-christi* extract treatment. The data are plotted with kidney weights (g) on the y-axis and the experimental groups on the x-axis (Fig 3).

In male rats, the control group exhibited the highest average kidney weight, approximately 2.4 grams. Exposure to cadmium resulted in a significant reduction in kidney weight, averaging around 1.8 grams, indicating potential nephrotoxicity induced by cadmium. Treatment with *Ziziphus spina-christi* extract alone resulted in kidney weights comparable to the control group, suggesting a protective or neutral effect on renal mass. Interestingly, the group treated with both cadmium and *Ziziphus spina-christi* extract showed a partial recovery in kidney weight, averaging around 2.0 grams, which suggests that *Ziziphus spina-christi* extract may mitigate some of the nephrotoxic effects of cadmium.

In female rats, the control group displayed kidney weights similar to their male counterparts, approximately 2.3 grams. Cadmium exposure led to a marked decrease in kidney weight, averaging around 1.7 grams, indicating a significant detrimental effect. The group treated with *Ziziphus spina-christi* extract alone showed kidney weights around 2.4 grams, slightly higher than the control group, suggesting a potential beneficial effect of the extract on kidney mass. The combined cadmium and *Ziziphus spina-christi* extract treatment group exhibited kidney weights around 2.1 grams, indicating a partial amelioration of cadmium's toxic effects by the extract (Fig 3).

Comparing the effects across sexes, both male and female rats exhibited similar trends in response to the treatments. Cadmium exposure universally resulted in reduced kidney weights, highlighting its nephrotoxic properties. *Ziziphus spina-christi* extract alone did not negatively impact kidney weights and appeared to offer some protection when combined with cadmium. This protective effect was slightly more pronounced in female rats (Fig 3).

Uric Acid Enzyme Levels in Male and Female Rats

The graph illustrates the uric acid enzyme levels (pg/ml) in male and female rats across four experimental conditions: control, cadmium exposure, *Ziziphus spina-christi* extract treatmentand combined cadmium and *Ziziphus spina-christi* extract treatment. The y-axis represents uric acid levels, while the x-axis differentiates the experimental groups (Fig 4).

In male rats, the control group exhibited the lowest uric acid levels, reflecting normal renal function. Cadmium exposure resulted in a marked increase in uric acid levels, indicating significant renal impairment and toxicity. The group treated with *Ziziphus spina-christi* extract alone showed uric acid levels comparable to the control group, suggesting the extract does not adversely affect kidney function. Notably, the combined treatment of cadmium and *Ziziphus spina-christi* extract led to a significant reduction in uric acid levels compared to the cadmium-only group, highlighting the extract's potential protective effect against cadmium-induced nephrotoxicity.

In female rats, the control group also showed the lowest uric acid levels, indicating normal kidney function. Cadmium exposure caused a significant elevation in uric acid levels, consistent with renal toxicity. The *Ziziphus spina-christi* extract

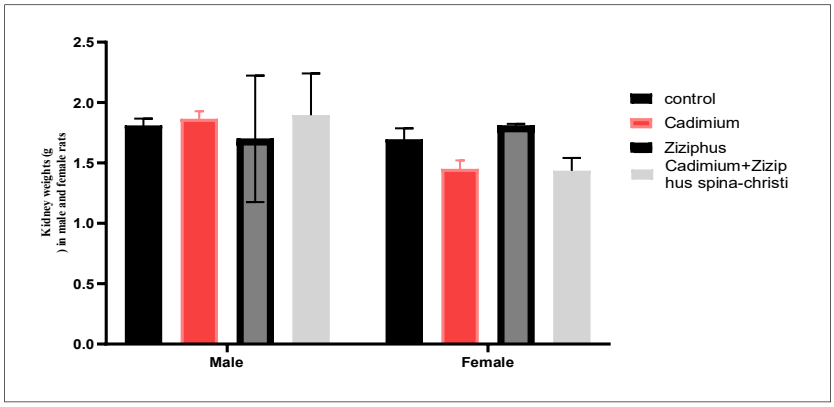

Fig 3: Effect of *Ziziphus spina-christi* extract on cadmium-induced changes in kidney weights in male and female rats.

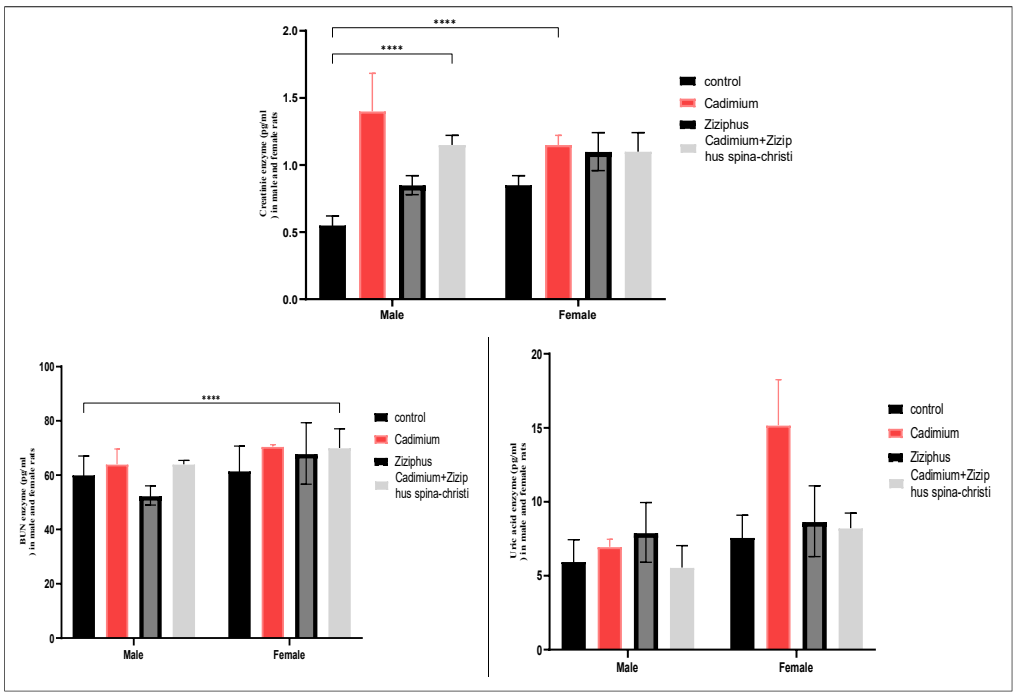

Fig 4: A comparative study of kidney enzymes and uric acid levels.

alone group maintained uric acid levels similar to the control, demonstrating its non-toxic effect on kidney function. The combined treatment of cadmium and *Ziziphus spina-christi* extract significantly lowered uric acid levels compared to the cadmium group alone, suggesting a protective effect of the extract against cadmium-induced renal damage.

Both male and female rats exhibited similar responses to the experimental treatments. Cadmium exposure consistently resulted in elevated uric acid levels in both sexes, underscoring its nephrotoxic effects. Conversely, *Ziziphus spina-christi* extract alone did not alter uric acid levels, indicating its safety and lack of adverse effects on renal function. The combined treatment significantly reduced uric acid levels compared to cadmium alone, demonstrating the extract's protective properties against cadmium-induced nephrotoxicity. The reduction in uric acid levels was significant in both sexes, indicating the broad-spectrum efficacy of the extract in renal protection (Fig 4).

The analysis of kidney weights in male and female rats under various treatments reveals significant insights into the nephrotoxic effects of cadmium and the protective potential of *Ziziphus spina-christi* extract.

In rats, the control group exhibited the highest kidney weights (approximately 2.4 grams), indicating normal renal health. Exposure to cadmium significantly reduced kidney weights to around 1.8 grams, suggesting severe nephrotoxicity. This finding aligns with previous studies indicating that cadmium exposure leads to renal damage by inducing oxidative stress and inflammation, which adversely affects kidney function and structure (Luo *et al.,* 2017; Wongmekiat *et al*., 2018). The group treated with *Ziziphus spina-christi* extract alone had kidney weights similar to the control group, indicating the extract does not negatively impact renal mass and may possess protective properties. The combination of cadmium and *Ziziphus spina-christi* extract resulted in partial recovery of kidney weights (around 2.0 grams), suggesting that the extract mitigates some nephrotoxic effects of cadmium.

The creatinine enzyme levels were significantly elevated in cadmium-exposed rats, both male and female, compared to control groups. This elevation indicates impaired renal function, as creatinine is a marker for kidney damage. The group treated with *Ziziphus spina-christi* extract alone had creatinine levels comparable to the control group, indicating the extract's non-toxic nature. The combined treatment of cadmium and *Ziziphus spina-christi* extract significantly reduced creatinine levels compared to the cadmium-only group, highlighting the extract's protective effect against cadmium-induced renal damage (Osukoya *et al*., 2021; Elkhadragy *et al*., 2018; Bhattacharya, 2018).

BUN levels followed a similar trend, with cadmium exposure causing a significant increase, indicative of renal impairment. *Ziziphus spina-christi* extract alone did not alter BUN levels significantly, while the combined treatment with cadmium resulted in a marked reduction in BUN levels. This suggests that *Ziziphus spina-christi* extract mitigates the nephrotoxic effects of cadmium, preserving renal.

Uric acid levels were elevated in cadmium-exposed rats, reflecting renal dysfunction. The group treated with *Ziziphus spina-christi* extract alone showed uric acid levels similar to the control, indicating no adverse effects on kidney function. The combined treatment with cadmium significantly lowered uric acid levels compared to cadmium exposure alone, further supporting the protective role of

Ziziphus spina-christi extract against cadmium-induced renal toxicity (Elkhadragy *et al.,* 2018; Poosa and Vanapatla, 2020).

Conclusion

The data indicates that cadmium exposure significantly decreases kidney weights and elevates creatinine, BUNand uric acid levels in both male and female rats, confirming its nephrotoxic effects. Conversely, *Ziziphus spina-christi* extract alone does not impact these parameters negatively and may protect against cadmium-induced nephrotoxicity. The combination of cadmium and *Ziziphus spina-christi* extract resulted in partial recovery of kidney weights and normalization of enzyme levels, suggesting the extract's potential therapeutic value in mitigating cadmium-induced renal damage. These findings warrant further investigation into the mechanisms of action and potential clinical applications of *Ziziphus spina-christi* extract in renal protection.

Acknowledgement

The authors sincerely acknowledge the Researcher Support Project (RSP-2024R232) for funding this work at King Saud University, Riyadh, Saudi Arabia.

Disclaimers

The views and conclusions expressed in this article are solely those of the authors and do not necessarily represent the views of their affiliated institutions. The authors are responsible for the accuracy and completeness of the information provided, but do not accept any liability for any direct or indirect losses resulting from the use of this content.

Informed consent

All animal procedures for experiments were approved by the Committee of Experimental Animal care and handling techniques were approved by the University of Animal Care Committee.

Conflict of interest

The authors declare that there are no conflicts of interest regarding the publication of this article. No funding or sponsorship influenced the design of the study, data collection, analysis, decision to publish, or preparation of the manuscript.

References

Ammari, A.A., Alhimaidi, A.R., Amran, R.A. and Rady, A.M. (2023). The possible side effects of *Ziziphus spina-christi* extract on the liver, kidneys of female rats. Indian Journal of Animal Research. 58(8): 1275-1279. doi: 10.18805/IJAR.BF-1768.

Bhattacharya, S. (2018). The role of medicinal plants and natural products in melioration of cadmium toxicity. Oriental Pharmacy and Experimental Medicine. 18(3): 177-186.

Dhanalekshmi, U.M., Khan, S.A., Alam, T. and Masoodi, M.H. (2022). An insight into the phytochemistry, traditional uses and pharmacology of *Ziziphus spina-christi* (L.) Willd.(Sidr): An edible wild Plant of Arabian Peninsula. In Edible Plants in Health and Diseases: Volume II: Phytochemical and Pharmacological Properties Singapore: Springer Singapore. pp. 43-93.

Elkhadragy, M.F., Al-Olayan, E.M., Al-Amiery, A.A. and Abdel Moneim, A.E. (2018). Protective effects of Fragaria ananassa extract against cadmium chloride-induced acute renal toxicity in rats. Biological Trace Element Research. 181. 378-387.

Genchi, G., Sinicropi, M.S., Lauria, G., Carocci, A. and Catalano, A. (2020). The effects of cadmium toxicity. International Journal of Environmental Research and Public Health. 17(11): 3782.

Hussein, A.S. (2019). Ziziphus spina-christi: Analysis of bioactivities and chemical composition. Wild Fruits: Composition, Nutritional Value and Products. pp. 175-197.

Luo, T., Liu, G., Long, M., Yang, J., Song, R., Wang, Y. and Liu, Z. (2017). Treatment of cadmium-induced renal oxidative damage in rats by administration of alpha-lipoic acid. Environmental Science and Pollution Research. 24: 1832-1844.

Makhawi, A.M., Mustafa, M.I. and Uagoub, H.A. (2020). Phytochemical screening and antimicrobial activity of *Ziziphus spina-christi* stem barks. BioRxiv. 2020-02.

Mostafa, M.A., Khojah, H.M. and Ohta, T. (2023). Isolation and identification of novel selective antitumor constituents, sidrin and sidroside, from *Zizyphus spina-christi*. Saudi Pharmaceutical Journal. 31(6): 1019-1028.

Osukoya, O.A., Oyinloye, B.E., Ajiboye, B.O., Olokode, K.A. and Adeola, H.A. (2021). Nephroprotective and anti-inflammatory potential of aqueous extract from *Persea americana* seeds against cadmium-induced nephrotoxicity in Wistar rats. Biometals. 34(5): 1141-1153.

Poosa, M. and Vanapatla, S.R. (2020). Protective effect of *Antigonon leptopus* (Hook et. Arn) in cadmium induced hepatotoxicity and nephrotoxicity in rats. Clinical Phytoscience. 6: 1-8.

Sabir, M.I.S. and Alrasheid, A.A. (2024). Comparative study of phytochemical analysis and anti-microbial activity of *Ziziphus spina-christi* L. leaves extracts from different areas in Sudan. doi: 10.20944/preprints202406.0466.v1.

Smereczański, N.M. and Brzóska, M.M. (2023). Current levels of environmental exposure to cadmium in industrialized countries as a risk factor for kidney damage in the general population: A comprehensive review of available data. International Journal of Molecular Sciences. 24(9): 8413.

Wongmekiat, O., Peerapanyasut, W. and Kobroob, A. (2018). Catechin supplementation prevents kidney damage in rats repeatedly exposed to cadmium through mitochondrial protection. Naunyn-Schmiedeberg's Archives of Pharmacology. 391: 385-394.