RESEARCH ARTICLE Indian Journal of Animal Research, Volume 59 Issue 2: 216-225 (February 2025)

The Impact of Argan Oil and Polyhexanide on Healing Wounds with Tissue Loss Infected by *Staphylococcus aureus* in Mice

Yusuf Kenan Dağlıoğlu[1], Selvinaz Yakan[2], Kıvılcım Eren Erdoğan[3], Fatih Köksal[4], Fazile Nur Ekinci Akdemir[5], İlhami Gülçin[6], Mustafa Gül[7], Suna Kızılyıldırım[8], Ruhay Aldık[9], Mehmet Öztan[10]

10.18805/IJAR.BF-1874

ABSTRACT

Background: One of the most important complications of the wound is tissue infection. One of the most common causes of tissue infections is microorganisms such as *Staphylococcus*. This research investigates the impact of argan oil and polyhexanide on the healing process in wounds with tissue loss infected with *Staphylococcus aureus* (*S. aureus*).

Methods: The study involved 45 male mice, with 10 mm skin incisions made on their backs under general anaesthesia to create wounds. After 24 hours, an *S. aureus* (ATCC) suspension was applied to the scars. Wound cultures were collected from each mouse 48 hours later and this was repeated every 48 hours until cultures confirmed *S. aureus* infection. Treatment commenced once *S. aureus* growth was detected. The mice were randomly assigned to three groups: A control group (wound created, but no treatment applied), an argan group (1 mL of argan oil administered to the wound via syringe) and a polyhexanide group (1 mL of polyhexanide administered similarly). The wound diameters and clinical symptoms were monitored daily. On the 7th and 14th days, tissue samples were taken from the sacrificed mice for histopathological examination.

Result: Based on clinical and histopathological observations, both argan oil and polyhexanide were found to be effective in treating *S. aureus*-infected wounds with tissue loss in mice. However, argan oil demonstrated a superior therapeutic potential compared to polyhexanide.

Key words: Argan, Mice, Polyhexanide, *Staphylococcus aureus*.

INTRODUCTION

The wound is defined as the deterioration of soft tissue integrity (Alkan, 1987). One of the most important complications of the wound is infection of the tissue, due to the colonization of pathogenic bacteria in cases of normal skin flora and skin integrity are disturbed. Microorganisms such as *Streptococcus* and *Staphylococcus* are responsible for most bacterial soft tissue infections (Citil *et al*., 2015). Bacterial infection of the wound is a complication that may delay wound healing and result in irreversible tissue loss (Gardner *et al*., 2001). In addition, wound infection increases the cost of health care seriously. Antibiotic therapy is used as a standard treatment for wound infection control. However, the usage of empirical antibiotics also causes drug resistance development over time (Gardner *et al*., 2001; Dealey *et al*., 2004). The reliability of antiseptics in wound treatment should be discussed because of their toxic effects (Asada *et al*., 2012).

This study aimed to use herbal compositions and antiseptics that reduce these toxic effects in infected wounds. Modern medicine also benefits from plants that have been used in traditional treatments for centuries. The usage of plants has been a guide in the development of many drugs. The chemical structure of their active compounds giving the medical properties of many plants has been determined, isolated, and synthetically produced and started to be used (Yildiz *et al*., 2015; Mohan and Kumar, 2018; Yavuz *et al*., 2022). It was reported that argan [(*Argonia spinosa* (L.) Skeels1911] oil grows naturally in Morocco (Marfil *et al*., 2011). Virgin argan oil is obtained by a cold-pressed technique (Charrouf and Guillaume, 2009). Interestingly,

[1]Department of Microbiology, Faculty, Kirşehir Ahi Evran University, of Medicine, Kirşehir-Türkiye.
[2]Department of Animal Health, Ağri Ibrahim Çeçen University, Eleşkirt Celal Oruç School of Animal Production, Ağri-Türkiye.
[3]Department of Pathology, Faculty of Medicine, Çukurova University, Adana-Türkiye.
[4]Department of Microbiology, Faculty of Medicine, Çukurova University, Adana-Türkiye.
[5]Department of Nutrition and Dietetics, Ağri Ibrahim Çeçen University, High School of Health, Ağri-Türkiye.
[6]Department of Biochemistry, Faculty of Science, Atatürk University, Erzurum-Türkiye.
[7]Department of Physiology, Faculty of Medicine, Atatürk University, Erzurum-Türkiye.
[8]Department of Pharmaceutical Microbiology, Faculty of Pharmacy, Çukurova University, Adana-Türkiye.
[9]Department of Fisheries Technology, Çanakkale Onsekiz Mart University, Çanakkale Academy of Applied Sciences Çanakkale-Türkiye.
[10]Department of Aesthetic, Private Clinic, Plastic and Reconstructive Surgery, Konya-Türkiye.

Corresponding Author: Selvinaz Yakan, Department of Animal Health, Ağri Ibrahim Çeçen University, Eleşkirt Celal Oruç School of Animal Production, Ağri-Türkiye. Email: syakan@gmail.com
ORCIDs: 0000-0003-3140-2937, 0000-0002-6274-9012, 0000-0002-4951-8703, 0000-0002-5921-3559, 0000-0001-9585-3169, 0000-0001-5993-1668, 0000-0002-0042-890X, 0000-0002-1039-8556, 0000-0001-5791-7491, 0000-0002-9157-3407.

How to cite this article: Dağlioğlu, Y.K., Yakan, S., Erdoğan, K.E., Köksal, F., Akdemir, F.N.E., Gülçin, I., Gül, M., Kızılyıldırım, S., Aldık, R. and Öztan, M. (2025). The Impact of Argan Oil and Polyhexanide on Healing Wounds with Tissue Loss Infected by *Staphylococcus Aureus* in Mice. Indian Journal of Animal Research. 59(2): 216-225. doi: 10.18805/IJAR.BF-1874.

Submitted: 21-08-2024 **Accepted:** 23-10-2024 **Online:** 18-12-2024

this oil's unsaponifiable fraction is notably abundant in antioxidant compounds like tocopherols, which are found in greater quantities than in olive oil (Morton and Voss, 1987; Khallouki *et al*., 2003). In addition, the therapeutic properties of the argan plant are based on anti-inflammatory and analgesic effects, and it also stimulates granulation and is used in wound healing since it supports tissue regeneration (El Babili *et al*., 2010; Avsar *et al*., 2016). One of these antiseptics polyhexanide (polyaminopropyl biguanide, polyhexamethylene biguanide, polyhexamethylene guanide), a modern wound antiseptic, is widely used to prevent bacterial infections and the treatment of mucous membranes and wounds (Horrocks, 2006; Valenzuela and Perucho, 2008; Hubner and Kramer, 2010). It is especially preferred in current treatments of chronic wounds, burn injuries and methicillin-resistant *Staphylococcus aureus* (*S. aureus*) (MRSA) infections (Kramer *et al*., 2004; Rietkotter *et al*., 2007). Even at very low concentrations (10 mg/L) it has bactericidal and fungicidal properties. It causes bacterial death by adhering to the cell wall of bacteria disrupting the membrane and reducing the permeability. It also adheres to the DNA of bacteria and creates deadly DNA damage (Allen *et al*., 2006). It has very low toxicity on human cells and has a broad spectrum against both gram-positive and gram-negative bacteria (Rosin *et al*., 2002). In a study that was conducted on the model of palate defects in rats; it was reported that the highest rate (87.61%) of decrease in defect size in the group that has been used polyhexanide solution compared to the control (Sahin *et al*., 2009). Valenzuela and Perucho reported that treatment of chronic skin wounds with 0.1% polyhexanide gel has made a significant reduction in wound size, an increase in granulation tissue, more decrease in bacterial biofilm level compared to the group of physiological saline (Valenzuela and Perucho, 2008).

In this research, our goal was to explore the effects of argan oil, a herbal drug commonly used in the treatment of various diseases and polyhexanide which is used as an antiseptic agent in modern medicine, in wounds infected with *S. aureus* in mice, which causes wound infections in hospitals that are difficult to treat.

MATERIALS AND METHODS

Chemicals and ethical approval

Argan oil and polyhexanide were purchased from commercial suppliers. Argan oil originates from the south of Morocco. Argan oil is derived from the hard kernel of the fruit by a conventional hand-pressing method and has been used without any prior processing. It is kept in a brown bottle at room temperature to protect it from light. Commercial preparation of polyhexanide was bought and used (Actolind W solution Acto CmbH). Our research was conducted at Çukurova University Health Sciences Experimental Application and Research Center between May and August 2018, after receiving the approval of the Çukurova University Experimental Animals Local Ethics Committee (approval number: 2018-01/05). In our study, 45 albino male BALB/c mice aged 3-4 weeks, weighing 25±5 g, were used. All animals were housed in room conditions to provide standard environmental conditions, and fed with standard food and tap water.

Application of experimental protocol

General anaesthesia was induced by intramuscular administration of a mixture of 50 mg/kg ketamine (Ketalar®) and 10 mg/kg xylazine hydrochloride (Alfazyne®, 2%) in mice. The operation areas of animals were shaved under deep anaesthesia. After the cleaning and disinfection of the wound area, the model described by Park *et al*. (2012) was applied as an experimental wound model. The dorsal skin of the mouse was picked up at the midline and punched through two layers of skin (10 mm in diameter and 1-2 mm deep). After surgery, mice received carprofen (Adamson *et al*., 2010), 5 mg/kg dose subcutaneously every day for 14 days for analgesia during all of the experimental procedures.

Preparation of infection strains

The type strain ATCC 25923 of *S. aureus* was cultured on trypticase soy agar plates containing 5% sheep blood by swap. Cultur plates were incubated for 48 h at 37°C under aerobic conditions. After the isolation of pure cultures, identiûcation of *S. aureus* was performed based on enzymatic activity by catalase and plasma coagulase tests after microscopic examination. A loopful of bacteria was collected on agar plates transferred to 10 mL of nutrient broth and incubated at 37°C for 15-18 h to replicate the organisms. After this incubation period, to be used to create experimental wound infection, bacterial cell concentration was adjusted to Mc Farland 0.5 turbidity equal to 1.5×10^8 cfu/ml at 590 nm using a UV/vis spectrophotometer. The prepared bacteria suspension was transferred to the surface of the wounds received with a swap to create an infection.

SmaI-PFGE

All *S. aureus* (ATCC-25923) strains cultured on TSA and identified by biochemical properties were used for PFGE. The chromosomal DNA had been extracted similarly to the standard protocol described by Mulvey *et al*. (2001). Electrophoresis was done with a contour-clamped homogeneous electric field (CHEFDRII; Bio-Rad Laboratories, Nazareth, Belgium). PFGE-generated DNA fingerprints were digitized and analyzed with the GelCompar II software system (version 5.0; Applied Maths, Sint-Martens Latem, Belgium) only 3 clusters were classified by using 95% similarity as a cutoff. This result has shown us that the strains isolated from wounds were the same strain as the test strain used to create an infection.

The planning of the experimental groups

After waiting for a day, to reduce the mortality, a suspension of *S. aureus* (ATCC) isolated in the microbiology laboratory of the Faculty of Medicine, University of Çukurova was inoculated to wounds on the back of the mice. Inoculation

as defined by Calame *et al*. (1991); a suspension bacteria 2×10^8 cfu/ml was administered subcutaneously as 100 µl. The wound was moistened with 0.9% saline and the operation terminated later and the mice were left to awaken from the anaesthesia. After 48 hours, wound dressings were opened and a touching sample of the wound for culturing was taken from each rat, then it was platted in the EMB agar in the microbiology laboratory of the Faculty of Medicine, University of Çukurova. This process was repeated every 48 hours until culturing of the *S. aureus* was achieved. Treatment of mice was started by our drug treatment every 24 hours when *S. aureus* was detected in culture. Mice were separated from each group before the treatment was started. Mice were sacrificed by applying a high-dose anaesthetic agent at the end of the experiment. The wound was also examined to reveal histopathologic findings of the infection in the wound area of mice.

Control group (n=14): An open ulcerative wound on the back of the mice was created. No drug was administered to mice in this group and during the experimental period of 14 days, the natural healing process in the wound area was observed.

Argan oil group (n=14): Open ulcerative wounds on the back of the mice were created and after 24 hours, a suspension of *S. aureus* was inoculated. After the infection was established, the treatment was started. 1 mL of argan oil (2 mg/kg dose) was applied daily via a syringe on the wound area. During the experimental period of 14 days, the process in the wound area was monitored.

Polyhexanide group (n=14): Open ulcerative wounds on the back of the mice were created and after 24 hours, a suspension of *S. aureus* was inoculated. 1 mL of polyhexanide (2 mg/kg) was applied daily via a syringe on the wound area. During 14 days of the experimental period, the process in the wound area was monitored.

It continued to receive wound swab cultures every 48 hours from all mice in the groups. In the same way, the wound diameters were measured and photographed. The progress of infection with cultures, wound diameter measurements and changes in wound healing were observed.

Wound size measurement

The change in wound size was measured and the wound was evaluated as macroscopically. Wound size was measured as 10 mm on the 1st day of wound creation. *S. aureus* (ATCC) was inoculated twice with intervals of 24 and 48 hours on the wound area after 5 days from wound formation. The wound size was measured on the very first day of the infection.

Histopathological evaluation

Seven mice from each group on the 7th day of drug treatment were sacrificed. Afterward, on the 14th day of drug application, the remaining mice in the groups were sacrificed with a high-dose of anaesthetic agent. The wound areas of mice were sampled. Macroscopically the tissues were sectioned in 2 mm thickness. Formaline fixed paraffin-embedded blocks were serially sectioned at 5 µm. Routine hematoxylin-eosin (H and E) stained slides were examined for ulceration, inflammation, reepithelization, collagen accumulation, tissue granulation, and angiogenesis in the wound area by light microscopy.

Statistical analysis

One-way ANOVA was used for statistical analysis, followed by Tukey's HSD for multiple comparisons. A p-value of less than 0.05 was considered statistically significant. The data are reported as mean ± standard error of the mean (SEM).

Results and Discussion

Wound size measurement and examination

Changes in wound size in all groups are shown in Fig 1. The change in wound size was measured and the wound was evaluated macroscopically. Wound size was measured as 10 mm on the 1st day of wound creation. *S. aureus* (ATCC) was inoculated twice with 24 and 48-hour intervals on the wound area after 1 day of wound formation. The wound size was measured on the first day of the infection. No statistically significant difference was observed in wound size among the groups on the first day of the infection (5 days of wound creation) ($P>0.05$). Treatment was started immediately after the microorganism was determined in microbiological culture (after two infections). The wound healing was more effective in the treatment groups compared to the control group at the 7th and 14th days of treatment ($P<0.001$). The wound healing rate was found to be faster in the argan oil group compared to the polyhexanide group when the two treatment groups were compared ($P<0.05$), (Fig 1).

Histopathological results

The parameters of the histopathological lesions and the evaluation of the healing are shown in Table 1. It was inoculated with a suspension of *S. aureus* (ATCC) on the wound area of all mice before leaving the groups. After two times of inoculations, the infection and strain isolated from the wound were the same as shown with PFGE in collected pretreatment samples. In all mice, intense inflammatory cells were observed in histopathological examination (Fig 2). On the 7th day of drug administration, the formation of re-epithelization was higher in the treatment groups compared to the control group (Fig 3). On the 7th day of the application of argan oil, intense collagen formation in the dermis is observed and re-epithelization is completed in the histopathological examinations of sections. Granulation tissue and angiogenesis levels were higher than the polyhexanide group (Fig 3A, B). Histopathologic examinations of the polyhexanide group revealed that the surface epithelium was completed and granulation tissue and angiogenesis levels were higher than the control group (Fig 3C, D). On the 7th day of the drug application, in the histopathologic examination of the sections of the control group appeared that the surface epithelium was not

complete. There was no difference in collagen accumulation in the histopathological sections of the three groups (Fig 3E, F). On the 14th day of drug application, it was revealed that surface epithelialization was completed and collagen accumulation was high in both groups in the histopathologic examination of sections of argan oil and polyhexanide groups. The granulation texture and angiogenesis formation (Fig 4) were higher in the group

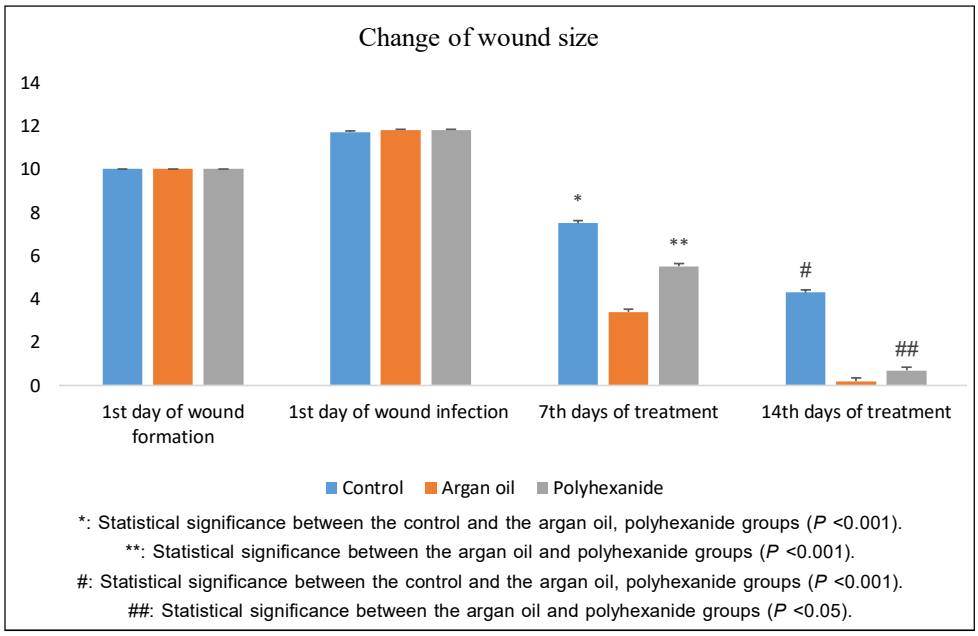

Fig 1: Changes of wound size at days 1st of wound, 1st of infection and 7th and 14th days of treatment in all groups.

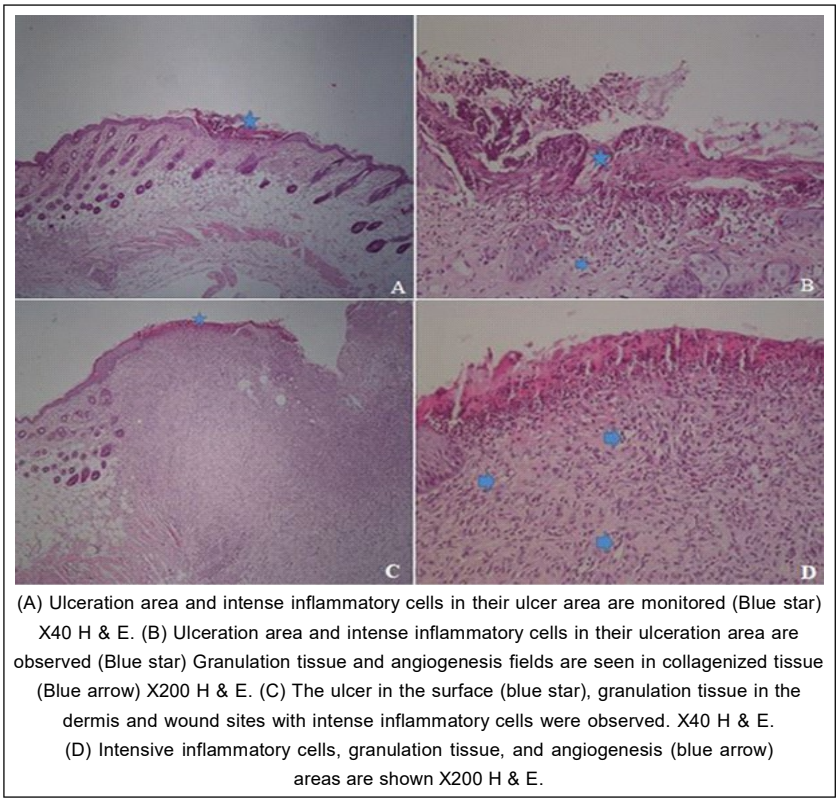

Fig 2: Histopathological view of a tissue section of a rat at 5th days (after two infections) of inoculation with *S. aureus* (ATCC) suspension.

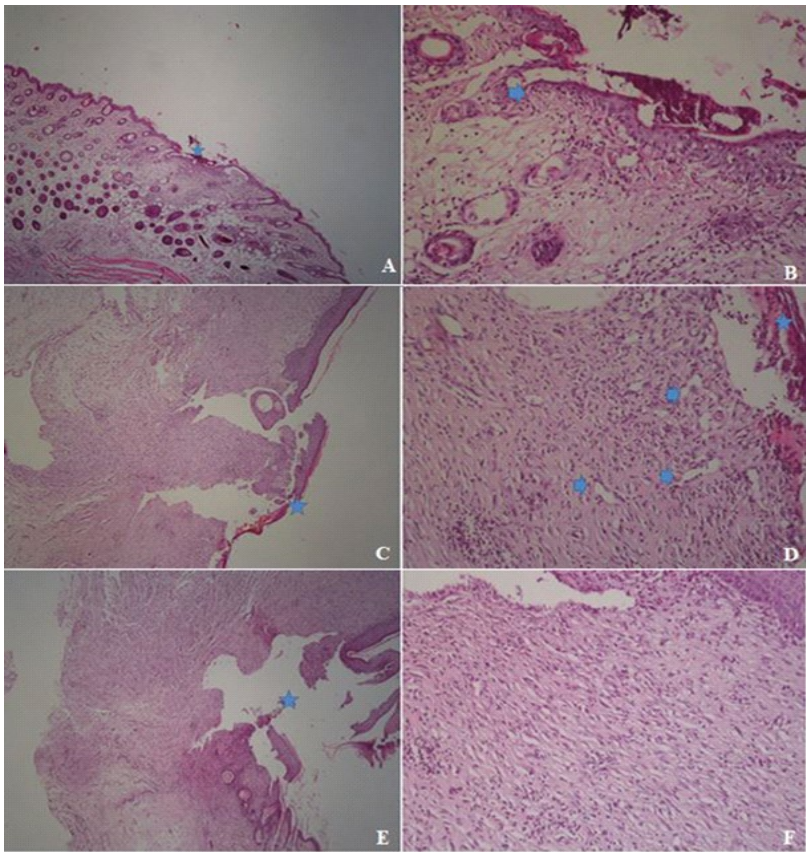

(A) A section of the group applied argan oil is seen. The crust layer on the surface and wound site appeared that completed epithelization (blue star) X40 H and E. (B) Reepithelization has occurred (blue arrow), and edematous tissue rich from inflammatory cells is monitored. X200 H and E. (C) A section of the polyhexanide group is seen. The integrity of the surface epithelium is disturbed occasionally, the granulation tissue in the dermis and angiogenesis is observed in wound site. X40 H and E. (D) It is seen that the crust layer of ulceration and inflammation cells on the wound surface, inflammatory cells in the dermis, angiogenesis (blue arrow), and granulation tissue. X200 H and E. (E) A cross-section of the control group is observed. A wound site rich in collagen in the dermis is seen uncontained surface (blue star). X40 H and E. (F) Intensive inflammation cells and tissue rich from the collagen are monitored under the surface epithelium. X200 H and E.

Fig 3: At day 7th of treatment, sections of groups are seen.

Table 1: All groups' histopathologic parameters of wound healing at the 7th and 14th days of drug application.

Histopathological parameters	Control group (Untreated group)		Argan oil group		Polyhexanide group	
	Days		Days		Days	
	7th	14th	7th	14th	7th	14th
Ulceration	+	+	+	-	+	-
Inflammation	+++	++	++	-	++	+
Reepithelization	-	+	++	+++	++	++
Collagen accumulation	+++	+++	+++	+++	+++	+++
Granulation tissue	+	+	++	+++	++	++
Angiogenesis	+	+	++	+++	+++	+++

Ulceration (presence +, absence -), inflammation (absence -, mild +, moderate ++, intense +++), reepithelization (absence -, mild +, moderate ++, intense +++), collagen accumulation (absence -, mild +, moderate ++, intense +++), granulation tissue (absence -, mild +, moderate ++, intense +++), angiogenesis (absence -, mild +, moderate ++, intense +++).

treated with argan oil according to the Polyhexanide group (Fig 5). On the 14th day of drug application, epithelization was not completed in the histopathological examination of the wound sections of the control group. Collagen accumulation was at the same level as the treatment groups (Fig 6).

Wound is defined as disruption of tissue integrity, which includes trauma, insect bites, burns, surgery, vaccinations, skin piercing, acne, and infections (Gauglitz *et al*., 2011). Wound healing is a dynamic and complex process that can be complicated by microorganisms and inflammatory components. It consists from three phases: inflammation, re-epithelization-granulation, matrix formation-tissue formation (Sahin *et al*., 2009). One of the most important complications that delay wound healing in the inflammatory phase is wound infection (Gardner *et al*., 2001). Antibiotic therapy is used as a standard control of wound infection. However, by time excessive use of antibiotics leads to the development of drug resistance. Reliability should be discussed because of the toxic effects of existing antiseptics (Asada *et al*., 2012; Shukla *et al*., 2022). We also aimed to use herbal compositions and antiseptics with less toxic effects in infected wounds. In wounds with tissue loss, the wound area is regenerated by primary or secondary wound healing. If the gap between the two wound lips is too wide to be approached, the healing of the wounds happens with secondary healing. First, a clot forms after the bleeding in the wound area, and the ulcer area is filled with granulation tissue. In this stage, acute inflammatory reaction, reepithelialization and angiogenesis occur in the wound site. On the surface of the wound, while epithelial mitosis and migration occur, the granulation tissue underneath proliferates. This granulation tissue until it reaches the surface, the epithelial cells at the wound edges can not

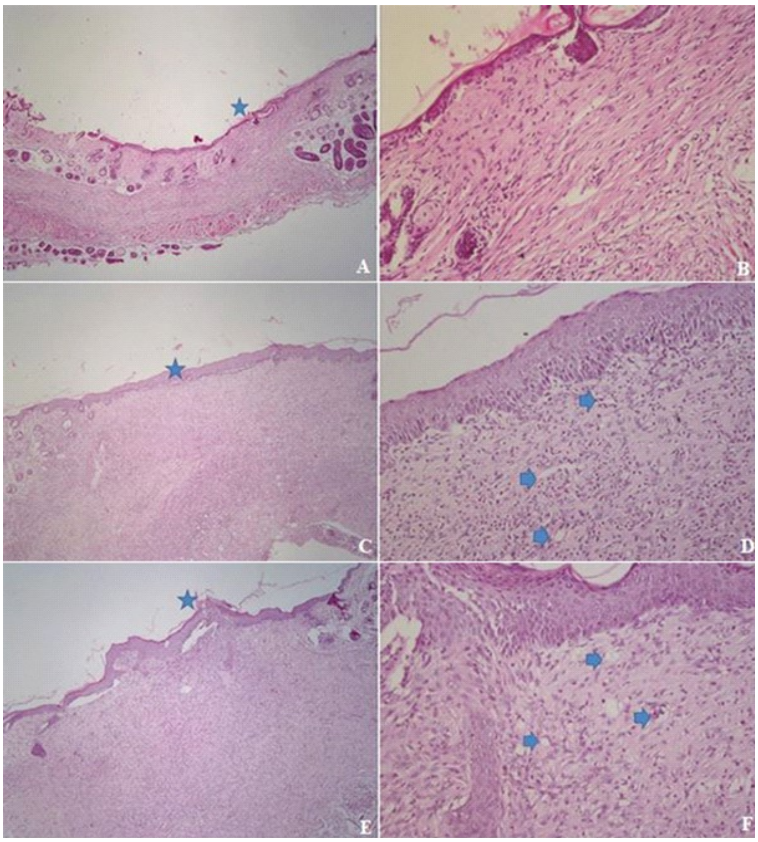

(A) Surface epithelization was completed (blue star) and areas rich in collagen in the dermis showed. X40 H and E. (B) The surface epithelialization is completed and the areas rich in collagen in the dermis are seen. X200 H and E. (C) Surface epithelialization was completed (blue star) and areas rich in collagen in the dermis showed. X40 H and E. (D) Intensive inflammatory cells, granulation tissue, and areas of angiogenesis (blue arrows) are observed. X200 H and E. (E) The surface epithelialization was completed (blue star), and the wound site showing intense inflammatory cells in the dermis is observed X40 H and E. (F) Granulation tissue and areas of angiogenesis (blue arrow) are observed. X200 H and E.

Fig 4: A cross-section of the argan oil group on the 14th day of treatment is seen.

completely cover the wound surface. As a result of the contraction of the fibroblasts formed within granulation tissue, wound contraction is shaped and closure of the ulcer is provided (Sahin *et al*., 2009).

We have tried to determine the effect of argan oil on the rate of healing of infected wounds with tissue loss in our study which we have experimentally formed. Argan oil has been shown to provide powerful antioxidant, antithrombotic, and antidiabetic effects (Cherki *et al*., 2005; Samane *et al*., 2009; Mekhfi *et al*., 2012). Because it has antioxidant properties, it is protective against damage caused by free radicals (El Babili *et al*., 2010). Avsar and colleagues reported that in their studies evaluating the effect of argan oil in the treatment of second-degree burns, argan oil had an anti-inflammatory effect and epithelial regeneration was higher in the argan oil group compared to silver sulfadiazine (Avsar *et al*., 2016). In our study, the closure of the ulcer occurred in a shorter time in the group that applied argan oil according to the macroscopic findings. Histolophatological findings in the sections of this group

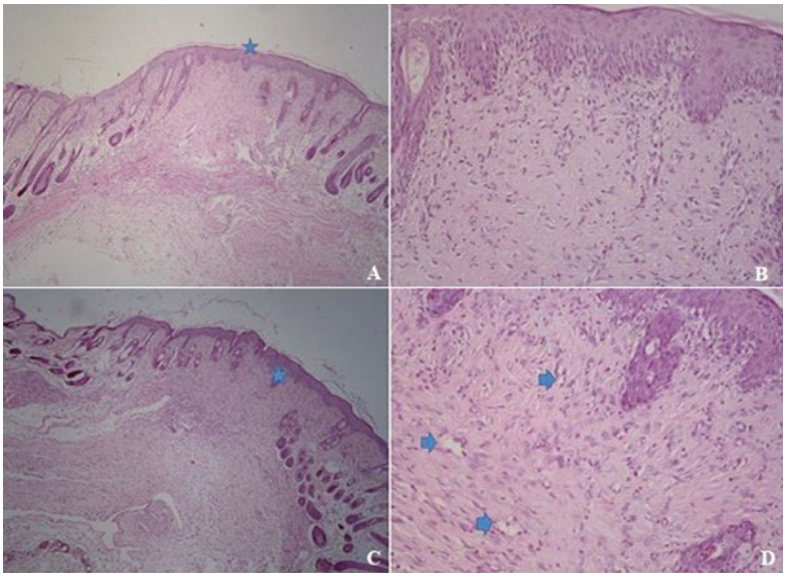

(A) The surface epithelium is full (blue star), wound site is rich in collagen in the dermis X40 H and E. (B) The granulation tissue is observed under the surface epithelial. X200 H and E. (C) A wound site showed that completed epithelization (blue star) followed an increase in collagen in the dermis. X40 H and E. (D) Granulation tissue and areas of angiogenesis (blue arrow) are observed. X200 H and E.

Fig 5: A cross-section of the group applied polyhexanide at the 14th day of treatment is seen.

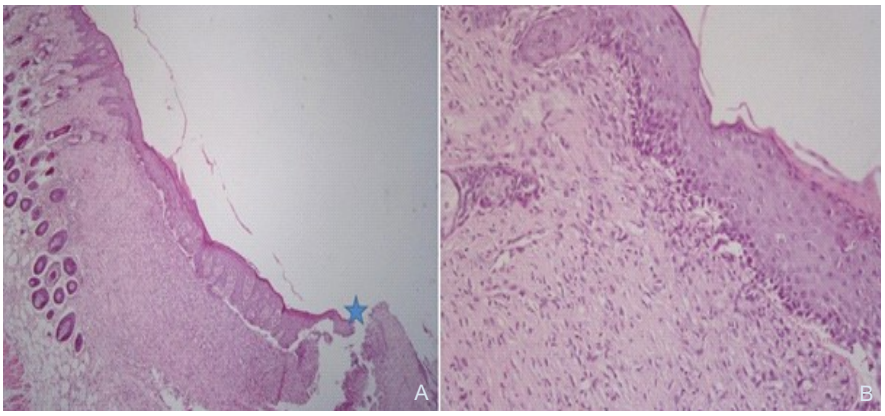

(A) Surface integrity not observed (blue star), wound area rich from collagen in the dermis is seen X40 H and E. (B) The granulation tissue is observed under the surface epithelial. X200 H and E.

Fig 6: A cross-section of the control group at day 14th of treatment showed.

supported macroscopic data. It was monitored that from the third day on granulation tissue started to occur and an increase in the following days continued. It is determined that declined over time of epithelial opening surrounding the wound surface. We aimed both to accelerate wound healing and to the treatment of infection by using together argan oil and polyhexanide.

One of these antiseptics, polyhexanide (polyhexamethylene biguanide), is a biguanide derivative that has a broad spectrum with bactericidal and fungicidal effects in wound healing. The spectrum of action includes microorganisms such as *Staphylococcus Enterococcus*, *Pseudomonas aeruginosa* and *Escherichia coli*. Polyhexanide does not adversely affect the formation of granulation tissue and therefore wound healing is not difficult. Since polyhexanide interacts with neutral phospholipids very little, it does not cause toxic effects on human cells (Rosin *et al*., 2002; Kramer *et al*., 2004; Allen *et al*., 2006; Horrocks, 2006; Rietkotter *et al*., 2007; Valenzuela and Perucho, 2008). In an experimental animal study conducted by Kramer *et al*. (2004), it was examined the healing effects of polyhexanide and octenedine on standardized skin wounds. Octenidine delayed the wound contraction significantly at the 9th day of early healing, compared to polyhexanide and placebo when complete wound closure times were examined, it was reported to provide complete wound regeneration longer time than polyhexanide (Kramer *et al*., 2004). Schmit-Neuerburg *et al*.(2001) showed that polyhexanide is highly active and that it provides rapid wound healing and cell or tissue tolerability it is good, they studied the effect of gauze compresses soaked in 0.04% polyhexanide in comparison with Ringer solution in a study in 85 patients. The polyhexanide group showed improved wound healing with a significantly more rapid reduction of Gram-positive organisms and better tissue compatibility than the control group. In a study by Daeschlein *et al*. (2007), in treating second-degree burns, they compared the effects of polihexamethylene biguanide, povidone-iodine and silver nitrate. It has been reported, that polihexamethylene biguanide has a clear superiority on epithelium formation in long-term burn treatment and the in-vitro tolerance is better. All these studies show the efficacy of polyhexanide in skin antisepsis. In our study similar to the findings of previous researchers (Schmit-Neuerburg *et al*., 2001; Kramer *et al*., 2004; Daeschlein *et al*., 2007). *S. aureus* (ATCC) could not be isolated during 3 days following wound healing in polyhexanide treated group and the wound healing rate was higher than the control group. This research has shown that polyhexanide can be used in the treatment of wound healing, as well as the antibacterial activity of polyhexanide in wounds with tissue loss infected by *S. aureus* (ATCC).

CONCLUSION

In conclusion, we believe that this antiseptic polyhexanide may be a good alternative in cases of widespread skin and wound colonization in wounds due to skin and soft tissue infections. At the same time, we consider that polyhexanide has beneficial effects on wound healing, both due to its antibacterial effect and high tissue compatibility, control of wound infection and healing by accelerating the reduction of tissue defect diameters in wounds with tissue loss. In our research, it has been shown that argan oil seems to be a good choice, especially as a powerful remedy for the treatment of infected wounds.

ACKNOWLEDGEMENT

We want to thank Çukurova University Health Sciences Experimental Application and Research Center and its staff, as well as Veterinary Health Technician/Operating Room Supervisor Faruk UĞUR, for allowing this study to be carried out.

Additional information

This research received no grant from any funding agency/ sector. The data supporting this study's findings are available on request from the corresponding author (Selvinaz YAKAN). This study was presented as an oral presentation at the "1st International Conference on Life and Engineering Sciences (ICOLES), Kyrenia, Cyprus, 2018".

Informed consent

The research was carried out at Çukurova University Health Sciences Experimental Application and Research Center between May and August 2018, after receiving the approval of the Çukurova University Experimental Animals Local Ethics Committee (approval number: 2018-01/05).

Conflict of interest

The authors declare that they have no conflict of interest. "I (We) declare that this study was done by the authors named in this article and all liabilities about claims relating to the content of this article will be borne by the authors".

REFERENCES

Adamson, T.W., Kendall, L.V., Goss, S., Grayson, K., Touma, C., Palme, R., Chen, J.Q., Borowsky, A.D. (2010). Assessment of carprofen and buprenorphine on recovery of mice after surgical removal of the mammary fat pad. Journal of the American Association for Laboratory Animal Science. 49(5): 610-616.

Alkan, Z. (1987). Yara iyileşmesinin plesenta kullanilmasiyla hizlandirilmasi. Ankara Üniversitesi Veteriner Fakültesi Dergisi. 34: 519-533. doi: 10.1501/Vetfak_0000001112.

Allen, M.J., White, G.F., Morby, A.P. (2006). The response of *Escherichia coli* to exposure to the biocide polyhexamethylene biguanide. Microbiology. 152: 989-1000. doi: 10.1099/mic.0.28643-0.

Asada, M., Nakagami, G., Minematsu, T., Nagase, T., Akase, T., Huang, L., Yoshimura, K., Sanada, H. (2012). Novel models for bacterial colonization and infection of full-thickness wounds in rats. Wound Repair and Regeneration. 20(4): 601-610. doi: 10.1111/j.1524-47 5X.2012.00800.x.

Avsar, U., Halici, Z., Akpinar, E., Yayla, M., Avsar, U., Un, H., Tarik, A.H., Bayraktutan, Z. (2016). The effects of Argan oil in second-degree burn wound healing in rats. Ostomy Wound Management. 62(3): 26-34.

Calame, W., Feitsma, H.I., Ensing, G.J., Goedemans, W.T., Camps, J.A., van Furth, R., Pauwels, E.K. (1991). Detection of a local staphylococcal infection in mice with technetium-99 m-labeled polyclonal human immunoglobulin. Journal of Nuclear Medicine. 32(3): 468-474.

Charrouf, Z., Guillaume, D. (2009). Sustainable development in Northern Africa: The Argan forest case. Sustainability. 1: 1012-1022. doi: 10.3390/su1041012.

Cherki, M., Derouiche, A., Drissi A., el Messal, M., Bamou, Y., Idrissi-Ouadghiri, A., Khalil, A., Adlouni, A. (2005). Consumption of argan oil may have an antiatherogenic effect by improving paraoxonase activities and antioxidant status: Intervention study in healthy men. Nutrition Metabolism and Cardiovascular Diseases. 15(5): 352-360. doi: 10.1016/j.numecd.2004.08.005.

Citil, M.U., Mete, E., Oguz, E.O., Abban, G.M., Sahin, B., Kaleli, I. (2015). Investigation of the effect of ibuprofen on wound healing in experimental *Staphylococcus aureus* soft tissue infections. Mikrobiyoloji Bülteni. 49(2): 166-180. doi: 10.5578/mb.9234.

Daeschlein, G., Assadian, O., Bruck, J.C., Meinl, C., Kramer, A., Koch, S. (2007). Feasibility and clinical applicability of polihexanide for treatment of second-degree burn wounds. Skin Pharmacology and Physiology. 20(6): 292-296. doi: 10.1159/000107577.

Dealey, C., Posnett, J., Walker, A. (2012). The cost of pressure ulcers in the United Kingdom. Journal of Wound Care. 21(6): 261-262. doi: 10.12968/jowc.2012.21.6.261.

El Babili, F., Bouajila, J., Fouraste, I., Valentin, A., Mauret, S., Moulis, C. (2010). Chemical study, antimalarial and antioxidant activities, and cytotoxicity to human breast cancer cells (MCF7) of *Argania spinosa*. Phytomedicine. 17(2): 157-160. doi: 10.1016/j.phymed.2009.05.014.

Gardner, S.E., Frantz, R.A., Doebbeling, B.N. (2001). The validity of the clinical signs and symptoms used to identify localized chronic wound infection. Wound Repair and Regeneration. 9(3): 178-186. doi: 10.1046/j.1524-475x.2001.00178.x.

Gauglitz, G.G., Korting, H.C., Pavicic, T., Ruzicka, T., Jeschke, M.G. (2011). Hypertrophic scarring and keloids: Pathomechanisms and current and emerging treatment strategies. Molecular Medicine. 17(1-2): 113-125. doi: 10.2119/molmed.2009.00153.

Horrocks, A. (2006). Prontosan wound irrigation and gel: management of chronic wounds.British Journal of Nursing. 15(22): 1224-1228. doi.10.12968/bjon.2006.15.22.22559.

Hubner, N.O., Kramer, A. (2010). Review on the efficacy, safety and clinical applications of polihexanide, a modern wound antiseptic. Skin Pharmacology and Physiology. 23: 17-27. doi: 10.1159/000318264.

Khallouki, F., Younos, C., Soulimani, R., Oster, T., Charrouf, Z., Spiegelhalder, B., Bartsch, H., Owen, R.W. (2003). Consumption of argan oil (Morocco) with its unique profile of fatty acids, tocopherols, squalene, sterols and phenolic compounds should confer valuable cancer chemopreventive effects. European Journal of Cancer Prevention. 12(1): 67-75. doi: 10.1097/00008469-200302000-00011.

Kramer, A., Roth, B., Muller, G., Rudolph, P., Klocker, N. (2004). Influence of the antiseptic agents polyhexanide and octenidine on FL cells and on healing of experimental superficial aseptic wounds in piglets-A double-blind, randomised, stratified, controlled, parallel-group study. Skin Pharmacology and Physiology. 17(3): 141-146. doi: 10.1159/000077241.

Marfil, R., Gimenez, R., Martinez, O., Bouzas, P.R., Fufian-Henares, J.A., Mesias, M., Carmen, C. (2011). Determination of polyphenols, tocopherols and antioxidant capacity in virgin argan oil (*Argania spinosa*, Skeels). European Journal of Lipid Science and Technology. 113: 886-893. doi: 10.1002/ejlt201000503.

Mekhfi, H., Belmekki, F., Ziyyat, A., Legssyer, A., Bnouham, M., Aziz, M. (2012). Antithrombotic activity of argan oil: An *in vivo* experimental study. Nutrition. 28(9): 937-941. doi: 10. 1016/j.nut.2011.11.032.

Mohan, A., Kumar, B.R. (2018). Clinical studies on the use of herbal chitosan spray for the clinical management of dog bitten wounds in veterinary practice. Indian Journal of Animal Research. 52(7): 1091-1097. doi: 10.18805/ijar.B-3324.

Morton, J.F., Voss, G.L. (1987). The argan tree (Argania-Sideroxylon, Sapotaceae), a desert source of edible oil. Economic Botany. 41(2): 221-233. doi: 10.1007/BF02858970.

Mulvey, M.R., Chui, L., Ismail, J., Louie, L., Murphy, C., Chang, N., Alfa, M., Mo, C.C.S. (2001). Development of a Canadian standardized protocol for subtyping methicillin-resistant *Staphylococcus aureus* using pulsed-field gel electrophoresis. Journal of Clinical Microbiology. 39(10): 3481-3485. doi: 10.1128/JCM.39.10.3481-3485.2001.

Park, S.I., Sunwoo, Y.Y., Jung, Y.J., Chang, W.C., Park, M.S., Chung, Y.A., Maeng, L.S., Han, Y.M., Shin, H.S., Lee, J., Lee, S.H. (2012). Therapeutic effects of acupuncture through enhancement of functional angiogenesis and granulogenesis in rat wound healing. Evidence-Based Complementary and Alternative Medicine. 1-10. doi: 10.1155/2012/464586.

Rietkotter, J., Korber, A., Grabbe, S., Dissemond, J. (2007). Eradication of methicillin-resistant Staphylococcus aureus in a chronic wound by a new polyhexanide hydrogel. Journal of the European Academy of Dermatology and Venereology. 21(10): 1416-1417. doi: 10.1111/j.1468-3083.2007.02217.x.

Rosin, M., Welk, A., Kocher, T., Majic-Todt, A., Kramer, A., Pitten, F.A. (2002). The effect of a polyhexamethylene biguanide mouthrinse compared to an essential oil rinse and a chlorhexidine rinse on bacterial counts and 4-day plaque regrowth. Journal of Clinical Periodontology. 29(5): 392-399. doi: 10.1034/j.1600-051X.2002.290503.x.

Sahin, S., Saygun I., Kurt, B., Canakci, F.C., Akyol, M., Altug, H.A., Kurtis, B., Sencimen, M. (2009). Lokal antimikrobiyal ajanların palatinal bölgeden alinan greft alanindaki doku defektinin iyileþmesi üzerine etkilerinin histomorfometrik yöntemle incelenmesi. Gülhane Tip Dergisi. 51: 27-33.

Samane, S., Christon, R., Dombrowski, L., Turcotte, S., Charrouf, Z., Lavigne, C., Levy, E., Bachelard, H., Amarouch, H., Marette, A., Haddad, P.S. (2009). Fish oil and argan oil intake differently modulate insulin resistance and glucose intolerance in a rat model of dietary-induced obesity. Metabolism-Clinical and Experimental. 58(7): 909-919. doi: 10.1016/j.metabol.2009.02.013.

Schmit-Neuerburg, K., Bettag, C., Schlickewei, W., Fabry, W., Hanke, J., Renzig-Köhler, K., Hirche, H., Kock, H.J. (2001). Wirksamkeit eines neuartigen antisepticum in der behandlung kontaminierter weichteilwunden. Der Chirurg. 72: 61-71. doi: 10.1007/s001040051269.

Shukla, S., Nayak, A., Sharma, R.K., Shukla, P.C., Singh, R.V. (2022). Bacteriophages: A potential new therapeutic alternate to antibiotics to treat chronic septic wounds in large animals. Indian Journal of Animal Research. 56(10): 1279-1282. doi:10.18805/IJAR.B-4317.

Valenzuela, A.R., Perucho, N.S. (2008). The effectiveness of a 0.1% polyhexanide gel. Revista de Enfermeria. 31(4): 7-12.

Yavuz, U., Dinc, H., Yigin A., Yumusak, N., Aslan, M., Yoldas, A., Ozel, A., Mýzraklýdag, A.S. (2022). Investigation of the effects of micromeria congesta essential oil extract on wound healing in rabbits and molecular genetics applications. Indian Journal of Animal Research. 56(2): 215-221. doi: 10.18805/ijar.B-1289.

Yildiz, Y., Gul, S., Yakan, S. (2015). Investigation of effects of essential oils of Cumin (*Cuminum cyminum*) and Wild Thyme (*Thymbra spicata*) on human lymphocyte chromosomes. Eastern Anatolian Journal of Science. 1: 87-97.