RESEARCH ARTICLE Indian Journal of Animal Research, Volume 59 Issue 2: 226-235 (February 2025)

Impact of *Boswellia serrata* Supplementation on Cytokines Profile, Antioxidant Status and NF-KB Expression in the Spleen and Thymus of Rats

Abeer Alahmari[1], Amin A. Al-Doaiss[1]

10.18805/IJAR.BF-1888

ABSTRACT

Background: *Boswellia serrata* (BS) is one of the medicinal plants that possess antioxidant and anti-inflammatory activities. This study aimed to investigate BS resin effect on cytokine levels, antioxidant status and NF-κB expression in the spleen and thymus of rats in a dose-dependent manner.

Methods: Twenty male rats were divided equally into four groups. The 1st group was served as a control, while the 2nd, 3rd and 4th groups were treated orally with gradual doses of BS (50, 100 and 150 mg/kg). After 30 days, all rats were sacrificed and their serum, spleen and thymus were collected for estimating the cytokines (IL-1α, IL-1β, IL-6 and TNF-α) levels and for the analysis of antioxidant markers (superoxide dismutase, catalase, glutathione and total antioxidant capacity). NF-κB expression and histopathological examination of the spleen and thymus were also studied.

Result: Our results showed the IL-6 level significantly increased in response to all dosages of the BS. While the high dose of BS (H-BS) led to a significant increase in IL-1β level, histopathological alterations in the spleen and thymus and intense expression of NF-κB in the red pulp of the spleen. We also noticed that the H-BS led to a highly increase in the levels of glutathione and total antioxidant capacity compared to control. Our results provide evidence that the intake of BS in specified dosages can boost the immune system and may have advantageous health effects on cellular redox homeostasis due to its rich content of sesquiterpenoids and triterpenoids.

Key words: Antioxidant status, *Boswellia serrata*, Cytokines, NF-κB, Spleen, Thymus.

INTRODUCTION

Plant-derived resources have expanded importance in recent pharmaceutical investigations. They supply raw materials possessing medicinal properties needed to prepare drugs with economic and therapeutic value (Kandpal *et al*., 2023). According to several scientific reports, the organic contents of these resources have antioxidant and anti-inflammatory capabilities that considerably prevent aging, pain and inflammation by supporting the repair of cellular structure and function and, as a result, boosting the physiological activity of the body (Alraddadi and Shin, 2022; Michalak *et al*., 2023).

Boswellia is one of the famous medicinal plants that has shown its pharmaceutical activities in animal models (D'Amico *et al*., 2022). It belongs to the Burseraceae family, which is grown in dry areas in Asia and East Africa. This family has been utilized for its fragrant qualities and therapeutic uses since ancient times (Thulin, 2020). *Boswellia* species are known for their aromatic essential oils and gum resins, which are popularly referred to as olibanum and frankincense (Najar *et al*., 2020). These products are widely used in traditional Arab and Chinese medicine to treat various illnesses such as fever, pain, asthma, rheumatoid arthritis and swelling (Schmiech *et al*., 2019). The *Boswellia* gum resin, which is generated as a milky liquid from cracks in the bark of the stems, has a broad spectrum of bioactive ingredients, including monoterpenes, diterpenes and triterpenes, as well as being a major source of boswellic acids such as tetracyclic and pentacyclic triterpene acids (Abdel-Tawab *et al*., 2011; Alluri *et al*., 2020). These components have been reported to be responsible for the therapeutic activities of *Boswellia* (Massei *et al*., 2023).

The mechanisms by which *Boswellia* resin protects the cells from oxidative stress and inflammation are not fully clarified. It has been found to have effective anti-inflammatory properties by inhibiting the inflammatory pathway of 5-LOX and then suppressing the production of proinflammatory cytokines (Shin *et al*., 2022). Several *in vivo* and *in vitro* studies demonstrated that efficiency of *Boswellia* resin extract in the attenuation of oxidative stress

[1]Department of Biology, Faculty of Science, King Khalid University, P.O. Box 9004, Abha 61413, Saudi Arabia.

Corresponding Author: Abeer Alahmari, Biology Department, Faculty of Science, King Khalid University, P.O. Box 9004, Abha 61413, Saudi Arabia. Email: alahmry@kku.edu.sa.
ORCID: 0000-0001-6310-7815, 0000-0003-3875-9840

How to cite this article: Alahmari, A. and Al-Doaiss, A.A. (2025). Impact of *Boswellia serrata* Supplementation on Cytokines Profile, Antioxidant Status and NF-KB Expression in the Spleen and Thymus of Rats. Indian Journal of Animal Research. 59(2): 226-235. doi: 10.18805/IJAR.BF-1888.

Submitted: 06-09-2024 **Accepted:** 21-10-2024 **Online:** 22-11-2024

through its free radical-scavenging activity (Beghelli *et al*., 2017; Barakat *et al*., 2018). Additionally, it may mitigate the oxidative damage in tissues *via* inhibiting lipid peroxidation and improving antioxidant status (D'Amico *et al*., 2022). Furthermore, the scientific studies have illustrated that this resin and its isolated compounds demonstrated significant benefits in the treatment of gastrointestinal diseases (Tambe *et al*., 2019), type II diabetes mellitus (Khalili *et al*., 2017) and different types of cancers (Parsonidis *et al*., 2019) assisting to support individual health and to resist pathological illnesses. Also, it has been proven that *Boswellia* resin significantly alle*via*.tes the neurodegenerative features of Alzheimer's disease in rats (Mohamed *et al*., 2021). These therapeutic potentials predict promising pharmacological applications of *Boswellia* resin.

To take advantage of the *Boswellia* resin benefits, it is important to define a safe dose for its daily consumption. Hence, the current research was aimed at quantifying the main components in the aqueous *Boswellia serrata* (BS) extract as well as the correlation between gradual doses (low, medium and high) and immunoactivity and antioxidant status in rats. Additionally, it will reveal histopathological alteration in the spleen and thymus gland.

MATERIALS AND METHODS

The research was conducted during the period (2023, August to 2024, June) at the Central Lab, Science College, King Khalid University (KKU), Saudi Arabia, Abha.

BS resin gum collection and preparation

BS was purchased from the Elhekma herbal market in Jeddah, Saudi Arabia, in the form of resin gum. It was washed with distilled water, then dried at room temperature. The dried resin was crushed into powder. About 50 grams of the powder were dissolved in 500 mL of distilled water for 24 hours at room temperature. The supernatant was placed into 50-mL Falcon tubes and centrifuged for ten minutes at 1000 rpm (Khalaj-Kondori *et al*., 2016). Then, Whatman No. 1 filter paper was used to filter the supernatants, which were diluted after that to obtain the required doses (50, 100 and 150 mg/kg) for the animals' subsequent feeding, then kept them at 4°C until used.

GC/MS analysis of aqueous BS extract

Phytoconstituents of an aqueous BS extract were analyzed using a Trace GC-TSQ mass spectrometer (Thermo Scientific, Austin, TX, USA) with a direct TG-5MS capillary column. The temperatures of the MS transfer line and injection port were maintained at 260°C and 270°C, respectively. The temperature of the column oven was started at 50°C and raised to 250°C (by 5°C/min), which was held for 2 minutes. Then it was raised to the final temperature of 300°C (by 30°C/min), which was held for 2 minutes. The mass spectra were measured at 70 eV, with the carrier gas being helium at a constant flow rate of 1 ml/min. The phytochemical constituents of BS have been recognized through the comparison of their mass fragmentation characteristics to those of the standard information data from the WILEY 09 and NIST 14 mass spectral databases.

Animal and study grouping

This research was performed on 20 adult male Sprague-Dawley rats weighing 200±50 g (6-8 weeks). The rats were obtained from the animal house of the Science College at King Khalid University (Abha, Saudi Arabia). For acclimatization before the experiment, each of the five rats was randomly put in a polycarbonate cage under standard humidity (45±5%) and temperature (25±2°C) with a 12-hour light/dark cycle. Animals were given free access to water and standard food. After acclimatization, the rats were orally treated as follows for 4 weeks (Khalaj-Kondori *et al*., 2016).

The control group

Received distilled water without any treatment.

L-BS group

Treated with a low dose of BS extract (50 mg/kg).

M-BS group

Treated with a medium dose of BS extract (100 mg/kg).

H-BS group

Treated with a high dose of BS extract (150 mg/kg).

Samples collection and preparation

Twenty-four hours after the last administration, all rats were sacrificed under ether anesthesia. Blood samples were taken *via.* direct heart punctures in non-heparinized tubes and allowed to clot at room temperature. To obtain clear serum, the blood samples were centrifuged at 3000 rpm for 10 minutes and then kept as aliquots at -18°C for evaluation of cytokine levels (Li *et al*., 2022a). The spleen and thymus were rapidly removed, washed with distilled water and then divided into two parts. One section was homogenized in cold PBS (10 mL/mg tissue) and centrifuged at 3000 rpm for 15 min (4°C) (Farag *et al*., 2021). The supernatant was preserved at - 20°C until used for measuring antioxidant levels. The other section was fixed in 10% formalin, dehydrated, embedded in paraffin and then cut into thick sections (4-5 μm) for histological and immunohistochemical examination.

Determination of cytokine levels in serum

The Milliplex Rat Cytokine/Chemokine Kit (MilliporeSigma, Germany) was used for simultaneous quantification of IL-1α, IL-1β, IL-6 and TNF-α (pg/mL) in the serum of all rats in triplicate in a 96-well microplate using a Bio-Plex xMAP Analyzer assays according to the protocol of the kit.

Estimation of endogenous antioxidant production in the spleen and thymus

To evaluate the production of endogenous antioxidants, levels of GSH, SOD, CAT and TAC were quantified in the spleen and thymus homogenates of all rats using

commercial ELISA kits (MyBioSource.com, USA) according to the manufacturer's instructions. An ELISA reader was used to read the absorbance of each marker at 450 nm.

Histopathological examination of spleen and thymus tissues

The thick sections of both the spleen and thymus were deparafûnized, rehydrated and stained with hematoxylin and eosin (H and E). The histological structure of the spleen and thymus was examined under a light microscope (Omax-M837ZL, China).

Expression of NF-κB p65 in spleen and thymus tissue

NF-κB p65 expression in spleen and thymus tissues was assayed by immunohistochemistry technique using anti-NF-kappaB p65 (phospho Ser276) antibody (Cat No. A93736, antibodies.com, UK). Paraffin-embedded sections of spleen and thymus were dewaxed with xylene, rehydrated with a series of graded alcohols and then heated for antigen retrieval using a microwave. These sections were incubated for 10 min in 3% H_2O_2/methanol as a blocking reagent, then treated overnight with NF-κB p65 primary antibody at 4°C. Next, all sections were incubated at 37°C with anti-rabbit secondary antibody for 30 min, followed by a 3,30-diaminobenzidine (DAB) reagent kit (Cat. No. ab64238, Abcam, UK) for color development. Finally, the background of the sections was stained with hematoxylin. The expression of NF-κB p65 in spleen and thymus tissues was examined under a light microscope (Omax-M837ZL, China), where the appearance of a brown color (positive stain) indicates the expression of NF-κB p65 in the tissue.

Statistical analysis

All data are presented as the mean±standard error of the mean (SEM). Statistical analysis of data was conducted by one-way ANOVA followed by a Tukey test using SPSS software (version 25, USA) to estimate the statistical differences between experimental groups at $P<0.05$.

RESULTS AND DISCUSSION

Phytoconstituent analysis of aqueous BS extract using GC/MS

The GC/MS analysis on the aqueous BS extract showed that the main bioactive constituents had a shorter retention time (RT) (19-45 min). Two major components of sesquiterpenoid, namely nerolidol-epoxyacetate (peak 1) and furoscrobiculin B (peak 3), were identified in the extract at 360 nm. Also, the GC/MS analysis of BS revealed the presence of two major compounds of triterpenoid, α-Amyrin (peak 2) and α-Amyrone (peak 4) at 360 nm, as shown in Fig 1.

Alteration of cytokine levels in serum by different doses of BS extract

From the data presented in Fig 2, all doses of BS extract (50, 100 and 150 mg/kg) did not significantly affect both IL-1α and TNF-α levels ($P\geq0.05$) compared to the control. Considering the IL-1β, only H-BS extract (150 mg/kg) induced remarkable elevation in its production ($P\geq0.01$), while no significant changes were observed after treatment with both M-BS (100 mg/kg) and L-BS (50 mg/kg) doses

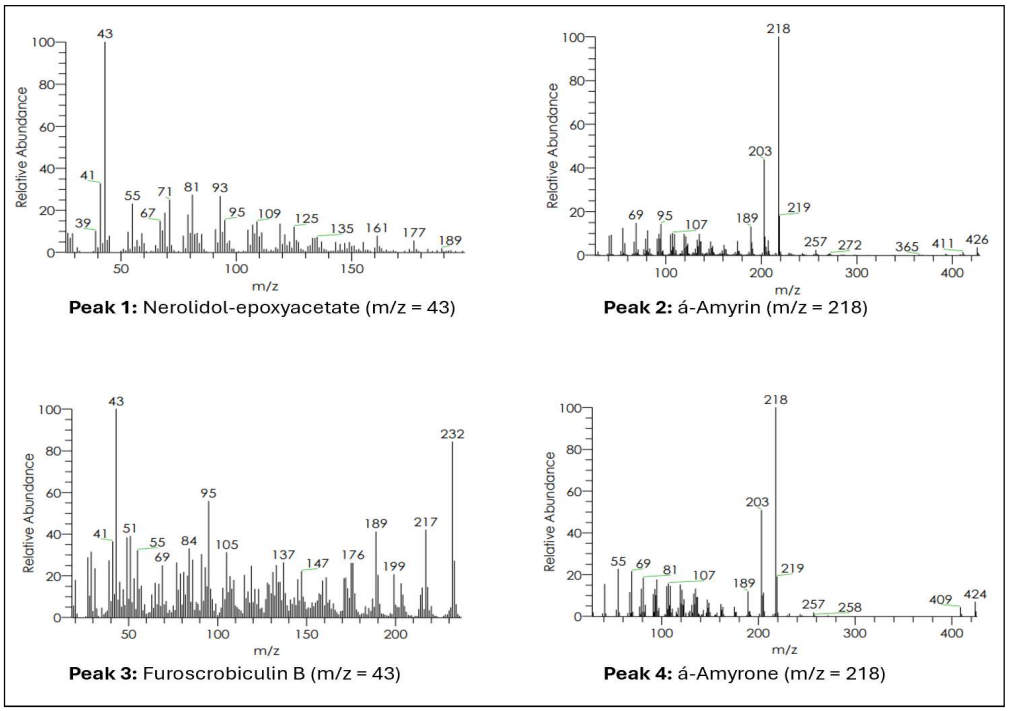

Fig 1: GC/MS chromatograms of aqueous BS extract showing the relevant molecular ion peaks of identified components in the extract.

compared to control (P≥0.05). Regarding IL-6, all doses of extract led to a significant increase in its level compared to the control.

Impact of aqueous BS extracts on the production of endogenous antioxidants in the spleen and thymus

Results in Table 1 suggested that the most reduction in endogenous antioxidant levels was seen after being treated with L-BS (50 mg/kg) in both spleen and thymus tissues and then their levels gradually increased as the dose increased (M-BS and H-BS), but they did not reach the level of the control group, except that TAC in spleen was not affected by the M-BS (100 mg/kg) and remained at the same level as the control (P≥0.05). On the other hand, we noticed that the levels of GSH in the spleen and thymus, as well as TAC in the spleen, were highly elevated (P≥0.0001) after treatment with H-BS (150 mg/kg) compared to those levels in the control.

Histopathological changes in the spleen tissue induced by aqueous BS extract

Examination of spleen sections from the control group showed that the parenchyma of the spleen is composed of white and red pulp areas. The white pulp consists of the central artery surrounded by the periarterial lymphoid sheath, with a normal distribution of lymphocytes in the lymphatic nodule. In between the white pulp is the red pulp, which is composed of splenic cords from Billroth and sinusoids. The red pulp (RP), which is composed of splenic cords and blood sinusoids, both of which contain blood cells of all types, splenic cords that are highly cellular contain plasma cells, white blood cells and lymphocytes. The splenic sinusoids contain blood cells of all types (Fig 3A-B). The spleen of the L-BS group (Fig 3C-D) demonstrated a normal, well intact splenic architecture and the absence of any alterations. In the M-BS group (Fig 3E-F), splenic tissue showed normal splenic architecture except for the appearance of congested central arteriole in some areas of the white pulp. In the H-BS group (Fig 3G-H), splenic sections showed loss of architecture in the spleen parenchyma with diffused and disorganized splenic white pulp and congested central arteriole; the red pulp showed megakaryocytes and giant cells with dilated blood sinusoids.

Histopathological changes in the thymus tissue induced by aqueous BS extract

Thymus sections of all the groups were analyzed. The architecture of the thymus gland of control rats showed intact and well-preserved normal histological structure, with thymic lobes and lobules of various sizes and orientations divided by connective septa. Each lobule had an externally stained cortex that surrounded and encased the slightly paler medulla. Thymocytes, or T-cells and pale-stained epithelial reticular cells are found in the thymic cortex. There are tiny lymphocytes in the thymic medulla. Compared to the cortex, which is composed primarily of closely spaced microscopic lymphocytes and a small number of epithelial reticular cells, the medulla is paler in color and has a

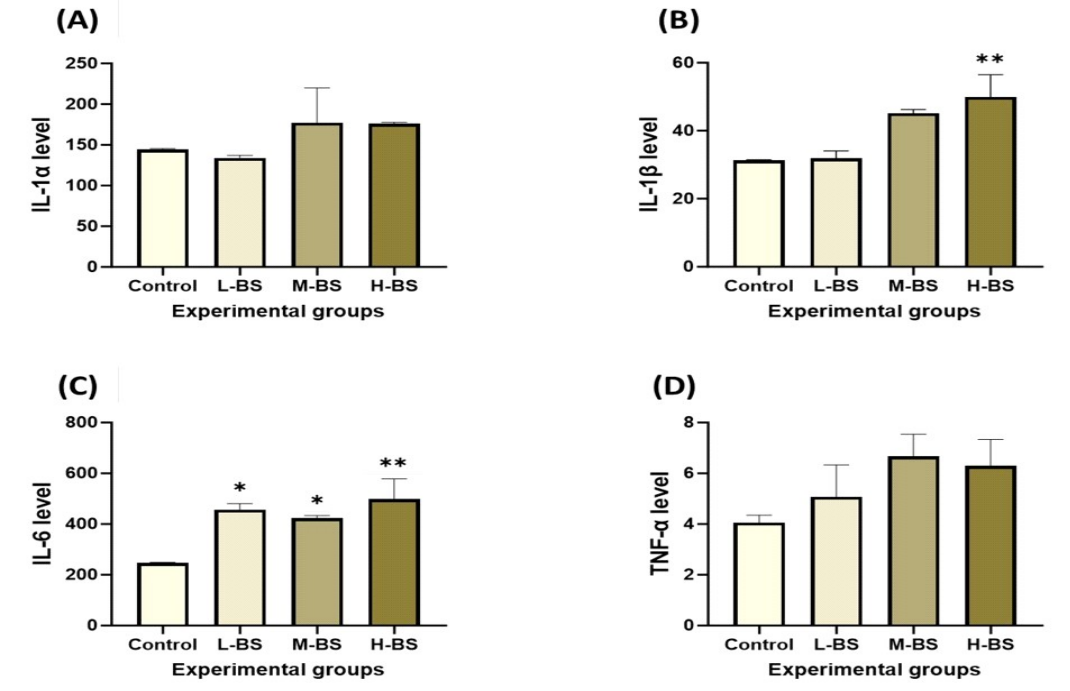

L-BS: Low-dose of BS extract (50 mg/kg); M-BS: Medium-dose of BS extract (100 mg/kg); H-BS: High-dose of BS extract (150 mg/kg). All values are mean ± SEM, n = 5, *P≥0.05, **P≥0.01 compared to control.

Fig 2: The effect of different doses of aqueous BS extract on IL-1α (A), IL-1β (B), IL-6 (C) and TNF-α (D) in serum.

Table 1: Effect of gradual doses of aqueous BS extract on the endogenous antioxidant levels in the spleen and thymus of rats after 4 weeks of treatment.

Groups	Spleen				Thymus			
	GSH ng\mL	SOD u\mL	CATM u\L	TAC ng\mL	GSH ng\mL	SOD u\mL	CATM u\L	TAC ng\mL
Control	12.35±0.29	199±0.45	137±1.34	5.90±0.31	14.55±0.47	188.5±0.67	131±3.58	8.15±0.11
L-BS (50 mg/kg)	7.90±0.27****	100±5.37****	73±2.46****	4.15±0.11****	9.95±0.20****	93±1.34****	88±1.34****	3.60±0.13****
M-BS (100 mg/kg)	10.25±0.17***	121±1.79****	81±2.91****	5.15±0.07	12.10±0.13****	113.5±3.35****	95±2.24****	4.95±0.02****
H-BS (150 mg/kg)	17.75±0.47****	164±3.36****	114±1.79****	8.55±0.34****	20.40±0.27****	158.5±0.67****	118±1.34**	6.65±0.16****

All data are mean ± SEM; n = 5; **$P \leq 0.01$, ***$P \leq 0.001$ and ****$P \leq 0.0001$ compared to control.

lower cell density. There were numerous large lymphocytes and epithelial reticular cells present (Fig 4A-B). In the thymus of the L-BS group (Fig 4C-D) and the M-BS group (Fig 4E-F), demonstrated thymic lobules with normal architecture and the absence of any alterations. The thymus of the H-BS group (Fig 4G-H) showed a thymic lobule with disfigurement in the organization, loss of corticomedullary demarcation and necrotic foci associated with hyperplastic epithelial cells that form tubules that contain eosinophilic secretory materials (Fig 4G-H).

Effect of aqueous BS extract on the expression of NF-κB p65 in spleen and thymus tissues

Our results illustrated the lack of NF-κB p65 expression in the white pulp of spleen tissues obtained from all groups (Fig 5). Regarding red pulp, we noticed moderate expression of cytoplasmic NF-κB p65 in some areas of the splenic control group (Fig 5A). In the L-BS group, weak expression of cytoplasmic NF-κB p65 was observed along the parenchyma of the red pulp (Fig 5B). While its expression was noticed to be moderate in M-BS and intense in H-BS in both the parenchyma of red pulp and the congested central arteriole (Fig 5C and D, respectively). In thymus tissue, negative expression of NF-κB p65 was detected in the control and all experimental groups, as shown in Fig 5 E-H.

Natural dietary products are used a long time ago to treat various diseases due to their pharmaceutical properties as well as their low side effects (Mech *et al*., 2021). Among the common dietary products is *Boswellia* gum resin. Our research revealed that aqueous B. serrata extract has a significant amount of sesquiterpenoids (nerolidol-epoxyacetate and furoscrobiculin B) and triterpenoids (Amyrin and α-Amyrone). The presence of these compounds in the extract is probably related to the antioxidative and anti-inflammatory properties of BS (Cherepanova and Subotyalov, 2023). Sesquiterpenoids are one of the largest family of terpenoids, which have received considerable attention from pharmacologists because of their diverse carbon structures with different ring architectures. Due to their carbon skeletons, sesquiterpenoids have a wide range of therapeutic properties with promising drug development opportunities (Chen *et al*., 2021; Zhan *et al*., 2021). Triterpenoids are secondary plant metabolites with six isoprene units possessing various carbon skeletons (Hillier and Lathe, 2019; Liu *et al*., 2022). They have great importance in the pharmaceutical field due to their unique chemical composition as antioxidant, antiviral, anticancer and analgesic agents (Borella *et al*., 2019; Yasin *et al*., 2021).

The current study demonstrated that oral administration of BSE at a high dose (150 mg/kg) led to significantly elevated IL-1β level. Conversely, the IL-6 level significantly increased in response to all dosages of the extract. While IL-1α and TNF-α were not significantly affected by all doses of the BS extract. In conjunction with

the previous data, immunohistochemical results showed moderate expression of NF-kB at the medium dose and intense expression at the high dose in the red pulp and congested central arteriole of the spleen, while we noticed a lack of NF-κB p65 expression in the thymus. The stimulatory impact of BS on the production of IL-1α and IL-6 in a dose-dependent manner might be related to its rich content of sesquiterpenoid and triterpenoids, which enhance the immune system *via* regulation of the NF-κB pathway, as reported by Yang and colleagues (Yang *et al*., 2020). In a normal state of the body, NF-κB contributes to the enhancement of innate and adaptive immunity through the maturation of immune cells (B and T cells) and the development of secondary lymphoid organs (Serasanambati and Chilakapati, 2016). Since its existence is essential for the synthesis and action of chemokines and cytokines, any factor that stimulates NF-kB will raise the efficiency of the immune system and trigger immune responses (Courtois *et al*., 2015). It has been known that T cells secrete IL-6, a soluble substance that is

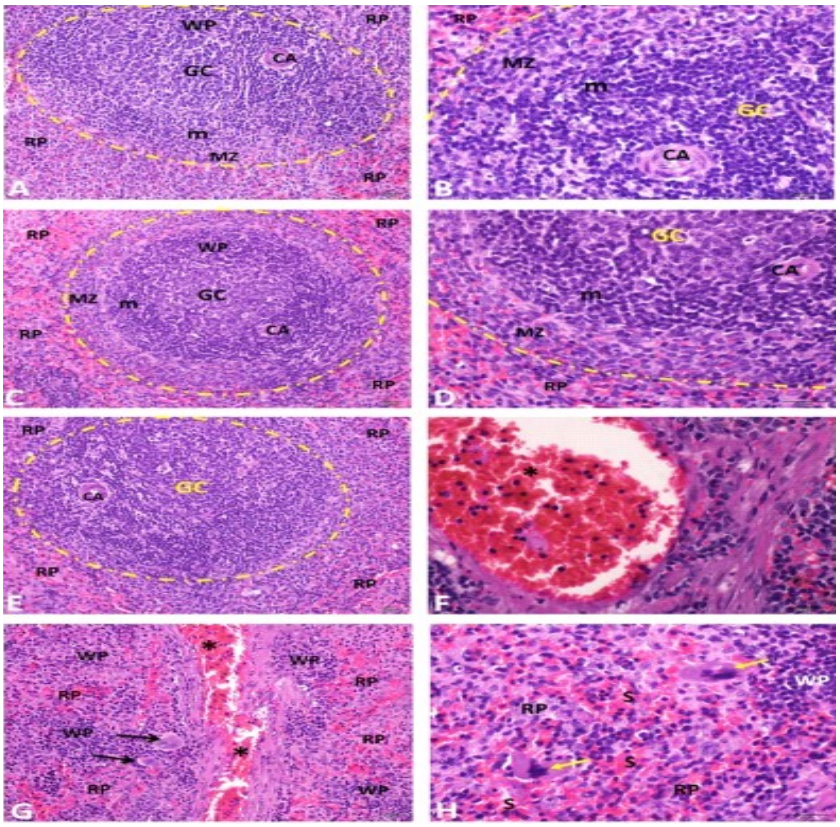

(A): the parenchyma of the spleen of control group consisted of white pulp (WP) in the yellow circle and red pulp (RP) areas. The white pulp formed of lymphoid follicles with an eccentrically located central arteriole (CA). The lymphoid follicles appeared to compose of a germinal center (GC) (only found in secondary follicles) which surrounded by a ring of lymphocytes (mantle zone= m) which surrounded by the marginal zone (MZ) demarcated the splenic lymphoid follicle from the red pulp. The red pulp appeared to be formed of branching splenic cords (Billroth cords) and blood sinusoids in between. 200x. (B): magnified spleen section showing normal white and red pulp areas in spleen of control group. 400x. (C): Section from the L-BS group showing the normal organization of the structure of white pulp (WP) in the yellow circle and red pulp (RP). 200x. (D): magnified spleen section showing normal white and red pulp areas in spleen of L-BS group. 400x. (E): Section from the M-BS group showing the normal organization of the structure of white pulp (WP) in the yellow circle and red pulp (RP). 200x. (F): magnified spleen section showing congested central arteriole in some areas of the white pulp (*). 400x. (G): Section from the H-BS group showing spleen parenchyma with diffused and disorganized splenic white pulp (WP) with megakaryocytes (black arrows) and congested central arteriole (*). 200x. (H): magnified spleen section of red pulp showing megakaryocytes (black arrows) and giant cells (yellow arrows) with dilated blood sinusoids (S) in spleen of H-BS group. 400x.

Fig 3: Photomicrographs of rat spleen stained with H and E stain.

critical for B cells to produce antibodies. Based on experimental research, it has been established that the IL-6 pathway plays a crucial role in immune control in health and disease (Ammon, 2010). Therefore, the significant increase in its secretion after treatment with the BS may be evidence of its effectiveness in enhancing the body's immunity by producing antibodies through the IL-6 pathway, which is stimulated by NF-κB.

Food is one of the most crucial factors influencing our antioxidant status that we can regulate (Papas, 2019). The antioxidative impacts of BS extract were illustrated by measuring antioxidant status indicators (GSH, SOD, CAT and TAC) in spleen and thymus. Our results demonstrated that the levels of antioxidant markers gradually increased as the dose increased but they did not reach those levels of the control group. According to our previous finding, it

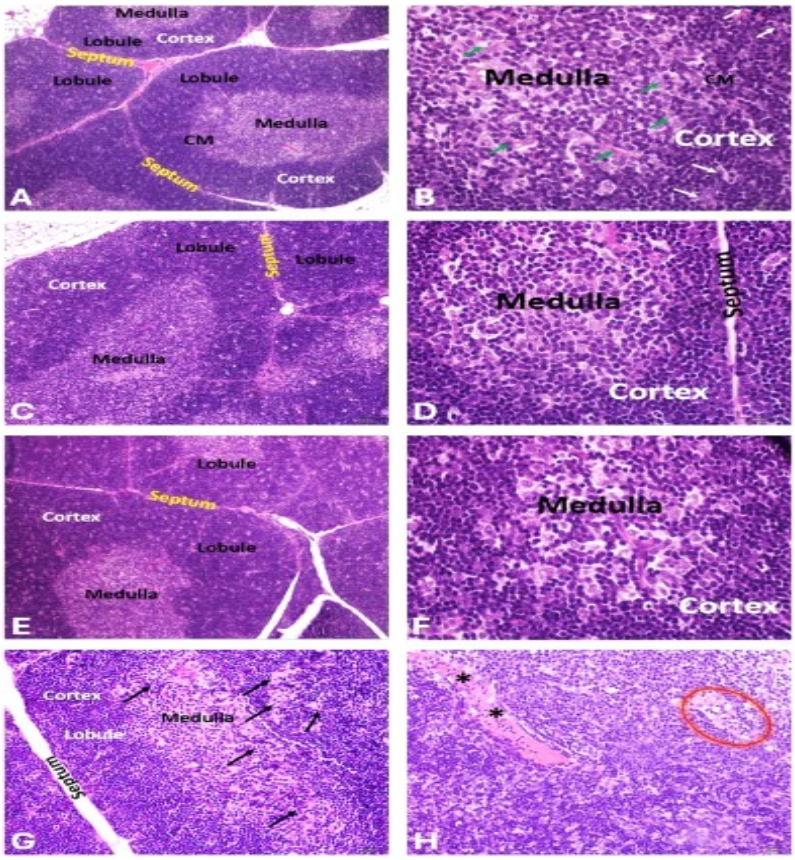

(A): A thymus from a control rat shows a distinct thymic lobule with normal architectures separated by interlobular septa (S), each lobule consists of d outer darkly stained cortex and slightly paler medulla. HandE. 200x. (B): Thymic cortex of control group contains an abundance of developing T-cells (thymocytes) and pale stained epithelial-derived thymic reticular cells (white arrows). Small lymphocytes are present in the normal thymic medulla, they are less dense than in the cortex. Prominent epithelial cells (green arrows) are readily apparent. Hassall's corpuscles are rare in rodents compared to humans. A distinct corticomedullary (CM) junction separates the cortex from medulla. 200x. (C): Sections from L-BS group showed thymic lobules with normal architectures in form of outer darkly stained cortex and slightly paler medulla. 200x. (D): magnified the thymic lobule section showing normal architecture of cortex and medulla of L-BS group. 400x. (E): Section from the M-BS group showing the normal organization of the structure of thymus gland. 200x. (F) magnified the section of thymic lobule showing normal darkly stained cortex and pale medulla of M-BS group. 400x. (G): Section from the H-BS group showed thymic lobule with disfigurement in the organization with loss of corticomedullary demarcation (black arrows), 200x. (H): thymic lobule with necrotic foci (circle) associated with hyperplastic epithelial cells form tubules contains eosinophilic secretory materials (*) in H-BS group. 400x.

Fig 4: Photomicrographs of rat thymus stained with H and E stain.

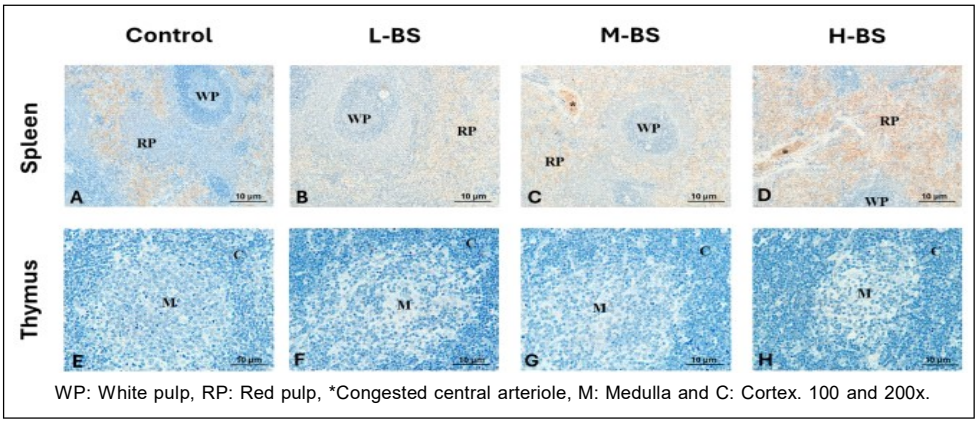

WP: White pulp, RP: Red pulp, *Congested central arteriole, M: Medulla and C: Cortex. 100 and 200x.

Fig 5: Immunohistochemical staining of NF-KB p65 expression (brown) in spleen and thymus tissues of control, L-BS (50 mg/kg), M-BS (100 mg/kg) and H-BS (150 mg/kg).

doesn't appear that the treatment with BS extract has a significant impact on the animal's antioxidant status. On the other hand, the levels of GSH in the spleen and thymus and TAC in the spleen in the H-BS group only were highly elevated and exceeded their levels in the control group. This may be due to the increase in sesquiterpenoid and triterpenoid compounds in the higher dose of the extract (H-BS) compared to the M-BS and L-BS. Based on previous research, practically all plant extracts showed evidence of antioxidant activity when administered. A possible mechanism by which endogenous antioxidants may promote is by the Nrf2 (nuclear erythroid factor-related factor 2)/ARE (antioxidant response element) pathway, which has been demonstrated to be enhanced *via* sesquiterpenoids and triterpenoids (Wu *et al*., 2023), which are the major components in the BS extract. Thereby, our results provide further evidence that H-BS intake as daily supplementation may have advantageous health implications with respect to cellular redox homeostasis. In normal healthy tissues, bodies produce free radicals through a variety of internal mechanisms in a well-regulated manner that aids in cellular homeostasis and serves as a critical second messenger in modifying signaling pathways. The accumulation of free radicals has been linked to aging and other human diseases by modifying lipids, proteins and DNA (Devasagayam *et al*., 2004; Jain and Shakkarpude, 2024). As a normal response, each cell possesses sufficient defensive mechanisms against the harmful consequences of free radicals. Among those mechanisms are endogenous antioxidants, which can eliminate free radicals and their damage in several phases, including intercepting, prevention and repair (Devasagayam *et al*., 2004). GSH and TAC are important markers of the body's antioxidant capacity because it serves as a fundamental cofactor for antioxidant enzymes to preserve cells against oxidizing agents to which cells are exposed. It also participates in biological functions such as cell cycle regulation and protein folding (Averill-Bates, 2023; Silvestrini *et al*., 2023). Therefore, the differently expressed of both biomarkers (GSH and TAC) in rats fed with H-BS in our study demonstrated that these rats are not more likely to experience oxidative stress than the rats that did not take this supplement as a control.

On the other hand, it seems likely that the adverse impacts of high-dose antioxidant consumption outweigh the possible advantages. This is confirmed by our histological examination, which revealed that both organs appeared intact after being treated with L-BS and M-BS, except for the appearance of congested central arterioles in some areas of the splenic white pulp only in M-BS-treated rats. While H-BS led to histopathological alterations in both the spleen and thymus after 4 weeks of treatment. Li and others demonstrated that the intake of high-dose antioxidants inhibits some biological processes of free radicals required for cell signaling, causing disruption of health-enhancing mechanisms that can result in histopathological and physiological changes (Li *et al*., 2022b). Consequently, the high quantity of sesquiterpenoids and triterpenoids in the high dose of BS (150 mg/kg) may be the reason for the histopathological changes that appeared in our study as a side effect of its long-term consumption in such a high amount.

Conclusion

The current study concludes that BS could be ingested as a dietary supplement at specified dosages to enhance the immune system and cellular redox homeostasis due to its rich content of sesquiterpenoid and triterpenoids, which improve the immune system by regulating the NF-kB pathway. As a result, BS could be a promising agent for clinical studies aimed at developing drugs that efficiently treat various diseases.

Acknowledgement

The authors extend their appreciation to the Deanship of Research and Graduate Studies at King Khalid University, KSA, for funding this work through General Research Project under grant number GRP/61/45.

Disclaimers

The views and conclusions expressed in this article are solely those of the authors and do not necessarily represent the views of their affiliated institutions. The authors are responsible for the accuracy and completeness of the information provided, but do not accept any liability for any direct or indirect losses resulting from the use of this content.

Informed consent

All animal procedures for experiments were approved by the Research Ethics Committee at King Khalid University, Saudi Arabia (approval no. ECM#2024-1302).

Conflict of interest

The authors declare that there are no conflicts of interest regarding the publication of this article. No funding or sponsorship influenced the design of the study, data collection, analysis, decision to publish, or preparation of the manuscript.

REFERENCES

Abdel-Tawab, M., Werz, O. and Schubert-Zsilavecz, M. (2011). *Boswellia serrata*: An overall assessment of *in vitro*, preclinical, pharmacokinetic and clinical data. Clinical Pharmacokinetics. 50: 349-369.

Alluri, V.K., Kundimi, S., Sengupta, K., Golakoti, T. and Kilari, E.K. (2020). An anti inflammatory composition of boswellia serrata resin extracts alleviates pain and protects cartilage in monoiodoacetate induced osteoarthritis in rats. Evidence Based Complementary and Alternative Medicine. (1): 7381625.

Alraddadi, B.G. and Shin, H.J. (2022). Biochemical properties and cosmetic uses of *Commiphora myrrha* and *Boswellia serrata*. Cosmetics. 9(6): 119. https://doi.org/10.3390/cosmetics9060119.

Ammon, H.P.T. (2010). Modulation of the immune system by Boswellia serrata extracts and boswellic acids. Phytomedicine. 17(11): 862-867.

Averill-Bates, D.A. (2023). The Antioxidant Glutathione. In: Vitamins and Hormones. Academic Press. 121: 109-141.

Barakat, B.M., Ahmed, H.I., Bahr, H.I. and Elbahaie, A.M. (2018). Protective effect of boswellic acids against doxorubicin induced hepatotoxicity: Impact on Nrf2/HO 1 defense Pathway. Oxidative Medicine and Cellular Longevity. (1): 829-6451.

Beghelli, D., Isani, G., Roncada, P. andreani, G., Bistoni, O., Bertocchi, M. and Alunno, A. (2017). Antioxidant and *ex vivo* immune system regulatory properties of *Boswellia serrata* extracts. Oxidative Medicine and Cellular Longevity. (1): 746-8064.

Borella, R., Forti, L., Gibellini, L., De Gaetano, A., De Biasi, S., Nasi, M. and Pinti, M. (2019). Synthesis and anticancer activity of CDDO and CDDO-Me, two derivatives of natural triterpenoids. Molecules. 24(22): 4097.

Chen, F., Wang, J., Luo, Y., Li, C., Huang, J., Ma, J. and Zhang, D. (2021). Characteristic dihydroagarofuran Sesquiterpenoids with neuroprotective effects from the celastraceae plant *Tripterygium wilfordii*. Chinese Journal of Chemistry. 39(9): 2547-2554.

Cherepanova, M.O. and Subotyalov, M.A. (2023). Component composition and biological activity of oleo-gum resin from boswellia serrata (Burseraceae). In Doklady Biological Sciences (Vol. Moscow: Pleiades Publishing. 512(1): 336-342.

Courtois, G., Pescatore, A., Gautheron, J., Fusco, F., Ursini, M.V. and Senegas, A. (2015). NF-κB-related Genetic Diseases. Springer.

D'Amico, R., Fusco, R., Cordaro, M., Interdonato, L., Crupi, R., Gugliandolo, E. and Di Paola, R. (2022). Modulation of NRF-2 pathway contributes to the therapeutic effects of *Boswellia serrata* gum resin extract in a model of experimental autoimmune myocarditis. Antioxidants. 11(11): 2129.

Devasagayam, T.P.A., Tilak, J.C., Boloor, K.K., Sane, K.S., Ghaskadbi, S.S. and Lele, R.D. (2004). Free radicals and antioxidants in human health: Current status and future prospects. J. Assoc. Physicians India. 52: 794-804.

Farag, M.R., Moselhy, A.A., El-Mleeh, A., Aljuaydi, S.H., Ismail, T. A., Di Cerbo, A. and Abou-Zeid, S.M. (2021). Quercetin alle*via*.tes the immunotoxic impact mediated by oxidative stress and inflammation induced by doxorubicin exposure in rats. Antioxidants. 10(12): 1906. doi: 10.3390/antiox 10121906.

Hillier, S.G. and Lathe, R. (2019). Terpenes, hormones and life: isoprene rule revisited. Journal of Endocrinology. 242(2): R9-R22.

Jain, A. and Shakkarpude, J. (2024). Oxidative stress: A biomarker for animal health and production: A review. Indian Journal of Animal Research. 58(1): 1-12. doi: 10.18805/IJAR.B-5300.

Kandpal, A.S., Kumar, S. and Kandpal, N.K. (2023). Diversity of ethno-medicinal plant: A study in Pithoragarh district of Uttarakhand. Agricultural Reviews. 44(4): 568-572. doi: 10.18805/ag.R-2271.

Khalaj-Kondori, M., Sadeghi, F., Hosseinpourfeizi, M.A., Shaikhzadeh -Hesari, F., Nakhlband, A. and Rahmati-Yamchi, M. (2016). *Boswellia serrata* gum resin aqueous extract upregulates BDNF but not CREB expression in adult male rat hippocampus. Turkish Journal of Medical Sciences. 46(5): 1573-1578.

Khalili, N., Fereydoonzadeh, R., Mohtashami, R., Mehrzadi, S., Heydari, M. and Huseini, H.F. (2017). Silymarin, olibanum and nettle, a mixed herbal formulation in the treatment of type II diabetes: A randomized, double-blind, placebo-controlled, clinical trial. Journal of Evidence-based Complementary and Alternative Medicine. 22(4): 603-608.

Li, Q., Zhang, T., Wang, Y., Yang, S., Luo, J., Fang, F. and Shang, H. (2022a). Qing-Wen-Jie-Re mixture ameliorates poly (I:C)-induced viral pneumonia through regulating the inflammatory response and serum metabolism. Frontiers in Pharmacology. 13: 891-851.

Li, S., Fasipe, B. and Laher, I. (2022b). Potential harms of supplementation with high doses of antioxidants in athletes. Journal of Exercise Science and Fitness. 20(4): 269-275.

Liu, Y., Yang, L., Wang, H. and Xiong, Y. (2022). Recent advances in antiviral activities of triterpenoids. Pharmaceuticals. 15(10): 1169.

Massei, K., Michel, T., Obersat, G. I., Al-Harrasi, A. and Baldovini, N. (2023). Phytochemical study of *Boswellia dalzielii* oleo-gum resin and evaluation of its biological properties. Phytochemistry. 213: 113-751.

Mech, A., Suganthi, U., Rao, S.B.N., Sejian, V., Soren, M., David, C. and Kadakol, V. (2021). Effect of dietary supplementation of linseed oil and natural antioxidants on production performance, fatty acid profile and meat lipid peroxidation in broilers. Asian Journal of Dairy and Food Research. 40(1): 62-68. doi: 10.18805/ajdfr.DR-1592.

Michalak, M., Zagórska-Dziok, M., Klimek-Szczykutowicz, M. and Szopa, A. (2023). Phenolic profile and comparison of the antioxidant, anti-ageing, anti-inflammatory and protective activities of Borago officinalis extracts on skin cells. Molecules. 28(2): 868.

Mohamed, T.M., Youssef, M.A.M., Bakry, A.A. and El-Keiy, M.M. (2021). Alzheimer's disease improved through the activity of mitochondrial chain complexes and their gene expression in rats by boswellic acid. Metabolic Brain Disease. 36: 255-264.

Najar, B., Shortrede, J.E., Pistelli, L. and Buhagiar, J. (2020). Chemical composition and *in vitro* cytotoxic screening of sixteen commercial essential oils on five cancer cell lines. Chemistry and Biodiversity. 17(1): e1900478.

Papas, A.M. (2019). Diet and antioxidant status. Antioxidant Status, Diet, Nutrition and Health. 89-106.

Parsonidis, P., Vlachou, I., Apostolou, P. and Papasotiriou, I. (2019). Effects of natural substances from *Boswellia sacra* and *Nerium oleander* (breastin) in colon and pancreatic cancer. Annals of Oncology. 30: iv19.

Schmiech, M., Lang, S.J., Werner, K., Rashan, L.J., Syrovets, T. and Simmet, T. (2019). Comparative analysis of pentacyclic triterpenic acid compositions in oleogum resins of different Boswellia species and their *in vitro* cytotoxicity against treatment-resistant human breast cancer cells. Molecules. 24(11): 2153.

Serasanambati, M. and Chilakapati, S.R. (2016). Function of nuclear factor kappa B (NF-κB) in human diseases-A review. South Indian Journal of Biological Sciences. 2(4): 368-387.

Shin, M.R., Kim, H.Y., Choi, H.Y., Park, K.S., Choi, H.J. and Roh, S.S. (2022). *Boswellia serrata* extract, 5 Loxin®, Prevents joint pain and cartilage degeneration in a rat model of osteoarthritis through inhibition of inflammatory responses and restoration of matrix homeostasis. Evidence Based Complementary and Alternative Medicine. pp 1-11.

Silvestrini, A., Meucci, E., Ricerca, B.M. and Mancini, A. (2023). Total antioxidant capacity: Biochemical aspects and clinical significance. International Journal of Molecular Sciences. 24(13): 10978.

Tambe, A., Mokashi, P. and Pandita, N. (2019). *Ex-vivo* intestinal absorption study of boswellic acid, cyclodextrin complexes and poloxamer solid dispersions using everted gut sac technique. Journal of Pharmaceutical and Biomedical Analysis. 167: 66-73.

Thulin, M. (2020). The Genus Boswellia (Burseraceae): The Frankincense Trees. Acta Universitatis Upsaliensis.

Wu, Z., Yang, Z., Liu, L., and Xiao, Y. (2023). Natural compounds protect against the pathogenesis of osteoarthritis by mediating the NRF2/ARE signaling. Frontiers in Pharmacology. 14: 118-8215.

Yang, W., Chen, X., Li, Y., Guo, S., Wang, Z. and Yu, X. (2020). Advances in pharmacological activities of terpenoids. Natural Product Communications. 15(3): 1934578X209 03555.

Yasin, M., Younis, A., Ramzan, F., Javed, T., Shabbir, R., Noushahi, H.A. and E.L. Sabagh, A. (2021). Extraction of essential oil from river tea tree (*Melaleuca bracteata* F. Muell.): Antioxidant and antimicrobial properties. Sustainability. 13(9): 4827.

Zhan, Z.C., Wu, Z.N., Tang, Q., Li, C.J., Wang, W.Z., Zhang, J.H. and Li, Y.L. (2021). Sesquiterpenoids from the whole plants of *Chloranthus holostegius* and their anti inflammatory activities. Chinese Journal of Chemistry. 39(5): 1168-1174.